



This is a digital copy of a book that was preserved for generations on library shelves before it was carefully scanned by Google as part of a project to make the world's books discoverable online.

It has survived long enough for the copyright to expire and the book to enter the public domain. A public domain book is one that was never subject to copyright or whose legal copyright term has expired. Whether a book is in the public domain may vary country to country. Public domain books are our gateways to the past, representing a wealth of history, culture and knowledge that's often difficult to discover.

Marks, notations and other marginalia present in the original volume will appear in this file - a reminder of this book's long journey from the publisher to a library and finally to you.

Usage guidelines

Google is proud to partner with libraries to digitize public domain materials and make them widely accessible. Public domain books belong to the public and we are merely their custodians. Nevertheless, this work is expensive, so in order to keep providing this resource, we have taken steps to prevent abuse by commercial parties, including placing technical restrictions on automated querying.

We also ask that you:

- + *Make non-commercial use of the files* We designed Google Book Search for use by individuals, and we request that you use these files for personal, non-commercial purposes.
- + *Refrain from automated querying* Do not send automated queries of any sort to Google's system: If you are conducting research on machine translation, optical character recognition or other areas where access to a large amount of text is helpful, please contact us. We encourage the use of public domain materials for these purposes and may be able to help.
- + *Maintain attribution* The Google "watermark" you see on each file is essential for informing people about this project and helping them find additional materials through Google Book Search. Please do not remove it.
- + *Keep it legal* Whatever your use, remember that you are responsible for ensuring that what you are doing is legal. Do not assume that just because we believe a book is in the public domain for users in the United States, that the work is also in the public domain for users in other countries. Whether a book is still in copyright varies from country to country, and we can't offer guidance on whether any specific use of any specific book is allowed. Please do not assume that a book's appearance in Google Book Search means it can be used in any manner anywhere in the world. Copyright infringement liability can be quite severe.

About Google Book Search

Google's mission is to organize the world's information and to make it universally accessible and useful. Google Book Search helps readers discover the world's books while helping authors and publishers reach new audiences. You can search through the full text of this book on the web at <http://books.google.com/>

COUNTWAY LIBRARY



HC 4BT7 .

HARVARD
MEDICAL LIBRARY



IN THE
Francis A. Countway
Library of Medicine
BOSTON

Gift of

GEORGE P. BERRY M.D.

Leslie A Sandholzer
872 Lancaster Ave
Syracuse, N.Y.

COMPARATIVE ANATOMY
OF
VERTEBRATES

KINGSLEY

OUTLINES
OF
COMPARATIVE ANATOMY
OF
VERTEBRATES

BY
J. S. KINGSLEY
PROFESSOR OF ZOOLOGY IN THE UNIVERSITY OF ILLINOIS

SECOND EDITION, REVISED

WITH 406 ILLUSTRATIONS
LARGELY FROM ORIGINAL SOURCES

PHILADELPHIA
P. BLAKISTON'S SON & CO.
1012 WALNUT STREET

HARVARD MEDICAL LIBRARY
IN THE
FRANCIS A. COUNTWAY
LIBRARY OF MEDICINE

3

K

1917

1

copy 2

COPYRIGHT, 1917, BY P. BLAKISTON'S SON & Co.

PRINTED IN U. S. A.
BY THE MAPLE PRESS COMPANY, YORK, PA.

PREFACE TO SECOND EDITION

The present edition has undergone a thorough revision, several sections having been rewritten, and every page having been carefully examined. A very considerable number of new illustrations have been added and several of those of the first edition have been redrawn. Experience has shown that it is easier to remember technical terms when their derivation and meaning is understood. Hence there has been added to this edition a list of Greek and Latin roots, from which the student can ascertain the origin and composition of practically every anatomical and embryological term in the volume. For assistance in the preparation of this, I am indebted to Professor W. A. Oldfather, of the University of Illinois. I would also return thanks here to the various persons who have sent me criticisms and corrections of statements in the first edition, and I cannot refrain from expressing my appreciation of the way in which the publishers have presented this and the former edition.

UNIVERSITY OF ILLINOIS.

PREFACE TO FIRST EDITION

Vertebrate anatomy is everywhere taught by the laboratory method. The student studies and dissects representatives of several classes, thus gaining an autoptic knowledge of the various organs and their positions in these forms. These facts do not constitute a science until they are properly compared and correlated with each other and with the conditions in other animals. It is the purpose of the author to present a volume of moderate size which may serve as a framework around which these facts can be grouped so that their bearings may be readily recognized and a broad conception of vertebrate structure may be obtained.

In order that this may be realized, embryology is made the basis, the various structures being traced from the undifferentiated egg into the adult condition. This renders it easy to compare the embryonic stages of the higher vertebrates with the adults of the lower and to recognize the resemblances and differences between organs in the separate classes. There has been no attempt to describe the structure of any species in detail, but rather to outline the general morphology of all vertebrates. To aid in the discrimination of the broader features and the more minor details, two sizes of type have been used, the larger for matter to be mastered by the student, the smaller for details and modifications in the separate classes to which reference may need to be made.

Considerable space has been given to the skull, as there is no feature of vertebrate anatomy which lends itself more readily to comparative study of the greatest value to the beginning student, while the same specimens can be used in the laboratory year after year. The skull also has a special interest since nowhere else is there the same chance of tracing modifications in all groups since the first appearance of vertebrates on the earth. To aid in this, extinct as well as recent species have been included.

It was the desire of the author to adopt the nomenclature of the German Anatomical Society ('BNA'), but this was often found impracticable. The BNA was based solely upon human anatomy and it fails utterly in many respects when the attempt is made to transfer

its terms to other groups. The single example of 'transverse process' is sufficient to illustrate this. To the writer another objection is that the BNA strives to do away with all personal names. These, it would seem, have a great value as they are indications of the history of anatomical discovery and memorials of the great anatomists of the past. Dorsal and ventral are used instead of the anterior and posterior of human anatomy, while anterior indicates toward the head, posterior toward the tail, these terms being readily applied to all vertebrates, man only excepted. Cephalad and caudad, adopted by some, lead to occasional peculiar phrases. The German word 'anlage' has been adopted bodily, and seems to call for no defense. It implies the indifferent embryonic material from which a part or an organ develops.

The illustrations have been drawn or redrawn expressly for this work. Some of them are original, some based on figures in special papers. Practically none have ever appeared in any text-book in the English language. In selecting the objects to be figured especial pains have been taken to avoid the forms usually studied in our laboratories, thus relieving the student of the temptation of copying the figure, instead of drawing from nature. Especial thanks are due to Professor C. F. W. McClure, who allowed me to draw at will from the splendid collection which he has built up at Princeton. These figures are indicated by the word 'Princeton' followed by the number of the preparation in the museum of the University.

TUFTS COLLEGE, MASS.

CONTENTS

	PAGE
PREFACE	v
INTRODUCTION	i
Introductory Embryology	8
Histology	21
COMPARATIVE MORPHOLOGY OF VERTEBRATES	29
The Integument	29
The Skeleton	41
Dermal Skeleton	43
The Endoskeleton	47
Axial Skeleton	48
Vertebral Column	48
Ribs	60
Sternum	63
Episternum (Interclavicle)	66
The Skull	67
The Skull in the Different Classes	82
Appendicular Skeleton	110
The Median Appendages	111
Paired Appendages	112
The Shoulder Girdle	114
The Pelvic Girdle	118
The Free Appendages	123
The Muscular System	129
The Parietal Muscles	131
The Visceral Muscles	138
The Dermal Muscles	139
The Diaphragm	140
Electrical Organs	140
The Nervous System	142
Central Nervous System	143
Spinal Cord	144
The Brain	147
Envelopes (Meninges) of the Central Nervous System	162
The Brain in the Separate Classes	163
The Peripheral Nervous System	173
The Spinal Nerves	173
The Sympathetic System	177
The Cranial Nerves	179
The Sensory Organs	192
Nerve-End Apparatus	193
Lateral Line Organs	194
The Auditory Organs	197
Organs of Taste	204
Olfactory Organs	204

The Eyes	213
The Digestive Organs.	220
The Oral Cavity	223
Teeth.	223
The Tongue	232
Oral Glands	235
Pharynx	238
The Oesophagus	238
The Stomach	239
Intestine	242
The Liver	248
The Pancreas	250
The Respiratory Organs	251
Gills or Branchiæ	252
Pharyngeal Derivatives	262
The Swim Bladder	266
Lungs and Air Ducts	269
The Air Ducts	270
Lungs	275
Accessory Respiratory Structures	285
Organs of Circulation.	285
Blood and Lymph	286
The Blood-Vascular System	287
The Heart	292
The Arteries.	298
The Veins.	307
The Fœtal Circulation	315
Circulation in the Separate Classes	316
The Lymphatic System	327
The Urogenital System	334
The Excretory Organs	335
The Reproductive Organs	345
The Reproductive Ducts	349
Copulatory Organs	353
Hermaphroditism	354
Adrenal System	354
Urogenital Organs in the Separate Classes.	356
Nutrition and Respiration of the Embryo—Fœtal Envelopes	379
Bibliography	387
Definition of Systematic Names	417
Latin and Greek Roots of Technical Words	423
INDEX	431

INTRODUCTION

Any animal or any plant may be studied from several different points of view, four of which are concerned in the present volume. We may study its structure, ascertaining the parts of which it is composed and the way in which these parts are related to each other. This is the field of Anatomy. If we go into the more minute structure, for which the microscope has to be used, we are entering the special anatomical field of Histology. When two or more different animals are compared in points of structure, their resemblances and differences being traced, the study is called Comparative Anatomy, and it is only through such comparisons that we are able to arrive at the true meanings of structure. Then it is of interest to see the way in which the structure comes into existence in development from the comparatively simple egg from which it arises—the province of Embryology or Ontogeny. Anatomy and ontogeny together give us a knowledge of the form and how it has arisen, and they are frequently grouped as Morphology. But morphology merely deals with the parts of a machine and these are usually studied in the dead organism; fully to appreciate the mechanism we should know how the parts and the whole perform their work, the study of function or Physiology.

In view of the foregoing the present volume is to be regarded as rather a comparative morphology of vertebrates, with here and there hints at the physiological side. Farther, there is an adaptation of the organism to the conditions in which it has to live, and the interactions of this environment upon the animal have to be considered, at least to a slight extent.

Zoologists divide all animals into two great groups, the Protozoa, in which the organism consists of a single cell, and the Metazoa, in which the body is composed of many cells, which vary according to the functions they have to perform. Of the Metazoa there are several divisions—Porifera (sponges), Cœlenterata (sea anemones, jelly fish), Echinoderma (starfish, sea urchins), Platodes (flatworms), Rotifera, Cœlhelminthes (ordinary worms), Mollusca, Arthropoda (crabs, insects), and Chordata.

The Chordata are bilaterally symmetrical animals with metameric bodies, which agree in several features not found in the other groups. These are (1) a central nervous system, entirely on one side of the digestive tract; (2) the presence of gill slits in the young if not in the adult; (3) an unsegmented axial rod, the notochord, between the digestive tract and the nervous system. All of these features will be described later.

There are three or four divisions of Chordata, the uncertainty depending upon the position to be accorded the Enteropneusta. These are worm-like animals, occurring in the sea and represented on our shores by *Balanoglossus*. What has been described as a notochord is a pocket from the digestive tract, lying in a curious proboscis above the mouth.

The next division, the Tunicata, includes the (marine) 'sea-squirts.' They were long regarded as molluscs, but the discovery that the young have true gill slits, a nervous system on one side of the alimentary canal, and, above all, a notochord, placed them in the present association. Their young (larvæ) are tadpole-like, the notochord is confined to the tail, but later the tadpole features are lost and with them the tail and notochord, and the adult is a sac-like animal with no resemblances to its former state, or to its allies.

The third division, the Leptocardii, embraces *Amphioxus* and a few other marine, fish-like animals. They were long classed as fishes, but they are far more simple than any true fish. The body is markedly segmented, the gill slits are very numerous and the excretory organs open separately to the exterior and are vermian in character. Stomach, vertebræ and heart are lacking and the brain and sense organs are very rudimentary, while jaws and paired appendages are absent.

The last class, the Vertebrata, are most nearly related to the Leptocardii, but differ in many important respects. Thus there is always a skull and vertebral column; the brain is larger than the spinal cord; there are always nose, eyes and ears; a heart is present and the excretory organs open into a common duct on either side, with an external opening near the anus.

Most of the characteristics of a vertebrate may be seen from the accompanying diagram. The body is bilaterally symmetrical, with anterior and posterior ends, dorsal and ventral sides well differentiated. There is no external segmentation, since the muscles are not directly attached to the skin, but a metameric arrangement of

parts is noticeable in muscles, skeleton, nerves, blood-vessels, and, to a less extent, in the excretory organs. There is no cuticular skeleton, but the outer layer of the skin may be cornified or the deeper layer may give rise to ossifications (scales of fishes, etc.).

There is an internal axial skeleton, consisting of the notochord, around which are developed rings of denser material, constituting a backbone or vertebral column, while in front a skull encloses the brain and organs of special sense, and gives support to the primitive respiratory organs (gills), which are always connected with the digestive tract. Typically there are two kinds of appendages, each with an internal skeleton. These are the unpaired or median fins, dorsal and ventral, which occur only in the Ichthyopsida, and the paired appendages, of which there are two pairs, anterior and posterior in position.

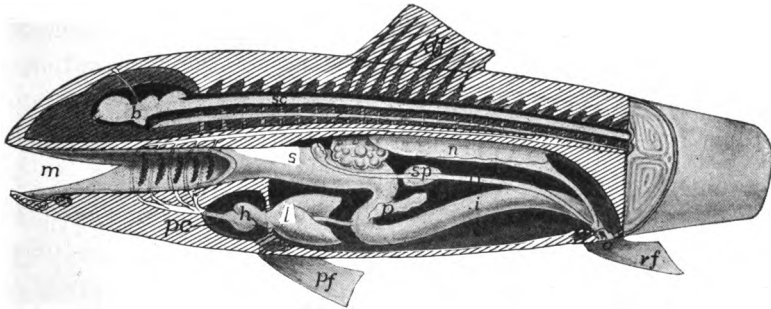


FIG. 1.—Diagram of a vertebrate. *a*, anus; *b*, brain; *c*, cœlom; *da*, dorsal aorta; *df*, dorsal fin; *g*, gonad; *gd*, genital duct; *h*, heart; *i*, intestine; *l*, liver; *m*, mouth; *n* nephridia; *o*, oviduct; *p*, pancreas; *pc*, pericardium; *pf*, pectoral fin; *ph*, pharynx, with gill clefts; *s*, stomach; *sc*, spinal cord; *sp*, spleen; *u*, ureter; *va*, ventral aorta; *vc*, vertebral column; *vf*, ventral fin.

The central nervous system consists of brain and spinal cord which lie dorsal to the notochord, and are usually protected by arches arising from the vertebræ and by the roof of the skull. Eyes and ears are the highest of the sense organs. The alimentary canal always has a liver connected with it, and a portion of the canal just behind the mouth is developed into a pharynx, from which, in the young of all, gill clefts extend through to or toward the exterior. In the terrestrial vertebrates these gill clefts are later replaced by lungs which develop from the hinder part of the pharyngeal region.

The blood, which always contains two kinds of corpuscles, flows through a closed system of vessels. A heart, ventral to the digestive tract and lying in a special cavity, the pericardium, is always present.

The heart consists of two successive chambers, an auricle (atrium) and a ventricle, and in forms which respire by means of gills, contains only venous blood. With aerial respiration both chambers may become divided into arterial and venous halves. A dorsal aorta, lying above the alimentary canal, is always present.

The sexes are usually separate. The reproductive and excretory systems are closely related, giving rise to a urogenital system. The excretory ducts usually carry off the reproductive products (eggs and sperm). The urogenital ducts empty near the anus. Reproduction is strictly sexual; parthenogenesis and reproduction by budding do not occur and alternation of generations is unknown. The viscera are enclosed in a large body cavity (cœlom) which in the adult does not extend into the head. Each viscus is supported by a fold (mesentery) of the lining membrane of the cavity.

For details of the classification of vertebrates reference must be made to special text-books of zoology, but as some of the larger groups must be referred to frequently, these, with a slight definition and one or two examples, are given here.

SERIES I. CYCLOSTOMATA

These are eel-like in form, breathe by gills, have but one nostril, a circular mouth, incapable of closing, for no jaws are present. The skeleton is poorly developed and there are no paired appendages.

Class I. Marsipobranchii

Characters as above.

Sub-class I. Petromyzontes (Hyperoartia)

Well-developed dorsal fin; naro-hypophysial duct on top of head; seven gill openings on either side.—Lampreys.

Sub-class II. Myxinoidei (Hyperotretia)

Dorsal fin small or absent; naro-hypophysial duct at tip of snout; either a single gill opening on either side, or from six to fourteen present.—Hagfishes.

SERIES II. GNATHOSTOMATA

This includes all other vertebrates. They have usually two pairs of appendages, paired nostrils, true jaws and a well-developed skeleton.

GRADE I. ICHTHYOPSIDA (ANAMNIA)

Fish-like, breathe, at least while young, by gills, have paired appendages, in the shape of legs or fins. In development there are never formed those structures to be described later as amnion and allantois.

Class I. Pisces

Fishes respire permanently by gills developed in gill slits in the sides of the pharynx, have median and paired fins unless the latter be lost by degeneration.

Sub-class I. Elasmobranchii

Fishes with cartilaginous skeleton, mouth usually on the lower side of the head, the gills usually opening separately on the neck or (skates) on the lower surface, and the tail with the upper lobe the larger (heterocercal). Sharks and skates. The Holocephali differ in having the gill slits covered with a fold of skin, so that but a single external opening appears.

Sub-class II. Ganoidea

Intermediate between elasmobranchs and teleosts.—Garpike, sturgeon.

Sub-class III. Teleostei

Fishes with bony skeleton, mouth with true jaws at the tip of the snout, gill openings concealed by an operculum or gill-cover supported by bone. Tail with upper and lower lobes equal.—All common fishes.

Sub-class IV. Dipnoi

The lung fishes are tropical forms in which the air bladder functions as a lung, nostrils open into mouth, the gill openings are covered with an operculum, and the tail is very primitive (diphycercal).

Class II. Amphibia

Ichthyopsida with legs replacing the paired fins, usually external gills in the young, lungs present and replacing the gills in the adult, nostrils connecting with the mouth.

Sub-class I. Stegocephali

Extinct amphibians with well-developed tail; the skull without gaps, except for eyes and nostrils, in the dorsal surface.

Sub-class II. Urodela

Amphibia with well-developed tail, gills sometimes retained through life.—Salamanders, Tritons, newts, efts.

Sub-class III. Anura

Tailless as adults, the young a tadpole with external gills.—Frogs and toads.

Sub-class IV. Gymnophiona

Blind, burrowing, legless amphibians occurring in the tropics.—Cæcilians.

GRADE II. AMNIOTA

Vertebrates in which there are never fins, never functional gills, the respiration being by lungs. In development the embryo becomes covered by an embryonic envelope called the amnion, while a second outgrowth from the hinder end of the digestive tract is concerned in the embryonic respiration and nutrition and is called the allantois.

Class I. Sauropsida

Body, at least in part, with scales, eggs large, lower jaw suspended from skull by a quadrate bone.

Sub-class I. Reptilia

Cold-blooded vertebrates, the whole body covered by scales or horny plates. The living forms are turtles, lizards, snakes and alligators (crocodiles) and a New Zealand species, *Sphenodon*. The fossil forms are more numerous and include Theromorphs, Plesiosaurs, Ichthyosaurs, Dinosaurs, and Pterodactyls.

Sub-class II. Aves

The birds are recognized by their warm blood and their feathers.

Class II. Mammalia

The mammals are as sharply marked by their hair as are the birds by their feathers, lower jaw suspended directly from the skull. They have warm blood; except the monotremes they bring forth living young; the young of all are nourished by milk secreted by glands (mammæ) in the mother.

There are a few other terms of convenience which may be defined here as they will save much circumlocution. The term Teleostomes is applied to ganoids and teleosts, from the fact that they have true jaws. The amphibia and the amniotes are frequently united as Tetrapoda, from their possessing feet, in contrast to the fishes with fins.

The geological history of these groups is important; their first appearance and their geological range is indicated in the accompanying table of the geological periods.

INTRODUCTORY EMBRYOLOGY

The structure of an adult vertebrate can be fully appreciated and the bearing of the facts recognized only by a knowledge of the development of the parts concerned. It

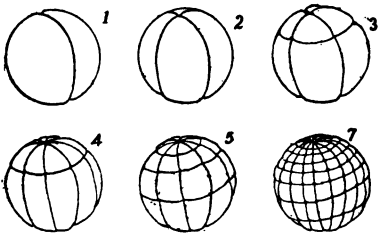


FIG. 2.—Successive stages in the segmentation of an amphibian egg. 1-7, Results of the corresponding cleavage planes.

would often appear, for example, that certain organs in different groups were exact equivalents of each other—duplicates in function and details of structure—while a knowledge of their development may show that they have had entirely different origins and different histories, and hence cannot be identical; they are examples of

what the evolutionist calls convergent evolution. Such cases are apt to lead one astray as to the relations of the forms in which they occur. Farther, the development affords a framework around which the details of organization may be arranged in a logical manner, thus aiding in their remembrance. For these reasons the following pages are based on embryology. Not only are the histories of the separate organs traced before an account is given of the adult conditions but this introductory chapter gives in the most generalized form the earlier stages before the organs are outlined.

Geological Period	Ostracoderms	Palaeospondylus	Elasmobranchs	Ganoids]	Teleosts	Arthrodira	Dipnoi	Stegocephals	Gymnophiona	Urodela	Anura	Theromorphs	Plesiosaurs	Chelonia	Ichthyosaurs	Rhynchocephals	Dinosaurs	Squamata	Crocodyles	Pterodactyls	Birds	Monotremes	Marsupials	Edentata	Insectivores	Chiroptera	Rodentia	Ungulata	Sirenia	Cetacea	Carnivores	Primates
Pleistocene																																
Pliocene																																
Miocene																																
Pocene																																
Cretaceous																																
Jurassic																																
Triassic																																
Permian																																
Carboniferous																																
Devonian																																
Silurian																																
Cambrian																																

Table showing the geological distribution of the various groups of vertebrates.

The enormously complicated body of every vertebrate is derived from a comparatively simple specialized cell, the egg or **ovum**. This ovum must be fertilized by a still more specialized cell, the **spermatozoon**, derived from the male. After this fertilization the egg goes through an orderly but very gradual series of changes which bring it continually nearer the adult condition. The phases of this differ with different animals; here only a generalized account will be given, which is subject to modifications in the several groups, for an account of which reference must be had to embryological text-books.

The Segmentation of the Egg.—The first steps of the process are the segmentation or cleavage of the egg, in which it divides again and

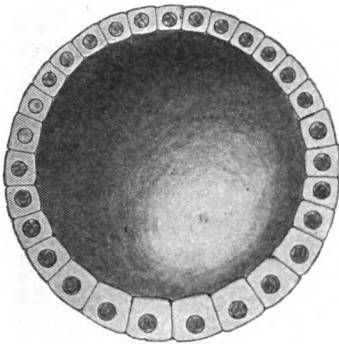


FIG. 3.—Diagram of a typical blastula with central segmentation cavity.

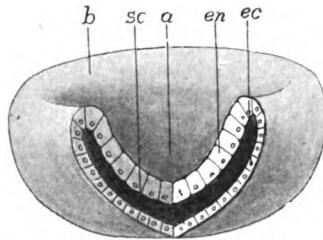


FIG. 4.—Diagram of a gastrula, *a*, archenteron; *b*, blastopore; *ec*, ectoderm; *en*, entoderm; *sc*, segmentation cavity.

again, until the single-celled egg is converted into a large number of cells or **blastomeres** (fig. 2). The character of this segmentation is modified accordingly as the egg is large or small, as it contains varying amounts of nourishment—**deutoplasm** or food yolk stored up for the growing embryo. These same variations also affect the later stages of development; the description given here follows the simplest conditions.

As a result of segmentation the egg is converted into a spherical mass of cells in which a cavity appears, called the **segmentation cavity** because it is formed during segmentation. It also has the name **archicœle** as it is the first or oldest space to appear in the embryo. This stage of the embryo is called the **blastula** (fig. 3). Its cells at first show but little differentiation except in size. Next

follow processes which are to differentiate the cells into layers, characterized by both position and fate.

Gastrulation.—In the simplest form this differentiation is brought about by an inversion of one-half of the blastula into the other, thus more or less completely obliterating the segmentation cavity, much as one may push one side of a rubber ball into the other, forming a double-walled cup (fig. 4). This stage is called the **gastrula**, and the process of inpushing is **invagination**. With this the first appearance of the structures of the adult is seen. The outer wall of the cup is turned to the external world and thus acts as a skin for the embryo. This layer is called the **ectoderm**. The opening or mouth into the cup is the **blastopore**. The inside of the cup is well fitted for the digestion of food as it can be held together there and the digestive fluids are less liable to waste. Hence the cavity is called the **archenteron** (primitive stomach), and the layer of cells which line it is the **entoderm**. That these comparisons are more than analogies of position is shown by their fates; the ectoderm forming part of the skin of the adult, the entoderm the lining of the digestive tract. Between ectoderm and entoderm are the remains of the segmentation cavity, filled with an albuminous fluid. It will be convenient later to speak of the line where ectoderm and entoderm meet at the blastopore as the **ect-ental line**.

Closure of the Blastopore.—Next, the blastopore closes, the process beginning at what will be the head end of the embryo and proceeding gradually backward. Usually the closure is complete, but occasionally the hinder part remains open and forms the anus. Where it closes completely the vent is subsequently formed in the line of closure. This union of the two lips of the blastopore in closing marks the middle line of the back of the future animal, and is called at first the **primitive groove**, the region on either side of it being known as the **primitive streak**, terms of importance in understanding the gastrulation of the higher vertebrates.

Mesoderm.—With the closure of the blastopore the embryo elongates and the archenteron is converted into a tube. Next, from the region of closure and from the entodermal layer, a fold of cells grows in on either side between ectoderm and entoderm, thus farther encroaching on the segmentation cavity. These cells form the middle layer or **mesoderm**. Inside this fold is a space, connected at first with the archenteron (fig. 5), but soon the cavity of each side is cut off by a growing together of the opening into the archenteron and is

henceforth known as a **cœlom**¹ or body cavity (fig. 6). Each cœlomic space has two walls, one toward the ectoderm, the **somatic** layer, the one toward the entoderm being the **splanchnic** layer (figs. 5 and 6, *so*, *sp*).

The mesoderm arising in this way and bounding the cœlom is called **mesothelium** to distinguish it from another kind—the **mesenchyme**—which also comes to lie in the segmentation cavity. This mesenchyme arises as separate cells, coming largely from the mesothelium, and to a less extent from the entoderm (see p. 20). Whether any arises from the ectoderm is disputed.

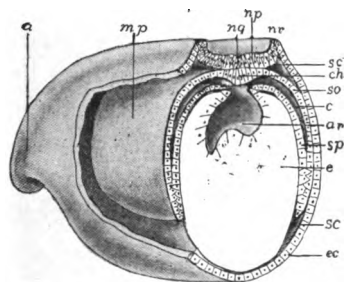


FIG. 5.

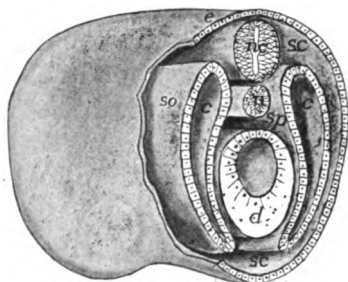


FIG. 6.

FIG. 5.—Stereogram of the anterior end of a developing amphibian, showing the out-lining of the mesothelium, nervous system and notochord. *a*, anterior end; *ar*, archenteron; *c*, cœlom; *ch*, notochordal cells; *ec*, ectoderm; *mp*, mesodermal pouch; *ng*, primitive groove; *nr*, neural folds; *sc*, segmentation cavity; *so*, somatic wall of cœlom; *sp*, splanchnic wall of cœlom.

FIG. 6.—Stereogram of the anterior end of a vertebrate, showing the relation of the cœlomic pouches; *c*, cœlom; *d*, digestive tract; *e*, ectoderm; *nc*, nervous system; *n*, notochord; *sc*, segmentation cavity; *so*, somatic and *sp*, splanchnic walls.

The Germ Layers.—Ectoderm, entoderm and the two types of mesoderm are called the **germ layers**, because in the animals first studied they were arranged like layers one on the other. Each plays its part in the formation of the adult and gives rise to its peculiar structures.

The ectoderm forms the outer layer of the skin, hair, claws, feathers, the outer layer of scales, enamel of teeth, and the essential or characteristic part of all sensory and nervous structures.

The entoderm gives rise to the lining of the digestive tract, and the various outgrowths—gills, lungs, liver, pancreas, etc.—connected with it. The notochord is also entodermal and possibly the lining of the blood-vessels is derived from this layer.

¹ A cœlom formed in this way is an **enterocœle**. Usually the cœlomic walls arise as a solid mass of cells from the corresponding region, which later splits internally, forming a **schizocœle**. The two are readily compared.

The mesothelium produces the lining of the cœlomic cavities—pericardial, pleural, peritoneal—the reproductive and excretory organs and the voluntary muscles and those of the heart.

The mesenchyme develops the deeper layer of the skin (corium) and of scales, the dentine of teeth, involuntary muscles (except those of the heart) connective tissue, ligaments, cartilage, bone, and the corpuscles of blood and lymph.

In the development of the embryo several processes of differentiation occur simultaneously, but in the written account one has to follow another. Hence it must be understood that the modifications described here may be taking place at the same time.

The Central Nervous System.—During the closure of the blastopore the ectoderm in front and to either side of the blastoporal lips becomes thickened, the cells elongating at right angles to the surface and becoming cylindrical or fusiform. These cells form the **neural or medullary plate** (Fig. 5, *np*), sharply marked off from the surrounding cells, which are more flattened, and which eventually are concerned in the formation of the outer layer (epidermis) of the skin. The neural plate is to develop into the brain and the spinal cord, and it is to be noted that later it extends around the hinder end of the blastopore. After it is outlined the plate is rolled into a tube, its front end and lateral margins rising up, forming **neural folds** (*nr*), between which is the **medullary groove** (*ng*). Eventually the folds meet and fuse above, so that a tube results (fig. 6, *nc*), the cavity of which persists throughout life as the cavities (**ventricles**) of the brain and the central canal of the spinal cord. From the cells of the walls of the canal the nervous tissue arises.

This process of infolding progresses from in front backward. For a time, in some vertebrates, a small opening, the anterior **neuropore**, persists at the anterior end. The infolding extends back to the posterior end of the neural plate so that, as will readily be understood, the whole limits of the blastopore are included in the floor of the neural canal. Occasionally the closure of the neural folds is completed before that of the blastopore so that for a short time a short tube, the **neurenteric canal** (fig. 7), connects the archenteron with the neural canal. Soon after the closure of the neural tube the fused tissue splits horizontally, separating the nervous system from the rest of the ectoderm. Its subsequent history will be traced in the section on the Nervous System.

The Notochord.—Immediately beneath the neural plate is an axial strip of entoderm¹ (fig. 5, *ch*), bounded on either side by the outgrowing mesothelium. When the latter separates (p. 10) this band is momentarily rejoined to the rest of the entoderm but is still recognizable from its different cells. It soon rolls into a rod (a tube in some amphibians and birds), is cut off from the rest (fig. 6, *n*) and lies between the digestive tract and the nervous system where it forms an axis around which the skull and vertebral column develop later.

The Digestive Tract.—After the separation of the notochord, the entoderm forms a tube, closed in front and usually behind as well.

The anterior end of the tube abuts against the ectoderm of the ventral side of the embryo. Later the ectoderm grows in at the point of contact, carrying the entoderm before it and forming a pocket, the **stomodeum**, which gives rise to the cavity of the mouth (fig. 212, *oc*). (In some the stomodeal ingrowth is at first solid, the pocket being formed later by splitting.) Eventually the ectoderm and entoderm fuse at the bottom of the cup, and

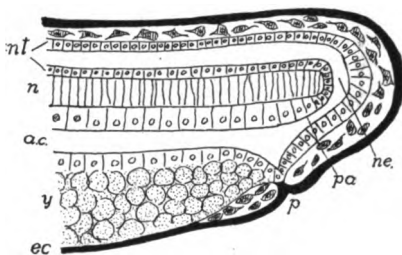


FIG. 7.—Schematic section of the hinder end of an amphibian embryo, showing the relations of the neurenteric canal. *ac*, alimentary canal; *ec*, ectoderm (black); *n*, notochord; *ne*, neurenteric canal; *nt*, neural tube; *p*, proctodeum; *pa*, post-anal gut; *y*, yolk.

then the fused area breaks through, placing the archenteron in connexion with the exterior. A similar, but less well-defined **proctodeum** (fig. 7, *p*) arises at the hinder end of the digestive tract. Thus the anterior and posterior ends of the alimentary canal are ectodermal, the middle region entodermal, in origin.

Metamerism.—In the adult, various parts, essentially like each other, are repeated one after another—are **metameric**. The list includes, among others, muscles, nerves, blood-vessels, vertebræ, ribs, etc. There is much evidence to show that metamerism had its origin in the mesothelial structures and has been secondarily impressed on other systems.

¹ The statement is made that in some groups the notochord arises from another germ layer than the entoderm, but these statements apparently rest on erroneous observations or interpretations. Different origins in different vertebrates would tend to show that what are called notochord are not homologous.

The mesothelial cœlomic pouches, as left above, are near the dorsal side of the embryo. With growth they gradually extend downward on either side and tend to enclose the whole archenteron, and upward on either side of the notochord and spinal cord (fig. 8). The fates of the different parts of the mesothelial walls warrants the recognition of three horizontal regions or zones in the walls of each cœlom. These are a dorsal muscle-plate zone (**epimere, *em***), a lower or lateral-plate zone (**hypomere, *hm***), and a middle-plate zone (**mesomere, *mm***) between them. All three of these occur in

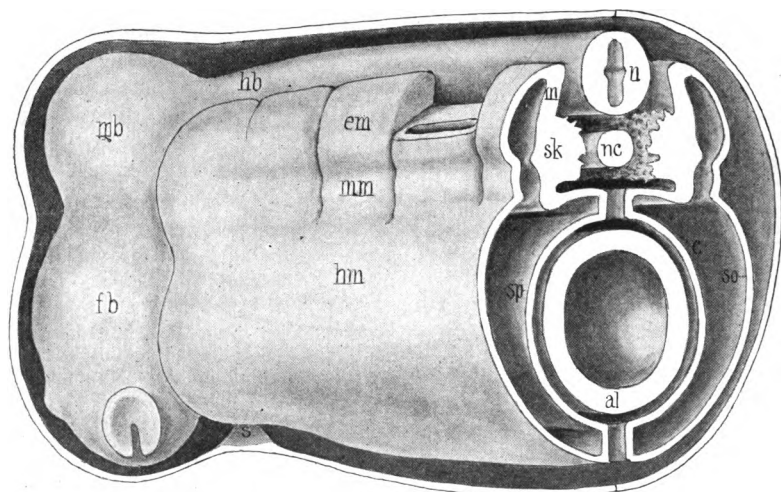


FIG. 8.—Stereogram of a later stage than fig. 6, showing the segmentation of the mesothelium. The approach of the walls of the cœlom (*c*), dorsal and ventral to the alimentary canal, to form the mesenteries is shown. *al*, alimentary canal; *c*, cœlom; *em*, epimere; *fb*, fore-brain; *hb*, hind-brain; *hm*, hypomere; *m*, myotome; *mb*, mid-brain; *mm*, mesomere; *mc*, metacœle; *myc*, myocœle; *n*, nervous system; *nc*, notochord; *s*, stomodæal region; *sk*, sclerotome. (In many vertebrates the sclerotome extends upward to the lower part of *m*.)

the trunk, but only the epimere is well developed in the anterior part of the head.

A series of vertical constrictions, beginning on the dorsal margin of each cœlomic pouch, cut down through epimere and mesomere (fig. 8) so that the whole may be compared to a glove with many fingers, each finger being hollow and all of the cavities connecting with that of the hypomere (palm). This segmentation process begins in front and gradually extends backward. Next, the dorsal (epimeral) part of each of the fingers is cut from the rest, thus forming a series of hollow cubes known as **myotomes**, each with a part of the cœlom, the **myocœle**, in its interior. Viewed from above, these

myotomes appear as square boxes, and early students, thinking that they gave rise to the vertebræ, called them **protovertebræ**, a term still in use to some extent.

After separation from the rest of the mesothelium each myotome grows dorsally along the side of the spinal cord, and to a greater extent ventrally, insinuating itself between the ectoderm and the somatic wall of the hypomere (fig. 9, in the direction of the arrows).

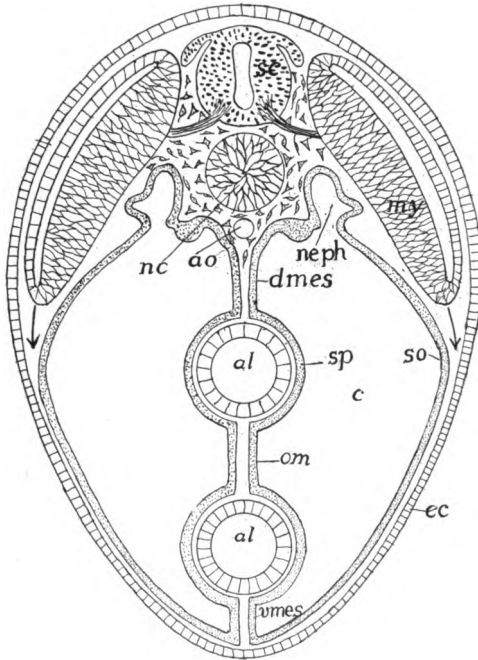


FIG. 9.—Diagrammatic transverse section of a vertebrate to illustrate mesenteries, omentum and downward growth of the myotomes. *al*, alimentary tract; *ao*, aorta; *c*, cœlom; *ec*, ectoderm; *dmes*, dorsal mesentery; *my*, myotome; *nc*, notochord; *neph*, nephrotome; *o*, omentum; *sc*, spinal cord; *so*, *sp*, somatic and splanchnic layers of mesothelium; *vmes*, ventral mesentery.

Each myotome has a somatic and a splanchnic wall. Later the somatic wall breaks up, its cells spreading beneath the ectoderm and furnishing the mesoderm immediately beneath the ectoderm (epidermis). The upper part of the splanchnic wall is gradually transformed into the body (somatic) musculature, while the ventral portion usually buds cells which take part in the formation of the axial skeletal tissue.

The mesomer (middle plate) part of the fingers is largely concerned in the formation of the excretory (nephridial) system, but

from the splanchnic wall cells are budded, which, like those from the myotomes, form part of the skeletogenous tissue. Since both the excretory portions of the middle plate and the skeletogenous parts of both myotome and middle plate are metameric in origin and retain their metamerism for some time, they are called respectively **nephrotomes** (fig. 9, *neph*) and **sclerotomes** (fig. 8, *ck*), the cavities in the nephrotomes being the **nephrocoeles**. The history of the skeletal and excretory systems will be given later.

The Cœlomic Cavities.—As has been described above, the cœlom in each mesothelial pouch becomes divided into a series of myocœles and nephrocoeles, connected with a larger cavity, the **metacœle**, in the hypomeral or lateral-plate region. With the separation of the myotomes the myocœles lose their connexion with the other cavities, and when the somatic walls of the myotomes break up into mesenchyme, these cavities are lost. The nephrocoeles form the cavities in the tubules of the excretory system, and in the lower vertebrates these never separate from the metacœle, but openings, the **nephrostomes**, connect the tubules with the larger cavity. The history and modifications of these are traced in the section on the excretory organs.

The metacœle is at first undivided and the cavities of the two sides are distinct. With increasing age the hypomeres of the two sides gradually extend downward between ectoderm and entoderm until their lower margins meet, ventral to the digestive tract. In this way the latter becomes surrounded by a pair of metacœlic cavities. Each cavity is bounded by epithelium, the **tunica serosa**, the outer or somatic portion of which is turned toward the ectoderm while the splanchnic portion adjoins the entoderm of the digestive tract. Later, when the myotomes extend into this region (fig. 10) they, with the invading mesenchyme, unite the ectoderm and somatic serosa into the thick outer body wall, the **somatopleure**, while a similar migration of mesenchyme between serosa and entoderm unites these into the wall of the alimentary canal, the **splanchnopleure**.

Mesenteries.—As has just been stated, the ventral margins of the two cœlomic pouches meet below the digestive tract, thus forming a double membrane running lengthwise of the body and binding the alimentary canal to the ventral body wall. This is the ventral mesentery (fig. 9, *mes*). At the same time the splanchnic walls of the two cavities meet just above the entoderm and between it and the notochord, forming a dorsal mesentery which ties the digestive

tract to the dorsal region of the body (fig. 9, *dmes*). With farther development mesenchyme grows in between the two serosal walls of the dorsal mesentery, uniting them and forming a tissue through which blood-vessels, lymphatics and nerves reach the digestive tract. In many vertebrates the dorsal mesentery persists throughout life, but in some it becomes reduced, persisting chiefly in those places where the vessels extend to the alimentary canal. The ventral mesentery, on the other hand, almost entirely disappears (fig. 10), the parts persisting being recognized as mesenterial in origin only by following their development. With the breaking down of the ventral mesentery the metacoeloms of the two sides are in open communication with each other and form the well-known 'body cavity' of the adult.

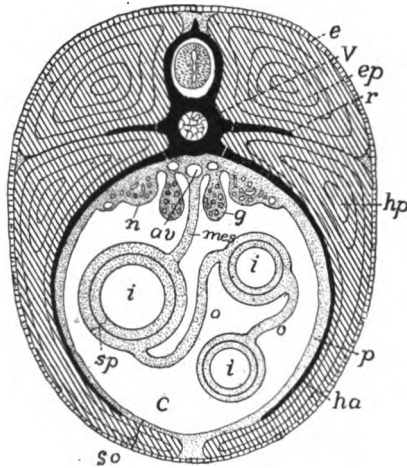


FIG. 10.—Diagrammatic section of a vertebrate to show the relation of the body walls, etc., *av*, aorta; *c*, coelom; *e*, ectoderm; *ep*, epaxial muscles; *g*, gonads; *ha*, hæmal arch; *hp*, hypaxial muscles; *i*, intestine; *mes*, mesentery; *n*, nephridium; *o*, omentum; *r*, rib; *p*, somatopleure; *sp*, splanchnopleure; *v*, vertebra.

For convenience of description different parts of the mesenteries have received special names according to the organs supported. The persisting remnant of the ventral mesentery occurs in the region of the liver where it is called the **mesohepar**, and in the ichthyopsida it may carry blood-vessels from the body wall to that organ. In the dorsal mesentery the regions are the **mesogaster**, **mesentery proper**, **mesocolon**, **mesorectum**, etc., accordingly as they support the stomach, intestine, colon, rectum and the like.

In all vertebrates except the cyclostomes the alimentary canal is bent on itself and the folds are connected with each other by portions of the serosa, and these mesenterial-like structures are called **omenta** (fig. 10, *o*). There may be several of these omenta, their names usually indicating the parts of the digestive tract which they connect. Thus the **gastrohepatic** omentum connects stomach

and liver. Then there are also **gastrosplenic, duodeno-hepatic** omenta, the positions of which are readily understood. The mammals have a **great omentum**, a double fold of mesogaster and mesocolon which connects stomach and colon and forms a large sac, the **bursa omentalis**, the cavity of which is connected with the rest of the body cavity by a small opening (**foramen epiploicum** or **foramen of Winslow**) near the hinder end of the liver.

Frequently the reproductive glands (gonads) project so far into the body cavity that the serosa meets behind them, forming supports for them similar to mesenteries. These are called **mesorchia** for the testes, **mesovaria** for the ovaries.

In the early embryo the metacoelom extend as well-developed cavities from just behind the head back to the anus. Each is soon divided by a cross partition, the **septum transversum**, into a smaller anterior cavity, the **pericardium**, which surrounds the heart, and a larger **splanchnocoelom** or **body cavity** which includes the rest of the viscera. The method of the formation of the septum transversum is described in connexion with the heart (p. 294), but here it may be stated that, just in front of the liver a pair of blood-vessels, the **Cuvierian ducts**, enter the heart from the sides. These arise in the somatopleure and as they increase in diameter, they project into the coelom, carrying the somatic serosa before them. The fold thus produced is the septum transversum which is attached to the front margin of the liver. In many lower vertebrates (*e.g.*, elasmobranchs) this septum is not complete, failing to reach the other (splanchnic) wall, thus leaving one or more openings—**pericardio-peritoneal canals**—connecting the pericardium with the body cavity. In the higher vertebrates the closure is complete.

In the formation of the pericardial cavity double serosal membranes (**mesocardia**) are formed which are similar to the mesenteries in origin and structure (see fig. 312). These are temporary and in all vertebrates disappear in the earlier stages of development.

In all the lung-bearing vertebrates except the mammals, the lungs are suspended in the general body cavity (splanchnocoelom), but in the latter group a second partition, the **diaphragm**, cuts off a pair of **pleural cavities** from the rest of the splanchnocoelom which is now called the **peritoneal cavity**. Traces of structures similar to the diaphragm, as indicated by nerve supply, etc., occur in vertebrates as low as the amphibia, but their exact homology is uncertain. The development of the mammalian diaphragm is a complicated process and is stated here only in outline. It involves a part of the septum transversum, but is largely a new formation. At first a part of the

splanchnocoel extends forward, dorsal to the pericardium and into this recess the lungs extend. Then a pair of folds grow ventrally from the dorsal wall of the body cavity until they meet the septum transversum, thus cutting off a pair of **pleural cavities** containing the lungs from the rest of the splanchnocoel (fig. 11, C). As the lungs increase in size, the pleural cavities extend, at first lateral to the pericardium, and later, ventral to it, until at last the pleural cavities of the two sides are separated ventrally by their two walls which form a mesenterial-like membrane, the **mediastinum**. The diaphragm undergoes several shiftings of position before reaching its final place. The dorsal parts of the diaphragmatic muscles are derived from the original folds, the ventral come from the rectus abdominis muscle of the ventral abdominal wall.

The tunica serosa lining the various divisions of the coelom has special names in each. The pericardial and pleural cavities are lined with **pericardium** and

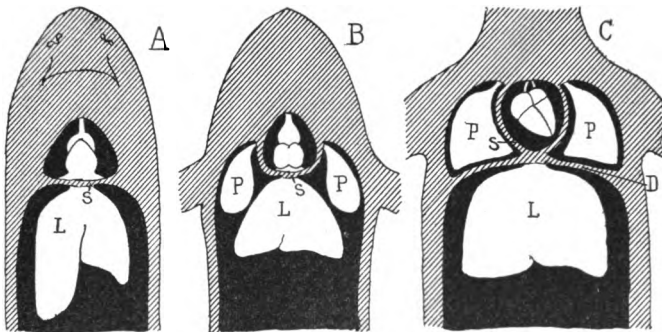


FIG. 11.—Diagram showing the relations of the coelomic cavities (black) in A, fishes, B, amphibians and sauropsida; and C, in mammals; L, liver; P, lungs in C in pleural coelom; S, septum transversum; D, diaphragm.

pleura respectively, that part of the pericardial serosa covering the heart itself being frequently called the **epicardium**. The body or peritoneal cavity is lined with **peritoneum** which extends over the mesenteries, the digestive tract and the excretory and reproductive organs.

The body cavity is not always completely cut off from the external world. In the ichthyopsida the urinary ducts which lead to the exterior frequently open into the body cavity by the nephrostomes (fig. 12), and, in the females of all vertebrates with true oviducts, including the mammals, these tubes connect the peritoneal cavity with the outer world. Many fishes have short tubes (**pori abdominales**) leading from the body cavity to the exterior, opening near the vent. These abdominal pores occur in cyclostomes, many elasm-

branches and teleosts, ganoids and dipnoi. None are known in amphibia, birds or mammals, but in crocodiles and turtles so-called **peritoneal canals** occur, usually ending blindly in turtles but emptying into the cloaca in the crocodilians. These may be homologous with the abdominal pores, but this can be decided only by a study of the development. In some fishes the abdominal pores serve for the escape of the eggs and spermatozoa; in other animals their function is uncertain.

Mesenchyme.—The principal places where the mesenchyme arises have been alluded to incidentally in the foregoing pages. These statements may be brought together here. A part is derived from the splanchnic walls of the mesomere and from the ventral part of the myotomes, each of which is a centre of rapid cell proliferation,

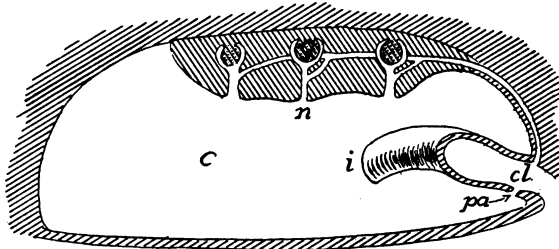


FIG. 12.—Diagram of possible connexions of coelom with the exterior, modified from Bles. *c*, coelom; *cl*, cloaca; *g*, glomerulus of kidney; *i*, intestine; *n*, nephrostome; *pa*, porus abdominalis.

the resulting cells passing toward the median plane of the body. From the method of formation from segmented structures, these bodies of mesenchyme are at first metameric, and since in part, they give rise to the axial skeleton, the separate portions are called **sclerotomes**. This mesenchyme extends dorsally beside the central nervous system and notochord, and ventrally on either side of the axial blood-vessels and the alimentary canal, thus forming a partition between the two sides of the body (fig. 33).

A second source of mesenchyme is found in the breaking up of the somatic walls of the myotomes, all of the cells of which are transformed into this layer and come to lie immediately beneath the ectoderm, forming a complete layer of mesenchyme around the whole body. There is also a probability that some mesenchymatous cells are budded from the entoderm of the archenteron, but it is uncertain whether the ectoderm contributes to the layer, farther than by the degeneration and metamorphosis of some transient nervous structures.

From these sources the mesenchyme extends everywhere in the remains of the segmentation cavity, surrounding the other layers and intruding between the muscles and around the various viscera, forming a framework in which the products of all the other layers are enveloped (fig. 33). This mesenchymatous framework has great importance in the development of the skeleton and its general plan will be described in connexion with the skeletal structures.

HISTOLOGY

In the gastrula the cells differ from each other chiefly in position, and the same is true, even when the germ layers are first differentiated. As development goes on the differences between the various groups of cells increase, each group becoming more specialized for some one purpose and losing the power to do more than the one kind of work. For community of work cells of the same kind become associated together, the result being tissues. A **tissue**, then, is a connected mass of cells similar in appearance and function, together with a varying amount of intercellular substance, usually formed by the cells themselves. The study of the minute structure of animals and especially of the tissues is the province of histology.

There are many kinds of tissues, only a few of which need mention here, but all may be grouped under four great heads: epithelial, nervous, muscular and connective tissues; the members of each group having certain fundamental points in common.

Epithelial Tissues

Epithelia are the covering tissues, and occur on any free surface, internal or external, of the body. Both comparative anatomy and embryology show them to be the primitive tissues, for there are many lower animals which are made up entirely of epithelia, while in the vertebrates the embryo consists solely of epithelia until the mesenchyme appears. Epithelia may come from any of the germ layers, in rare cases (synovial cavities) even from mesenchyme.

The character of epithelium varies according to the nature of the work it has to perform. That on the outside of the body is largely protective, hence it is often thickened and strengthened in different ways to afford resistance against external injuries. In other places, as glands, it has to elaborate and to allow the passage outward of material from within. In the body cavity and in the blood-vessels

it has merely to form the thinnest of coverings, while in the case of sensory structures it is modified (sensory epithelium) to receive the stimuli from without.

The usual classification of epithelia is based on the shapes and arrangements of the cells. Thus in cubical epithelium (fig. 10, *A*)

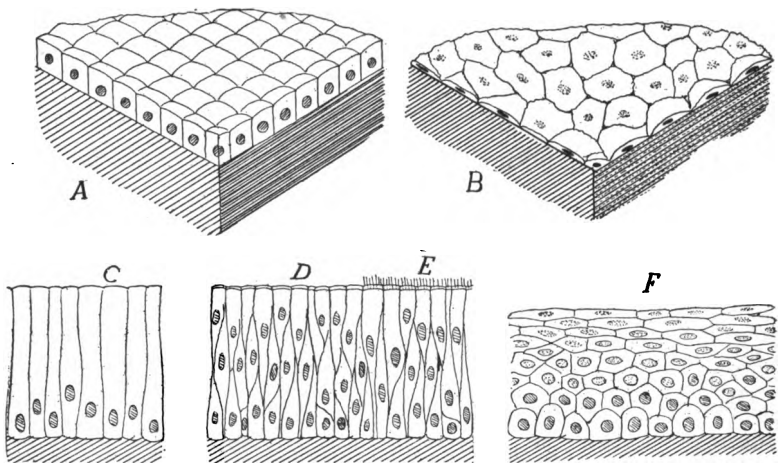


FIG. 13.—Epithelia: *A*, cubical; *B*, squamous; *C*, cylindrical; *D*, stratified cylindrical ciliated at *E*; *F*, stratified squamous. The deeper tissues indicated by oblique lines.

the cells are about as high as broad; in **columnar** (*C*) their height exceeds their diameter; while in **squamous** epithelium, the cells are thin and flat, covering the largest amount of surface with the least amount of material (*B*). Sometimes the epithelial cells are in a

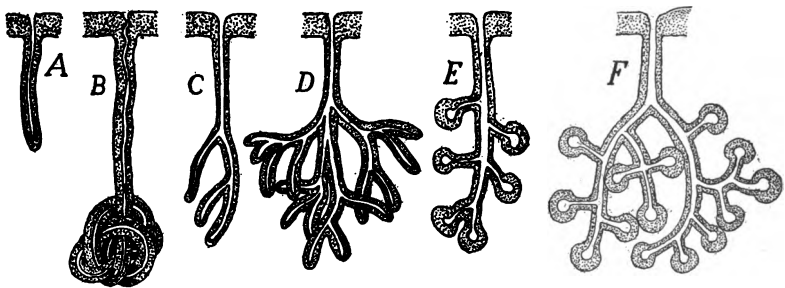


FIG. 14.—Different types of glands; *A*, to *D*, tubular; *E*, *F*, acinous; *A*, simple; *B*, coiled; *C*-*F*, branched.

single layer, forming **simple** epithelium (*A*, *B*, *C*); in other places there are several layers—the epithelium is **stratified** (*D*, *E*, *F*).

Frequently epithelia, usually the columnar variety, are called upon to move fluids slowly; then the free surface is covered with

minute vibratile hairs of *cilia* (*E*) which create currents. In glandular epithelium the cells, usually cubical or columnar, are specialized for the elaboration of secretions to be used by the animal or of waste products (excretions) to be voided from the body.

Glands.—The chief kinds of glands may be mentioned here. All have for their function the extraction and elaboration of certain products from the blood, consequently they have a good blood supply. Glands may be unicellular or multicellular according as they consist of isolated cells or of many cells. In unicellular glands (abundant in the digestive tract) each cell passes its own secretion directly to the place where it is to be used (fig. 22, *u*).

Multicellular glands occur where a large amount of secretion is necessary in a limited space, hence they are not on the surface but at some deeper point, and their product is conveyed to the desired place by a duct. Multicellular glands are of two structural kinds. In the *tubular gland* the whole is approximately of the same diameter throughout, with little differentiation of gland and duct. It may be simple (*A*) or coiled (*B*) or branched (*C*, *D*), these modifications serving to increase the secreting surface. In *acinous glands* (*D*, *E*) there is a marked difference between gland and duct, the glandular part forming an enlargement (*acinus*) on the end of the duct. Both simple and compound acinous glands are common.

Still another type of gland, the *ductless* or 'internal secretion' gland, occurs. In this there is no duct, the secretion elaborated by the cells passing by osmose into the blood-vessels. These secretions, collectively known as *hormones*, have recently acquired great prominence from their influence on different organs.

Nervous Tissues

Nervous tissue has for its function the correlation of the animal with its environment. In order to accomplish this it must provide for the recognition of stimuli from without, the inauguration of other impulses within itself and the transfer of both to other parts. The essential constituent of the tissue is the *nerve cell*, *ganglion cell* or *neuron*, to which are added others of a supportive (glia cells) or nutritive character. As the parts to be connected by the nervous tissues are often remote from each other the neuron is not compact like most other cells, but gives off long processes from the central mass, these processes differing in their terminations. Some end in places where they can only receive stimuli, others where the stimuli can only cause parts to act. Thus the processes are physiologically divisible into afferent and efferent tracts, the body of the cell being, besides a place for the regulation of the nutrition of the neuron, the locality for the regulation and correlation of impulses, and apparently in many cells, for the inauguration of new impulses.

A nerve cell (fig. 15) is **uni-**, **bi-** or **multipolar** accordingly as it has one, two or more processes. In unipolar cells (*C*) the single process sooner or later divides, so that the cell in reality is at least bipolar. At either end the processes may break up into minute twigs, or at one end may terminate, as in muscles and sensory structures, in special end organs. Apparently the impulse enters the cell at one side by one or several processes, and is carried out by a single process. Thus there are to be recognized afferent and efferent processes. The efferent process is called the **axon (axis cylinder)**, When the axon breaks up into twigs, these are called **telodendra**, similar twigs on the afferent sides being **dendrites** (fig. 15, *A*, *t* and *d*).

All parts of the neuron proper—cell bodies and processes—are gray in color, but usually the processes are surrounded by a **medullary sheath** (*m*) of a peculiar white substance (myelin) rich in fat, which

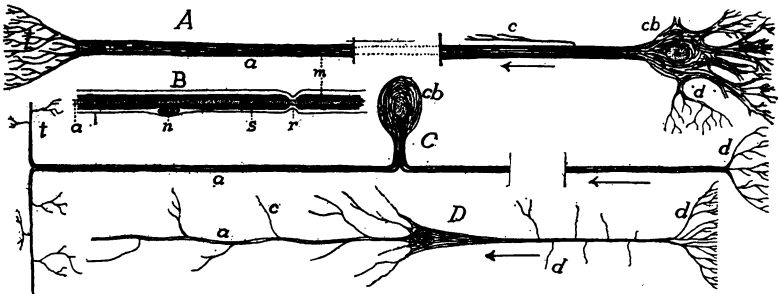


FIG. 15.—Various kinds of nerve cells. *A*, multipolar cells; *B*, portion of nerve fibre with sheaths; *C*, unipolar cell; *D*, pyramidal cell; *a*, axon; *c*, collateral; *d*, dendrites; *cb*, cell body; *m*, medullary sheath; *n*, nucleus of cell of Schwann's sheath; *r*, node of Ranvier; *s*, sheath of Schwann; *t*, telodendron.

apparently acts in part as an insulator, preventing nervous impulses from passing from one axon to another. It is also nutritive in character. This sheath does not continue over the dendrites. Frequently the dendrites of two neurons interlace for the transference of stimuli from one to the other, but the present opinion is that, at least in vertebrates, there is no actual continuity of substance between neurons, only an interlacing of terminal twigs. The medullary sheath is not cellular, but frequently fibres may be surrounded by a **sheath of Schwann** (*s*), with scattered nuclei. This has been regarded as mesenchymatous, but recent researches tend to show that it is ectodermal, its cells coming from the early nervous system.

Nervous tissue consists of these neurons plus connective tissue and glia cells. A nerve, as found in dissection, consists of numbers of

axons, bound together by a connective-tissue envelope (**perineureum**). The myelin gives these nerves a white color. In the brain and spinal cord there are tracts of medullated fibres (**white matter**) while the parts with abundant nerve cells are gray. When such nerve cells are aggregated in the course of a nerve, it causes an enlargement called a **ganglion**. Interlacing among the neurons in brain and spinal cord is the **neuroglia**, which is also derived from the ectoderm, and acts as a support, but has no nervous functions. Certain of these **glia cells** develop many branches (mossy cells) which twine among nerve cells, axons, and dendrites.

Muscular Tissues

While several kinds of cells have the power of changing shape, those composing the muscular tissues possess it in a marked degree, acting quickly and with force, so that these tissues are preeminently the tissues of motion. The cells become elongate and develop in their interior a large amount of contractile substance (**myofibrillæ**), which on stimulation, contracts, shortening the cell. In the vertebrates, muscular tissue always arises from the mesoderm. Two types are recognized, differing markedly in origin, appearance and physiological action.

The **smooth** or **involuntary muscles** arise from the mesenchyme. They consist of long and spindle-shaped cells (fig. 16, *A*), each with a single nucleus, the protoplasm traversed by numerous myofibrillæ, which appear like fine longitudinal lines. In the vertebrates the smooth muscle is not under control of the will; it contracts slowly.

In contrast to the smooth is the **striped** or **voluntary muscular tissue**, which arises from a modification of the mesothelium. Except in the case of the muscles of the heart, the striped tissue is under control of the will; it usually occurs in larger masses than does the smooth, and is capable of rapid contraction. It differs structurally from smooth muscle. Instead of distinct, uninucleate cells there are long cylindrical elements (fig. 16, *B*), the primitive fibres, each with several nuclei in the interior in lower vertebrates, on the periphery in the higher. Most of the protoplasm of the fibre has been altered to minute contractile fibrillæ, each crossed by lighter and darker bands, and as these correspond in position in the different fibrillæ, they give the fibre its characteristic cross-banded appearance.

The primitive fibres rarely branch at their extremities. Each is

surrounded by a structureless envelope, the **sarcolemma**, while numbers of fibres are bound into bundles and muscles by connective tissue (**perimysium**) which carries nerves and blood-vessels. At the ends of the bundles the perimysium continues into the tendons which attach the muscles to other parts.

The heart muscle also arises from the mesothelium, is cross-banded, but is removed from control of the will. The cells are usually short (usually with a single nucleus); they branch, the branches connecting adjacent muscle cells.

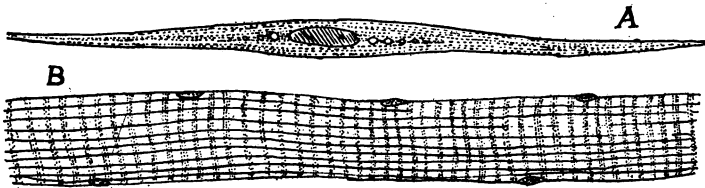


FIG. 16.—A, smooth muscle cell; B, striped muscle.

Connective Tissues

The tissues grouped here arise from the mesenchyme and are distinguished from all other tissues by the great amount of intercellular substance produced by the cells themselves. This substance or **matrix** varies in character and determines the variety of tissue. Frequently it is dense and hence the connective tissues may give the body support, and in fact they are sometimes called supportive tissues.

In the earliest phase, known as **embryonic connective tissue** (fig. 17, A), the cells are scattered, with long radiating processes, and between the cells is a thin gelatinous matter. It is by increase of this intercellular substance by taking up water that many embryos gain so in size without taking food. The embryonic connective tissue may develop in various directions.

Thus some of the cells may contain pigment granules, forming **pigment cells** (B), or oil globules may be deposited in them to such an extent that the cells become spherical, while the intercellular substance is reduced, thus affording fat or **adipose tissue**. Most common of the connective tissues is **fibrous tissue** (white or non-elastic tissue) in which the cells are branched or spindle-shaped while the matrix is filled with fine fibrillæ of considerable strength and little elasticity.

These fibrillæ are parallel to each other in tendons (C), which have to convey strains in one direction; or they may be interlaced confusedly, the tissue then forming sheets or membranes. Occasionally, as between the skin and the muscles, the fibrous tissue may be loose (**areolar tissue**). In **elastic tissue** fibres of another kind are mingled among the non-elastic fibrils. These are yellow and elastic, and when abundant give an elastic character to the whole.

In cartilage and bone the matrix is more solid and is abundant. These are the skeleton-building tissues. In **cartilage** the matrix is firm and consists of a peculiar substance called **chondrin**. When the

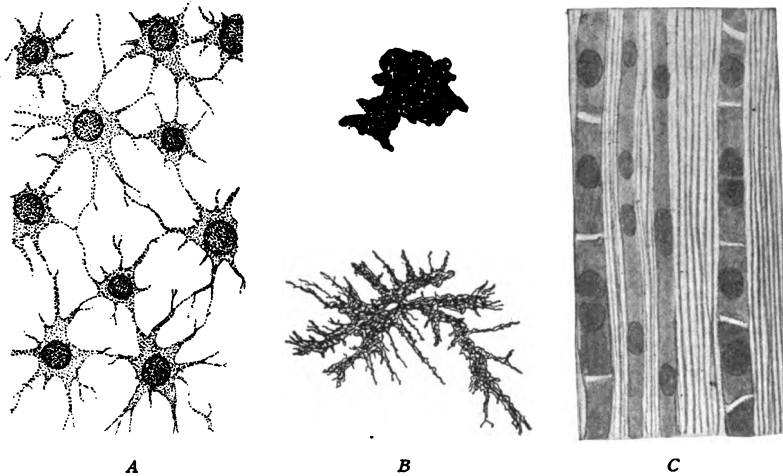


FIG. 17.—Connective tissues. A, embryonic, from *Amblystoma*; B, expanded and contracted pigment cells from *Amblystoma*; C, fibrous, from tendon.

chondrin is nearly pure it is milky in appearance (hyaline cartilage, fig. 18), but it may be invaded by numerous strands of fibrous or elastic tissue, resulting in fibrous or elastic cartilage. Cartilage increases in size by additions to the exterior and also by divisions of its cells and by increase in the amount of matrix. Externally it is bounded by an envelope of connective tissue (**perichondrium**) which bears blood-vessels and may give attachment to muscles, etc.

Bone may arise directly from embryonic connective or fibrous tissue, or by the ossification of cartilage. In either case the result is a strong matrix composed of calcium phosphate and carbonate in a ground substance of organic matter (ossein). Minute tubes (**Haversian canals**), bearing blood-vessels, etc., run through the matrix (fig. 19), and parallel to these canals or to the external surface of the

bone are the cells, arranged in layers. The space occupied by a cell is called a **lacuna**, from which minute tubules or **canaliculi** penetrate the matrix. There are small spaces in many bones occupied by the red marrow, which is especially noticeable as one of the places of for-

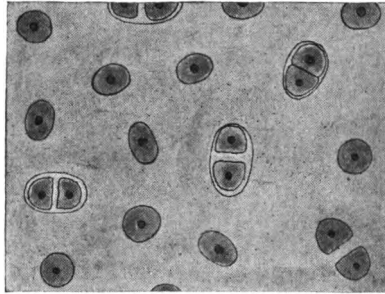


FIG. 18.—Hyaline cartilage.

mation of red blood-corpuscles. Externally every bone is covered by a layer of fibrous connective tissue, the **periosteum**.

The **dentine** of teeth and placoid scales is closely allied to bone, the chief difference in density, the bone-forming cells (odontoblasts)

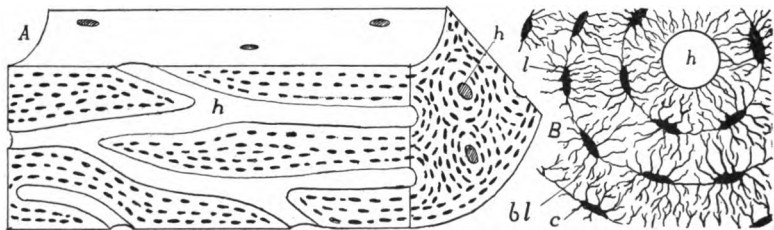


FIG. 19.—A, Stereogram of bone; B, cross-section of bone, more enlarged; c, canaliculi; bl, bone lamellæ; h, Haversian canal; l, lacuna.

not being enclosed in the matrix, while the canaliculi (here called **dentinal canals**) are parallel to each other.

Blood is sometimes regarded as a connective tissue, the corpuscles being the cells and the fluid part (plasma) the matrix. It is here dealt with in connexion with the circulatory system.

COMPARATIVE MORPHOLOGY OF VERTEBRATES

THE INTEGUMENT

The integument is the covering of the body, the term including the skin (**cutis**) and all structures derived from it. From its position it is a protective coat. It comes into relation with the external world and is modified in various ways, becoming hardened to ward against mechanical injury, developing sensory structures to give information of untoward conditions and being impervious so as to prevent loss of the body fluids, or the entrance of others from without. Naturally the habitat, aquatic or terrestrial, has great influence in the character of the modifications.

In all vertebrates the integument consists of two layers, an outer **epidermis** which consists of the ectoderm after the separation of the nervous system, and a deeper layer, the **corium (derma)** of mesenchyme, largely derived from the somatic wall of the myotomes, into which other structures (nerves, blood-vessels, etc.) extend.

In the epidermis, again, two layers are always present. At the base, next to the corium is the **Malpighian layer (stratum germinativum)**, the cells of which are nourished by the fluids of the corium. Hence they can grow and divide, the new cells thus formed gradually passing to the outside where they form the second layer, the **stratum corneum**, the outer cells of which are usually worn away as fast as new ones are added from below. Occasionally these outer cells come off in large sheets, as when a salamander or a snake sloughs its 'skin.' In the development of the epidermis of the terrestrial vertebrates the first layer of cells budded from the Malpighian stratum form a continuous sheet which is later shed as a whole. This is the **periderm** (fig. 20), the older name of **epitrichium** being inappropriate, since the layer is found in reptiles and birds where no hair occurs.

The Malpighian layer alone is concerned in the formation of the glands connected with the skin, and the corresponding part of the ectoderm contributes to the sensory structures like the nose and ear.

The corneum, on the other hand, takes part in the formation of protective structures like hair, nails, claws, feathers, and other cuticular outgrowths. The epidermis is generally thicker in terrestrial than in aquatic vertebrates, and in the latter, being constantly moist, shows less of the horny consistency, than occurs in animals which live in the air.

The corium lies immediately beneath the epidermis and is less sharply separated from the deeper tissues by a looser layer of connective tissue (**subcutis, tela subjunctiva**) in which fat is frequently extensively developed. The corium is largely composed of fibrous connective tissue, intermingled with elastic tissue, blood-vessels, nerves, smooth muscle fibres, etc. It is usually thin in the lower vertebrates, but is much thicker in most mammals, and forms the whole of ordinary leather. Pigment cells may occur in both epidermis and corium. These are mesenchyme cells, loaded with pigment, which are frequently under control of the nervous (sympathetic) sys

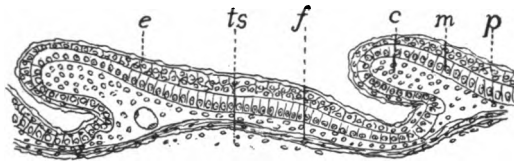


FIG. 20.—Section of developing scales of lizard, *Scoloporus*. *c*, papilla of corium; *e*, outer layer of epidermis which later becomes cornified; *f*, fibrous layer of skin; *m*, Malpighian layer; *p*, periderm; *ts*, tela subjunctiva.

tem, and can be altered in shape (**chromatophores**), thus producing color changes, which, as in the chameleons, may be very marked.

Horny scales, produced by a cornification of the epidermis, are found in all groups of terrestrial vertebrates, but they are rare in amphibians and mammals. The development is best seen in reptiles (fig. 20). By a multiplication of the cells of both corium and epidermis in definite regions the skin becomes divided into thicker areas, separated by thinner lines, each area corresponding to a future scale, which arises by the conversion of the stratum corneum into horny material. In snakes and lizards these scales, together with all of the stratum corneum (even the covering of the eye) is periodically molted, the separation taking place at the surface of the stratum Malpighii. In turtles and alligators there is a gradual wearing away of the surface.

Closely allied to scales are claws, hoofs and nails (fig. 21). A claw may be regarded as a cap on the tip of a digit, formed by two

scales, one dorsal (**unguis**), the other ventral (**subunguis**). Of these the unguis is the more important. It grows continually from a root, and in mammals is forced forward over its bed. In the claw (*B*) the unguis is curved both transversely and longitudinally, the subunguis forming its lower surface. In the human nail (*A*) it is nearly flat in both directions and the subunguis is reduced to a narrow plate just beneath the tip of the nail. In the hoof (*C*) the unguis is rolled around the tip of the toe, while the subunguis forms the 'sole' inside it. The 'frog' is the reduced ball of the toe which projects into the hoof from behind.

Strictly speaking the scales of fishes are tegumentary, but because of their close relations to the skeleton they are best treated in that connexion.

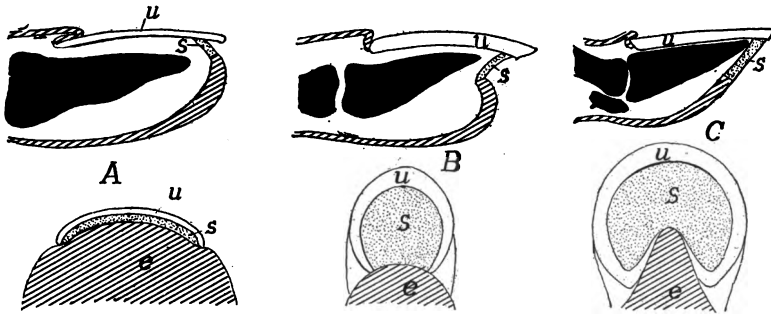


FIG. 21.—Diagrams of (*A*) nails, (*B*) claws, and (*C*) hoofs, based on Boas. *e*, unmodified epidermis; *u*, unguis; *s*, subunguis.

The integument presents many different conditions in the separate groups of vertebrates, and so details are best given under the special heads.

FISHES.—The aquatic life renders the epidermis of fishes soft and cornifications of it are comparatively rare, among them the peculiar 'pearl organs' which appear in the skin of some teleosts at the breeding season. Glands, on the other hand, are abundant. There are unicellular and multicellular mucus glands of different shapes in the epidermis, the secretion of which furnishes the slime on the surface (fig. 22). Some elasmobranchs and a number of teleosts have poison glands, usually in close relation to the spines of the fins (fig. 23). The elasmobranchs also have large **pterygopodial glands** in the 'claspers' of the males, but their purpose is not well understood.

Possibly the most striking of the epidermal organs are the luminous organs or **photophores**, which are most common in elasmobranchs

and teleosts from the deep seas, where sunlight does not exist. They are apparently modified glands, and the development is known in *Porichthys*. There is an involution of cells of the Malpighian layer into the corium, where they become cut off from their point of origin, and are differentiated into a deeper glandular layer and an outer

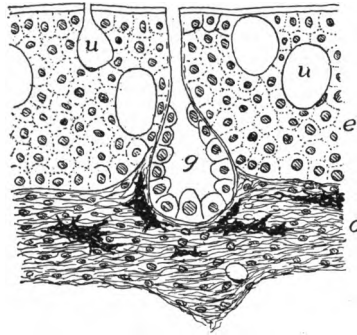


FIG. 22.—Section of skin of *Protopterus*. *c*, corium; *e*, epidermis; *g*, multicellular gland; *u*, unicellular glands.

rounded body, the lens (fig. 24). Around this the corium forms a reflecting layer enclosed in a pigment coat. The glandular layer is the seat of light production. In other photophores either reflector or pigment may be lacking, but in their highest development they so resemble an eye that at first they were described as such. They are really 'dark lanterns.'

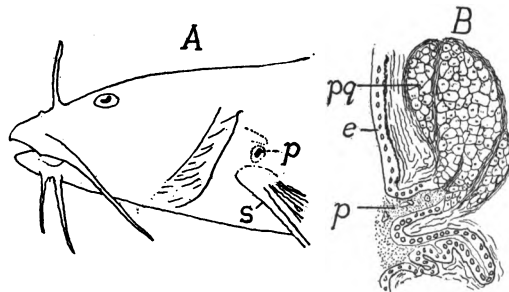


FIG. 23.—A, head of *Noturus flavus*; B, section of poison gland of *Schilbeodes miurus* (after Reed). *e*, epidermis; *p*, pore of poison gland, *pg*; *s*, spine of pectoral fin.

In the myxinoids the skin contains numerous thread cells in pockets which may extend into the underlying muscles. Each thread cell contains a long thread, which is discharged upon stimulation, the threads forming a network in which the mucus secreted by the ordinary gland cells is entangled.

The corium is thin and consists of horizontal bands of fibrous tissue, crossed at intervals by vertical strands. Fat is common in the tela subcutanea, and in

some fishes this layer contains numerous crystals of guanin which gives it a silvery appearance. This guanin forms the base of 'essence of pearl' from which artificial pearls are made. The scales of fishes, although formed in the skin, are considered in connexion with the skeleton.

AMPHIBIA.—The amphibia are remarkable in that the epidermis of the larvæ is ciliated in the early stages, and is two cells in thickness from the first. The skin, in the larvæ and the aquatic species, contains numerous mucous glands and some for the production of poison, some of the latter being prominent like the 'parotid glands' on the neck of the anura and the gland on the back near the base of the tail.

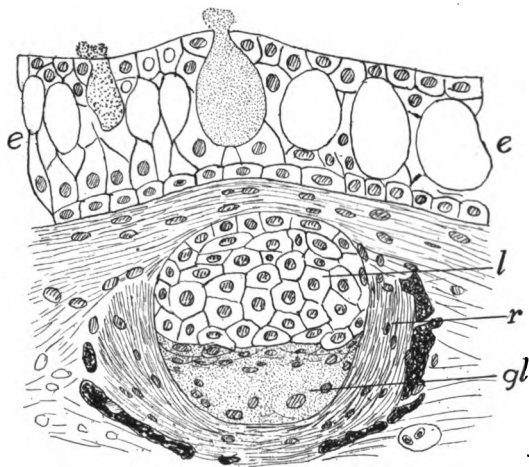


FIG. 24.—Section of luminous organ (photophore) of *Porichthys*, after Greene. *e*, epidermis with mucous cells; *gl*, glandular layer of photophore; *l*, lens; *r*, reflector surrounded by pigment.

The corium is thin, and in the frogs is separated from the underlying parts by large lymph spaces which render the skinning of these animals so easy. As the amphibia respire largely by the skin (there are several lungless salamanders) the corium is richly supplied with blood-vessels, and at the time of the metamorphosis of the anura these penetrate even into the epidermis, as at that time the lungs are not yet functional and the gills are absorbed. The stratum corneum is shed periodically, either as a whole (urodeles) or in patches. The warts of toads are in part cornifications of the epidermis, and a similar hardening of the skin on the ends of the toes of some results in claws. In the males of an African frog (*Astylosternus*) the skin has the granules of the surface developed, at the breeding season into hair-like structures, supplied with nerves and apparently sensory in character.

REPTILES.—All living reptiles are characterized by the extensive development of horny scales and frequently of bony plates in

the skin, but some of the fossil groups (ichthyosaurs, pterodactyls, some dinosaurs, possibly plesiosaurs) had a naked skin. Correlated with this cornification of the epidermis, glands are rare. Some turtles have scent glands beneath the lower jaw and along the line between carapace and plastron; snakes and crocodilians have them connected with the cloaca, while the latter have others, of unknown function, between the first and second rows of plates along the back, as well as protrusible musk glands on the lower jaw. These latter are not true glands as they produce no secretion but cast out the lining cells.

The corium presents two layers, the outer rich in chromatophores, but, aside from some snakes and lizards, the color changes are not remarkable. Claws are common on the toes. The so-called "femoral pores" on the undersurface of the legs of lizards are not glands, but are epidermal structures composed of horny cells, and possibly have a sexual function.

BIRDS have both layers of the skin very thin, the epidermis developing both scales and feathers. Correlated with this extensive

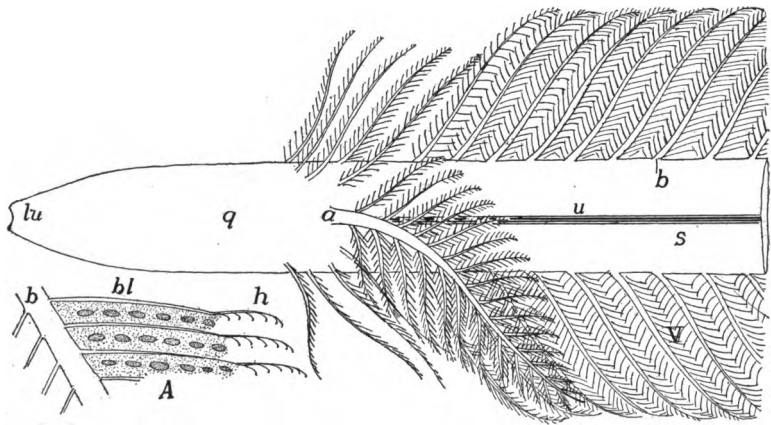


FIG. 25.—Diagram of base of contour feather. *a*, aftershaft; *b*, barbs; *bl*, barbules; *h*, hooks on ends of barbules; *lu*, lower umbilicus; *u*, umbilicus; *q*, quill; *s*, shaft; *v*, vane. *A*, portion of a barb showing the barbules and hooks.

development of cornified structures is a striking paucity of glands. There are none in the ostriches, but others have the familiar oil (**uro-pygial**) glands at the base of the tail, the secretion of which is used in dressing the feathers. The only other dermal glands in birds are modified sebaceous glands near the ear in some rasoers. The scales on the legs and the claws on the feet and occasionally on the wings, are derivatives from reptilian ancestors. The feathers are also derived from scales, but are greatly modified.

Feathers.—There are several kinds of feathers but all may be grouped under three heads: hair feathers (*filoplumes*), down feathers (*plumulæ*), and contour feathers (*plumæ*). The latter have all of the feather features (fig. 25) and in the typical form consist of shaft and vane. The basal part of the shaft is the hollow quill, in which is a small amount of loose pith. In the region of the vane the shaft, here called *rhachis*, is solid, and running the length of its lower surface is a groove, the *umbilicus*. The vane consists of lateral branches (*barbs*) on either side, which have, in turn, smaller side branches (*barbules*), these with small hooks at their sides and tips (A). In-

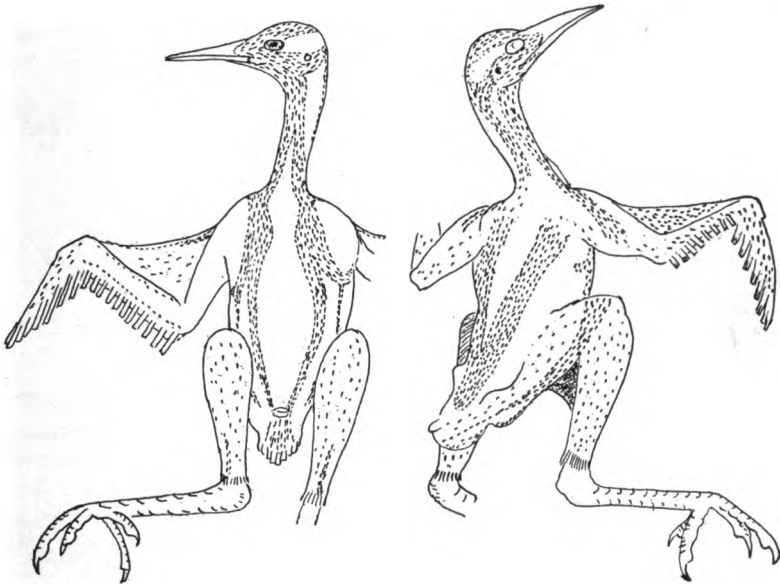


FIG. 26.—Feather tracts of *Geococcyx californianus*, after Shufeldt.

terlocking of these hooks gives firmness and continuity to the whole vane. In down feathers the barbs arise directly from the end of the quill, and, as hooks are lacking, the barbs do not interlock and no vane is formed. Hair feathers are merely long and slender shafts with no barbs, the simplest, if not the most primitive kind of feather. It is still a question as to the primitive type. The oldest known fossil bird, *Archæopteryx*, had well-developed contour feathers.

Except in the ostriches, penguins, and toucans, feathers are not distributed everywhere on the surface of the body, but are gathered in feather tracts (*pterylæ*), separated by *apteria* in which no contour

feathers and but few down or hair feathers occur. These vary in their arrangement in different groups of birds and are of systematic importance (fig. 26).

Complicated as they are, feathers are probably derived from scales, and the section of lizard skin (fig. 20) might well represent an early stage in the development of a feather. A down feather begins as a thickening of the corium, pushing the epidermis before it. By continued growth this forms a long, finger-like papilla, projecting from the skin. The corium extends into the outgrowth, carrying blood-vessels with it, while an annular pit, the beginning of the feather follicle, forms around the base of the papilla. Next, the corium or pulp of the distal part of the papilla forms several longitudinal ridges (fig. 27) which gradually increase in height, growing into the epidermis and pressing the Malpighian layer above them against the periderm. As a result the stratum corneum is divided distally into a number of slender rods arising from the base (quill), which

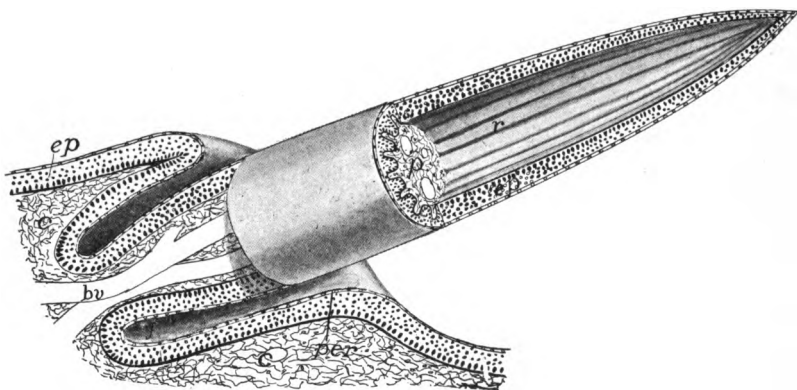


FIG. 27.—Stereogram of developing down feather. *bv*, blood-vessels entering pulp; *c*, corium; *ep*, epidermis; *f*, feather follicle; *p*, pulp (mesenchyme) of developing feather; *per*, periderm; *r*, rods of epidermis, which later dry, separate, and form the down.

at last are only held together by the periderm. Then the pulp retracts, carrying with it the Malpighian layer. With the blood supply removed, the epidermal parts dry rapidly, and the periderm ruptures, allowing the rods to separate to form the down.

A contour feather has much the same development, differing in details, for an account of which reference must be made to special papers. The ridges of the corium are no longer longitudinal, but, beginning on the dorsal side of the papilla, run obliquely outward and downward (fig. 28) until they meet below. Thus there are formed a series of rods set at an acute angle to the undivided dorsal strip, the future shaft. When set free, as before, by the rupture of the periderm, these rods straighten out, forming the vane. In the region of the shaft there are two longitudinal ridges on the ventral side. These gradually roll together, thickening and strengthening the shaft, the groove between them forming the umbilicus. As will be understood, the dorsal and ventral sides of the feather were the outside and inside of the stratum corneum of the papilla.

The corium of birds is thin and consists of irregularly interlaced fibres; it is rich in sense (tactile) organs and smooth muscle fibres, which are largely used in elevating the feathers. The colors of feathers depend in part upon pigment—red, yellow, orange, brown, and black—deposited in them, but the iridescent colors are due to interference spectra.

MAMMALS have a skin relatively thicker than have other vertebrates, both layers contributing to the thickness and the whole is rather loosely attached to the lower tissues. There are numerous glands, and the hair, abundant in all orders except the whales and sirenians, is found in no other class. Other cuticular structures as horn and claws (p. 31) are widely distributed, and scales occur in several forms.

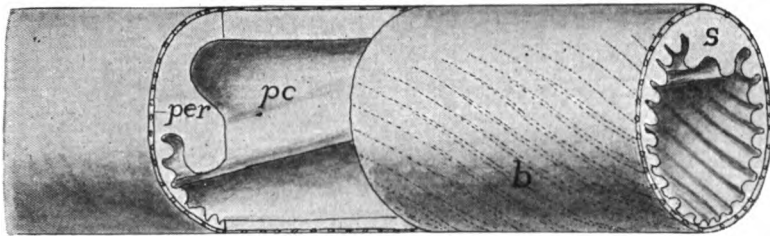


FIG. 28.—Stereogram of part of developing contour feather; compare with fig. 24. *b*, developing barbs; *pc*, pith cavity; *per*, periderm; *s*, rhachis.

The corium is thick and composed of irregularly interlaced fibres with muscles, blood vessels, etc. Its outer surface is frequently thrown into papillæ or ridges, especially on the palms and soles, these carrying the epidermis with them. In the thick epidermis several strata may usually be recognized: at the base a thick Malpighian layer; then a thin stratum lucidum in which distinct cells cannot be recognized; and on the outside the stratum corneum. One or more others are sometimes present. As will readily be understood a cell passes through all of these layers before it is worn from the surface of the skin.

Hair.—The epidermis takes the initiative in the formation of hair. It thickens in spots, the thickenings pushing into the corium and each being cupped at the tip, blood-vessels extending into the cup. The basal cells of the ingrowth, thus richly nourished, proliferate rapidly and the new cells thus formed are forced outward, forming the hair. While this is going on the ingrowth splits around the hair, forming the follicle, while another ingrowth of the Malpighian layer forms the sebaceous gland which oils the hair.

A section through a hair and its follicle gives the following layers (fig 29). Around all is the connective-tissue envelope, formed from the corium; next inside is the outer root sheath formed of the Malpighian layer and extending

to the cavity of the follicle. Around the root of the hair is the inner root sheath, two cells in thickness, the layers being known as Henle's and Huxley's layers. These do not extend outside the follicle. In the hair itself there is a cortical layer surrounding the central medulla, the hair not being hollow.

Hair differs greatly in size, the spines of the porcupines forming one extreme, the prenatal hair (lanugo) of man the other. Hair is shed at intervals. The old hair ceases to grow, separates from its base, and later is pushed out when the root begins again to proliferate. There are smooth muscle fibers connected with the roots of the hairs, their function being to raise the hair from its usual inclined position under influence of the sympathetic system. There are also usually nerves distributed to the base of the hairs, making them to some extent sense organs, a condition which reaches its greatest development in the facial hairs (vibrissæ) of carnivores and the hairs on the wings of bats.

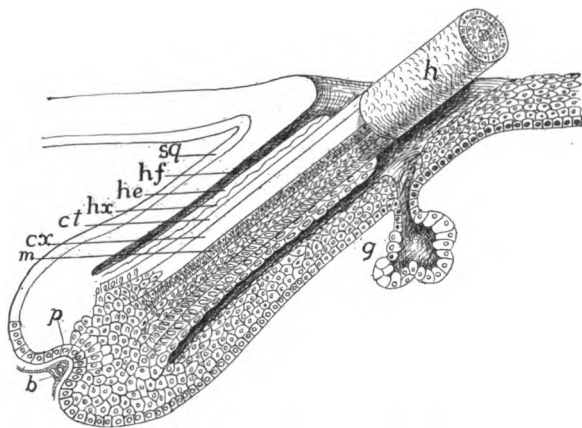


FIG. 29.—Diagram of structure of hair. *b*, blood-vessels; *ct*, cuticle of hair; *cx*, cortex; *g*, gland; *h*, hair; *he*, Henle's layer; *hf*, hair follicle; *hx*, Huxley's layer; *m*, medulla; *p*, papilla; *sg*, stratum germinativum of epidermis.

Scales occur in several orders, being usually best developed on the tail and feet. They may be rounded, quadrangular or hexagonal, the square scales being arranged in rings around the part, the others in quincunx. These are closely similar to the cuticular scales of reptiles (p 30). Recent investigations tend to show that there is a close relation between scales and hairs, since in the mammals with scales the hairs are usually arranged in groups of three or five behind each scale (fig. 30); while in those without scales the hairs are frequently grouped in the same manner. The illustration (fig. 31) is interesting as showing the arrangement in man and the possible relation to ancestral scales. The statement is also made that in the early embryo the hairs are arranged in longitudinal rows and that the grouping comes later.

The mammalian skin is usually rich in glands which are of two types, tubular and acinous (p. 23). To the first belong the sweat glands, which extend from the Malpighian layer, where they arise,

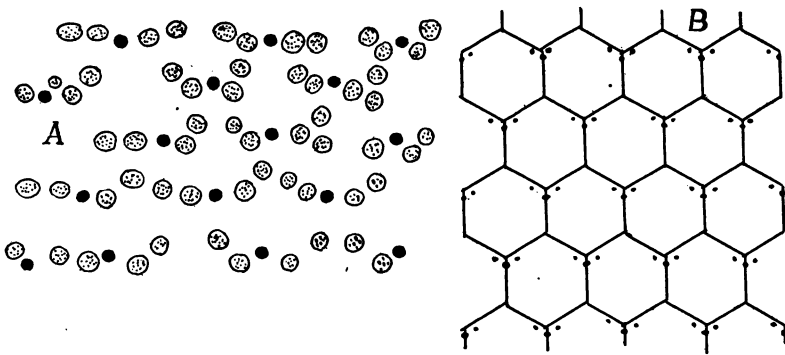


FIG. 30.—A, arrangement of the two kinds of hair in *Ornithorhynchus*; B, Arrangement of hair in *Ptilocercus lori*, with the probable relation of the hair to the ancestral scales; both after Meijere.

down through the corium and then are coiled in order to obtain greater length. The acinous glands are represented by the sebaceous glands in connexion with each hair (fig. 29, g), and by the scent glands in the anal or inguinal region of many carnivores, rodents and

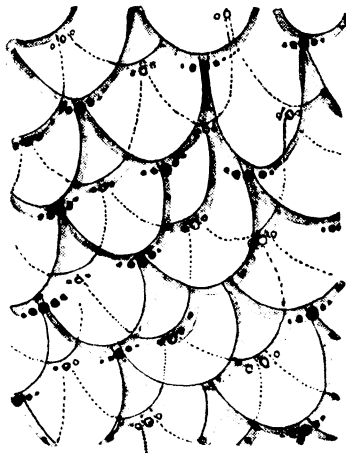


FIG. 31.—Arrangement of the hairs in groups of three and five in the human embryo, with the probable ancestral arrangement of the scales, after Stöhr.

edentates. Others may occur in very diverse regions, as on the face (bats, deer), in the occipital (camel) or temporal region (elephant), or on the legs (swine).

The mammary or milk glands are now known to be modified tubular glands, possibly derived from sweat glands. In the monotremes the simplest condition is found, numbers of glands opening into a pair of sacs in the sides of the marsupium, or pouch where the young are kept, on the ventral side of the body (fig. 32, *A*). In the marsupials there is a slight nipple developed from the bottom of the pocket. In the higher groups of mammals the first appearance of the milk glands is the formation of a 'milk line,' a ridge on either side of the body from in front back to the inguinal region. This is soon divided into 'milk points,' from each of which there is an ingrowth of epidermis into the corium, the intermediate parts of the

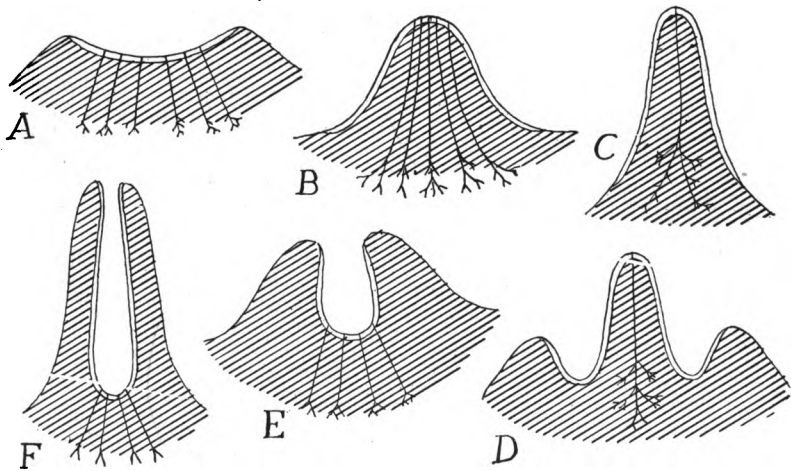


FIG. 32.—Scheme of different kinds of nipples, based on figures by Weber. Single line, ordinary integument, double line, that of primary mammary pocket. *A*, primitive condition, found in *Echidna*; *B*, human nipple; *D*, *Didelphys* before lactation; *C*, same at lactation; *E*, embryonic, *F* adult conditions in cow. *B* and *C* are true nipples, *F* a pseudo-nipple (teat).

line disappearing. Each of the points may develop into a definitive **mamma** or milk gland, but not all of them come to full development; for the number in the adult is less than in the embryo, varying from a single pair in many mammals to eleven in Centetes, the number roughly corresponding to the number of young at a birth. This method of formation explains the varying position of the mammae and also the occasional occurrence of more than the normal number (polymastism) in man and other mammals. Each gland is provided with a nipple and of these there are two kinds (fig. 32). In the one the whole surface on which the lacteal ducts empty becomes elevated,

the true nipple, in the other—the teat—the region around the openings of the ducts becomes drawn out into a tube with the ducts opening at the bottom (ungulates).

THE SKELETON

The term skeleton as used here is applied to any of the harder parts of the body, developed from the mesoderm and serving for support, for the attachment of muscles, for protection and the like.

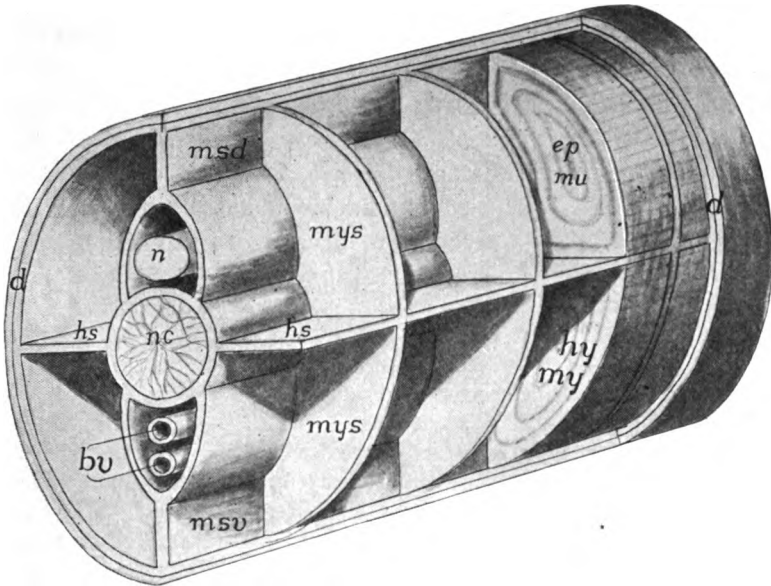


FIG. 33.—Diagram of the skeletogenous tissue in the caudal region of a vertebrate. *bv*, blood-vessels; *d*, corium; *epmu*, epaxial muscles; *hs*, horizontal partition; *hymy*, hypaxial muscles; *msd*, *msv*, dorsal and ventral median septa; *mys*, myosepta; *n*, spinal cord; *nc*, notochord.

This excludes any purely epidermal hard parts, and these have been included with the integument.

As the skeleton can only develop where there is mesenchyme; the distribution of the chief skeletogenous parts, sometimes called the membranous skeleton, may be given here, continuing the account from page 21. First is the corium, immediately beneath the epidermis, forming an envelope around the internal structures. This connects in the middle line, above and below, with a longitudinal partition (*msd* and *v*) which separates the muscle masses of the two sides. This partition splits to pass on either side of the central

nervous system and the notochord, and, just beneath the peritoneum, around the viscera. From the median partition sheets of mesenchyme (**myosepta**) pass vertically between the myotomes to the corium, they being, like the myotomes, metameric. Then there is a horizontal sheet on either side which lies between the epaxial and hypaxial muscles (p. 132). Not all parts of this membranous skeleton develop hard structures, but these are most apt to arise at the intersection of the various planes.

The skeletal structures are divided into the **dermal**, arising in the outer mesenchymatous envelope, and the **endoskeleton**, formed in the other parts and lying deeper in the body. The dermal skeleton includes the scales of fishes, the dermal armor of many reptiles and fossil amphibians and the bony scales in the skin of crocodilians and some mammals. In the strict sense the so-called membrane bones of the skull and the cleithrum of fishes and the clavicle and episternum of higher vertebrates should be included here, since they apparently have been derived from dermal ossifications, but convenience of treatment necessitates their consideration with the endoskeleton, with which they are intimately associated.

It is a question whether the dermal or the endoskeleton is the older. The most primitive of the living species, the cyclostomes, have no dermal skeleton, but have cartilage developed to some extent. In development, also, cartilage always appears before there is a trace of the exoskeleton. On the other hand, some of the oldest fishes known have a well-developed dermal armor, while the best preserved ostracoderms show no trace of an internal skeleton. The external skeleton has probably arisen as a means of protection, the internal as a result of muscular or other strains.

Bones and cartilages are connected (**articulated**) with each other in different ways, the parts in some joints being movable on each other; in other cases no motion is possible. In the latter (**synarthroses**) there may be a close approximation of the elements with a thin membrane between them, this type being strengthened in the skull by the interlocking of sawtooth-like projections (**suture**). In places, with growth, all lines of demarcation between two originally distinct elements may disappear and the elements form one continuum (**ankylosis** or **synostosis**). The movable joints are grouped under two categories. In **amphiarthrosis**, illustrated by the movements of the human vertebræ on each other, the motion is slight and is accomplished largely by intervening ligaments and cartilages. In **diarthrosis** the parts are freely movable, there being between them a closed articular cavity, lined by a (**synovial**) membrane which secretes a fluid which lubricates the surfaces.

Cartilages and bones are covered on their outer surfaces by an envelope of connective tissue, called respectively **perichondrium** or

periosteum. These membranes form the means by which muscles are attached to the skeleton, and by which blood-vessels obtain entrance to the hard parts. The periosteum is also a seat of bone formation.

DERMAL SKELETON

When present, the dermal skeleton arises by a marked proliferation of cells at definite points in the corium. These cells become specialized (**scleroblasts, odontoblasts or osteoblasts**) for the deposition of salts of lime plus a varying amount of organic matter (**ossein**). Upon limy plates formed in this way other parts, also calcareous, may be laid down by the basal surface of the epidermis, so that the whole dermal element may be in part mesenchymatous, in part ectodermal in origin.

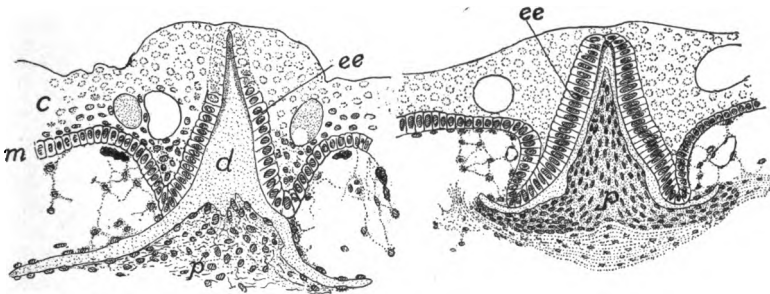


FIG. 34.—Cross-sections of developing scale of *Acanthias*. *c*, stratum corneum; *d*, dentine of scale; *ee*, enamel organ; *m*, stratum Malpighii; *p*, pulp.

It is generally thought that the primitive dermal skeleton resembled that of existing sharks, and that from the hypertrophy or fusion of such scales the so-called membrane bones have arisen. Then the scales of other vertebrates are to be traced back to an elasmobranch ancestry, while teeth are thought to be modified scales. Hence the structure and development of the elasmobranch scale should be understood.

At regular intervals in the skin of a shark there is a multiplication of cells of the corium, each aggregation forming a small papilla which projects above the surrounding corium, carrying with it the basal layer of the epidermis (fig. 34). The surface cells of the papilla and the region around it become converted into osteoblasts which secrete calcic salts on their outer ends, thus forming a small plate of dentine (p. 28) with a central spine into which the papilla extends. The overlying epidermal cells form an **enamel organ**, the lower

surface of which secretes an even harder layer of **enamel**¹ upon the dentine base, this being thickest on the tip of the spine. The mesenchyme in the papilla is the so-called pulp. With continued growth the spine projects through the epidermis, giving the skin of the shark its characteristic rough (shagreen) condition. This is the **placoid** type of scale.

FISHES.—In the adult elasmobranchs the scales may be large and remote from each other (skates) or small and closely set. In the torpedo scales are lacking, while in the chimæroids they occur only on the claspers, on the frontal horn, and as extreme forms, in a great spine in front of the dorsal fin.

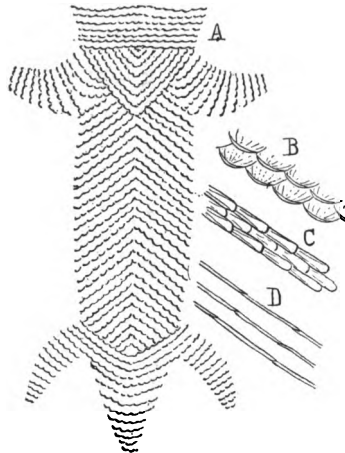


FIG. 35.—Ventral armor of Stegocephals (after Credner-Zittel). *A*, *Branchiosaurus*; *B*, detail of same; *C*, detail of *Archegosaurus*; *D*, of *Peirobates*.

A few ganoids lack scales (*Polyodon*), while the sturgeon have minute granules and five rows of large plates along the sides. *Amia* has scales of the cycloid type, soon to be described. With these exceptions the ganoids have **ganoid** scales, which are rhomboid in outline and joined to each other like parquetry. They consist of two layers, the lower apparently homologous with the dentine of sharks, except that it is formed in, not on, the corium. The outer layer of ganoin is formed by the corium and consequently cannot be enamel as once was thought.

A few teleosts are scaleless (some eels), but elsewhere scales are formed in pockets in the corium (fig. 203). At first they lie side by side, but with growth they overlap like shingles. There is only one layer of bone mixed with a large amount of ossein (p. 27). In cycloid scales the element is circular and is marked with concentric and radiating lines, the former indicating periods of growth. The **ctenoid** scales differ in having the posterior edge of each scale truncate and this edge and the surface toothed. Cycloid and ctenoid scales intergrade and both kinds may occur on the same fish (many gobiids).

¹ There is some question whether this layer is really enamel; the usual statement as to its nature is followed here.

AMPHIBIA.—Traces of a dermal skeleton are found in recent amphibians only as scattered plates in the skin of the backs of a few exotic toads and as rows of scales in the cutaneous rings of cæcilians (fig. 36). These, which are roughly circular in outline, bear small plates (squamulæ) on the anterior (outer) surface, these being roughly arranged in circles as if representing stages of growth. Some fossil stegocephalans had an armor on the ventral surface while others had one protecting the whole body. The elements of the ventral exoskeleton—sometimes scales or plates, sometimes long bars—are arranged in oblique rows (fig. 35) and possibly represent the source of the gastralialia (p. 46) found in several reptiles. Apparently certain of these ventral elements were modified into comb-like organs which have been interpreted as sexual in function. Episternum and clavicle were possibly dermal in the stegocephals; they are described in connexion with the sternum (p. 66).

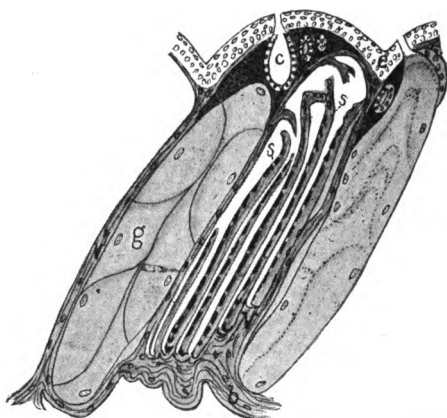


FIG. 36.—Section of a body ring of the Cæcilian *Epicrion* showing the scales, after the Sarasins. *b*, basal layer of the corium; *c*, gland in the corium; *e*, epidermis; *g*, giant gland; *s*, scales, the black spots indicating the squamulæ; *v*, vertical partitions of the corium connecting the basal and superficial layers; the head toward the left.

REPTILES.—Among living reptiles the dermal skeleton is best developed in the turtles, though here it is closely associated with the endoskeleton. In these animals the body is enclosed in a box, composed of dermal plates which in part fuse with the endoskeleton. This box consists of a dorsal **carapace** and a ventral **plastron** united at the sides to a varying extent, and each consisting of a number of elements. In the middle line of the carapace is a series of **neural plates** (fused below with the vertebræ); the margin of the carapace consists of **marginal plates**, and between marginals and neurals are long **costal plates** fused to the underlying ribs. The plastron (fig. 38) usually consists of nine wholly dermal plates, their names shown in the figure. The three hinder pairs are regarded as homologous with the gastralialia of other reptiles, the anterior pair as the clavicles, while the unpaired entoplastron is supposed to represent the episternum of other tetrapoda.

Some of the extinct crocodilia were armored with closely applied scales, and these are retained in a reduced condition in the living species. These reptiles

also have well-developed **gastralia**. These are rods of dermal bone in the ventral body wall between the true ribs and the pelvis, which so closely resemble the true ribs that they have been called 'abdominal ribs.' They do not meet in the middle line; each, except the first, consists of two parts and the pairs corre-

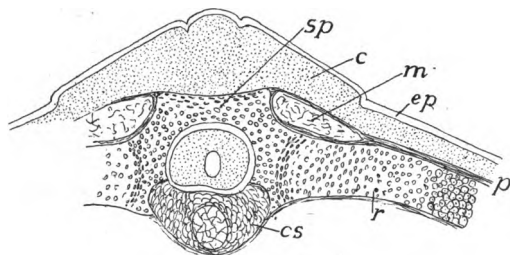


FIG. 37.—Section through developing vertebra, rib and exoskeleton of *Chelone imbricata*, after Götte. *c*, corium in which the dermal plates are developed; *cs*, primitive vertebral body, *ep*, epidermis; *m*, external oblique muscle; *p*, perichondrium; *r*, rib; *sp*, spinous process.

spond to the somites in number. In *Sphenodon* (fig. 37) the gastralia are more numerous than the somites.

In a few lizards there are dermal scales, while the extinct stegosaurs had dermal ossicles, sometimes of great size (plates a yard across, spines half a yard long) in the dorsal region.

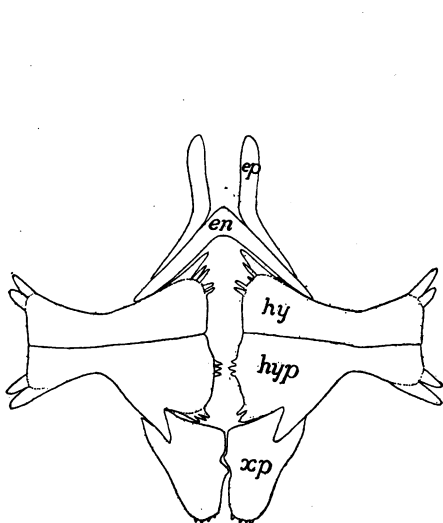


FIG. 38.—Plastron of *Trionyx*. *en*, entoplastron; *ep*, epiplastron; *hyp*, hypoplastron; *hy*, hyoplastron; *xp*, xiphiplastron.




FIG. 39.—Ventral ends of ribs (*r*) and gastralia (*g*) of *Sphenodon*.

BIRDS.—All recent birds lack dermal ossifications, but *Archæopteryx* had gastralia.

MAMMALS rarely have dermal bones. They are known in the extinct zeuglo-

dont whales and in several fossil edentates, but in the living species they occur only in the back and dorsal fins of some cetacea and in the armadillos, where they form a complete armor above, the plates arranged in transverse rows, some of which are movable on each other. In the extinct glyptodons they formed an inflexible case. It is uncertain whether these are a new acquisition in the edentates or have been inherited from non-mammalian ancestors.

THE ENDOSKELETON

The endoskeleton may pass through three stages in its development, including the membranous stage (p. 41). From this it may pass through a cartilage stage before becoming bone, or it may in part develop directly into bone from membrane, or, lastly, it may never pass beyond the cartilage stage. Thus only the membranous stage is constant. These differences in development are of great importance in tracing homologies between bones in different groups, but the distinction between bones developing directly from membrane (**membrane bones**) and those passing through a cartilage stage (**cartilage bones**) can be recognized only by following the ontogeny of the element in question.

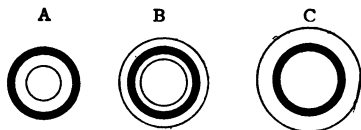


FIG. 40.—Diagram of growth of bone. *A*, from an animal recently fed with madder causing a layer of bone (black) colored by the dye; *B*, later, no madder fed for some time, a deposit of colorless bone on outside of colored layer, internal layer thinner; *C*, still later, outer layer thicker, inner layer absorbed.

As stated above, there is much evidence to show that the membrane bones are dermal bones which have sunk to a deeper position and have become secondarily associated with the endoskeleton. This is especially evident in the skulls of some of the lower ganoids. Ossification of cartilage takes place in two ways. In *ectochondrostosis* the deposit of lime salts begins on the deeper surface of the perichondrium and gradually invades the cartilage. In *entochondrostosis* the cartilage becomes altered in the interior, some of the cells becoming modified into osteoblasts, and from these as centres of ossification, the process of bone formation extends in all directions. In *ectochondrostosis* at least, the centres of ossification may have been derived, phylogenetically, from elements of the dermal skeleton.

In ossification the bone is developed in layers, between which the osteoblasts are arranged. In the elasmobranchs the skeleton is frequently strengthened by deposits of lime, but this **calcified cartilage** differs from bone in that the deposits of lime take the form of polygonal plates and there are no lacunæ.

Many bones increase in length by the addition of **epiphyses** at the ends.

These are separate ossifications which only unite with the main bone at the time the adult condition is reached. The increase in diameter has some interesting features. In animals fed with madder, the bone formed during the feeding is colored. In this way it is found that the new bone (fig. 40, *A*) is laid down on the outside of the other, and that with growth (*B* and *C*); the 'marrow cavity' on the inside is increased in size by the resorption of the bone already formed.

For convenience of treatment the endoskeleton is divided into axial and appendicular portions, the axial consisting of the vertebral column (backbone) and the skull, together with the ribs and sternum which are closely associated with the vertebræ. The appendicular skeleton includes the framework of the limbs and fins and the girdles to which they may be attached.

AXIAL SKELETON

Both the skull and the vertebral column surround and protect the central nervous system (brain and spinal cord) and in this way the skull is an enlarged and specialized portion of a continuous axis, but it is not possible to carry the comparisons into details. The idea of Oken and Owen that the skull is a complex of three or four vertebræ has long been overthrown. The skull differs markedly from the vertebral column in the presence of numerous membrane bones, while in the more primitive vertebrates and in the early stages of all, the Okenian vertebræ are entirely lacking.

Vertebral Column

The vertebral column ('backbone') is the longitudinal skeletal axis of the body behind the head. It lies dorsal to the alimentary canal and most of it is ventral to the spinal cord, only the neural arches arising above the central nervous system. In all vertebrates, except some of the cyclostomes, it is markedly metameric, being composed of a series of elements—the **vertebræ**—which are always preformed in cartilage, but which, in the higher groups, are ossified later.

The most typical vertebræ are found in the tails of the lower vertebrates (fig. 41, *A*). Each vertebra consists of several portions or regions. Between the spinal cord and the caudal blood-vessels, and surrounding the notochord is the **body** or **centrum**, the successive vertebræ of the column articulating by the anterior and posterior faces of the centra. From the dorsal side of each centrum a **neural arch** arises, enclosing the spinal cord in its opening, the

vertebral canal. Each arch is composed of a pair of **neural plates** (**neurapophyses**) which meet above the cord and are continued dorsally as the **neural spine**. A similar **hæmal arch** extends from the ventral side of the centrum around the blood-vessels of the tail. This consists of similar paired plates (**hæmapophyses**) and a **hæmal spine**. In the trunk region centrum and neural arch are similar, but the hæmal arch is either incomplete (surrounding the various viscera in fishes) or is entirely absent.

In the higher vertebrates other parts are frequently added to those just mentioned (fig. 42). Most common of these are **articular processes** (**zygapophyses**) on the anterior and posterior sides of the

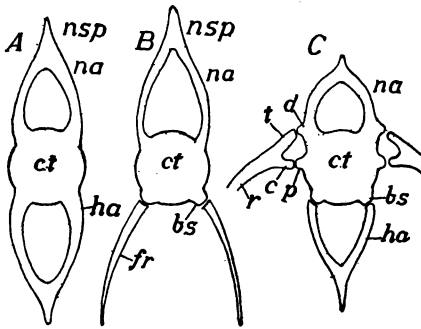


FIG. 41.

FIG. 41.—Diagrams of (A and B) fish vertebrae and (C) vertebra from higher groups. *b*, basal stumps; *c*, capitular head of rib; *ct*, centrum; *fr*, fish rib; *ha*, hæmal arch; *na*, neural arch; *p*, parapophysis; *r*, rib; *t*, tubercular head.

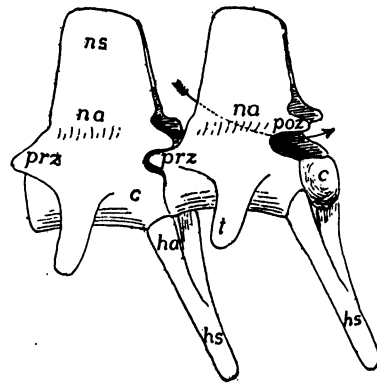


FIG. 42.

FIG. 42.—Two caudal vertebrae of alligator. *c*, centrum; *ha*, hæmapophysis; *hs*, hæmal spine; *na*, neurapophysis; *ns*, neural spine; *pos*, *prz*, post- and prezygapophyses; *t*, transverse process. The arrow passes through the neural arch.

neurapophyses, which aid in articulating more firmly the several vertebrae. In most vertebrates higher than fishes there are also **transverse processes** which extend laterally in the planes of the partitions (**myosepta**) between the muscles. There may be two of these transverse processes on either side of a vertebra, a more dorsal **diapophysis** (fig. 41, C) arising from the neural arch, and a more ventral **parapophysis** extending from the side of the centrum. The true ribs, to be described later, articulate with the ends of these processes.

The ends of the centra by which the successive vertebrae are articulated show, in different vertebrates, four distinct conditions (fig. 43). As in most fishes, they may be hollow at both ends (**amphi-**

coelous). They may bear a ball at one end and a corresponding socket at the other; the socket may be in front (**procoelous**) or behind (**opisthocœlous**). In the birds a saddle-shaped articulation

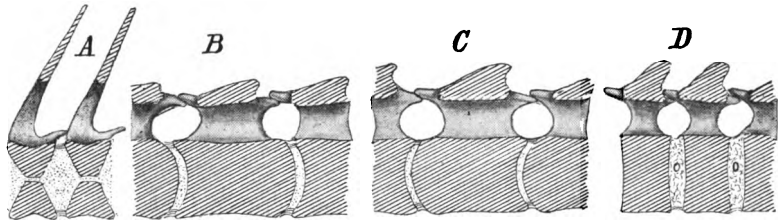


FIG. 43.—Diagrammatic sagittal sections of (A) amphicoelous; (B), procoelous; (C), opisthocœlous; and (D), amphiplatyan vertebræ; the head supposed to be at the left.

occurs (fig. 55), while in mammals the ends of the centra are usually flat (**amphiplatyan**), though in the necks of ungulates the vertebræ are **opisthocœlous**.

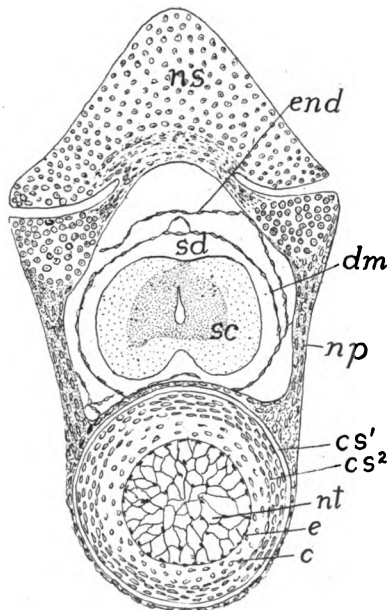


FIG. 44.—Section of developing vertebra of 45 mm. *Amblystoma*. *c*, cartilage of intercentrum; *cs*¹, outer chorda sheath; *cs*², inner chorda sheath; *dm*, dura mater; *e*, epithelioid layer of notochord (elastica interna); *end*, endorhachis, torn from wall of vertebral canal; *np*, neurapophysis (ossified); *ns*, neural spine of preceding vertebra; *nt*, notochord; *sc*, spinal cord; *sd*, sub-dural space.

Comparative anatomy, embryology and paleontology all agree in showing that the vertebral formation began with the arches and extended from these to the centra. In what must be regarded as the

most primitive condition arches alone occur, and these may even ossify without any appearance of distinct centra.

The vertebræ (and the basal part of the skull) are developed around the notochord. This is a cylindrical rod of cells, arising from the entoderm,¹ and extending in the middle line of the body, between the central nervous system and the alimentary canal, from the infundibulum (see brain) to the posterior end of the body. In its early stages it shows no signs of metamerism. Soon the cells of which it is composed become vacuolated, and the nuclei and most of the protoplasm migrate to the surface of the rod where they appear like

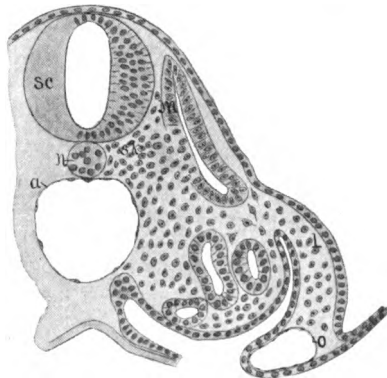


FIG. 45.—Section of embryo lizard (*Lacerta muralis*) with twenty-eight somites, the section passing through the tenth somite. To show the proliferation of mesenchyme from the splanchnic layer of the myotome. *a*, aorta; *l*, limb-bud; *m*, part of myotome to form muscle; *n*, notochord; *o*, omphalomesenteric vein; *sc*, spinal cord; *sk*, sclerotomic part of mesenchyme.

an epithelium, which, together with its basal (external) membrane is called the **elastica interna** or **epitheliomorph layer** (fig. 44, *e*).

This internal elastic layer now secretes a structureless envelope, the **notochordal sheath**, which encloses the whole cord, its outer layer, the **elastica externa** (fig. 44, *cs*¹) being somewhat sharply marked off from the rest. This condition of the sheath persists throughout life in the cyclostomes and a few other forms, but is transitory in all other vertebrates.

The skeleton-forming (skeletogenous) tissue is derived from the sclerotomes (p. 20). Its history in outline is as follows: Each epimeral and mesomerall somite buds cells from its medial and splanchnic surface (fig. 45); these cells form the sclerotomes, which, since they arise from metameric structures are at first also metameric. But

¹ For the entodermal origin of the notochord see p. 13.

each sclerotome is also divided by a vertical incision into an anterior or cranial and a posterior or caudal half (fig. 46), a point of great importance in explaining certain vertebral peculiarities.

The sclerotome halves gradually extend medially to the axial structures and their cells become most abundant in the triangular grooves—two on either side—between the spinal cord and the notochord above, and the notochord and the blood-vessels below. From these tracts the cells extend dorsally, gradually enclosing the spinal cord, while ventrally the blood-vessels are similarly enclosed. With the formation of cartilage these collections of cells develop the neural and hæmal arches, and, since there are two sclerotome halves to a somite, there may occur, as in the adult lamprey, two arches to each segment of the body. In the cyclostomes the verte-

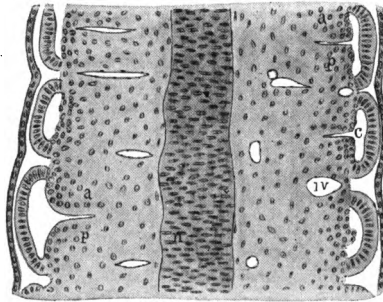


FIG. 46.—Horizontal section through embryo snake (*Tropidonotus*) at the level of the notochord and the lower part of the myotomes, after Corning. Cells are shown budding from the splanchnic wall of each myotome, and in three places the resulting sclerotomes are plainly divided into anterior (*a*) and posterior; (*p*) sclerotome halves; *c*, myocœle; *iv*, intersegmental blood-vessels; *n*, notochord. The section passes through the middle of the myotomes, *cf*, fig. 45.

bral development goes no farther than this, no centra being formed (fig. 82). The vertebral column thus consists in these animals (and the same holds true for many fossil ganoids) of a series of arches resting on an unchondrified notochordal sheath. In the myxinoids the cranial and caudal arches are about equal in size, but in most vertebrates the caudal are the larger, the cranial often being entirely lost in development.

In most gnathostome vertebrates the centra are formed by extensions from the bases of the neural and hæmal arches, but in two different ways. In the one the skeletogenous cells extend from the bases of the arches around on the outside of the *elastica externa* and later chondrify, the notochordal sheath in this case being unmodified, sometimes throughout life. In the other case cells from the bases

of the arches penetrate the external elastic layer and migrate into the sheath, the tissue thus formed being later converted into cartilage (fig. 44).

As is the case with the arches, there may be a duplicity of centra in the vertebrates, a condition (**diplospondyly**) well known, for instance, in the tail of *Amia*. In most vertebrates, however, the two half centra fuse to form a single (true) centrum. This fusion may take place in two ways. In some regions of a few fishes the cranial and caudal half centra of the same (myotomic) somite unite so that the resulting centrum coincides in position with the myotome. But in the great majority of vertebrates the caudal half centrum of one somite fuses with the cranial half of the succeeding somite to form the definitive centrum of the adult. In this way there is brought about an alternation of myotomes (and the resulting muscles) and vertebræ, a condition more advantageous for the interaction of skele-

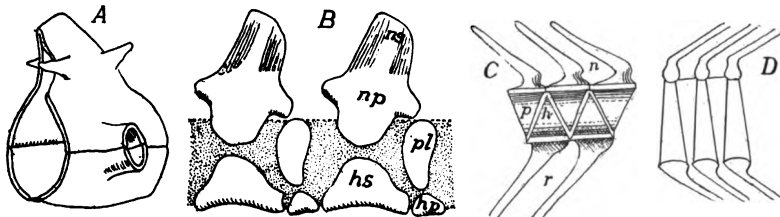


FIG. 47.—Stegocephalan vertebræ, after Zittel and Woodward. *A*, phyllospondylos; *B*, rachitinous of *Chelydrosaurus*; *C*, *Collopterus*; *D*, embolomerous of *Eurycormus*, *hs*, hypocentrum arcuale; *hp*, hypocentrum pleurale; *np*, neurapophysis; *ns*, neural spine; *h*, hypocentrum; *p*, pleurocentrum.

ton and muscles, for where vertebræ and muscles are coextensive, flexure of the body to right or left cannot be so well effected.

In the higher vertebrates all traces of this double origin of the vertebræ are lost in the adult. But in many of the ichthyopsida different conditions occur. In the tail of *Amia* referred to above and in several extinct ganoids and stegocephals there are apparently two centra and but a single arch for each muscle segment (fig. 47, *D*). Of these the incomplete element is usually called the intercentrum. In other stegocephals more complex conditions occur (fig. 47, *B*). Here each vertebra consists of several parts to which the names in the legend of the cut have been applied, and this type of vertebra has been called rhachitinous or temnospondylous. No certainty has been reached as to the homologies between these and other vertebræ, but it appears probable that the parts labelled *hs* and *np* represent the bases of the hæmal and neural portions of the caudal half-scle-

rotome, while those with the letters *hp* and *pl* are the corresponding cranial elements of the succeeding body somite. The relations of the parts in the phyllospondylous vertebra (fig. 47, *A*) are even more uncertain, since here the bone (alone preserved) was apparently, a coating over the cartilage.

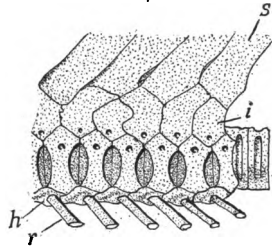


FIG. 48.—Trunk vertebræ of *Rhynchobatus*, after Duméril. *h*, hæmal process; *i*, intercalary plate; *n*, neural process; *r*, rib; *s*, spinous process.

In the formation of the arches derivatives of both caudal and cranial half sclerotomes may persist (fig. 48). The two may be dis-

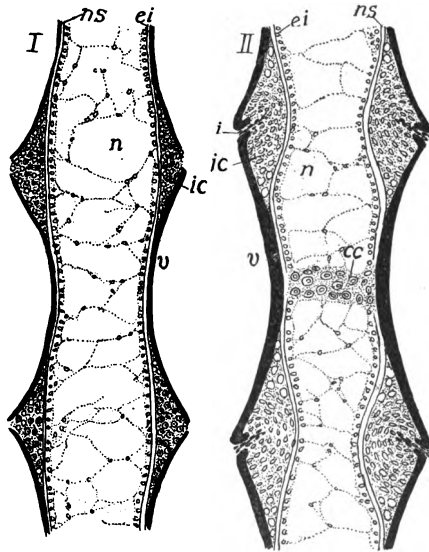


FIG. 49.—Earlier and later stages of development of a vertebra of *Amblystoma*. *cc*, cartilage in centre of vertebra; *ei*, elastica interna; *i*, incisure cutting through *ic*, intercentral cartilage; *n*, notochord; *ns*, notochordal sheath; *v*, vertebra (bone) black.

tinguished by their relation to the nerve roots. Thus the ventral root usually penetrates the caudal plate (in the figure fused with the centrum), while the dorsal root passes between cranial and caudal

or penetrates the former. So it follows that the plates labelled *i* (intercalaria of most authors) are derived from the cranial half sclerotomes.

The vertebræ are outlined at an early stage of the embryo and their number is not subsequently increased. Consequently increase in length of the vertebral column can occur only by growth of the vertebræ themselves. When first formed each centrum encircles the notochord and prevents its increase in diameter at this point, while between the centra it can expand. As a result the notochord soon resembles a string of beads (is moniliform) with intervertebral enlargements. Then, as additions are made to the centra to increase their length, the new parts must form around the intervertebral enlargements and in this way the ends of the centra become cup-shaped and the amphicœlous condition (fig. 49, *I*) is produced. In some urodeles this stage is followed by the deposition of cartilage in the cups (fig. 49, *II*) producing intervertebral constrictions of the cord. As this progresses absorption of the cartilage begins between the ends of the vertebræ (*ic*) and continues in such a way that the result is a ball of cartilage attached to the hinder vertebra and a corresponding cup in the one in front; in other words, an opisthocœlous condition. The procœlous condition (fig. 43, *B*) is the result of a similar process, except that the socket is in front, the ball behind.

Regions of Vertebral Column.—Several regions may be differentiated in the vertebral column, these being the most numerous in the higher groups of vertebrates. These are (1) the cervical, in the neck, with great reduction or even absence of ribs; (2) the thoracic, following the cervical, with distinct ribs; (3) lumbar, without ribs; (4) sacral, including one or more vertebræ with which the pelvis is connected; (5) caudal, the tail, behind the sacrum. Sometimes the ribs extend back to the sacrum so that thoracic and lumbar cannot be distinguished, all being then grouped as dorsal. Then in the fishes and some higher vertebrates (snakes, whales, etc.) sacral vertebræ are not differentiated, and in the fishes there is no line between cervicals and dorsals, so that only trunk or abdominal, and caudal regions can be distinguished, the line being drawn (fishes) at the point where hæmal arches are transformed into so-called ribs (see p. 60).

One or two of the anterior vertebræ are modified in the higher (tetrapodous) vertebrates and have received names. The first,

which immediately adjoins the skull, is the **atlas** (fig. 50). It bears on its anterior face an articular surface which receives the one or two condyles of the cranium. In the amniotes the second vertebra, the **axis** or **epistropheus** is also specialized. On the anterior face of its centrum is a pivot (the **dens** or **odontoid process**) on which the

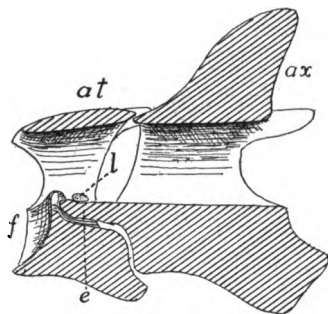


FIG. 50.—Section through atlas (*at*) and axis (*ax*) of fowl, cut surfaces lined, *e*, epistropheus; *f*, facet for articulation with skull; *l*, transverse ligament.

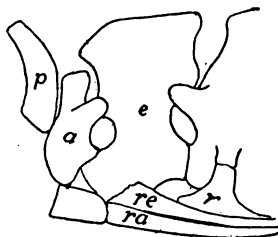


FIG. 51.—Proatlas, atlas and axis of alligator. *a*, atlas; *e*, epistropheus (axis); *p*, proatlas; *r*, rib of third vertebra; *ra*, *re*, ribs of atlas and epistropheus.

atlas turns. Development shows that this dens is the centrum of the atlas which has separated from its own vertebra and has fused to that of the axis. The dens is held in position by a transverse ligament on the inside of the atlas (fig. 50).

In a few reptiles and possibly some mammals a so-called **proatlas** occurs as a plate or pair of plates (fig. 51) of bone between the atlas and the skull, in the position of a neural arch. It is not certain whether this is the remains of a vertebra which once occupied this position, or is a new formation. Nor has it been settled whether the atlas of the amphibians is homologous with that of mammals.

In cyclostomes, fishes and aquatic urodeles the posterior end of the vertebral column is involved in the formation of the caudal fin, which presents three modifications (fig. 52). The most primitive is the **diphycercal** tail in which the vertebral column runs straight to the end of the body, the fin being developed symmetrically above and below it (fig. 52, *B*). This is found in the young of all fishes and in the adult cyclostomes, dipnoans, many crossopterygians and urodeles. In the **heterocercal** tail (*C*), which occurs in elasmobranchs and ganoids, the axis bends abruptly upward near the tip, and while retaining the caudal fin of the diphycercal stage, has a second, smaller lobe developed below, giving the whole an unsym-

metrical appearance. In the **homocercal tail**, which occurs in *Amia* and all teleosts since the cretaceous, there is the same upward bend to the vertebral column (fig. 52, *A*), but symmetry is restored externally by the reduction of the neural arches and the development and fusion of the hæmals into larger plates (**hypurals**), while the lower lobe of the tail grows out to equal the other (fig. 52, *D*).

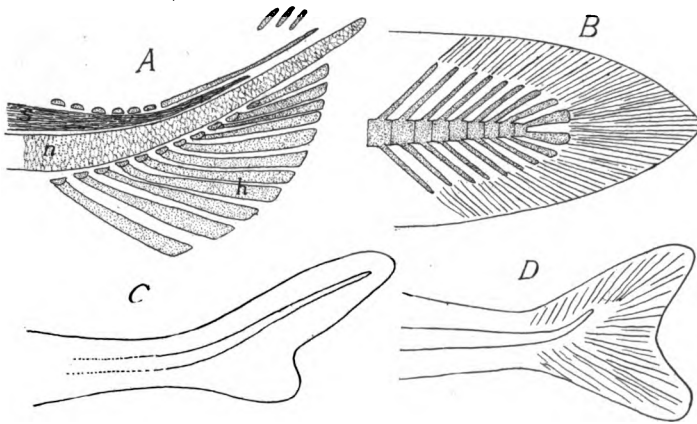


FIG. 52.—Tails of fishes. *A*, young *Amia*, skeleton; *B*, diphycercal; *C*, heterocerca; *D*, homocercal; *h*, hypurals; *n*, notochord; *s*, spinal cord

CYCLOSTOMES have a persistent notochord, which increases in size with the growth of the animal, and lacks constrictions, since no centra are developed.

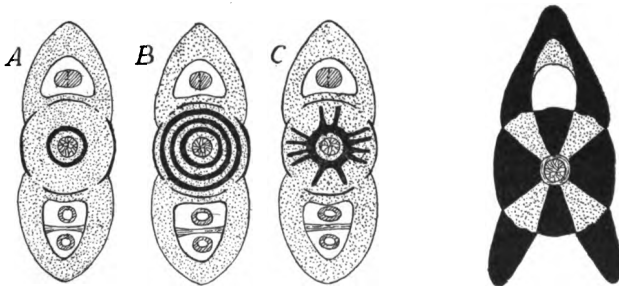


FIG. 53.

FIG. 54.

FIG. 53.—Diagrammatic sections of elasmobranch vertebrae. *A*, *B*, cyclospondylous; *C*, asterspondylous.

FIG. 54.—Cross-section of teleost vertebra; bone, black; cartilage, dotted.

In the myxinoids there are cartilaginous neurapophyses and intercalaria developed in the caudal region; in the lampreys they occur in the trunk as well.

FISHES.—In all fishes only two vertebral regions—trunk and tail—are differentiated. In the elasmobranches the typical vertebrae are developed in cartilage, with intercalaria in connexion with the arches. Usually the centra

undergo more or less calcification (p. 1), the lime being either deposited in concentric rings around the notochord (*cyclospondylous* vertebræ) or in radiating plates (*asterospondylous*, fig. 53). In the trunk region each centrum often bears a pair of transverse processes with short ribs at their extremities. In a few forms (skates, etc.) diplo- or polyspondyly (p. 53) occurs in the tail, and in the holocephali the centra are replaced by numerous rings of cartilage. In skates and in *Chimæra* there is a true joint between the skull and the column, but in the sharks the anterior vertebræ are fused together and to the skull.

The ganoids vary greatly in vertebral characters, some of the Chondrostei having only cartilage and some of the fossil forms lacked centra. On the other hand, nearly the whole vertebra is ossified in *Amia* and *Lepidosteus*, the latter having opisthocœle vertebræ, a condition not reappearing until the amphibians, as all other fishes in which centra are developed have amphicœlous vertebræ.

As the name implies, ossification of vertebræ and other parts is common in teleosts. The arches are almost always ossified, while the centra may be, or those parts directly connected with the arches may remain cartilaginous while the rest ossifies (fig. 54), so that the section presents a radiate figure as in the asterospondylous sharks. Some teleosts have zygapophyses and a few genera have transverse processes on some of the vertebræ.

The dipnoans, so far as ossification of the vertebræ is concerned, are on a par with the cartilaginous ganoids. There are no centra and the notochord grows throughout life.

AMPHIBIA, except the legless forms (gymnophiona, and aistopoda of the stegocephals), have caudal, sacral, and trunk regions, and a single cervical vertebra, the sacrals being single except in a family of extinct anurans. Zygapophyses and both kinds of transverse processes may be present.

The stegocephals had the greatest range of vertebral structure, rhachitinous, embolomerous, and amphicœlous types occurring, the first two even in the same individual. Phyllospondylous vertebræ (fig. 47) only in the fossil Branchiosauridæ.

The cæcilians have a very large number (up to 275) of amphicœlous vertebræ in correlation with the snake-like body form. The perennibranchs, derotremes and many salamandrina are amphicœlous; the rest of the urodeles are opisthocœlous.

The anura, as a rule, have procelous vertebræ, but a few genera have them opisthocœle. All recent species have eight presacral vertebræ, but there were nine in the tertiary forms. A striking feature is the fusion, in the adult, of all of the caudal vertebræ into the well-known rod, the *coccyx* or *urostyle*.

REPTILES always have the vertebræ ossified, although remnants of the notochord may persist in the centra, of which all types, amphi-, pro-, opisthocœlous and flat occur in the group. In lizards, snakes and dinosaurs the articulation between the successive vertebræ is strengthened by *zygantra* and *zygosphenes*, a cavity on one vertebra into which a projection from the next fits. In the existing species there are never more than two sacral vertebræ, but the pterosaurs had from three to seven, while in the dinosaurs there might be ten, all being co-ossified when there were more than three.

Little is known of the theriomorph vertebræ, except that some species had

persistent notochords, others amphicœlous centra. In the plesiosaurs they were flat, while in the turtles the dorsals are fused and the neural spines are united with the neural plates (p. 45). The other centra vary. Those of the rhynchocephals and most dinosaurs are flat, while snakes and lizards (except the geckos) have them procœlous. In the earliest crocodiles they were amphicœlous, while later they are procœlous or flat, and in the pterodactyls they are procœlous in front, amphicœlous in the tail.

BIRDS usually have saddle-shaped ends to the centra (the atlas procœlous). Several of the dorsals are usually fused for strength, but the first presacral is free. A characteristic feature is the **synsacrum** (fig. 56), foreshadowed in the dinosaurs. As the bird stands on two feet and holds the body obliquely, several of the dorsal and caudal vertebræ (up to 20) have fused with the true sacrals into a common synsacral mass, a large proportion also uniting with the pelvis, thus give a

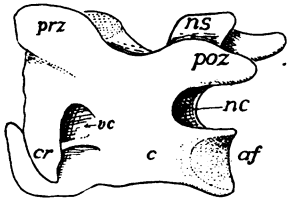


FIG. 55.

FIG. 55.—Cervical vertebra of a bird showing the saddle-shaped articular surface (*af*) on the centrum, *c*; *cr*, cervical rib; *nc*, neural canal; *ns*, neural spine; *poz*, *prz*, post- and prezygapophyses.

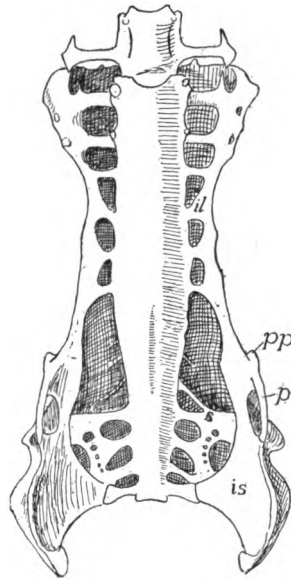


FIG. 56.

FIG. 56.—Ventral view of synsacrum and pelvis of hawk (*Buteo*). *il*, ilium; *is*, ischium; *p*, pubis; *pp*, pectineal process; *s*, sacral ribs.

firmer framework for the attachment of the muscles of the legs. The true sacrals (three in ostriches, two elsewhere) lie just behind the pits occupied by the kidneys and may be recognized by their lower articulation with the pelvis. A few of the caudals behind the synsacrum are free, as all were in *Archæopteryx*, but the others in recent birds are united into an upturned bone, the **pygostyle**.

MAMMALS, except whales where the sacrum is lacking, have all five vertebral regions differentiated. With four exceptions the cervicals are seven in number (*Manatus australis* and *Cholæpus hoffmanni*, six; *Bradypus torquatus*, eight; *B. tridactylus*, nine). The dorsals (thoracics plus lumbaris) vary between fourteen in armadillos and thirty in *Hyrax*, but usually are nineteen or twenty; increase in the number of thoracics usually being at the expense of the lumbaris. There are primitively two sacrals, but others may unite with these until they amount to nine or ten in some edentates. Usually the centra are amphiplatyan, but in the cervicals of ungulates opisthocœle vertebræ are common. It is to be

noted that the 'transverse processes' of the cervical vertebræ are, as in birds, composed in part of reduced ribs, as will be shown below.

Ribs

Two different structures are included under the common name of rib or *costa*, both connected at one end with a vertebra, the other supporting the body walls around the viscera. In following forward the hæmal arches in the skeleton of a bony fish (fig. 41, *A*, *B*) it is seen that when the body cavity is reached the arch becomes incomplete below, the two hæmapophyses separating and coming to lie just beneath the peritoneum in the walls of the cœlom. Above, each is either united directly to the centrum or is jointed to a small process of it. More careful study shows that this fish rib (hæma-

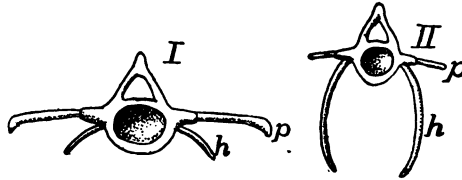


FIG. 57.—Vertebræ and ribs of (*I*) anterior and (*II*) posterior trunk region of *Polypterus*, after Gegenbaur. *p*, pleural rib; *h*, hæmapophysial rib.

pophysial rib) lies in the intersection of a myoseptum with the median partition of the skeletogenous tissue (p. 41) and is medial to the hypaxial muscles. In the higher vertebrates the rib is formed in the intersection of the myosepta with the horizontal plate, and thus is lateral to the hypaxial muscles and between them and the epaxial series. This is the true or pleural rib. Any vertebra may bear ribs of either kind (including hæmal arches) and the two kinds frequently coexist on the same vertebra in the trunk of salmonids, clupeids and *Polypterus* (fig. 57), and in the caudal region of urodeles and some reptiles. Their possible occurrence in all parts of the body is explained by the existence of the myosepta and other skeletogenous structures in all regions.

Another view regards hæmal and pleural ribs as homologous structures, but this does not commend itself. It would explain the coexistence of the two kinds of ribs in the same individual by supposing that the hæmal rib had shifted dorsally and that another structure arising from the stump or from a process on the medial side of the hæmapophysis had developed into the lower rib (fig. 58).

The hæmaphophysal ribs end freely below, never being connected with a sternum. In some aberrant fishes they are lacking, while in the ostariophysal they play a part in the 'Weberian apparatus' connecting the swim bladder with the ear (p. 269). The teleosts have, in addition, numerous rib-like structures which are not preformed in cartilage (epineurals, epiplurals) scattered among the muscles; these are formed in the epaxial or hypaxial myosepta or in the horizontal partition.

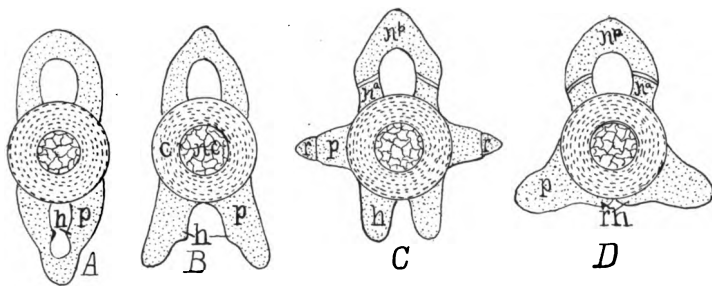


FIG. 58.—Diagrams of vertebræ of *Lamargus*, based on Schauinsland, to illustrate his view of the homologies of the two types of ribs. *A*, mid caudal; *B*, base of tail; *C*, middle of trunk; *D*, cervical region. *c*, centrum; *h*, hæmal process; *ca*, cranial neural arch; *nc*, notochord; *np*, caudal neural arch; *p*, hæmal arch or hæmapophysis; *r*, rib.

Typically, the true rib (it is not certain whether this is the primitive form) has two heads for articulation with the vertebra, a **capitular head** connecting with the parapophysis, a **tubercular head** joining the diapophysis. Between the two heads and the centrum is a space, the **vertebrararterial canal**, through which the

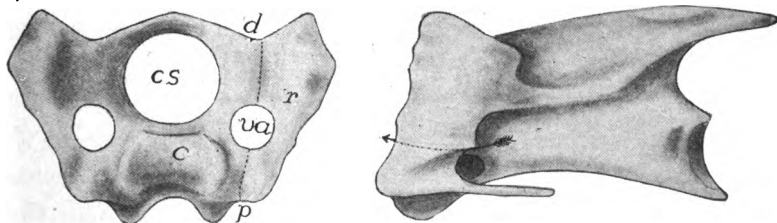


FIG. 59.—Front and side views of cervical vertebra of fowl, showing the cervical rib. *c*, centrum; *cs*, spinal canal; *d*, diapophysis; *p*, parapophysis; *r*, rib; *va*, vertebrararterial canal; the arrow in the side view passes through the canal.

vertebral artery passes (fig. 41, *C*). The true ribs, which are preformed in cartilage, have various extents in the different regions of the body. In the thoracic region, where they have the greatest extension, the ribs have to allow for changes in size of the contained cavity, and hence parts of them are frequently left unossified, or at least they are jointed, the two parts being called **vertebral** and **sternal ribs** (fig. 60, *vr*, *sr*).

In the cervical region the true ribs are usually greatly reduced, and are lacking in the turtles. In many reptiles they clearly show their nature, being short, bicipital and with their heads articulated to dia- and parapophyses (fig. 51). In the birds they may be recognized (fig. 59), their distal ends being bent inward to protect the carotid arteries. In the mammals they form the distal part of the 'transverse process' of human anatomy, the vertebral canal and the development revealing their true nature.

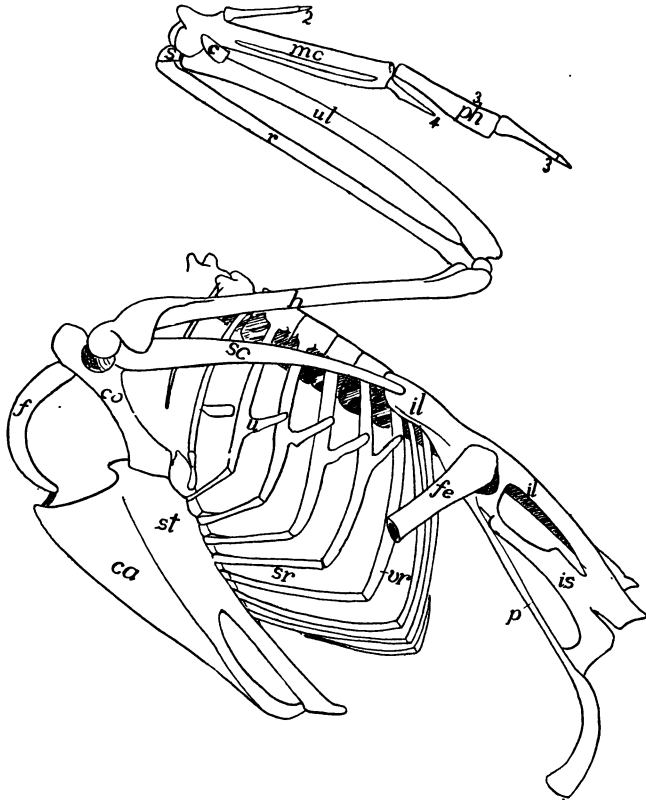


FIG. 60.—Skeleton of trunk of common goose, *Anser domesticus*. *c*, cuneiform; *ca*, carina; *co*, coracoid; *f*, furcula (clavicle); *fe*, femur; *h*, humerus; *il*, ilium; *is*, ischium; *mc*, metacarpals; *p*, pubis; *ph*, phalanges; *r*, radius; *s*, scaphoid; *sc*, scapula; *sr*, sternal rib; *st*, sternum; *u*, uncinat process; *ul*, ulna; *vr*, vertebral rib; 2, 3, 4, digits.

The dorsal ribs are very short in amphibians, never extending far from the backbone. They are bicipital in most forms, except the anura where they form small projections on the ends of the transverse processes. In the amphibia the vertebral artery is ventral to the parapophysis. In all vertebrates with a sternum, the amphibia excepted, at least a part of the dorsal ribs reach that struc-

ture, encircling the viscera like the hoops of a barrel. Those ribs which do not reach the sternum are called **false ribs**. In most reptiles and some birds most of the thoracic ribs bear an uncinatè process directed upward and backward (fig. 60), overlapping the rib behind and strengthening the thorax. In the chelonia the ribs are confined to the dorsal side of the body and are fused to the costal plates (dermal skeleton) to form the carapace. Single- and double-headed ribs often occur in the same individual of various groups, and in the mammals the capitular head, instead of articulating with a distinct parapophysis, may rest in a socket formed by two successive vertebræ.

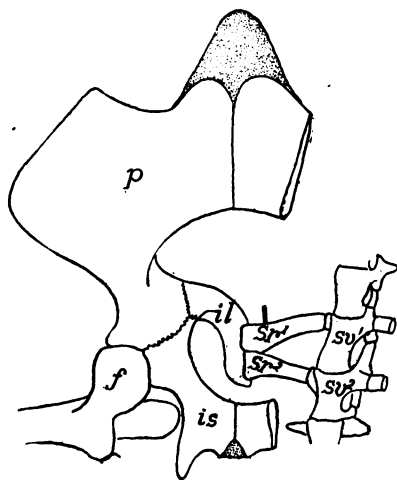


FIG. 61.—Sacral vertebræ, ribs and pelvis of *Trionyx*, obliquely from below. *f*, head and trochanter of femur; *il*, ilium; *is*, ischium; *p*, pubis; *sr*, sacral ribs; *sv*, sacral vertebræ.

The pelvis is never directly united to the sacrum, but sacral ribs intervene. These are distinct in the reptiles (fig. 61), but are fused to the transverse processes in other groups.

The Sternum (Breastbone)

The sternum includes the skeletal parts on the ventral side of the body, which are closely connected with the shoulder girdle and, except in the amphibia, with the ribs. The fact that it occurs only in vertebrates with legs (it is lacking in snakes and cæcilians) shows that it has arisen in adaptation to terrestrial locomotion. In man it consists of three parts, a **manubrium** above, a middle piece (**gladiolus**), and a **xiphoid (ensiform) process** below, and these terms have been carried into other groups.

In development the sternum arises in mammals by the formation of a longitudinal bar of cartilage in the linea alba on either side, ventral (medial) to the ends of the ribs, eventually connecting them together (fig. 62). With continued growth these bars of the two sides meet and fuse in the median line, forming a median plate, the sternum. Later this separates from the ribs, and

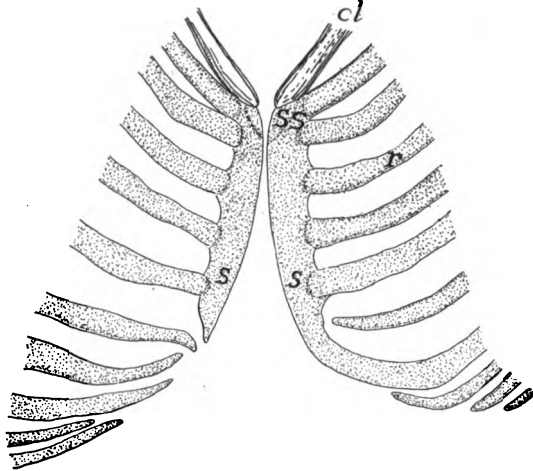


FIG. 62.—Development of sternum in 30 mm. human embryo, after Ruge. *cl*, lower end of clavicle; *r*, ribs; *s*, two halves of sternum; *ss*, suprasternalia.

with the appearance of bone, becomes a series of separate elements, the sternebrae (fig. 65), alternating with the ribs. The three parts of the human sternum arise by the fusion of sternebrae.

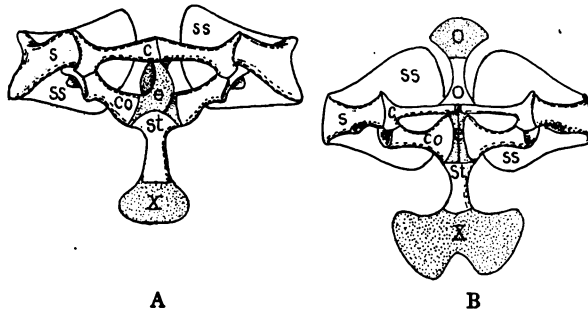


FIG. 63.—Sterna and shoulder girdles of (A) *Bufo*, and (B) *Rana*, cartilage dotted except in the suprascapula. *c*, clavicle; *co*, coracoid; *e*, episternum; *o*, omosternum; *s*, scapula; *ss*, suprascapula; *x*, xiphisternum.

In the amphibia the short ribs never extend to the sternum, but skeletal parts occur near the mid-ventral line in a few forms, which may be ventral ribs as they participate in the formation of the sternum. Nothing is known of a true sternum in the stegocephals.

In the urodeles it is a short cartilaginous plate, lying mostly behind the girdle, with its sides grooved to receive the medial ends of the coracoids. In the toads (fig. 63, *A*) and their allies (arcifera) it has hardly passed beyond the urodele condition, but the hinder angles are produced into long processes. In the frogs (firmisternia) it consists of a slender thread between the medial ends of the girdles (epicoracoids), but in front it expands into an **omosternum**, ossified behind; while behind the girdle it forms a broad **xiphisternum**, the anterior part of which is bone (fig. 63, *B*).

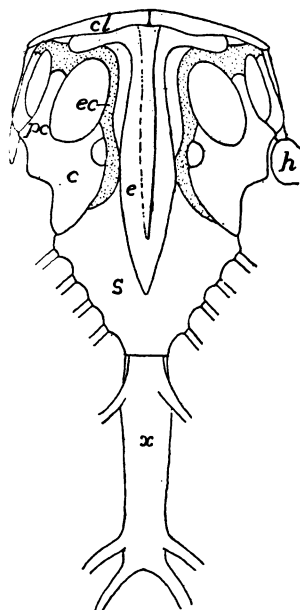


FIG. 64.—Sternum, etc., of *Iguana tuberculata*, after Blanchard. *c*, coracoid; *cl*, clavicle; *e*, episternum; *ec*, epicoracoid; *h*, humerus; *pc*, procoracoid; *x*, xiphisternum.

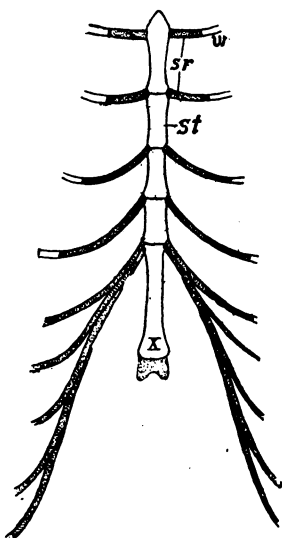


FIG. 65.—Sternum of guinea pig. *sr*, sternal rib; *st*, sternbrae; *vr*, vertebral rib, *x*, xiphisternum.

In the lizards the sternum is a large rhomboid plate, largely cartilaginous, sometimes perforated with two foramina and joined by a varying number of ribs (fig. 64). In the crocodilia there is an anterior rhombic plate, joined by two pairs of ribs and followed by a second, so-called abdominal sternum, connected with from five to seven pairs of ribs. Ichthyosaurs, plesiosaurs and snakes have no sternum, while it was imperfectly ossified in theriomorphs and dinosaurs.

In the birds (fig. 60) the sternum is ossified and at most is connected with eight pairs of ribs. Behind, it may be rounded, perforated, notched, or prolonged into one or two long processes. In the ostriches the ventral surface is smooth and this was formerly used as a character separating these birds as a group of *ratitæ*, in contrast to all other birds (*carinatae*) which either use their wings in flight or in swimming (penguins) and in which there is a necessity for strong wing muscles. For the attachment of these the ventral surface of the sternum is developed into a strong projecting keel (**carina**). It is to be noted that a similar keel is developed in the bats and pterodactyls.

In the mammals the number of ribs connected with the sternum is greater than in the lower classes. The sternobræ may remain distinct throughout life (fig. 65) or, as in man, they may fuse into fewer elements, the xiphoid process being unconnected with the ribs. In the edentates and rodents elements known as *ossa suprasternalia* and *prosternum* occasionally occur in front of the sternum, the significance of which is unknown. It is possible, that traces of them persist in the higher orders, even in man (fig. 62, *ss*).

Episternum (Interclavicle)

In stegocephals and the oldest rhynchocephals there is a median bone on the ventral surface, called the **episternum** (fig. 66). It is

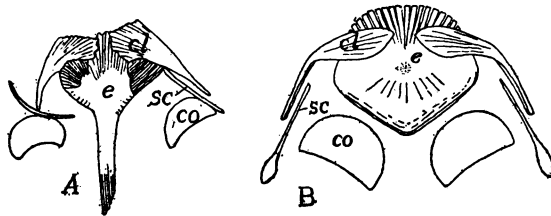


FIG. 66.—Shoulder girdles of (A) *Melanerpeton* and (B) diagram of *Branchiosaurus*, after Credner, the determination of elements after Woodward. *cl*, clavicle; *co*, coracoid; *e*, episternum; *s*, scapula.

rhomboid in front and may have a long posterior process, the medial ends of the clavicles lying ventral to the broad anterior end. This element is regarded as homologous with a T-shaped membrane bone which occupies a similar position in lizards (fig. 64) and crocodilians, where it acts as a brace between the shoulders. It arises in membrane by two centres of ossification and hence cannot be the same as the suprasternalia of mammals. An episternum also occurs in

theriomorphs, pythonomorphs, ichthyosaurs, and plesiosaurs, and possibly the entoplastron of the chelonians (fig. 38, p. 46) is the same structure. It has not been recognized in birds, but it appears in the monotremes among mammals (fig. 124), with nearly the same relations as in the lacertilians.

The Skull

The skull is a complex structure and the last word concerning its composition has yet to be said. A century ago Oken pointed out that a series of parts could be distinguished in the mammalian skull, each of which somewhat resemble a vertebra in its general relations, and thus laid a foundation for a 'vertebral theory of the skull' which was farther developed by Owen. Huxley showed that these were superficial resemblances, that the three or four vertebræ they would recognize were nothing of the sort, and that the skull shows no real metamerism except in the occipital region and in the visceral arches.

In its development the skull, like the rest of the skeleton, passes through two, and in the bony vertebrates, three stages; membranous, cartilaginous and osseous, and in the early stages and in the adult elasmobranchs there is no trace of segmentation or of vertebræ, the Okenian segments only appearing with the development of bone. The skull may be divided into two portions, a **cranium**, composed of a case for the brain, and sense capsules enclosing the organs of special sense (ears, eyes and nose); and a **visceral skeleton**, more or less intimately related to the anterior end of the digestive tract.

Development of the Skull

Little is known in detail of the development of the membranous skull (**membranocranium**) save that it envelops the brain and sense organs, extends into the visceral region, and that it affords the substance in which the second, or cartilaginous, skull is formed.

The cartilaginous envelope of the brain and sense organs is called the **chondrocranium**. The notochord extends forward beneath the brain as far as the infundibulum, and a horizontal cartilage plate forms on either side of it. These **parachordal plates** extend laterally as far as the ears, forward as far as the end of the notochord and back to the exit of the tenth nerve. A little later a cartilaginous **otic capsule** forms around each internal ear and joins the parachordals, thus forming a trough in which the posterior part of the

brain lies, its floor formed of parachordals and notochord (**basilar plate**) and its sides of the sense capsules (fig. 67, 68).

From this posterior part two cartilages extend forward on either side, forming a somewhat similar trough for the anterior part of the brain; the lower of these, the **trabeculæ cranii**, join the anterior margin of the basal plate, while the dorsal bars, the **alæ temporales** or **alisphenoid cartilages** are eventually connected with the anterior wall of the otic capsules (fig. 68). In most vertebrates the trabeculæ and alisphenoids develop as a continuum, but in some elasmobranchs they are at first distinct (fig. 67). The two trabeculæ unite in front to form a median **ethmoid plate** beneath the olfactory lobes of the brain, beyond which they diverge as two horns, the **cornua trabeculæ**, ventral to the nasal organs. The floor of the trough in front

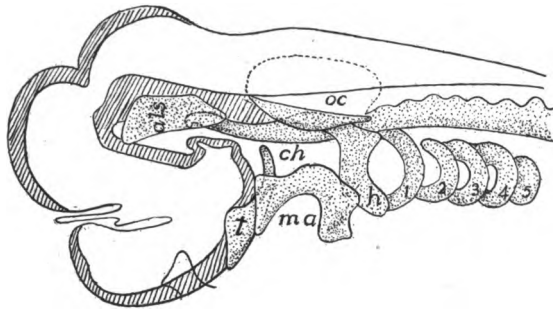


FIG. 67.—Early chondrocranium of *Acanthias*, after Sewertzoff. (The brain in outline.) *als*, alisphenoid cartilage; *ch*, anterior end of notochord; *h*, hyoid arch; *ma*, mandibular arch, not yet divided into pterygoquadrate and Meckelian; *oc*, otic capsule; *t*, trabecula; *r-5*, branchial arches; cartilages dotted.

of the ears is formed by the ethmoid plate anteriorly, while behind it is usually of membrane, but in the elasmobranchs cartilage gradually extends from one trabecula to the other, closing last below the infundibulum and hypophysis, these lying for a time in an opening (**fenestra**, later **fossa hypophyseos**), and after the closure, in a pocket in the floor of the chondrocranium, one of the cranial landmarks, the **sella turcica**.

In the elasmobranchs and amphibians the trabeculæ are widely separated until they reach the ethmoid plate, a condition correlated with the anterior extension of the brain. This is the **platybasic chondrocranium** (fig. 68). In the other classes the brain does not extend so far forward and the two trabeculæ meet just in front of the hypophysis (fig. 70) to continue forward as a **trabecula communis** to the ethmoid region. The trabecula communis is usually compressed between the eyes to a vertical **interorbital septum**. This represents the **tropibasic chondrocranium**.

In the more primitive vertebrates the trough is converted into a tube around the brain by the extension of cartilages between the alisphenoid cartilages and the otic capsules of the two sides dorsal to the brain. This roof or **tegmen cranii** is usually incomplete, having one or more gaps or **fontanelles**, closed only by membrane. In the higher vertebrates the cartilage roof is at most restricted to a mere arch, the **synotic tectum**, between the otic capsules of the two sides.

Later a pair of **nasal capsules** develop around the olfactory organs. These are usually fenestrated and become united to the cornua, alisphenoids, and ethmoid plate. In a similar way a **sclera** (sclerotic coat) forms around each eye, but since the eye must move, this sense capsule never unites with the rest of the cranium. Behind the otic capsules a varying number of (four in some sharks and most teleosts, in others three, in amphibia two, fig. 91) **occipital vertebræ** are developed, which later fuse with the rest of the chondrocranium. They alternate with myotomes and nerves in this region as do the vertebræ of the vertebral column.

The cartilaginous **visceral skeleton** arises in the pharyngeal region, which is weakened by the presence of the gill clefts. It consists of a series of pairs of bars, the **visceral arches** (fig. 69, I-VII), lying in the septa between the clefts, the bars of a pair being connected below the pharynx. Each bar, at first, is a continuous structure, but to allow of changes of size in the pharynx, each becomes divided into separate parts, while the arches become connected in the mid-ventral line by unpaired elements, the **copulæ**. The two anterior arches are specialized and have received special names, the first being the **mandibular**, the second the **hyoid arch**, the others, in the region of the functional gills, being called collectively **gill** or **branchial arches**. The number of these last varies with the number of gill clefts, there

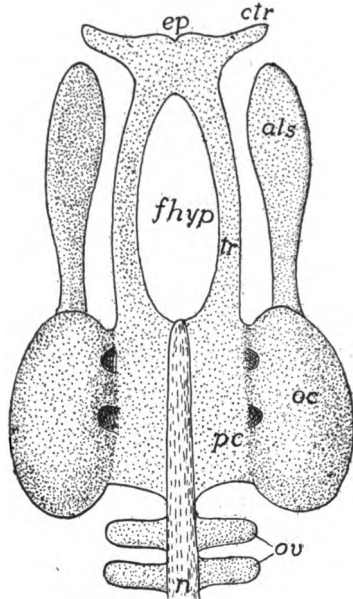


FIG. 68.—Early (platybasic) chondrocranium of an elasmobranch, straightened out. Compare with still earlier fig. 67. *als*, alisphenoid; *ctr*, cornua trabeculæ; *ep*, ethmoid plate; *fhyp*, fenestra hypophyseos; *oc*, otic capsule; *ov*, occipital vertebræ; *n*, notochord; *pc*, parachordal plate; *tr*, trabeculæ.

being seven in the primitive sharks, a smaller number in the higher groups, in which, with the loss of branchial respiration, their form and functions may be altered. At first all are clearly in the head

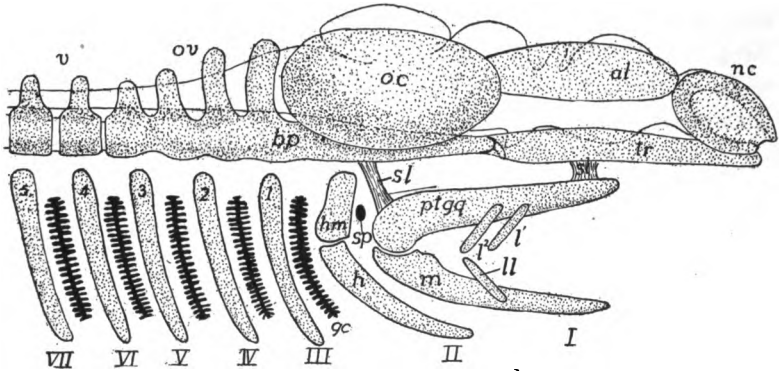


FIG. 69.—Diagram of early elasmobranch chondrocranium in side view, the brain outlined. *al*, alisphenoid plate; *bp*, basal plate; *gc*, gill clefts; *h*, hyoid; *hm*, hyomandibular; *l*, upper labials; *ll*, lower labials; *m*, Meckel's cartilage; *nc*, nasal capsule; *oc*, otic capsule; *ov*, occipital vertebræ; *ptgq*, pterygoquadrate; *sl*, suspensory ligaments; *sp*, spiracle; *tr*, trabeculæ; *v*, vertebræ; *I-VII*, visceral arches; *1-5* branchial arches.

region, but by the unequal growth of cranium and pharynx the gill arches are carried back some distance behind the head. All of the arches are cartilaginous at first.

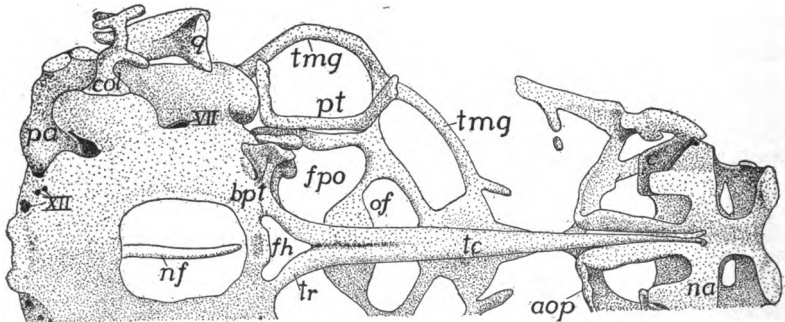


FIG. 70.—Ventral view of (tropibasic) cranium of *Lacerta agilis* after Gaupp. *aop*, antorbital plate; *bpt*, basipterygoid process; *c*, entrance to nasal conch; *col*, columella; *fh*, fenestra hypophyseos; *fpo*, post-optic foramen; *na*, nasal capsule; *nf*, notochord; *of*, optic foramen; *pa*, prominence of posterior ampulla; *pt*, pterygoid; *q*, articular process of quadrate; *tc*, trabecula communis; *tmg*, tænia marginalis; *tr*, trabecula; *VII*, *XII* seventh and twelfth nerves.

The mandibular arch lies in the region of the fifth nerve, behind the mouth and between it and the first visceral cleft or pocket, the spiracle or Eustachian tube. The arch is divided into dorsal and

ventral halves (fig. 69, *I*), known respectively as the **pterygoquadrate** (**palatoquadrate**, *ptgq*), and **Meckelian cartilages** (*m*). In the elasmobranchs and chondrosteous ganoids the pterygoquadrate forms the upper jaw, lying parallel to and joined to the cranium by ligaments or (chimæroids) by continuous growth. With the appearance of bones a new upper jaw is formed, as described below, and

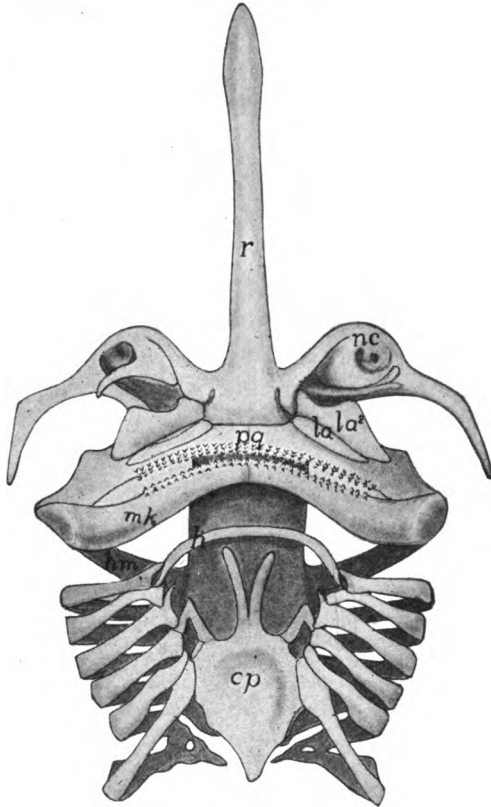


FIG. 71.—Ventral view of cranium and visceral arches of skate (*Raia*) after Gegenbaur. *cp*, copula; *h*, hyoid; *hm*, hyomandibular; *la*, upper labials; *mk*, Meckelian cartilage; *nc*, nasal capsule; *pg*, pterygoquadrate; *r*, rostrum.

the pterygoquadrate becomes more or less reduced, and ossifies as two or more bones with greatly modified functions. Meckel's cartilage is the lower jaw of the lower vertebrates, while in the higher it forms the axis around which the membrane bones of the definitive jaw are arranged.

The hyoid arch lies between the spiracle and the first true gill cleft, in the region of the seventh nerve. It divides into an upper element

the **hyomandibular** cartilage (fig. 69, *hm*), and a ventral portion, the **hyoid proper**, which may subdivide into several parts (*infra*). In the lower elasmobranchs the hyomandibular and the rest of the hyoid arch are closely connected, but in the higher fishes the hyomandibular becomes more separated from the ventral portion and tends to intervene between the mandibular arch and the cranium, becoming a **suspensor** of the jaws (figs. 71). Still higher it loses its suspensorial functions, becomes greatly reduced, and apparently is subsidiary to the sense of hearing (see auditory ossicles), or it may be lost, the question not being decided. The hyoid proper becomes more or

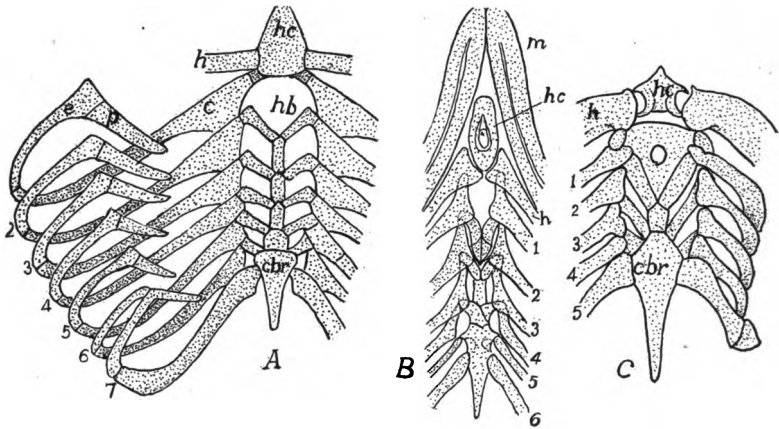


FIG. 72.—Branchial arches of (A) *Heptanchus*; (B), *Chlamydoselache*; and (C) *Cestracion*; A and C after Gegenbaur, B after Garman. *c*, ceratobranchial; *e*, epibranchial; *h*, hyoid; *hb*, hyobranchial; *hc*, hyoid copula; *cbr*, cardiobranchial (posterior copula); *p*, pharyngobranchial; 1-7, branchial arches; *m*, Meckel's cartilage.

less intimately connected with the arches behind and also is largely concerned in affording a support for the tongue.

The branchial arches are all similar to each other in the lower vertebrates, but with the loss of branchial respiration in the higher groups, they tend to become reduced, the reduction beginning behind. Some may entirely disappear, others give rise to the laryngeal cartilages (see respiration) and the first may fuse with the hyoid. The first arch is in the region of the ninth nerve; the others in that supplied by the tenth.

The elements of the branchial arches have the names (fig. 72), beginning above, **pharyngobranchial**, **epibranchial**, **ceratobranchial** and **hypobranchial**, the copulae (p. 69) usually being called the **basibranchials**. The elements of

the hyoid are correspondingly, epi-, cerato-, and hypohyal. These parts lie in the medial ends of the gill septa, medial to the aortic arches.

Other cartilages, which seem to be of less morphological importance, occur in the same region. Among these are the labial cartilages (fig. 67, *l*), usually two above and one below, which lie in front (outside) of the cartilages of the mandibular arch of sharks, and in a modified form as high as some of the ganoids. By some they are regarded as remnants of visceral arches of the preoral region. In the branchial region of the elasmobranchs a variable number of extrabranchial cartilages may occur, small bars external and parallel to the upper and lower ends of the gill arches.

The foregoing sketch of the chondrocranium is based on conditions in the gnathostomes, and ignores the peculiarities of the cyclostomes which are summarized below.

In the elasmobranchs and cyclostomes the skull is cartilaginous throughout life, or at most is calcified cartilage, without sharp division into separate elements. In the higher vertebrates the cartilage is supplemented or almost entirely replaced by bone which may be of the two kinds, cartilage bone and membrane bone (p. 47), the distinctions between which must constantly be kept in mind in tracing homologies in the different classes. The membrane bones are usually derivatives of the deeper or dentinal layer of scales or teeth which have fused together (fig. 73) and have sunk to a deeper position, coming into close connexion with the elements derived from the cartilage skull, in some cases replacing considerable of it. The cartilage bones arise by an ossification of the cartilage. Even in the sturgeons the chondrocranium is complete, the membrane bones being superficial and not intimately connected with the deeper parts.

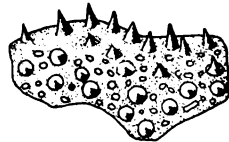


FIG. 73.—Vomer of 25 mm. *Amblystoma* larva, after Hertwig, showing the bone developed by the fusion of the bases of teeth.

The names of the bones are largely based on the terminology of human anatomy. In many cases what appears as a single bone in the human skull is represented by several bones in the young and in the lower vertebrates. In these cases the bones in the lower forms are usually given names which indicate their relation to the human bones or to the part or region in which they occur. Dermal bones are apparently the older, phylogenetically, but for convenience the cartilage bones are considered first.

The chondrocranium shows several centres of ossification, but only those giving rise to distinct bones are considered here.¹ The

¹ Basi- and presphenoid, for example, arise each from two centres, but in all vertebrates the resulting bones are unpaired.

bones of the cartilaginous brain case may be arranged in four groups, beginning behind and called respectively **occipitalia**, **sphenoidalia** and **ethmoidalia**, there being two sets of sphenoidalia. The occipitalia arise in the occipital vertebræ and in the basilar plate. Of these there are four (figs. 74, 75): A **supraoccipital** above, an **exoccipital** on either side, and a **basioccipital** below, the latter extending forward into the basilar plate. These four form a ring around a central opening, the **foramen magnum**, through which the spinal cord connects with the brain.

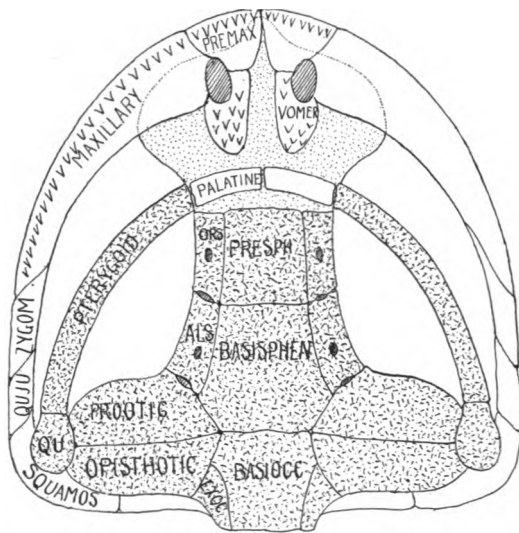


FIG. 74.—Ventral view of schematic skull, chondrocranium dotted, cartilage bones with lines and dots. *basiocc*, basioccipital; *basisph*, basisphenoid; *als*, alisphenoid; *exoc*, exoccipital; *ors*, orbitosphenoid; *presph*, presphenoid; *premax*, premaxilla; *qu*, quadrate; *quju*, quadratojugal; *squamos*, squamosal; *zygom*, zygomatic; other names in full.

Just in front of the basioccipital the basilar plate ossifies to form the **basisphenoid**, which extends forward to the sella turcica (p. 68), and is there succeeded by the **presphenoid**, arising from the trabeculæ, and extending forward to the ethmoid plate. On either side a bone, the **alisphenoid**, ossifies in the cartilage of the same name, and comes into close relation with the basisphenoid. Farther in front a second element, the **orbitosphenoid**, arises in the alisphenoid cartilage and comes into relation to the presphenoid. The alisphenoid bone is just in front of the otic capsule, but there is always a large gap (**sphenoidal fissure**, **foramen lacerum anterior**) between it and the orbitosphenoid, through which the third, fourth, and

sixth and the ophthalmic branch of the fifth nerve pass, the rest of the fifth nerve passing through the alisphenoid bone. The optic nerve usually perforates the orbitosphenoid, but may pass through notch in its margin.

The ethmoid plate may ossify into a median **mesethmoid** bone bounded on either side by an **ectethmoid** and in some there may be added other bones included among the 'turbinal bones.' The olfactory nerves pass on either side of the mesethmoid, the ectethmoids (below) in the mammals developing as perforated plates (**cribiform plate**).

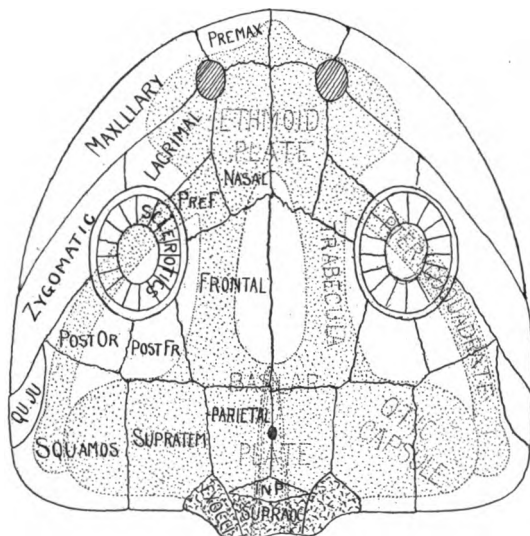


FIG. 75.—Dorsal view of schematic skull, the chondrocranium dotted, cartilage bones with lines and dots. *premax*, premaxilla; *pref*, prefrontal; *postfr*, postfrontal; *postor*, postorbital; *squamos*, squamosal; *quju*, quadratojugal; *qu*, quadrate; *inp*, interparietal; *exoc*, exoccipital; *supratem*, supratemporal; *supraoc*, supraoccipital; other names in full.

A series of **otic** or **petrosal** bones is developed in each otic capsule. The most constant of these are a **prootic** in front, an **opisthotic** behind, the two usually meeting below (fig. 74), and between them, above, an **epiotic**, concerning which more evidence is needed. In the teleosts and some other forms the lateral wall of the otic capsule may develop, in addition, a **sphenotic** in front and a **pterotic** behind, the latter overlying the horizontal semicircular canal of the ear. In the higher groups the various otic bones fuse in the adult to a single **petrosal** bone, which is wedged in between the lateral parts of the basioccipital and basisphenoid.

In the stegocephals, reptiles and birds the sclera of the eye often gives rise to a ring of **sclerotic bones** (fig. 75), which, however, never unite with the other bones of the skull. The nasal capsules often develop a **lateral ethmoid** on the upper wall, and turbinals on the medial and lateral walls.

To place these bones in the terms of human anatomy: the four occipitalia fuse to form the single **occipital** of man; the six sphenoidalia similarly unite to form the single **sphenoid**, the alisphenoids forming the greater wings, the orbitosphenoids the lesser wings; while the ethmoidalia fuse to the **ethmoid**.

In all bony vertebrates the cranial walls are completed dorsally by membrane bones, which in the lower fishes overlie the tegmen cranii, while in the higher groups they replace it, the cartilage failing to develop in the roof. The number of these elements varies between wide limits, the following being the most constant.

Beginning in front (fig. 75), there are, on either side of the median line a pair of **nasal bones** covering the olfactory region; a pair of **frontals** between the orbits; a pair of **parietals** at the level of the otic capsules, between which there is frequently a **parietal foramen** for the connexion of the parietal eye with the brain; and an **interparietal**, arising from paired centres, between the parietals and the supraoccipital.

In the higher vertebrates (where the interparietal frequently fuses with the supraoccipital) these are practically all of the membrane bones in the cranial roof of the adult. In the lower groups there are several other bones, some of which may appear in the development of the higher forms. Thus lateral to each parietal there may be a **supratemporal**; behind the orbit a **postfrontal** may articulate with the frontal, and lateral to this, and forming the rest of the posterior wall of the orbit a **postorbital**. Occasionally the superior (or medial) wall of the orbit is formed by one or more **supraorbital bones**, which, when present, exclude the frontal from the orbit. The orbit may be bounded in front by a **prefrontal** bone, adjoining the antero-lateral margin of the frontal, and lateral to this there is usually a **lacrimal bone**. Less constant are an **intertemporal** bone dorsal (medial) to the alisphenoid, a pair of **postparietal** bones between parietals and interparietals and a so-called 'epiotic' above each otic capsule, which, since it is not a cartilage bone and has no relation to the true epiotic, is better called the **tabulare**.

In the ichthyopsida, and to a less extent in the sauropsida, the basilar plate and trabeculae may fail to ossify. In these cases the

floor of the cranium (roof of the mouth) is formed by a membrane bone, the **parasphenoid**, which lies ventral to the cartilage in the sphenoid region. Farther forward, in the nasal region, are an additional pair of membrane bones, the **vomers**. Both vomers and parasphenoids frequently bear teeth and their origin by fusion of the bases of teeth is clearly seen in developing amphibia (fig. 73).

Some think the parasphenoid the homologue of the mammalian vomer, calling the vomers of the non-mammals **prevomers**, their representatives being sought in the 'dumb-bell bone' of the monotremes. More evidence is needed on these points.

With the appearance of bone the mandibular arch undergoes the greatest modifications of all the visceral arches. Its pterygoquadrate half loses its function as the upper jaw and becomes more closely connected with the cranium in front, its median portion disappearing, even as cartilage, and being replaced by a pair of membrane bones, the **palatines** (fig. 74), which lie between the pre- or parasphenoid and the vomers. The rest of the arch ossifies as two bones on either side, an anterior **pterygoid** and a posterior **quadrate**, which now becomes the suspensor of the lower jaw. In the teleosts and reptiles there are a series of pterygoid bones.

A second arch of membrane bones develops outside of the pterygoquadrate to form the functional upper jaw (figs. 74, 75) in all bony vertebrates. In its fullest development it consists of bones on either side, beginning behind with a **squamosal**, which overlies the quadrate, and followed by a **quadratojugal**, a **zygomatic (malar or jugal)**, and a **maxillary**, which joins the **premaxillary**, the latter forming the tip of the jaw and meeting its fellow of the opposite side. Of these only the maxillary and premaxillary bear teeth.

In the lower vertebrates the roof of the skull is continuous, its only openings being those for the nares and the orbits. In the higher groups vacuities or **fossæ** appear in the postero-lateral parts, these being bounded by bars or **arcades** of bone. At most there may be three of these fossæ. The more lateral of these, the **infratemporal fossa** (fig. 76), is bounded laterally by the zygomatic and quadratojugal, while on the inner side it is separated from the **supratemporal fossa** by a squamoso-postorbital arcade. The **posttemporal fossa** lies between parietal, supratemporal and occipital bones. Occasionally only the infratemporal fossa is present, or, by disappearance of the intervening arcade, infra- and supratemporal fossæ may unite in a single **temporal fossa**. Lastly, by the breaking down

of the zygomatic-postorbital bar, the temporal fossa and the orbit may unite.

One or another of these bones may disappear in some groups, either by fusion or by complete dropping out. Occasionally they may obtain different

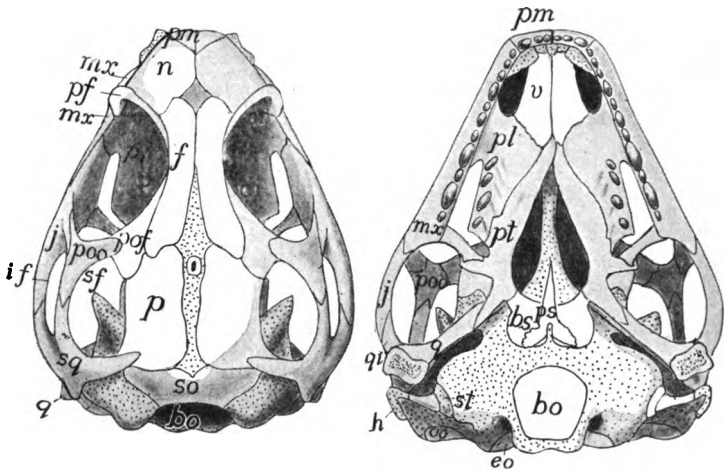


FIG. 76.—Dorsal and ventral views of skull of young *Sphenodon*, after Howes and Swinnerton. *bs*, basisphenoid; *bo*, basioccipital; *eo*, exoccipital; *f*, frontal; *h*, anterior cornu of hyoid; *if*, infratemporal fossa; *j*, zygomatic (jugal); *mx*, maxillary; *n*, nasal; *oo*, opisthotic; *p*, parietal; *pf*, postfrontal; *pl*, palatine; *pm*, premaxillary; *poo*, postorbital; *pof*, postfrontal; *ps*, parasphenoid; *pt*, pterygoid; *q*, quadrate; *qj*, quadratojugal; *sf*, supratemporal fossa; *so*, supraoccipital; *sq*, squamosal; *v*, vomer; cartilage dotted.

connexions and relations, as in the case of the quadrate in mammals (see ear bones) so that the homologies are traced with difficulty. The complexity is increased by the fusion of membrane bones and cartilage bones and by the union of cranial bones with those of the visceral arches.

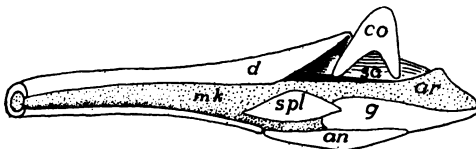


FIG. 77.—Reconstruction of developing jaw of *Sceloporus*, cartilage dotted; *an*, angular; *ar*, articular (not yet ossified); *co*, coronoid; *d*, dentary; *g*, antarticular or goniale; *mk*, Meckel's cartilage; *sa*, surangulare; *spl*, splenial.

In the lower jaw there are no such extensive modifications as in the upper. At most Meckel's cartilage gives rise by ossification to two bones in either half. Behind, at the articulation of the jaw with the quadrate, there is an **articular bone**, while at the tip, at either side of the union (**symphysis**) of the two halves of the jaw, there is rarely a **mento-Meckelian bone**. The rest of Meckel's cartilage forms an axis around which the membrane bones which form the definitive jaw are arranged (fig. 77).

These are, at most, as follows: (1) a **dentary** which surrounds the Meckelian in front and usually bears teeth; (2) a **splénial** on the inner side, behind the dentary and frequently bearing teeth; (3) an **angulare** on the lower side, usually extending back to the hind end of the jaw; (4) a **surangulare** on the outer posterior part of the jaw; (5) a **coronoid** on the upper side, affording attachment for the muscles which close the jaws; and (6) a **goniale** (**antarticular** or **dermatarticulare**) on the medial and ventral sides of the articulare, with which it usually fuses. This whole series is present in few vertebrates, dentary, splénial and angulare being the most constant.

In the hyoid and branchial arches ossification occurs to a greater or less extent, the resulting cartilage bones having the same names as the corresponding cartilages. There are never any membrane bones

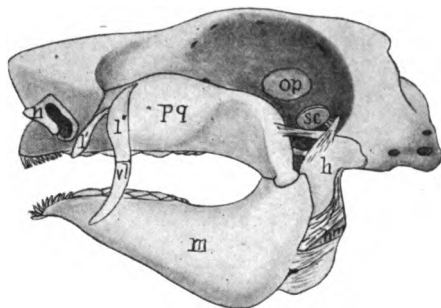


FIG. 78.—Skull of *Heterodontus fransisci*, after Daniel. *h*, hyomandibular; *l*, labial cartilages; *m*, Meckel's cartilage (lower jaw); *n*, nasal capsule; *op*, optic pedicle; *pq*, pterygoquadrate; *sc*, spiracular cartilage.

in this region. In the teleosts the hyomandibular ossifies as two bones, a dorsal hyomandibular and a lower **symplectic** which connects with the quadrate. There is, however, a considerable amount of union between the various arches in the adults of all tetrapoda, where the branchial respiration is lost and the arches have to assume other functions than the support of gills.

The mode of suspension of the jaws varies. In a few elasmobranchs the pterygoquadrate articulates directly with the cranium (**amphistylic**) (fig. 78); in others it is suspended by ligament and by the interposition of the hyomandibular between the otic capsule and the hinder end of the jaw (**hyostylic**, fig. 84); while in all groups above the fishes the pterygoquadrate is more or less completely fused with the cranium (**autostylic**).

TABLE OF THE PRINCIPAL CRANIAL BONES

		Notochord		
Cranium	Chondrocranium	Parachordals	{ Basi-, ex-, and supra-occipitals	
		Trabeculae	{ Basi- and ali-, pre- and orbitosphenoids	
		Ethmoid plate	Mes- and ectethmoids	
		Sense capsules	{ Otic	{ Pro-, epi-, opisth-, pter- and sphenotics (petrosal)
			{ Optic	{ (Sclerotics)
	{ Nasal		{ Lateral ethmoid, turbinals	
	Membrane bones	Roofing bones	{ Parietals, frontals, nasals, pre- and post-frontals, supra- and post-orbitals, supratemporal	
		Lateral line	Lacrimals, infraorbitals	
	Visceral skeleton	Maxillary arch	Membrane bones	{ Premaxillary, maxillary, zygomatic, quadratojugal, squamosal
			Pterygoquadrate cartilage	{ Pterygoid (ect-, ent-, epi-, mesopterygoids), quadrate (incus)
Mandibular arch		Membrane bones	Palatines, vomers	
		Meckel's cartilage	{ Articular, (malleus), mento-Meckelian	
		Membrane bones	{ Dentary, splenial, coronoid, angulare (tympanic), surangulare, goniale	
Hyoid arch			{ Hyomandibulare (stapes), symplectic, interhyal, epicerato-, hypo- and basihyal (corpus, copula), columella (lesser cornua)	
Gill arches			{ Pharyngo-, epi-, cerato-, hypo-, basi-, hyobranchial (copula, greater cornua)	

The ear bones or *ossicula auditus* are best treated together here, although their consideration requires the mention of structures not yet described. The ear bones occur only in the tetrapoda; they present several modifications not readily homologized with each other, though they all have the same function of conveying sound waves across the tympanum to the inner ear. In all there is an opening, the

fenestra vestibuli (f. ovale) in the lateral wall of the otic capsule, which is occupied by a movable bone, the **stapes**, of uncertain homologies, but probably representing the hyomandibular of the fishes, which otherwise is lacking in all tetrapoda. This view is the more probable since in some vertebrates the stapes is connected developmentally with the rest of the hyoid arch.

In urodeles (fig. 91) and cæcilians a slender process extends from the quadrate across the poorly developed tympanic cavity to articulate with the stapes. In the anurans there is no connexion of quadrate with stapes, but a slender rod, the **columella**, extends from the

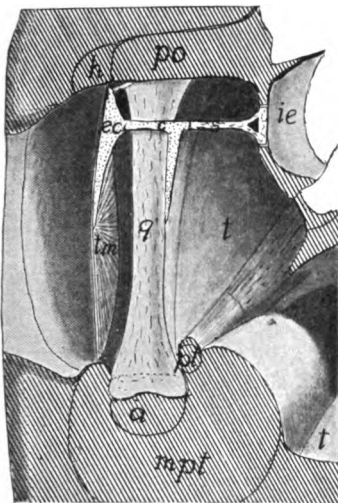


FIG. 79.—Diagram of the middle ear of a lizard, after Versluys. *a*, articular; *c*, columella; *ec*, extra-columella; *h*, hyoid; *ie*, inner ear; *mpt*, pterygoid muscle; *a*, oral cavity; *po*, parotic process; *pt*, pterygoid bone; *s*, stapes; *t*, tympanic cavity; *tm*, tympanic membrane.

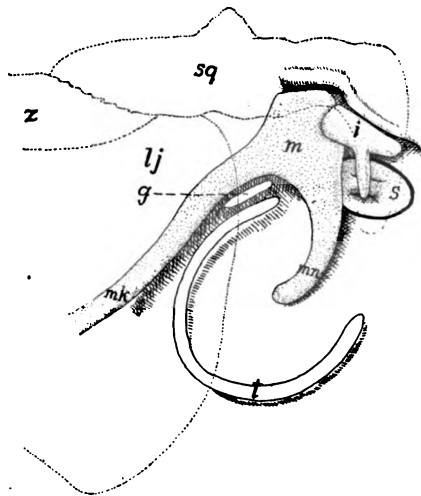


FIG. 80.—Diagram of ear bones of embryo pig, the tympanic cavity laid open. *g*, goniale; *i*, incus; *lj*, lower jaw; *m*, malleus; *mk*, Meckel's cartilage; *mm*, manubrium of malleus; *s*, stapes; *sq*, squamosal; *z*, zygomatic. The outlines of the zygomatic arch and the hind end of the jaw are dotted.

tympanic membrane to the stapes. This columella arises behind the tympanic cavity, but with growth is included in it, so that in the adult it appears to run directly through the cavity. In the sauropsida (figs. 70, 79), the relations are much as in the anura, but when ossification sets in, the columella may form several elements. In development, the columella in these forms is directly connected with the hyoid arch.

In the mammals a chain of three bones carries the sound waves across the tympanic cavity (fig. 80). In the fenestra vestibuli is

the stapes, which connects with an **incus**, and lastly comes the **malleus**, which has two long processes, a **manubrium** which is inserted in the tympanic membrane, and a **processus anterior (Folian process)** which extends into the **petrotympanic (Glaserian) fissure** of the temporal bone. That these parts are not to be compared to the columella of the sauropsida and anura is shown by the fact that they invade the tympanic cavity from in front and that they are in front of the chorda tympani nerve, the columella of the non-mammals lying behind it.

The homologies of these parts seem clear. In development the malleus is the posterior end of Meckel's cartilage, being in the position of the articulare of lower groups. It articulates with the incus, which in turn at first articulates with the wall of the otic capsule, as well as with the stapes, and thus corresponds to the quadrate. The stapes is apparently the same throughout the whole of the tetrapoda. It is to be noted that many paleontologists deny the homologies recognized here, think that in the mammals the quadrate has been lost in the glenoid fossa, and find the malleus and incus in the columella. For this they have no evidence except comparisons with certain theriomorph reptiles. The literature, which is extensive, should be consulted for details.

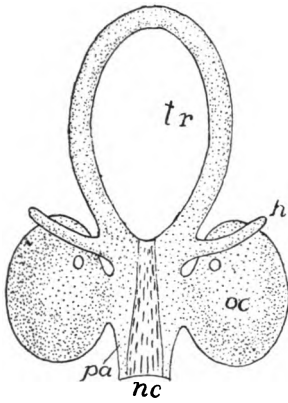


FIG. 81.—Early chondrocranium of Ammocete stage of *Petromyzon*, after Schneider. *h*, hyoid; *nc*, notochord; *oc*, otic capsule; *pa*, parachordal; *tr*, trabeculae.

The Skull in the Different Classes

CYCLOSTOMES have only the cartilage skull, and this can be homologized only in part with that of other vertebrates; indeed the skulls of the two groups of cyclostomes are not easily compared. The peculiarities are in part due to the development of a suctorial mouth with its necessary framework. The chondrocranium of the Ammocete stage of *Petromyzon* is readily understood. Parachordals, otic capsules and trabeculae (fig. 81) are normal, but a pair of ventral horns (*h*) are problematical. Their position in front of and below the otic capsule renders doubtful the interpretation of hyoid or quadrate sometimes given them.

The adult *Petromyzon* (fig. 82) has a typical brain trough, roofed by a slender synotic tectum and fibrous tissue, and closed in front by the unpaired nasal capsule, bound to the rest by fibrous tissue. The cranium is continued

forward by a large plate (mesethmoid?) lying dorsal to the mouth, this part being roofed by two 'dorsal cartilages,' the anterior articulating with the annular cartilage supporting the mouth. A subocular bar extends forward from each

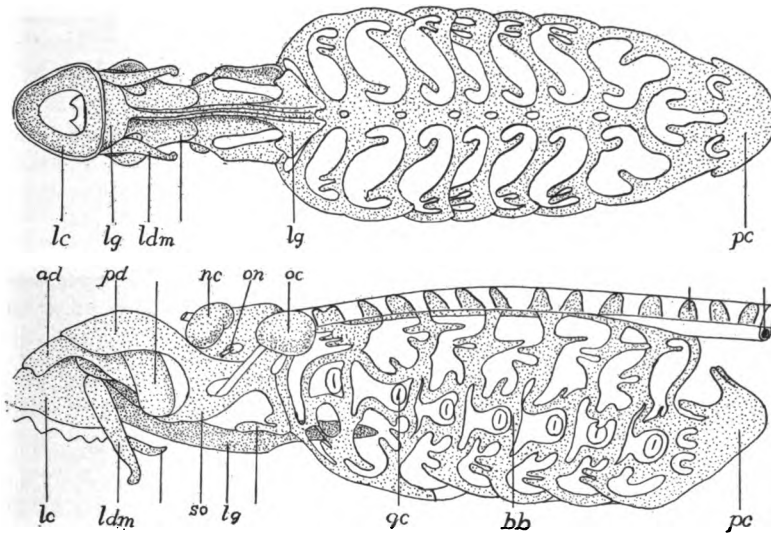


FIG. 82.—Ventral and lateral views of the skull of lamprey (*Petromyzon marinus*), after Parker. *ad*, anterior dorsal cartilage, *bb*, branchial basket; *gc*, gill cleft; *lc*, labial cartilage; *ldm*, lateral distal mandibular; *lg*, lingual cartilage; *nc*, nasal capsule; *oc*, otic capsule; *on*, optic nerve; *pc*, pericardial cartilage; *pd*, posterior dorsal cartilage.

otic region and an elongate lingual cartilage extends from the mouth back to the gill region. Several other elements occur, the names and positions of which may be seen from the figures.

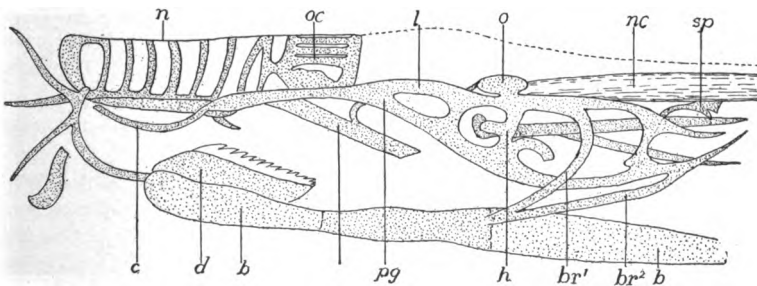


FIG. 83.—Side view of cranium of *Bdellostoma*, after Ayers and Jackson. *b*, basal plate; *br*, branchial basket; *c*, cornual cartilage; *d*, dental plate; *h*, hyoid; *l*, lateral labial cartilage; *n*, nasal tube; *nc*, notochord; *o*, otic capsule; *oc*, olfactory capsule; *pg*, subocular bar; *sp*, supratharyngeal plate.

The myxinoid skull (fig. 83), the development of which is unknown, is readily interpreted so far as basilar plate, trabeculae and otic capsules are concerned. The large nasal capsule is continued forward by a latticed framework

for the naso-hypophysial canal and a bar (subocular) joins the trabecula of either side and in front is continued in a cornual cartilage. The lingual cartilage is enormous (is it the lower jaw as has been suggested?), is divided into three segments and bears a dental plate with teeth at its tip. There are cartilage axes to the tentacles around the mouth.

The branchial skeleton of the lampreys consists of a gill basket of continuous cartilage with fenestræ for the gills and above and below them as well. It cannot be homologized with the branchial skeleton of other vertebrates as it lies immediately beneath the skin and is lateral to gill pouches and aortic arches. It is more easily compared to the extrabranchials (p. 73) of the elasmobranchs. The branchial apparatus of the myxinoids is reduced, consisting of two true gill arches, in front of which is another arch, usually interpreted as a hyoid.

ELASMOBRANCHS have a nearly typical chondrocranium (fig. 84) which is never divided into separate elements and is never ossified. The floor is complete, the hypophysis resting in a sella turcica. Above there is an anterior

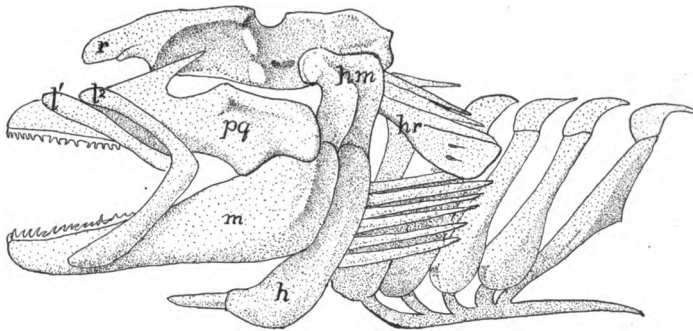


FIG. 84.—Skull of *Squatina*, after Gegenbaur. *h*, hyoid; *hm*, hyomandibular; *hr*, hyomandibular rays; *l*¹, *l*², labial cartilages; *m*, Meckel's cartilage; *pq*, pterygoquadrate; *r*, rostrum.

fontanelle, closed by membrane, and a posterior fontanelle may occur. The occipital region typically articulates with the vertebral column by a pair of prominences, the occipital condyles, but in most species this joint is not functional, the skull being immovably united to the backbone. In front the snout is supported by rostral cartilages, usually three in number, but these are frequently fused to a single mass.

The pterygoquadrate and the Meckelian cartilages bear teeth and form the functional jaws. Most species are hyostylic (p. 79), the pterygoquadrate being supported in front of the orbit by a ethmopalatine ligament on either side; behind by ligament and by the hyomandibular. In the Cestracionts the pterygoquadrate articulates with the cranium in front (fig. 78), but the hyomandibular is still suspensorial. The Notidanids are amphistylic, the hyomandibular being connected with the rest of the hyoid and not acting as a suspensor of the jaws, but the pterygoquadrate bears a strong process which articulates with the postorbital process of the cranium. A fourth condition is found in the holocephalans where the pterygoquadrate, free in the young, becomes autostylic by fusion with the cranium.

The variations in the branchial skeleton (figs. 71, 72) are readily reducible to the typical conditions. In living elasmobranchs the number of gill arches is five, except in *Hexanchus* and *Chlamydoselache* (six) and *Heptanchus* (seven). Hyoid and branchial arches bear numerous branchial rays which support the gills and the gill septa, while smaller cartilages on the inner surface of each arch extend into the gill strainers.

TELEOSTOMES show a wide range of structure of skull, yet the series so intergrade that no sharp lines can be drawn. The chondrocranium persists to a considerable extent, and numerous membrane bones are present, supplementing those of cartilaginous origin. With few exceptions cartilage bones (the four occipitals, orbito- and alisphenoids and prootics are the most constant)

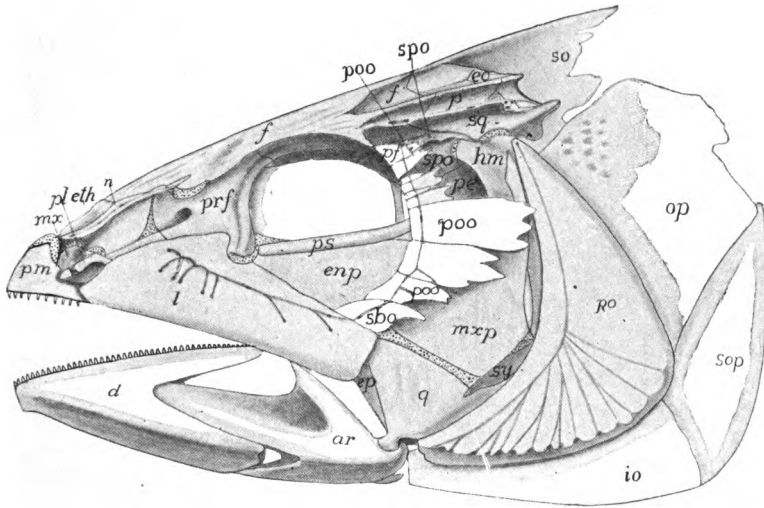


FIG. 85.—Side view of skull of mackerel (*Scomber*) after Allis. *ar*, articular; *as*, alisphenoid; *bo*, basioccipital; *d*, dentary; *enp*, entopterygoid; *eo*, exoccipital; *ep*, ectopterygoid; *es*, extrascapular; *epo*, epiotic; *f*, frontal; *io*, interopercular; *l*, lacrimal; *mx*, maxillary; *mxp*, metapterygoid; *n*, nasal; *op*, opercular; *p*, parietal; *pe*, petrosal; *pf*, postfrontal; *pl*, palatine; *pm*, premaxillary; *po*, preoperculum; *poo*, postorbital; *prf*, prefrontal; *ps*, parasphenoid; *q*, quadrate; *sbo*, suborbital; *so*, supraoccipital; *sop*, suboperculum; *spo*, sphenotic; *sq*, squamosal; *ssc*, suprascapular; *sy*, symplectic.

are developed, while the inner wall of the otic capsule disappears, so that the cavity is connected with that for the brain. Even more characteristic is the presence of skeletal structures supporting the opercular fold which covers the external openings of the gill slits. This is in part of membrane bones, in part of cartilage or cartilage bones. There are two parts to the opercular fold, a gill cover or **operculum** above and a **branchiostegal membrane** below. The latter is supported by **branchiostegal rays**, comparable to the hyoid branchial rays of the elasmobranchs, while the operculum contains membrane bones, there being at most, four of these: (fig. 85) a **preoperculum** in front, and behind this in a row from above downward, **operculare**, **suboperculum** and **interoperculum**. The preoperculum overlies hyomandibular, symplectic and quadrate, and it is

possible that the opercular bones have been developed in connexion with the hyomandibular rays of the elasmobranchs. There are five branchial arches, the last more or less reduced. Often they bear teeth on their inner surfaces, thus acting as accessory chewing organs.

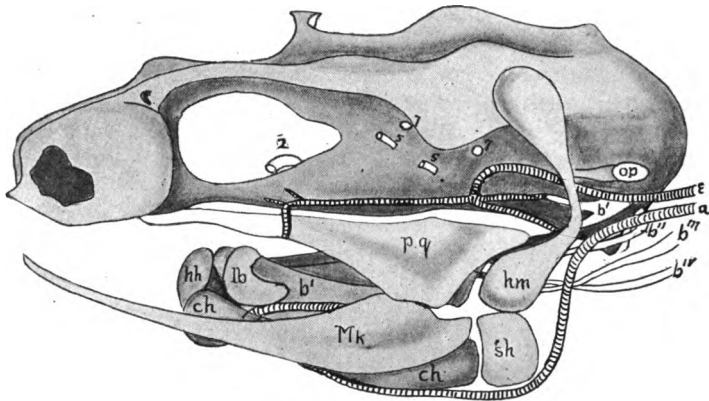


FIG. 86.—Chondrocranium of *Polypterus*, after Budgett. *a*, afferent artery to external gills; *b*¹⁻⁴, branchials; *ch*, ceratohyal; *hh*, hyophyal; *hm*, hyomandibular; *lb*, labial; *Mk*, Meckel's cartilage; *op*, operculum; *pq*, pterygoquadrate; *sh*, stylohyal; 2, 5, 7, nerve exists.

The chondrostei, the most shark-like of the GANOIDS, have no cranial cartilage bones. They are also primitive in the great development of the rostral cartilage (enormous in *Polyodon*), which gives the mouth its ventral position, and in the extension of the cranial cavity into the ethmoid region. They have a few bones in the visceral skeleton, while there are numerous membrane bones

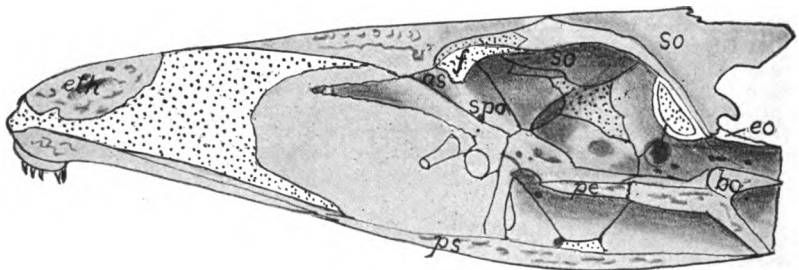


FIG. 87.—Median section of skull of mackerel (*Scomber*) after Allis. For letters see fig. 85.

in the roof of the skull, a few of them readily homologized with those of other vertebrates.

In other ganoids (holosteans and crossopterygians) the skull is much like that of the teleosts, differing in the extension forward of the cranial cavity. There are one (*Amia*) or two (*Polypterus*) gular bones developed between the rami of the lower jaw, and in *Polypterus* parietals, frontals and nasals fuse with

age, and there are numerous small bones in the cranial roof, developed along the lateral line canals. *Amia* has several splenials in the lower jaw.

TELEOSTS (figs. 85, 87-89) have a considerable range of skull structure. In the lower groups like siluroids and cyprinids, the chondrocranium is largely persistent and the cranial cavity extends into the ethmoid region as in the higher ganoids. In other teleosts the trabeculæ are approximate between the orbits (tropibasic) and develop a thin interorbital septum which limits the anterior end of the cranial cavity. The cartilage bones are more numerous. All four occipitalia are present, the occipital condyle being formed by basi- and exoccipitals. Basi, ali-, and orbitophenoids occur, and besides ectethmoids a pair of mesethmoid ossifications. In the otic capsule there are usually pterotic and sphenotic ossifications.

The cranial roof is largely formed by the frontals and parietals, the latter frequently separated by a strong process of the supraoccipital. Several of the cartilage bones are visible from above. The roof of the mouth is formed by the large parasphenoid and the vomers. Premaxillaries (rarely lacking) and maxillaries form the upper jaw, both usually bearing teeth, but occasionally, by overdevelopment of the premaxillary, the maxillary is excluded from the margin of the jaw.

Instead of the single pterygoid of higher vertebrates there are three bones, an **entopterygoid** adjoining the palatine, a **mesopterygoid** (ectopterygoid) which extends back to the quadrate, and a **metapterygoid** above the quadrate (fig. 89). When the hyomandibular cartilage ossifies it forms a hyomandibular bone from its upper portion and a **symplectic** (an element not known outside the teleostomes), which supports the quadrate. A small bone, the **interhyal**, intervenes between the hyomandibular and the rest of the hyoid. The hyoid copula consists of several elements, the anterior, which supports the tongue being called the **entoglossal**, the posterior, which connects with the branchial arches, the **urohyal**. The fifth gill arch consists of a single element on either side, the **hypopharyngeal** bone, which usually bears teeth, the hypopharyngeals of the two sides being fused in the plectognaths, forming a pharyn-

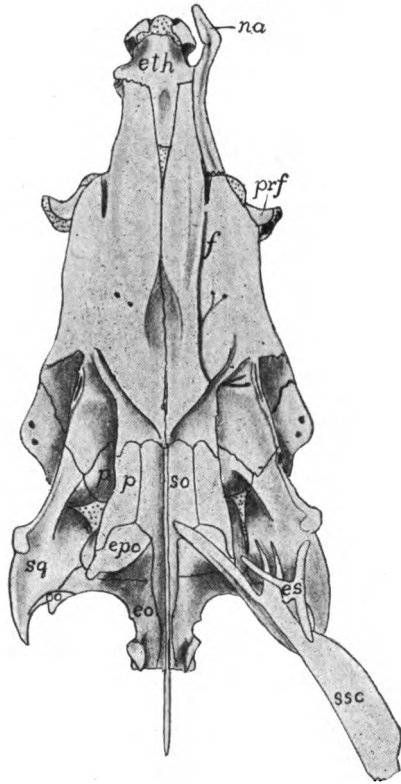


FIG. 88.—Dorsal view of skull of mackerel, *Scomber*, after Allis; letters as in fig. 85.

geal jaw. The upper elements of the other arches are frequently expanded, bear teeth, and are called **epipharyngeal bones**.

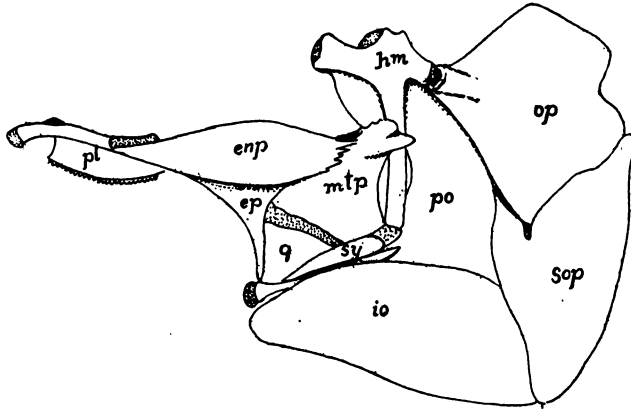


FIG. 89.—Pterygoids, suspensorium and operculum of mackerel (*Scomber*) after Allis. *enp*, entopterygoid; *ep*, ectopterygoid; *hm*, hyomandibular; *io*, interoperculum; *mtp*, metapterygoid; *op*, operculum; *pl*, palatine; *po*, preoperculum; *q*, quadrate; *sop*, suboperculum; *sy*, symplectic.

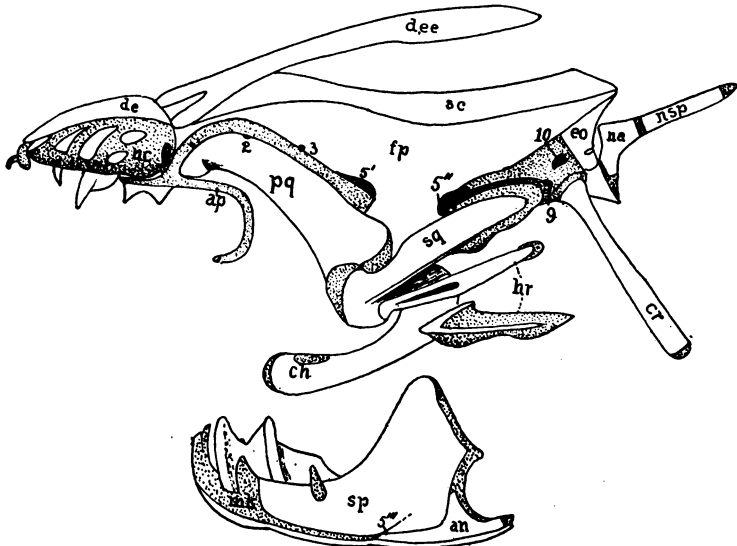


FIG. 90.—Skull of *Lepidosiren*, after Bridge. *an*, angular; *ap*, antorbital process; *ch*, ceratohyal; *cr*, cranial rib; *de*, dermal ethmoid; *dee*, dermal ectethmoid; *eo*, exoccipital; *fp*, frontoparietal; *hr*, hyoidean ribs; *mk*, Meckel's cartilage; *na*, first neural arch; *nc*, nasal capsule; *nsr*, neural spine; *pq*, pterygoquadrate; *sc*, sagittal crest of frontoparietal; *sp*, splenial; *sq*, squamosal; 1-10, nerve exits.

DIPNOI.—In the three existing genera (fig. 90) the skull is comparatively uniform, but the fossils, beginning in the Devonian, have a wide range of structure. In the former the cavity of the chondrocranium extends to the ethmoid

region and the nasal capsules have a second opening, corresponding to the inner nares (choanæ), inside the oral cavity. The pterygoid is fused with the cranium (autostylic), and there are one (*Protopterus*) or two (*Ceratodus*) labial cartilages connected with the nasal capsules. In *Ceratodus* there are no cranial cartilage bones, but in the other genera a plate composed of fused ex- and supraoccipitals occurs.

The membrane bones are few, but their homologies are not always certain. The roof is largely formed by an unpaired bone in the position of frontals and parietals, in front of which is a median bone (supraethmoid, dermal ethmoid or fused nasals) above the nasal capsules. In *Ceratodus* a bone of uncertain homology occurs on either side of the fronto-parietal, but it is lacking in the others, unless it be represented in *Protopterus* by a pair of bones which abut against the supraethmoid and overlap the fronto-parietals. The otic capsule and quadrate are covered by a squamosal, and the roof of the mouth is formed by a large parasphenoid, in front of which are a pair of palatines. In advance of these last are a pair of large teeth resting directly on cartilage, their bases representing the greatly reduced vomers. The lower jaw has three bones on either side, a small dentary, a larger angulare, and an enormous splenial, which alone bears teeth.

In *Ceratodus* there is a hyomandibular fused to the cranium behind the exit of the seventh nerve, but elsewhere there is only the hyoid. The operculum has one or two elements (operculare and interoperculum) the free edges of which bear cartilaginous rays, and the gill arches are five in *Ceratodus*, six in the other genera. A peculiar feature of *Protopterus* and *Lepidosiren* is the so-called cranial rib, a slender cartilage bone articulated with the chondrocranium below the occipital plate, and extending backward and downward across the shoulder girdle (fig. 90, *cr*).

In those extinct Dipnoi which are united with the recent genera to form the order Sirenoidea, the skull is much as in the existing forms, except for the more numerous bones. In the Arthrodira (formerly called placoderms) the cranium is hinged to a large plate which covers the anterior part of the trunk, and the skull is roofed with a few large plates, some of which may be homologized with those of the sirenoids, the others not being readily compared with the bones of other vertebrates. The suggestion has been made that the problematic fossil *Palæospondylus* resembles, in its skull, the larvæ of the dipnoans, the adults of which were common in the same seas.

AMPHIBIA.—Several points distinguish the amphibian from other skulls. The chondrocranium (fig. 91) is platybasic (p. 68); except for a small synotic tectum frequently present, it is not roofed by cartilage; the otic capsule has a fenestra vestibuli occupied by the stapes, a development connected with the power of hearing (p. 81); there are two occipital condyles; and the quadrate is immovably united to the cranium by two processes, an otic process, joining the otic capsule, and an 'ascending process' which reaches the upper margin of the trabecula (*ap*), and which, in many reptiles, often ossifies as the epipterygoid bone.

The cartilage cranial bones are few. Usually only exoccipitals are developed in the hinder region, while the rule is a single petrosal (prootic), but occasionally

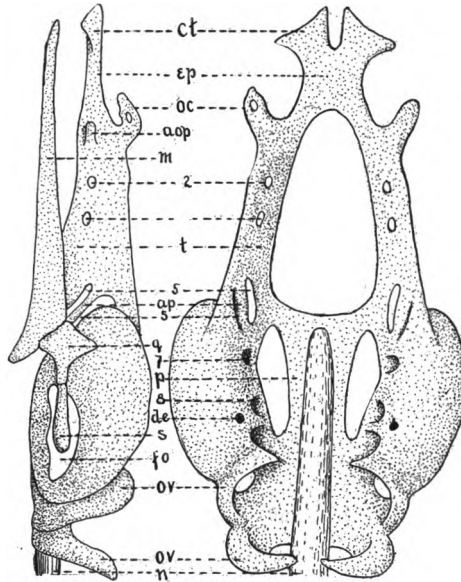


FIG. 91.—Chondrocranium of *Amphiuma*, lateral and dorsal views. *aop*, antorbital process; *ap*, ascending process of quadrate (eipterygoid); *ct*, cornua trabeculae; *de*, foramen for ductus endolymphaticus; *ep*, ethmoid plate; *fo*, fenestra vestibuli; *m*, Meckel's cartilage; *n*, notochord; *oc*, olfactory capsule; *ov*, occipital vertebrae; *p*, parachordal; *q*, quadrate; *s*, stapes; *t*, trabecula; 2-8, nerve exists.

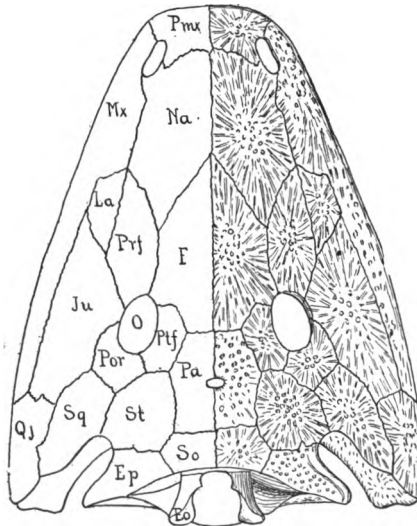


FIG. 92.—Skull of a stegocephalan (*Capitosaurus*) after Zittell. *eo*, exoccipital; *ep*, epiotic; *f*, frontal; *ju*, zygomatic (jugal); *la*, lacrimal; *mx*, maxillary; *na*, nasal; *o*, orbit; *pa*, parietal; *pmx*, premaxillary; *por*, postorbital; *prf*, prefrontal; *ptf*, postfrontal; *qj*, quadratojugal; *so*, supraoccipital; *sq*, squamosal; *st*, supratemporal.

epi-, opisth-, and pterotic occur. There is but a single pterygoid, while basi-, pre-, and alisphenoids are not ossified. The membrane bones in existing amphibians have separated from the integument and have sunk to a deeper position than in fishes, but in many stegocephals the presence of grooves for the lateral line system would indicate a close connexion between skin and bones. In the latter group the membrane bones are numerous, but in existing species they are noticeably reduced. Except in stegocephals and the cæcilians there are large vacuities in both floor and roof of the skull. The lower jaw also has a reduced number of bones, there being at most five, including the articulare and the mento-Meckelian.

The most primitive conditions occur in the stegocephals (fig. 92), where, as the name indicates, the dorsal surface is covered, leaving only gaps for the eyes and nostrils. In general the account of the skull given on p. 74 ff will apply

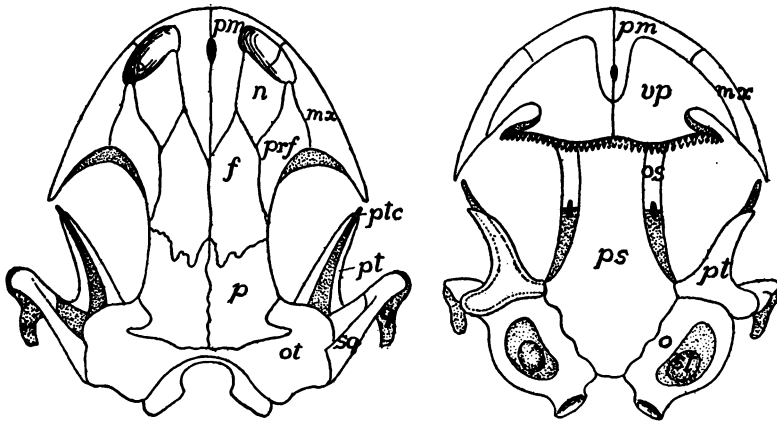


FIG. 93.—Skull of *Amblystoma punctatum*, after Wiedersheim. *f*, frontal; *mx*, maxillary; *n*, nasal; *os*, orbitosphenoid; *ot*, otic bones; *p*, parietal; *prf*, prefrontal; *ps*, parasphenoid; *pt*, pterygoid; *ptc*, pterygoid cartilage; *q*, quadrate; *sq*, squamosal; *st*, stapes; *vp*, vomeropalatine.

to these forms, and so far as the dorsal surface is concerned little more needs to be said, aside from the fact that the supratemporal is sometimes transversely divided, that an interparietal foramen occurs (indicating the existence of a parietal eye), that the bones called supraoccipital may be interparietal, and that the sclerotics are common. The floor of the cranium is formed by a large paraphenaeo, bordered in front by a pair of (usually toothed) palatines, in front of which are the vomers. Of the cartilaginous parts almost nothing is known; a few, chiefly larval forms, have well-developed branchial arches preserved.

Of the GYMNOPHIONES (cæcilians) the cartilage skull is known only in *Ichthyophis*; its peculiarities are the reduced parachordals, an ethmoidal nasal septum, a stapes, perforated as in mammals, and alisphenoid and trabecular cartilages more distinct than in most amphibia. Most noticeable of the cartilage bones is the ethmoid, while otics and exoccipitals are fused as are quadrate and pterygoid. The membrane bones form a complete roof to the skull, recalling the stegocephals, but the number of bones is smaller, squamosal, supratemporal, jugal

and quadratojugal being absent, while a large prefrontal and a larger postfrontal (usually called squamosal) occur. In the roof of the mouth maxillary and palatine are fused, the vomers distinct, while the united parasphenoid and basioccipital form a large *os basale*. In the lower jaw there are only dentary and angular, the latter being produced behind the articulare in a remarkable way.

In the cartilage skull of the *URODELES* (fig. 91) the pterygoid does not usually reach the anterior part of the skull but projects as a process from the quadrate, which bears, besides the two processes already mentioned (p. 89), a palatobasal process joining the otic capsule in front of the otic process. Cartilage bones are few; supra- and basioccipital, alisphenoid and ethmoids are lacking; the otics fuse to a single petrosal; an orbitosphenoid occurs and quadrate and pterygoid are continuous.

The roof of the adult skull is chiefly formed of parietals, frontals and nasals, the latter being frequently separated by processes of the premaxillaries. Each frontal has a ventral process which limits the cranial cavity in front; there is usually a prefrontal, and a septomaxillary may be developed on the posterolateral part of the nasal capsule. A supratemporal is always lacking, the squamosal extending up to the parietal. The upper jaw is composed of premaxillaries and (except some perennibranchs, fig. 94) maxillaries; a jugal is always absent

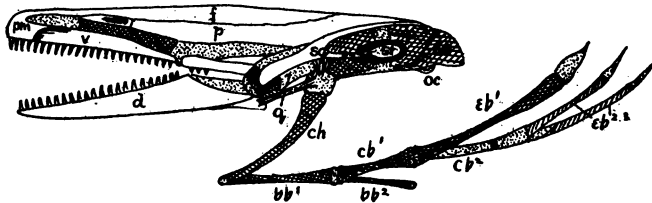


FIG. 94.—Skull of *Proteus*, after Wiedersheim. *bb*, basibranchial; *cb*, ceratobranchial; *ch*, ceratohyal; *d*, dentary; *eb*, epibranchial; *eo*, exoccipital; *f*, frontal; *p*, parietal; *pm*, premaxillary; *q*, quadrate; *sg*, squamosal; *st*, stapes; *v*, vomer; cartilages dotted.

and the quadratojugal, formed in the larva, fuses with the squamosal. In the roof of the mouth are the large parasphenoid, frequently with teeth, and a pair of vomero-palatines, the choanæ lying behind the vomerine portion, which is farther back than in the dipnoi (fig. 93).

In the lower jaw Meckel's cartilage persists, its hinder end forming the articulare, while in front it is surrounded by the dentary and splenial, each bearing teeth. In the larvæ the branchial skeleton is nearly typical, there being a hyoid and four gill arches. In the adult, with the loss of aquatic respiration, the posterior arches are reduced or even disappear, those remaining being connected by a one- or two-jointed copula.

The chondrocranium of the larval *ANURA* (*Rana*, fig. 95) differs considerably from that of other amphibia as well as from the adult conditions. Like all amphibians it is platybasic. The pterygoquadrate has, besides the normal otic and epipterygoid processes, a cranio-quadrate process connected with the nasal region, in front of which is the articulation of the lower jaw. In front of the cornua are a pair of suprarostrals cartilages and a similar pair of infrarostrals lie in front of the Meckelian, from which they are apparently derived. These

four rostrals form a ring around the suctorial mouth and recall the labial cartilages of the elasmobranchs and the annular cartilage of the cyclostome mouth.

At the time of metamorphosis the changes are great, and as the result (fig. 96) is more like the chondrocranium of other amphibia, the larval condition must be regarded as adaptive rather than ancestral. The suprarostrals disappear and the jaw shifts the hinge back to the normal position, this being accompanied by the elongation of Meckel's cartilage, an absorption of the ascending process and a folding of the pterygoquadrate bar. At the same time

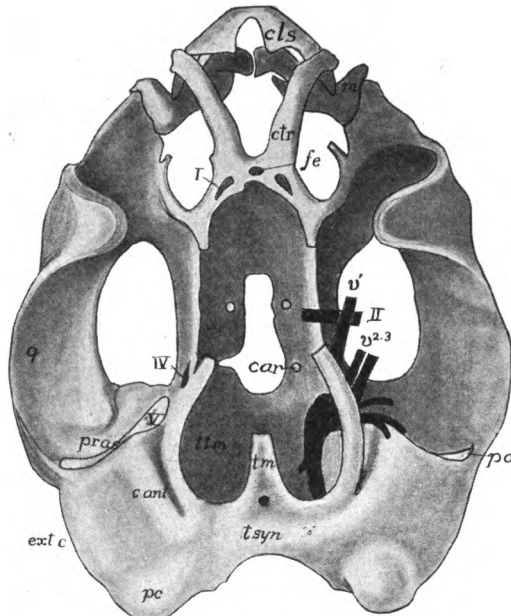


FIG. 95.—Chondrocranium of tadpole of *Rana* before the metamorphosis; after Gaupp. *c.*, *ant*, anterior canal; *car*, foramen for carotid; *cls*, superior labial cartilage; *ctr*, cornu trabeculae; *ext. c.*, external canal; *fe*, ethmoid fenestra; *m*, Meckel's cartilage; *pc*, posterior canal; *po*, otic process of quadrate; *pras*, ascending process of quadrate; *q*, quadrate; *tm*, tectum medialis; *tm*, tænia tecti marginalis (raised border to side of letters); *tsyn* tectum synoticum; I-V, nerves and nerve exits.

a. pterygoid grows out in front to join an antorbital process from the cranium. A stapes develops and connects with the columella, which meets the tympanic membrane. This membrane is stretched on a cartilaginous tympanic annulus, derived from the pterygoquadrate. (Annulus and columella are lacking in those genera, *Bombinator*, etc., which have no tympanum). There is no connexion between stapes and quadrate.

The chondrocranium largely persists, the only constant cartilage bones being the exoccipitals and prootics. A supraoccipital rarely occurs and basioccipital and basisphenoid are unknown. In the ethmoid region, except in the aglossa, there is a peculiar bone, the sphenethmoid, which arises as two bones on either

side. These fuse, forming a ring ('os en ceinture') around the olfactory nerves and the anterior end of the brain.

The frontals and parietals of a side are fused and often the fronto-parietals are continuous across the middle line. They may extend to the nasals or there may be a gap between, leaving the sphenethmoid visible from above (fig. 97). A large squamosal extends above the quadrate, from the otic region to the angle

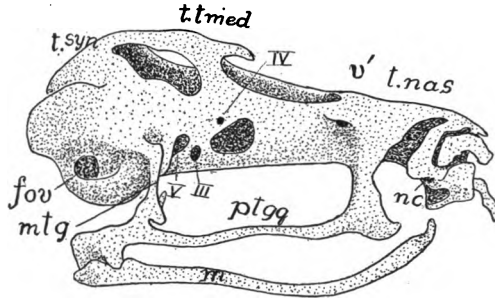


FIG. 96.—Chondrocranium of a frog after metamorphosis, from Gaupp. *fov*, fenestra vestibuli; *m*, Meckel's cartilage; *mtg*, metapterygoid; *nc*, nasal capsule; *ptgg*, pterygoquadrate; *inas*, tectum nasalis; *tsyn*, tectum synoticum; *tmed*, tænia tecti medialis; III-V, nerve exits.

of the jaw. The upper jaw consists of premaxillary and maxillary, and, except in the aglossa, of quadratojugal. The pterygoid cartilage persists, but is overlaid by a membrane bone, also called the pterygoid. Slender palatines, transverse to the axis of the skull, are lacking only in the aglossa, while small vomers are almost always present. The floor of the cranium is completed by a \perp -shaped parasphenoid, which extends to the premaxillaries in the aglossa, elsewhere only to the sphenethmoid.

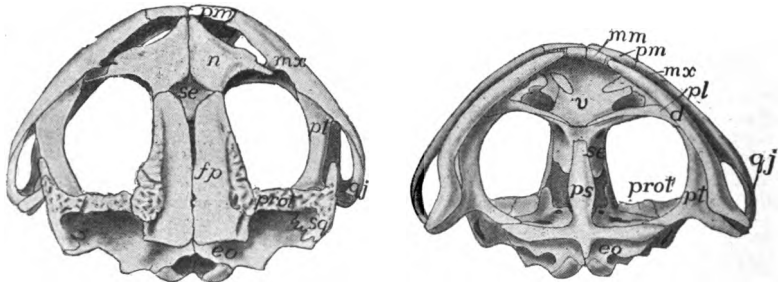


FIG. 97.—Dorsal and ventral views of skull of toad, *Bufo americanus*. *d*, dentary; *eo*, exoccipital; *fp*, fronto-parietal; *mm*, mento-Meckelian; *mx*, maxillary; *n*, nasal; *pl*, palatine; *pm*, premaxillary; *prot*, prootic; *ps*, parasphenoid; *pt*, pterygoid; *qj*, quadratojugal; *se*, sphenethmoid; *sq*, squamosal; *v*, vomer

In the lower jaw there is a mento-Meckelian in front, followed by dentary and angular; Meckel's cartilage persists through life. The larval branchial and hyoid arches are typical, there being four gill arches. With the loss of gills the posterior arches disappear, and the broad hyoid plate of the adult has four processes which are new formations.

REPTILES.—The skull of existing reptiles is very different from that of amphibians, but that of many theriomorphs is strikingly like that of the stegocephalans. The principal differences alluded to in the first sentence have arisen by reduction and disappearance of bones appearing in the more primitive types, but aside from these there is little except the parasphenoid to separate the two groups.

The chondrocranium is known in but a few forms and these agree with other amniotes in being tropibasic (see fig. 70) except in snakes and amphisbænans. In the adults cartilage largely disappears, except in the ethmoid region, more persisting in *Sphenodon* (fig. 98) and the lizards than elsewhere. All four occipitalia are ossified, but some may not participate in framing the foramen

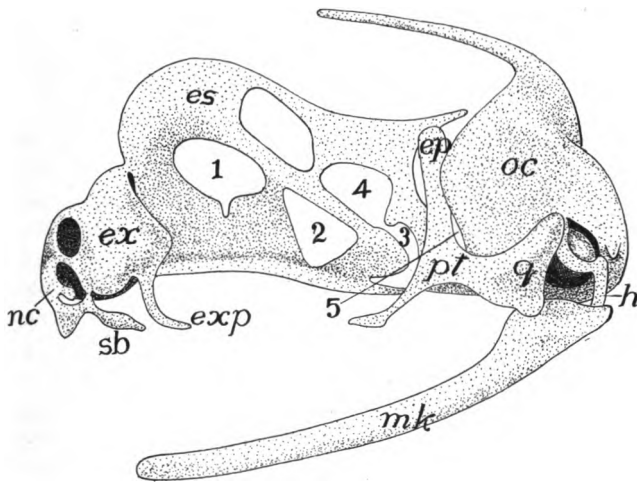


FIG. 98.—Chondrocranium of *Sphenodon*, stage "R," after Howes and Swinnerton. *ep*, epipterygoid; *es*, ethmosphenoidal plate; *ex*, extranasal cartilage; *exp*, extranasal process; *h*, hyoid; *mk*, Meckel's cartilage; *nc*, nasal capsule; *oc*, otic capsule; *pt*, pterygoid; *g*, quadrate; *sb*, subnasal process; 1-5, exits of nerves.

magnum, the basioccipital being excluded in many chelonians, the supraoccipital in snakes, crocodiles and theriomorphs. There is but a single occipital condyle (except in a few theriomorphs), which is borne on the basioccipital as in the crocodiles, or on this and the exoccipitals as in chelonians and squamata. Basisphenoids are present, orbito- and alisphenoids are but slightly ossified and the ethmoid region is largely cartilaginous. Pro-, epi- and opisthotics are present, the epiotic fusing with the supraoccipital, while the opisthotic in all recent forms except the turtles unites with the exoccipital in the adult.

In all except the squamata, in which it is movable (**streptostylic**), the quadrate is firmly united to the squamosal and sometimes to other bones (**monimostylic**). The pterygoids extend forward to the palatines. In the squamata and the ichthyosaurs pterygoids and palatines are widely separated in the middle line, but elsewhere they are closely approximate, the pterygoids even meeting the basisphenoid. In all except chelonians, some dinosaurs and the typhlopida an **ectopterygoid** (*os transversum*) extends from pterygoid to maxilla, while in

plesiosaurs and most lizards (kionocraniate) ossification of the ascending process of the quadrate forms an **epipterygoid** bone between the pterygoid and the parietal.

Membrane bones are more numerous than in the amphibians. In many theriomorphs there is a supratemporal fossa between parietal and supratemporal bones and the same is true of plesiosaurs, ichthyosaurs and chelonians. In the rhynchocephals, dinosaurs, pterodactyls and crocodiles there is in addition, an infratemporal fossa, bounded laterally by an arcade in which squamosal quadratojugal and zygomatic participate in varying degrees. In the lizards the two unite in a single temporal fossa by the disappearance of the upper arcade, and lastly, in the snakes the lower arcade is lost and the fossa becomes a gap in the side of the skull.

Parietals and frontals are usually paired, a parietal foramen being common; pre- and postfrontals usually occur, sometimes excluding the frontal from the orbit. Lacrimals are common and the margins of the upper jaw are formed in front by premaxilla and maxillary, the latter connected with the squamosal, sometimes by zygomatic and quadratojugal, or the zygomatic may drop out, or lastly the jaw may end with the maxillary. Several membrane bones may aid in the formation of the roof of the mouth. There is a small parasphenoid in ichthyosaurs, plesiosaurs, many squamata, some rhynchocephals, and rarely in turtles. It is usually associated with the basisphenoid and in ophidia it forms the base of the interorbital septum. The vomers are paired except in the chelonia, and only in *Sphenodon* of recent species do they bear teeth, and here but one to each bone. The maxillaries usually have broad palatal processes extending toward the middle line, causing the choanæ to open farther back, and in some, these, together with the palatines and pterygoids, form a false palate, ventral to the nasal passages, so that, as in the crocodiles, the choanæ are carried far back in the mouth. In some dinosaurs there is a rostral bone in front of the premaxillæ.

The two halves of the lower jaw are united by ligament in most rhynchocephals, snakes and pythonomorphs; by suture in crocodiles, rhynchocephals and lizards; while they are fused in turtles and pterosaurs. All of the bones mentioned on page 78 may occur in the lower jaw, usually with distinct sutures, while in crocodiles, theriomorphs and some dinosaurs there are gaps or vacuities in its walls. In many dinosaurs there is a **predentary** bone at the tip of the jaw. Except in the chelonia and a few isolated forms, both jaws bear teeth, which may be restricted to maxillaries and premaxillaries, or may also occur on palatines, vomers and pterygoids. In their fixation three types are found: **acrodont**, when fused to the margin of the bone; **pleurodont**, when fastened to the side of the bone; and **thecodont**, when implanted in sockets.

The hyoid apparatus is much modified, but is adequately known only in recent species. The branchial arches are usually better developed than the hyoid proper, which is cartilaginous in most snakes and is lacking in the crocodiles. In the chelonia (fig. 102) two branchial arches are usually present.

The **THERIOMORPHS** (fig. 99) have a short, broad skull with parietal foramen; and that of the cotylosaurs was much like that of the stegocephals. In the more differentiated groups the skull recalls that of mammals, especially in the

participation of the squamosal in the hinge of the jaw. Lacrimals are occasionally absent, sclerotics sometimes present. The palatal region is known in a few forms. The pterygoids may meet only in front, leaving a vacuity between them

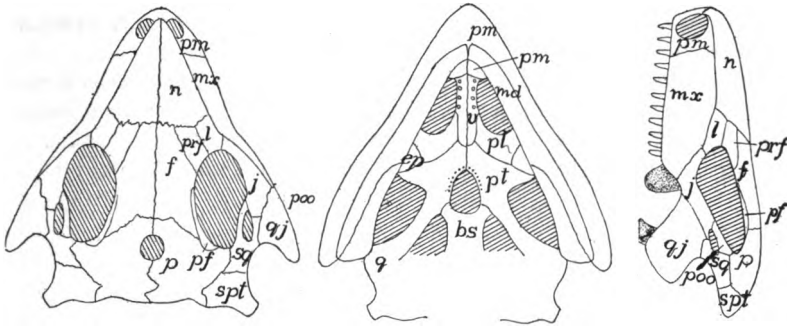


FIG. 99.—Skull of *Procolophon*, after Woodward. *bs*, basioccipital; *ep*, epipterygoid; *f*, frontal; *j*, zygomatic (jugal); *l*, lacrimal; *md*, mandible; *mx*, maxillary; *n*, nasal; *pf*, postfrontal; *pl*, palatine; *pm*, premaxillary; *poo*, postorbital; *prf*, prefrontal; *q*, quadrate; *qj*, quadratojugal; *spt*, supratemporal; *sq*, squamosal; *v*, vomer.

and the basisphenoid, or they may meet that bone. The choanæ are in front of the palatines but (theriodonts) may be displaced backward by palatine processes of the maxillaries.

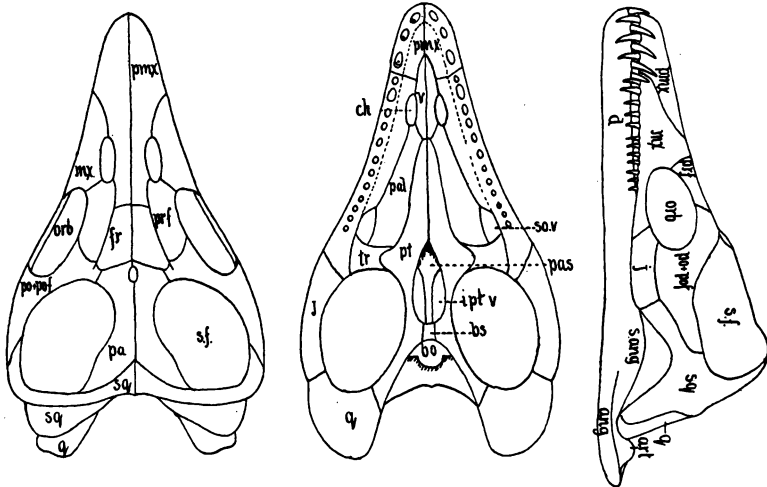


FIG. 100.—Skull of *Plesiosaurus macrocephalus*, after Andrews. *ang*, angular; *art*, articular; *bo*, basioccipital; *bs*, basisphenoid; *ch*, choana; *d*, dentary; *fr*, frontal; *iptv*, interpterygoid vacuity; *j*, zygomatic (jugal); *mx*, maxillary; *orb*, orbit; *pa*, parietal; *pal*, palatine; *pas*, parasphenoid; *po + pos*, postorbital and postfrontal; *pmx*, premaxillary; *prf*, prefrontal; *pt*, pterygoid; *q*, quadrate; *sang*, surangulare; *sf*, supratemporal fossa; *sov*, suboptic vacuity; *sq*, squamosal; *tr*, transversum.

All four occipitalia are developed; the occipital condyle is tripartite, being formed by basi- and exoccipitals, but in *Cynognathus* the recession of the basioccipital results in a dicondylic condition. The greatest variations occur in the

temporal region. In the lower cotylosaurs the cranial roof is without fossæ (Broom doubts the infratemporal fossa of *Procolophon*). In other theromorphs quadratojugal and supratemporal are lacking, the squamosal meeting the parietal. *Placodus* has only the supratemporal fossa, but in the majority the upper arcade has disappeared, leaving a large temporal vacuity, much as in mammals.

Little is known of the lower jaw. The bones are sometimes discrete, sometimes extensively fused. The teeth are thecodont, and in the theriodonts are differentiated into incisors, canines and molars, but in the anomodonts teeth are absent, or at most there is a pair of large incisors in the upper jaw.

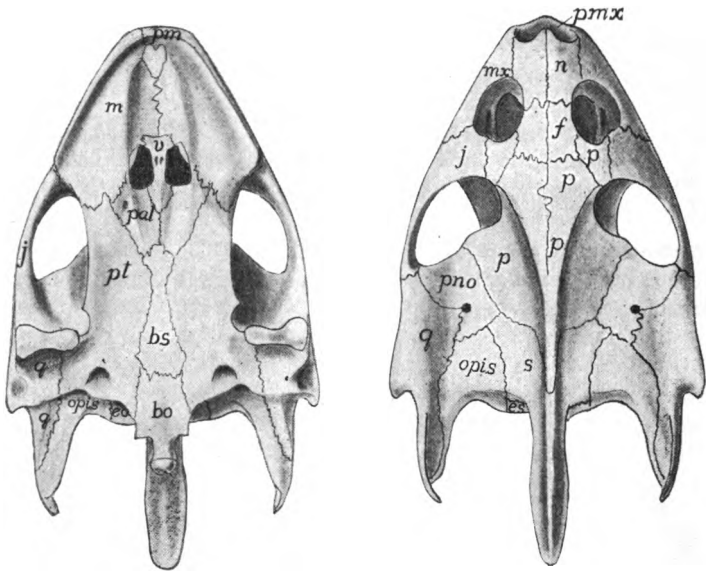


FIG. 101.—Dorsal and ventral views of the skull of turtle, *Trionyx*. *bo*, basioccipital; *bs*, basisphenoid; *eo, es*, exoccipital; *f*, frontal; *j*, zygomatic (jugal); *m, mx*, maxillary; *n*, nasal; *op, opis*, opisthotic; *p*, (behind naris) prefrontal, (others) parietal; *pal*, palatine; *pmx*, premaxillary; *pno*, postorbital; *pt*, pterygoid; *q*, quadrate; *s*, supraoccipital; *v*, vomer.

In the PLESIOSAURS (fig. 100) and their allies the skull is about a twelfth of the total length. There is a parietal foramen between the parietals, which have a process for articulation with the squamosal, the supratemporal being absent. The large prefrontals intervene between the frontals and the orbits; lacrimals and usually nasals are absent. The large temporal fossa is bounded externally by the zygomatic which extends back to the quadrate. The choanæ are in front of the palatines; an os transversum is present and there is frequently a parasphenoid in the interpterygoid vacuity. All have a subtemporal vacuity and there is another in the plesiosaurs in the angle between palatine and transversum. The usual bones are frequently distinct in the lower jaw.

In the CHELONIANs the cranial cavity extends forward between the eyes and the mesethmoidal cartilage largely persists in the adult. Although the bones

are comparatively few, the skull is primitive and can only be derived from that of the cotylosaurs. The bones are firmly united, but the sutures are evident (fig. 101). The basioccipital is usually excluded from the foramen magnum, and it and the exoccipitals participate in the tripartite occipital condyle. The supraoccipital is often prolonged into an occipital spine and is fused with the epiotics. The basisphenoid is present, but pre-, ali- and orbitosphenoids are not ossified, a descending plate of the parietal taking the place of the alisphenoid. The pterygoids meet the basisphenoid and may extend to the basioccipital. No ectopterygoid is present. The monimostylic quadrate is large and expanded laterally to support the tympanic membrane, and notched or perforate behind for the columella.

In the most primitive chelonians a complete false roof is formed by the expanded postfrontals, parietals and squamosals. In most of the species the recession of the parietals and squamosals causes a large gap, bounded in front by postfrontal and jugal and exposing the otic bones. Laterally this gap is

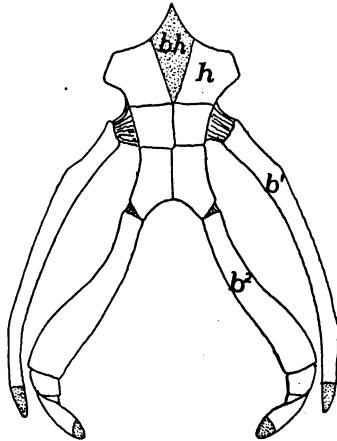


FIG. 102.—Hyoid apparatus of *Trionyx*. b^1 , b^2 , first and second branchial arches; bh , basihyal (copula); h , reduced hyoid; cartilage dotted.

limited by an arcade of squamosal and quadratojugal, but the latter may be reduced or (*Cistudo*) absent. In front of the frontals are a pair of bones, which bound the single naris behind. These occupy the position of lacrimals, nasals and prefrontals, and are called by the latter name. The premaxillaries are usually fused; the maxillæ have broad palatal processes and trenchant margins. They, together with the zygomatics, form the lower border of the orbit.

The vomer is a single vertical plate separating the two choanæ. The palatines, which bound the choanæ behind, are broad and are firmly united to pterygoids and basisphenoid. A parasphenoid is known only in *Dermochelys*. In the lower jaw the bones are often fused, the two halves being united. Again the bones may be distinct, the splenial being the least constant element. The hyoid apparatus consists of a cartilaginous copula and two pairs of cornua which do not reach the cranium.

ICHTHYOSAURS have a short temporal region, but elongate nasals and premaxillaries form a long rostrum. There is a large supratemporal fossa and enormous orbits, bounded above by pre- and postfrontals, below by an elongate zygomatic, and containing a sclerotic ring. The nares are just in front of the

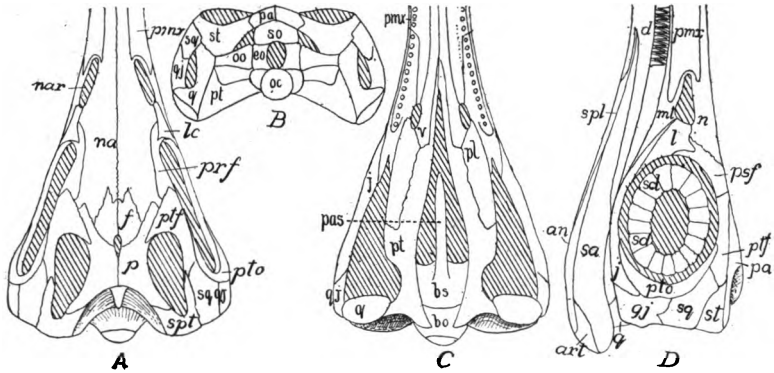


FIG. 103.—Dorsal (A), posterior (B), ventral (C), and lateral (D) views of the skull of *Ichthyosaurus longifrons*, after Woodward, nar, naris; pas, parasphenoid; pmx, premaxilla; ptf, postfrontal; pto, postorbital, an, angular; art, articular; bo, basioccipital; bs, basisphenoid; eo, exoccipital; f, frontal; j, zygomatic (jugal); l, lc, lacrimal; ml, maxillary; n, na nasal; nar, naris; oc, occipital condyle; oo, opisthotic; p, parietal; pas, parasphenoid; pl, palatine; pmx, premaxillary; prf, psf, prefrontal; pt, pterygoid; ptf, postfrontal; pto, postorbital; q, quadrate; qj, quadratojugal; sa, surangular; scl, sclerotics; spl, splenial; spl, supratemporal; sq, squamosal; st, supratemporal.

orbits and the parietal foramen is at the junction of frontals and parietals. All four occipitalia bound the foramen magnum; the basisphenoid is short, the presphenoid long; and the pterygoids are separated in front by the vomers, leaving large pterygoid vacuities. The choanæ are far forward. Teeth (some-

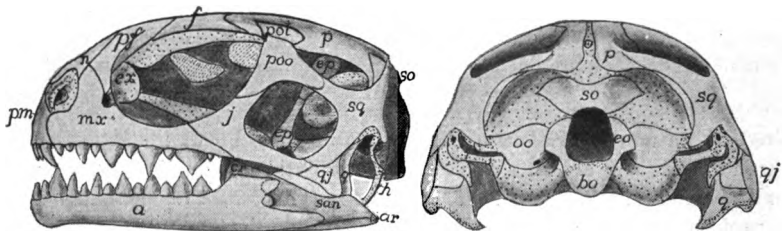


FIG. 104.—Side and posterior views of skull of young *Sphenodon*, after Howes and Swinnerton. Compare with fig. 76. Cartilage dotted; a, dentary; ar, articulate; bo, basioccipital; cr, coronoid; eo, exoccipital; ep, epipterygoid; ex, extranasal; f, frontal; h, hyoid; j, (jugal) zygomatic; mx, maxillary; n, nasal; oo, opisthotic; p, parietal; pf, prefrontal; pm, premaxillary; pos, postfrontal; poo, postorbital; q, quadrate; qj, quadratojugal; so, supraoccipital; sq, squamosal.

times absent) occur in grooves. The lower jaw has five or six distinct bones, and a rib-like hyoid has been found in some species.

The only living RHYNCHOCEPHALIAN is *Sphenodon* (*Hatteria*) of New Zealand. It is lizard-like, but its skull (figs. 76, 104) differs in the three temporal

fossæ, the infratemporal arcade being osseous as in no lizard. Then the quadrate is ankylosed to pterygoid, squamosal and quadratojugal. Premaxillæ, maxillæ and palatines bear teeth; an epipterygoid is present and the lower margin of the orbit is formed by the maxillary. In the extinct genera the zygomatic may bound the orbit below (*Palaeohatteria*), and the vomer may bear teeth.

DINOSAURS have both supra- and infratemporal fossæ and frequently a pre-orbital vacuity as well. The rostral and prefrontal bones have been mentioned (p. 96). The palatal region recalls that of *Sphenodon*, except that the teeth, in grooves or sockets, never occur on the palatines. There are such variations in the skulls that few general statements can be made.

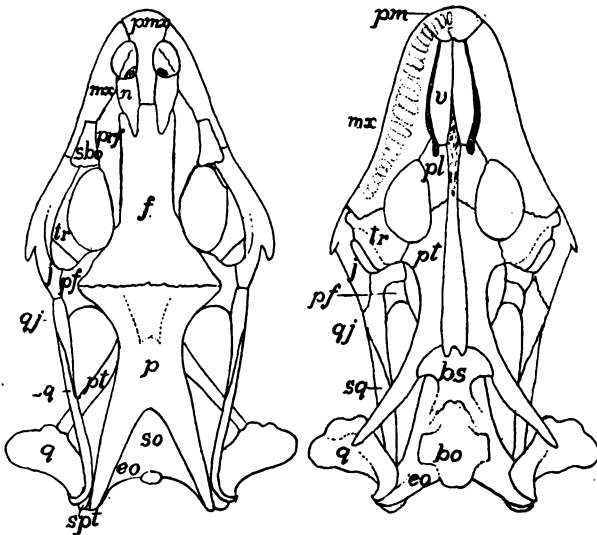


FIG. 105.—Skull of *Gerrhonotus imbricatus*, after Siebenrock. *bo*, basioccipital; *bs*, basisphenoid; *eo*, exoccipital; *f*, frontal; *mx*, maxillary; *n*, nasal; *p*, parietal; *pf*, postfrontal; *pl*, palatine; *pm*, *pmx*, premaxillary; *prf*, prefrontal; *pt*, pterygoid; *q*, quadrate; *qj*, quadratojugal; *sbo*, supraocular; *so*, supraoccipital; *spt*, supratemporal; *sq*, squamosal; *tr*, transversum; *v*, vomer.

Statements which will apply to all SQUAMATA are few. Except in chamæleons the quadrate is movable, a quadratojugal is lacking, the boundary of the infratemporal fossa being completed by ligament. The external nares are separate, there are large vacuities in the floor of the skull and the choanæ are forward. An ectopterygoid occurs except in the typhlopids and all four occipitalia bound the foramen magnum.

The chondrocranium of the LIZARDS (fig. 70), while much like the general type of tropibasic, is very light and is fenestrated to an extent not seen in the ichthyopsids. Among the peculiarities of the adult skull (fig. 105) are the fusion of exoccipital and opisthotic to form a 'parotic process' which, together with the squamosal, supports the quadrate. There is a looseness of connexion of the front of the skull with the occipito-sphenoidal portion, these parts moving on

each other. The hyoid apparatus bears two cornua which either end freely in the neck or may reach the parotic process (fig. 203).

In the fossil *PYTHONOMORPHS* the striking features are the large supratemporal fossæ, the quadrate recalling that of chelonians; and the joint in the lower jaw, between dentary and angular regions, allowing the jaw to bend on itself.

The *OPHIDIA* (snakes) lack parotic process, parietal foramen, temporal arcades and epipterygoid, and have the squamosal excluded from the cranial wall. The attachment of the visceral skeleton to the cranium is loose, the pterygoid being connected to the other parts by a long bar, consisting of squamosal and quadrate behind, and by transversum and palatine in front, features

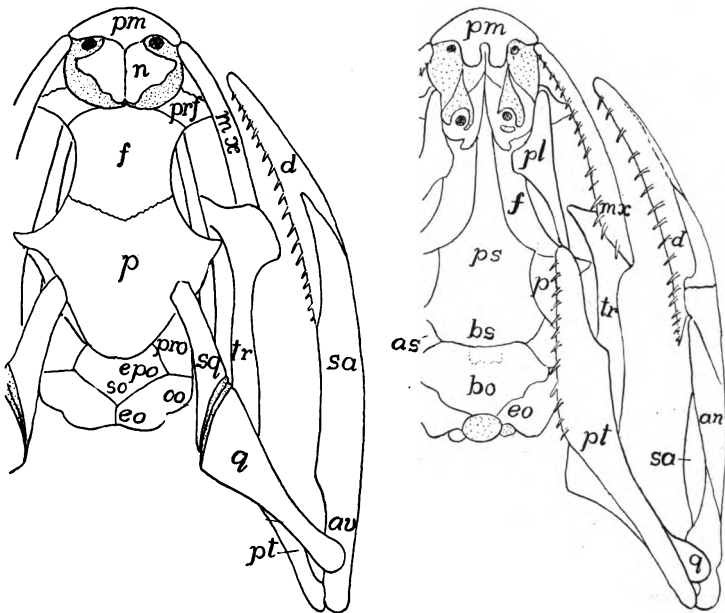


FIG. 106.—Skull of snake, *Tropidonotus*, after W. K. Parker. *an*, angular; *av*, articular; *bo*, basioccipital; *bs*, basisphenoid; *d*, dentary; *eo*, exoccipital; *epo*, epiotic; *f*, frontal; *mx*, maxillary; *n*, nasal; *oo*, opisthotic; *p*, parietal; *pl*, palatine; *pm*, premaxillary; *pro*, prootic; *ps*, parasphenoid; *pt*, pterygoid; *q*, quadrate; *sa*, surangulare; *so*, supraoccipital; *sq*, squamosal; *tr*, transversum.

related to the great distensibility of the jaws. In the poisonous serpents the poison fangs are either permanently erect, or they fold back when the mouth is closed. In the latter the fangs are supported on the maxillaries, which are moved by a rod formed of quadrate, pterygoid and ectopterygoid. In the lower jaw distensibility is provided for by the elastic ligament connecting the two halves in front. Some species have remnants of the hyoid apparatus, but occasionally all are lost in the adult.

When the whole series of *CROCODILLA*, recent and extinct, is considered, the range of variation in the skull is considerable. In all, supra- and infratemporal fossæ are present, the quadrate is immovable, there is more or less of a secondary

palate, no parietal foramen, and the thecodont teeth are confined to the margins of the jaws. In the complete series the gradual change of position of the choanæ can be traced from the oldest, in which they are beside the vomers; then in the mesosuchia the palatines meet in the middle line, carrying the choanæ back as a single opening behind these bones; while in the recent species the pterygoids have also met, so that the choanæ are between them and the basisphenoid.

Among the recent species (fig. 107) the basioccipital is excluded from the foramen magnum, pre- and orbitosphenoids are imperfectly ossified, the nasals are long and the premaxillaries short so that the nares are far in front; parietals and usually the frontals are fused in the middle line. There are vacuities in both walls of the lower jaw, which is also pneumatic.

Although there is no phylogenetic relation between the two, the skull of the PTEROSAURS is very bird-like in its length and in having its axis at right angles

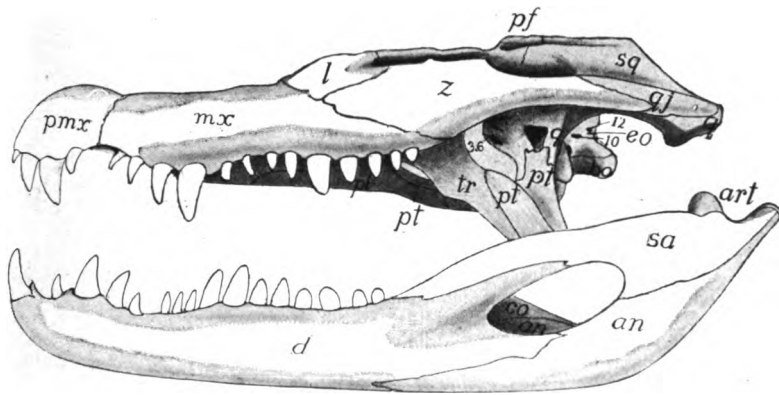


FIG. 107.—Skull of *Caiman latirostris*, based on a figure by Reynolds; the irregularities of the surface omitted. *an*, angular; *art*, articular; *co*, coronoid; *d*, dentary; *eo*, exoccipital; *l*, lacrimal; *mx*, maxillary; *pf*, postfrontal; *pl*, palatine; *pmx*, premaxillary; *pt*, pterygoid; *q*, quadrate; *qj*, quadratojugal; *sa*, surangular; *sq*, squamosal; *tr*, transversum; *z*, zygomatic.

to that of the body, while the elongate premaxillæ form a bird-like beak. The sutures between the bones are largely obliterated in the adult and the brain cavity recalls that of birds. The resemblances are heightened in some by the lack of teeth, in others they are in sockets. Both supra- and infratemporal fossæ are present, as well as a large preorbital vacuity, sometimes united with the naris. Squamosal and quadrate are inclined forward so that the hinge of the jaw is often beneath the orbit. There is no parietal foramen and all of the bones of the jaw are fused, including those of the two halves.

AVES.—The skull of birds is similar in many respects to that of lizards. The chondrocranium (fig. 108) arises as two distinct parts, pre- and perichordal, which, on account of the great head flexure, are at an angle of 100° to each other, later increased to 160° , which persists through life. There are three (or four?) occipital vertebræ behind the ear, the last being the most prominent, and there is a small synotic tectum. From the first the otic capsules are continuous with the basal plate, and the fenestra vestibuli is formed later

by resorption of the cartilage. The trabeculæ are at first distinct from each other as well as from the perichordal part; later they fuse in front of the hypophysis to give rise to the base of the interorbital septum. In *Tinnunculus* the ethmoid plate arises early as an intertrabecular mass, from which, later, the dorsal part of the interorbital septum arises as a backward growth of cartilage.

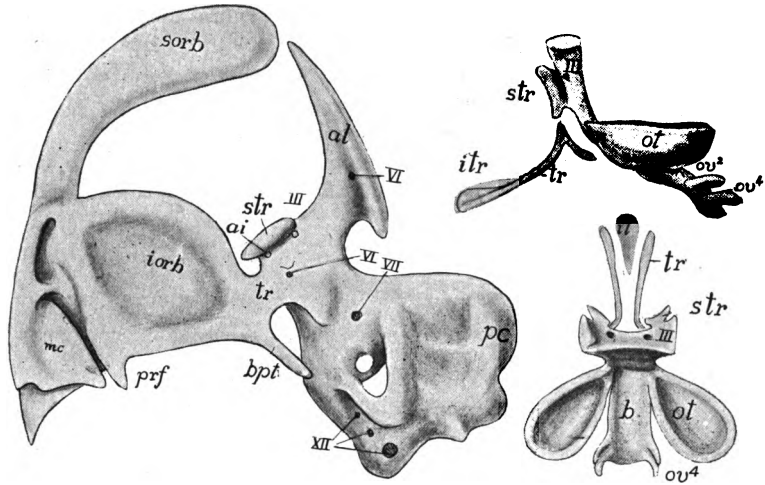


FIG. 108.—Earlier and later stages of skull of bird (*Tinnunculus*) after Suschkin. *al*, alisphenoid cartilage; *ai*, foramen for internal ophthalmic artery; *b*, basal plate; *bpt*, basipterygoid; *ec*, external semicircular canal; *hm*, 'hyomandibular'; *iorb*, interorbital plate; *itr*, intertrabecula; *mc*, middle concha of nose; *ot*, octi capsule; *ov*, occipital vertebra; *pc*, posterior semicircular canal; *sorb*, supraorbital; *str*, supratrabecula; *tr*, trabecula.

Large alisphenoid cartilages are connected with the otic capsules. The nasal capsules are complicated and later give rise to several centres of ossification. The quadrate is free from the rest of the cranium (streptostylic) and its pterygoid process, the homologue of the pterygoid cartilage in other groups, is greatly reduced. The other visceral arches are much as in the adult (*infra*).

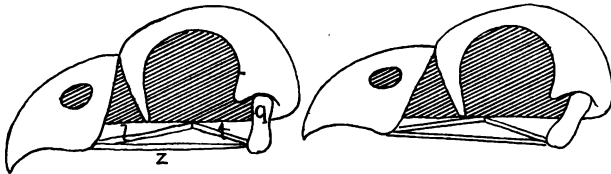


FIG. 109.—Diagram (after Boas) of the movement of the upper jaw of birds. *l*, palatine; *t*, pterygoid; *z*, zygomatic arcade.

The bones are lighter than those of reptiles and are often pneumatic, that is, are penetrated with canals connected with the respiratory system. The brain cavity is larger than in reptiles; sutures between the bones largely disappear in the adult, and the single occipital condyle (mostly basioccipital) is on the floor of

the skull so that the axis of the skull is at right angles to that of the body. There is only a single temporal fossa, bounded laterally by an arcade of zygomatic and quadratojugal, connecting quadrate and maxillary. There is a preorbital vacuity; and the nares may have the posterior margin rounded (**holorhinal**) or slit-like (**schizorhinal**). The premaxillaries are fused and sclerotic bones are common.

A peculiarity of the ventral surface is the union of the anterior part of the parasphenoid to the basisphenoid to form a 'rostrum sphenoidale' which projects forward in the middle line. The rest of the parasphenoid forms a 'basitemporal plate' below the basisphenoid and basioccipital. Dorsal to the rostrum is a small presphenoid (sometimes lacking in the adult) to which the orbitosphenoids are at-

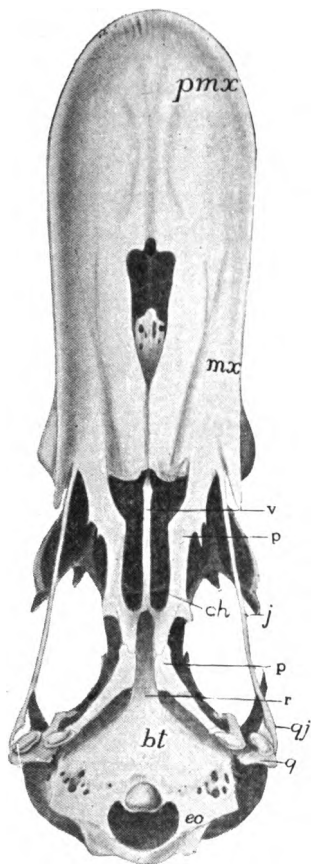


FIG. 110.—Ventral view of skull of a duck; *bt*, basitemporal plate; *ch*, choana; *eo*, exoccipital; *j*, zygomatic (jugal); *mx*, maxillary; *p*, palatine; *pmx*, premaxillary; *pt*, pterygoid; *q*, quadrate; *qj*, quadratojugal; *r*, rostrum; *v*, vomer.

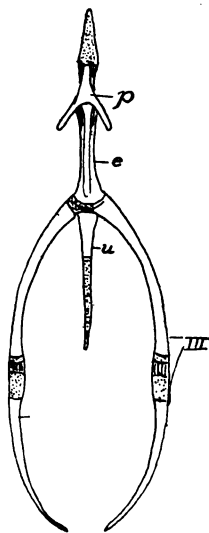


FIG. 111.—Hyoid of hen, after Parker. *e*, entoglossal; *p*, paraglossal; *u*, urohyal; *III*, posterior cornua.

tached as alæ, while the alisphenoids become similar wings to the basisphenoid. Ectethmoids are connected with the mesethmoid; they are sometimes large, appearing ('prefrontals') on the top of the skull. Epi- and ectopterygoids are lacking. The pterygoids, here membrane bones, extend from the quadrates to the palatines, and the two either slide along the rostrum or the vomers intervene. This, together with the hinging of the front part of the skull upon the rest, forms a mechanism by which the upper jaw is raised

when the mouth is opened, the temporal arcade aiding in the motion (fig. 109). The vomers may be paired; usually they form a thin vertical plate between the anterior ends of the pterygoids; occasionally they disappear. The choanæ are between the palatines and vomers. Some birds have an 'os uncinatum,' a small bone connecting the lacrimal with the palatine or zygomatic bar. All of the bones enumerated on page 73 may appear in the development of the lower jaw.

Teeth occur only in a few fossil birds, where they are implanted in sockets; several species are known to have a dental ridge in the embryo (see Development

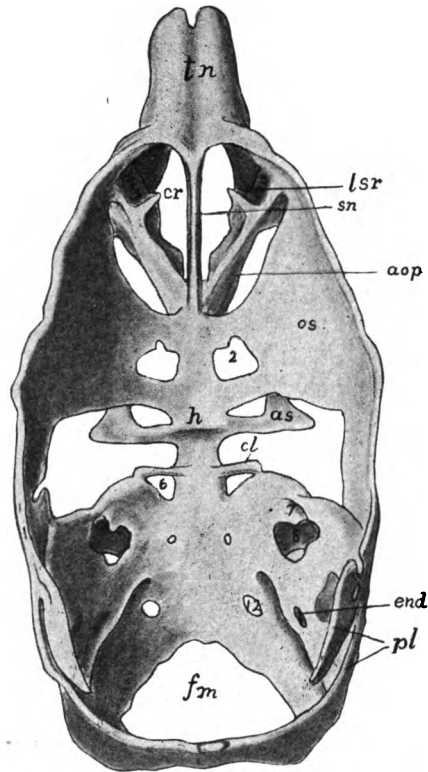


FIG. 112.—Chondrocranium of a pig, after Mead. *as*, alisphenoid; *cl*, posterior clinoid process; *cr*, fenestra cribrosa; *end*, foramen for endolymph duct; *fm*, foramen magnum; *h*, fossa hypophyseos; *lsr*, lateral superior recess; *os*, orbitosphenoid; *pl*, parietal lamina; *sn*, septum nasi; *tn*, tectum nasi; 2-12, exits of nerves.

of Teeth). The hyoid apparatus (fig. 111) consists of a pair of cornua (first branchials) sometimes extremely long, connected by the hyoid copula (os entoglossum), behind which is a second copula (urohyal), while in front of the entoglossum is a 'paraglossal' element with a pair of small cornua.

The palatal structures have considerable importance in classification. All living birds can be arranged in two groups. In the 'dromæognathous' group the palatines and pterygoids do not articulate with the rostrum, the vomers

usually intervening. In the 'euornithes' the articulation occurs. The latter are subdivided into the *desmognathous* forms where the vomer is small or wanting, and the maxillopalatines meet in the middle line; the *schizognathous* in which the maxillopalatines do not meet the vomer or each other; the *segitognathous*, like the last except that the vomer is broad and truncate; and the *saurognathous* with delicate, rod-like vomers and maxillopalatines scarcely extending inward from the maxillaries.

The chondrocranium of the MAMMALS has several peculiarities (fig. 112). There are four occipital vertebræ, the last only with a complete vertebral character, all eventually fusing with the synotic tectum. The dorsal part of the otic capsule chondrifies first, owing to the late development of the cochlear part of the ear in the lower half; and the capsules themselves have their axes inclined, so that the exit of the seventh nerve is on the anterior rather than on the lateral

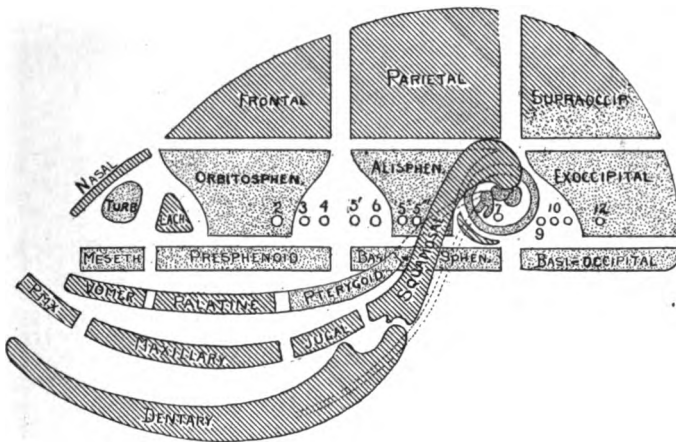


FIG. 113.—Diagram of the bones of the mammalian skull, altered from Flower. Cartilage bones dotted, membrane bones lined; 2-12, nerve exits.

face. The trabeculæ soon join the basal plate, and from their sellar part an alary process is given off on either side which extends upward to join an alisphenoid (*ala temporalis*) which chondrifies separately, but soon joins the otic capsule above, leaving between them the foramen ovale for the third branch of the fifth nerve, the other branches passing forward over the ala and then between it and the orbitosphenoid (*ala orbitalis*) through the sphenoidal fissure (foramen lacerum anterior). The ala orbitalis joins the trabecula by two processes, bar and processes sometimes forming a reduced interorbital septum. Later a marginal band (*tænia marginalis*) extends back from the orbitosphenoid to a cartilage plate developed on the otic capsule. The ethmoid parts are complicated, consisting of the two nasal capsules, the septum between them, and, on the inside, coiled turbinal cartilages to support the olfactory membrane.

Some of the visceral arches have been mentioned in speaking of the ear bones (p. 80). The pterygoid cartilage is apparently lacking, and there is nothing that can be interpreted as a quadrate except the incus. Meckel's cartilage extends forward from the incus to the tip of the jaw. In the procartilage stage the

hyoid is continuous with the stapes; later it joins the otic capsule behind the fenestra vestibuli, while ventrally it joins its fellow and is connected with the first branchial arch by a median cartilage, probably the copula.

In the adult the so-called facial bones are more closely related to the cranium than in the lower groups, and distinct bones are fewer than in lower vertebrates, the reduction being due in part to actual loss, in part to the fusion of elements which elsewhere remain distinct. The obliteration of sutures has gone farther in the monotremes and some of the carnivores and apes than elsewhere. Connected with the loss of bones is the absence of the supratemporal arcade, but the infratemporal bar consisting of processes from the squamosal and zygomatic (jugal or malar) is always present, bounding the single temporal fossa. This may be separated from the orbit by a bar formed by zygomatic and frontal, or the bar may be incomplete or absent so that orbit and fossa communicate.

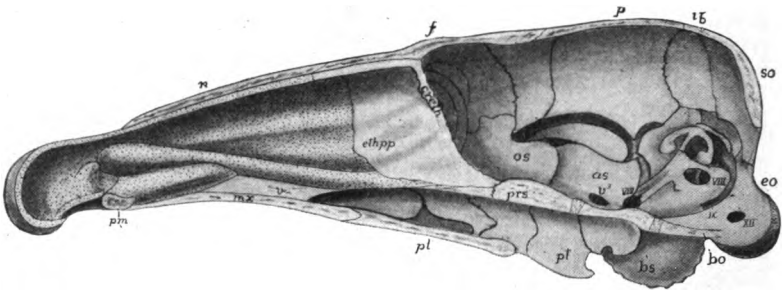


FIG. 114.—Median section of skull of young *Erinaceus*, after Parker. *as*, alisphenoid; *bo*, basioccipital; *bs*, otic bulla; *creth*, cribiform plate of ethmoid; *ethpp*, perpendicular plate of ethmoid; *f*, frontal; *ip*, interparietal; *mx*, maxillary; *n*, nasal; *os*, orbitosphenoid; *pl*, palatine; *pm*, premaxillary; *prs*, presphenoid; *pt*, pterygoid; *so*, supraoccipital; *v*, vomer; *V¹-XII*, nerve exits; cartilage dotted.

Usually the bones fuse in such a way that the complexes named on page 74 are readily recognized. The occipitalia are usually united into a single occipital bone, though the sutures between them may persist for some time. The basioccipital forms the so-called basilar process, while the exoccipitals bear the two occipital condyles for articulation with the atlas. The exoccipitals may also bear strong, ventrally directed, paramastoid (**paroccipital**) processes. The membranous interparietal is sometimes distinct, sometimes fused to the supraoccipital, though it may unite with the parietals.

The sphenoidalia form the sphenoid bone of human anatomy. Basi- and presphenoid form a 'body' from which two pairs of 'wings' arise, the alisphenoids being the greater, the orbitosphenoids the lesser wings. A pair of pterygoid processes are given off from the ventral side of the body and a part of these in some cases persist as distinct pterygoid bones, but apparently are not homologous with some of the elements of the same name in the lower vertebrates since they are membrane bones. The equivalents of the pterygoids of the non-mammals occur in the monotremes. A second pair of membrane bones, the **intertemporals**, also belong to the sphenoid complex, fusing at an early date with the dorsal margin of the alisphenoids.

The ethmoid complex consists of a mesethmoid which ossifies in the septum between the nasal organs, and an ectethmoid in the outer wall of each nasal capsule. Mes- and ectethmoids are distinct for a time, the olfactory nerve passing between them. Later bony strands passing between the nerve fibres unite them, producing a perforated **cribiform plate**, characteristic of the mammals. The part of the mesethmoid projecting above the cribiform plates is the **cristi galli**, below them is the **perpendicular plate**. Two other centres in the lateral wall of each capsule give rise to coiled bones (**inferior and sphenoidal turbinal**) on which the olfactory membrane is spread, while two other turbinals (**superior and middle**) arise from the ectethmoid. A few mammals have in addition, a **prenasal bone**, developed in the septum in front of the mesethmoid.

The temporal complex consists of squamosal, otic bones and tympanic. On the ventral side of the squamosal is the **glenoid fossa** for the articulation of the lower jaw; in front the bone gives off a **zygomatic process** for articulation with a similar process of the zygomatic (malar) bone, the two forming the arcade bounding the temporal fossa. The tympanic (apparently the angulare of the lower vertebrates) curves below the auditory meatus, (fig. 8o) joining the squamosal on either side. In many forms it expands to form a large capsule, the **auditory bulla**. The otic bones (it is said that there are six centres of ossification in the otic capsule) unite early to form a single **petrosal bone**, which, in turn (cetacean excepted) fuses with squamosal to form the **temporal bone**. Later, the posterior part of the otic region expands to form the **mastoid process**, while the upper part of the hyoid, fused to the capsule, forms a **styloid process**.

On account of the great size of the brain some parts of the skull are changed in position. Thus the petrosal, instead of forming part of the side wall, is carried to the floor of the brain cavity and the squamosal forms part of the lateral wall. The roof of the brain cavity is largely formed by parietals and frontals. (In some whales, denticetes, the supraoccipital and interparietal extend to the frontal, preventing the parietals from meeting.) The frontals may be distinct or they may fuse. In many ungulates they bear horns or antlers. In cattle, antelopes, sheep and goats (cavicornia) a strong bony process or horn core is developed on each frontal, and this is covered by a cornified epidermis and persists through life. The antlers of the deer differ from horns. Each year there is an outgrowth of bony material, covered by a richly vascular skin, from each frontal bone. This grows with remarkable rapidity, and when its full extent is reached, the skin ('velvet') is lost, leaving the core alone. After about a year resorption takes place at the base so that the antler is soon lost, to be replaced by a similar but larger one in a few weeks.

The nasals lie above and behind the nares. The margin of the upper jaw is formed by premaxillaries, followed by the maxillaries which ossify from several centres, difficult to homologize with distinct bones in the lower vertebrates. The inferior turbinals fuse to the medial surfaces of the maxillaries. Premaxillaries and maxillaries may fuse or they may remain distinct. They have broad palatine processes on the oral surface, these meeting in the middle line and forming the anterior part of the hard palate, with frequently one or two **incisive foramina** for the passage of the nasopalatine nerve between them. The choanæ are usually behind the palatine bones which form the rest of the

hard palate, but in some edentates and whales the pterygoids form part of the partition between the narial passages and the mouth cavity.

The ingrowth of the hard palate has forced the vomer from the roof of the mouth to a position just ventral to the anterior part of the cartilage of the nasal septum. In the monotremes there is a 'dumb-bell bone' in front of the vomer (p. 77). A lacrimal bone always occurs at the inner side of the orbit and the zygomatic forms the external wall of that cavity.

The lower jaw articulates directly with the squamosal without the intervention of a quadrate (see Ear Bones, p. 80). Its halves may unite in front by ligament or by complete ankylosis. It is usually described as consisting of

a pair of dentaries, but there are several centres of ossification and a splenial and possibly a coronoid element may be recognized. The angulare is apparently the tympanic, while the articulare of lower vertebrates is the malleus. A remarkable feature in development is an enormous cartilage at the posterior angle of the jaw, the dorsal side of which forms the condyle for articulation with the glenoid fossa.

Its homologies are very uncertain.

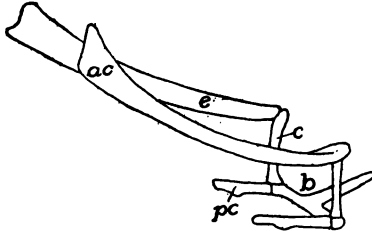


FIG. 115.—Hyoid of rhinoceros (*Atelodus*). *ac*, anterior cornu; *b*, body; *c*, ceratohyal; *e*, epihyal; *pc*, posterior cornua (thyrohyal).

The hyoid apparatus varies. As described above, the hyoid is connected above with the otic region, below with the first branchial. The part connected with the otic capsule forms the styloid process (p. 109), while the rest may ossify as epi-, cerato-, and hypohyals, or a part may change to a stylohyal ligament, connecting the ventral parts with the skull. The hyoid of the adult (fig. 115) consists of the copula forming the body, a part of the hyoid the anterior cornua, while the first branchial arch (of which at most but one or two 'thyrohyal' elements are formed) give rise to the posterior cornua. These are connected by ligament with the greatly modified posterior branchial arches, described in connexion with the larynx (see respiratory organs).

Appendicular Skeleton

The appendages fall in two categories, the median or *azygos* (median fins) found only in aquatic vertebrates, and the paired appendages, which (cyclostomes excepted) are found in every class, although here and there individual species or genera may lack them. Both kinds have an internal skeleton. Opinions differ as to the origin of these appendages. The two most prominent views are given below.

According to one view the two types have no relation to each other. The paired appendages are derived from gill septa, all traces of which are otherwise lost from these somites. The girdles which support the appendages are modified gill arches, while the skeleton of the appendage itself is derived from the

radialia which support the gills, one radial forming an axis, the adjacent radialia being arranged on either side of this, and carried outward from the arch by the growth of the septum to form the body of the appendage (fig. 133). A somewhat similar view is that the appendage itself is a modification of an external gill, such as is found in larval amphibians.

Another view supposes an ancestor with two pairs of longitudinal folds running the length of the body behind the head, each fold supported by a series of skeletal rods (fig. 116). With farther development the upper folds on either side migrated dorsally until the two met and fused in the middle line of the back, thus producing a continuous dorsal fin. The ventral folds migrated

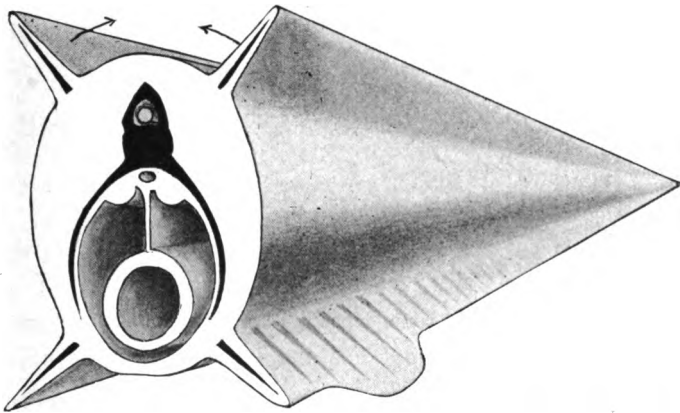


FIG. 116.—Diagram of the origin of median and paired appendages from lateral fin folds.

downward in the same way, eventually uniting behind the vent, but that opening prevented their meeting farther forward. From the fused part behind the vent the anal and the lower part of the caudal fins were formed, while the paired appendages are differentiations of the preanal parts of the ventral longitudinal folds.

It may be said that in development there is no such double origin of the dorsal fin. In several sharks the paired fins arise from continuous folds, while in the Japanese gold fish the anal fins are frequently paired and the caudal has a double condition below, such as would result from the failure of folds to unite in this region. In criticism of the gill-arch theory it may be said that the supports of the paired appendages arise outside of the body musculature, while the visceral arches (p. 73) are internal.

THE MEDIAN APPENDAGES

The median or azygos appendages always have the form of fins, and may be dorsal, terminal (caudal) or ventral (anal) in position.

Primitively, and in many species through life, they are continuous, but usually gaps occur during development so that the fins of the adult are separated by intervals from each other. They occur in practically all fishes, in larval and tailed amphibians, and in isolated groups like the ichthyosaurs and whales. In amphibians and higher groups the median fins have no skeleton, but elsewhere it is of cartilage, bone, or a horny substance (elastoidin), the latter being the most constant and occurring in connexion with either of the others.

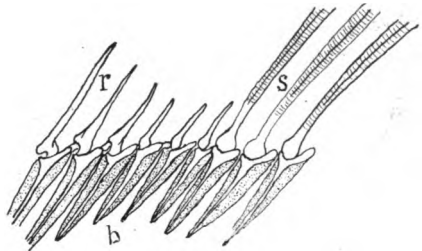


FIG. 117.—Part of skeleton of dorsal fin of perch. *b*, basalia; *r*, radialia; *s*, soft fin rays.

The simplest skeleton (fig. 117) consists of a metameric series of cartilage or osseous bars, each usually divided into a deeper **basale** and a more distal **radiale**, the former frequently articulating with or alternating with the spinous processes of the vertebræ, while the radialia support the fin proper. The elastoidin elements consist of a number of slender rods (**actinotrichia**), outnumbering the somites, and arising from the corium, immediately below the epidermis. Frequently they are united into bundles (soft fin rays, *s*) and they may replace the radialia.

Paired Appendages

The paired appendages are not, as the gill-arch theory would demand, derived from a single somite, but a varying number of segments participate in their formation. Apparently the simplest fin known is that of the extinct shark, *Cladoselache* (fig. 118), in which it is a rounded lobe supported by a number of rods, like the radialia in a median fin. These are attached proximally to a few larger plates, the basalia, the basalia of the two sides being unconnected with each other. Greater growth of the basalia would result in some of them meeting and fusing in the middle line, thus forming a bar across the ventral side

of the body, giving additional support to the fin. Then, to compensate for the rigidity, the basals become jointed on either side, leaving the medial bar with an articular surface on either side for the reduced basalia. The ventral muscles of the fin would find firm attachment to the bar, while the need for a similar attachment for the dorsal muscle results in an extension of the bar dorsally above the articulation of the limb, thus producing the typical girdle. The derivation of the fin of any fish from that of *Cladoselache* is easily imagined, but no satisfactory comparison of the fin with the leg has yet been made.

In the skeleton of the paired appendages the internal supports or **girdles** and the skeleton of the free appendage are to be recognized. Each girdle is an inverted arch crossing the ventral side of the body and extending up on either side above the articulation of the limb. The girdles, as well as the skeleton of the free appendage, are always laid down in cartilage, and in the free appendage, aside from the actinotrichia, no parts of other than cartilaginous origin usually occur. In the girdles membrane bones may be added as will appear below.

In its typical state each girdle consists of three elements, one dorsal and two ventral, all meeting at the point of attachment of the free appendage, and all contributing to the socket (**glenoid fossa, acetabulum**) which receives the basal element of the skeleton of the limb. The limbs themselves are much alike in their general structure, as may be seen from the adjacent diagram.

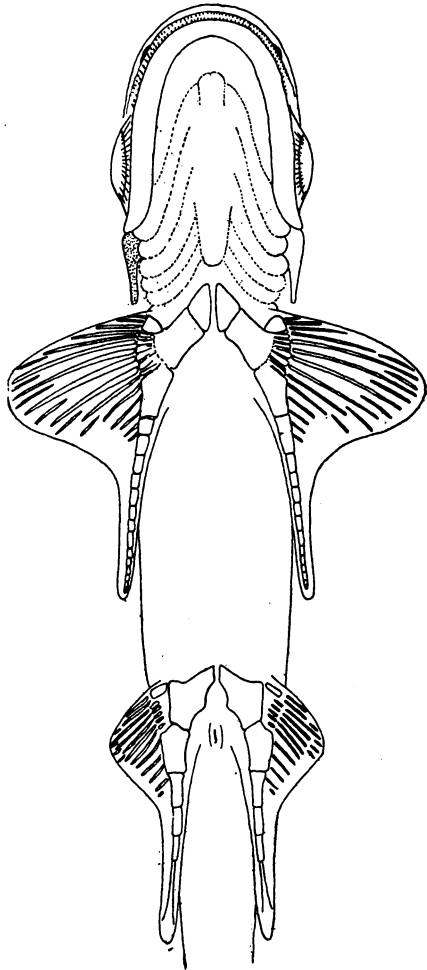


FIG. 118.—Ventral surface of *Cladoselache*, after Jaekel.

The Shoulder Girdle

FISHES.—The pectoral or shoulder girdle in the elasmobranchs is more or less U-shaped, the bottom of the arch crossing the ventral surface between the skin and the peritoneal membrane, this ventral portion being known as the **coracoid region**, which is limited dorsally

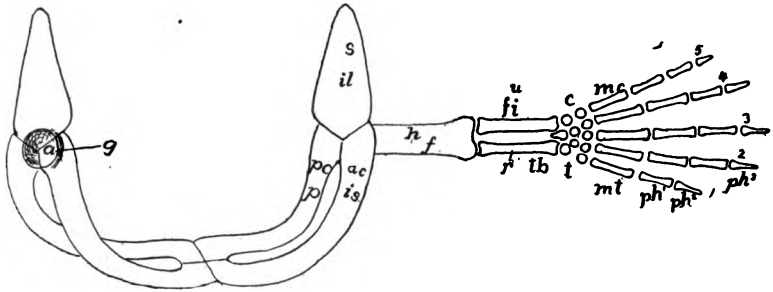


FIG. 119.—Diagram of girdles and appendages from the posterior side; upper letters, fore limb; lower, hind limb. *a*, acetabulum; *c*, carpus; *ac*, coracoid, *f*, femur; *fi*, fibula; *g*, glenoid fossa; *h*, humerus; *il*, ilium; *is*, ischium; *mc*, *mt*, metacarpals, metatarsals; *p*, pubis; *pc*, procoracoid; *ph*¹⁻⁵, phalanges; *r*, radius; *s*, scapula; *t*, tarsus; *tb*, tibia; *u*, ulna; 1-5, digits.

by the point of attachment (glenoid fossa) of the fin. Dorsal to the fossa is the **scapular region**. Not infrequently the dorsal part of the scapular region is segmented from the rest as a separate **supra-**

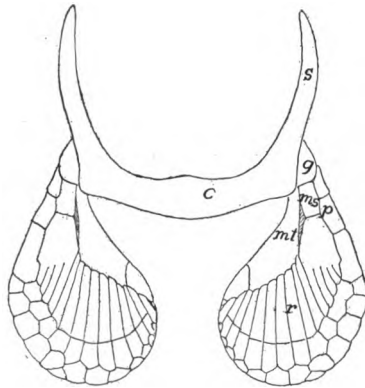


FIG. 120.—Pectoral girdle and cartilaginous fin skeleton of *Scyllium*. *c*, coracoid region; *g*, glenoid surface; *ms*, mesopterygium; *mt*, metapterygium; *p*, propterygium; *r*, radialia; *s*, scapular region.

scapula. The girdle is usually free from the axial skeleton, but in the skates (*raia*) the suprascapula articulates with the adjacent vertebrae.

In the simpler teleostomes (some ganoids, dipnoans) the carti-

luginous girdle is reinforced by membrane bones derived from the skin. Of these there are at least two on either side, a pair of **clavicles** which overlie the coracoid region and meet in the middle line, and lateral to each clavicle and extending to or above the glenoid fossa, is a second bone, the **cleithrum**. In some ganoids (*Polypterus*, fig. 121) the cleithra extend toward the middle line, and a little higher in the scale, meet and take the strains. This assumption of stress by the membrane bones results, in the higher forms, in the separation of the two halves of the cartilaginous girdle.

In the higher ganoids and teleosts the cleithrum has increased greatly, usurping the function of the clavicles, which have conse-

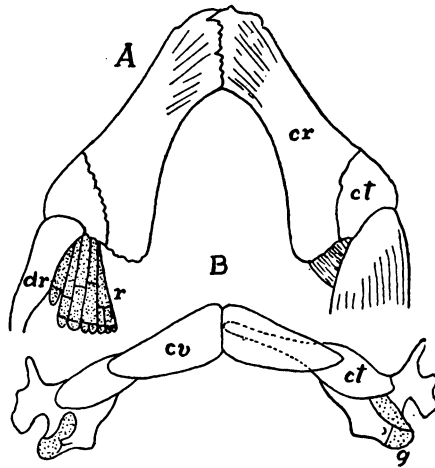


FIG. 121.—Pectoral girdles of (A) *Acipenser* and (B) *Polypterus*, after Gegenbaur. *ct*, cleithrum; *cv*, clavícula; *dr*, dermal rays; *g*, glenoid surface; *r*, cartilaginous radialia.

quently disappeared. Dorsal to the cleithra other membrane bones frequently occur. There may be one or two **supracleithra** (**post- or supratemporals**, fig. 88) which connect the girdle with the skull, and occasionally others as **postclavicle**, **infraclavicle**, etc. As a result of the great development of the cleithra the cartilaginous girdle has been reduced, but it usually has at least two ossifications on either side, a scapula dorsal to the glenoid fossa and a coracoid in the ventral region, these contributing to the support of the appendage.

AMPHIBIA.—In the stegocephals the cartilage has not been preserved and the bones are variously interpreted (fig. 66). The bone meeting the episternum is the clavicle, and lateral to this is an equally slender bone, usually called scapula, but by some the

cleithrum. A large round element is called the coracoid. In the recent amphibians we are on firmer ground. The halves of the girdle develop separately, and the cleithrum is lacking. In urodeles the coracoid region has two processes diverging from the glenoid fossa, an anteriorly directed **procoracoid** and a coracoid proper, directed toward its fellow of the opposite side, the two meeting the sternum behind and overlapping in front. Ossification begins in the neighborhood of the glenoid fossa, the resulting bone being called the scapula, although it invades the coracoid region, the cartilage dorsal to it being the **suprascapula**.

In the toads and allied anura (arcifera) the halves of the girdle overlap as in the urodeles, but the procoracoids extend toward the middle line, each being joined to its coracoid by longitudinal cartilage plate, the **epicoracoid**, leaving a gap between them. With the appearance of bone, scapula and coracoid ossify, while a clavicle

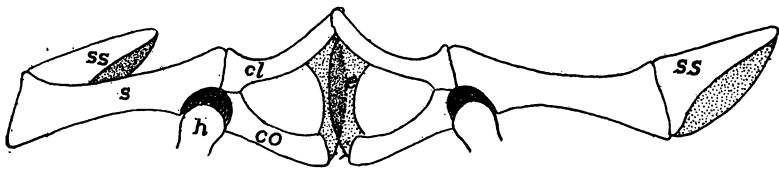


FIG. 122.—Arciferous girdle of *Ceratophrys ornatus*. *cl*, clavicle; *co*, coracoid; *e*, epicoracoid; *h*, head of humerus; *s*, scapula; *ss*, suprascapula; cartilage dotted.

of membranous origin overlies the procoracoid cartilage (fig. 122). In the frogs (firmisternia) the relations are much the same (fig. 63), except that the epicoracoids, instead of overlapping, abut against each other, and the clavicles nearly or quite replace the procoracoid, while sternum and omosternum join the girdle in front and behind. Girdles are lacking in the gymnophiones.

REPTILES.—With the development of a considerable neck in the reptiles the pectoral girdle is removed further from the head; it shows considerable differences in the various groups. In the fossil rhynchocephals it is much as in the stegocephals, except that the scapula is large. In the turtles it occupies a peculiar position, being inside the carapace, *i.e.*, internal to the ribs; but this is explained by the development; the girdle arises in front of the ribs and later sinks to the definitive position. Scapula, procoracoid and coracoid are well developed, the medial ends of the latter two being connected by a cartilaginous epicoracoid. Elsewhere in the reptiles the procoracoid tends to reduction, the clavicle taking its place, though it

is retained in the lizards in a reduced condition (fig. 123). The clavicle in turn is lost in chamæleons and crocodiles, and if present in the chelonians, it is represented by the epiplastron (p. 46), an element of the carapace. The girdles are greatly reduced in the limbless lizards and have vanished in the ophidians.

In the BIRDS (fig. 60) the scapula is a sword-shaped bar overlying the ribs, while the coracoid extends from its junction with the scapula at the glenoid fossa to the anterior end of the sternum. The procoracoid has disappeared. The clavicles of the two sides are

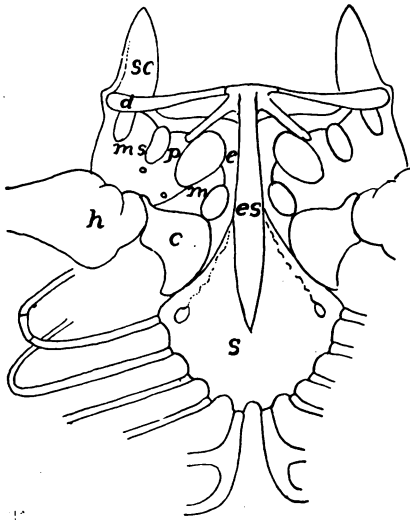


FIG. 123

FIG. 123.—Sternum and pectoral girdle of *Amblyrhynchus*, after Steindacher. *c*, coracoid; *cl*, clavicle; *e*, epicoracoid; *es*, episternum; *h*, humerus; *m*, mesocoracoid; *ms*, mesoscapula; *p*, procoracoid; *sc*, scapula; *s*, sternum.

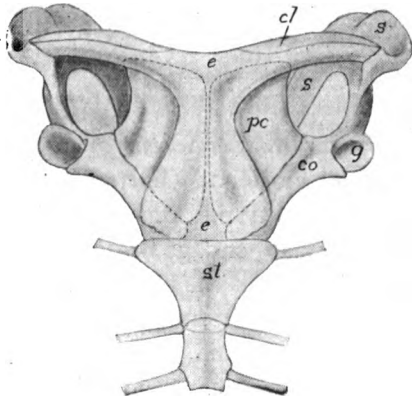


FIG. 124.

FIG. 124.—Shoulder girdle of *Ornithorhynchus*. *cl*, clavicle; *co*, coracoid; *e*, episternum; *g*, glenoid fossa; *pc*, procoracoid; *s*, scapula; *st*, sternum.

united at their medial or ventral ends to form the well-known **furcula** (wishbone) which may articulate with the sternum between the two coracoids, or, with diminishing powers of flight, may end freely below.

MAMMALS.—The shoulder girdle of the monotremes (fig. 124) is strikingly like that of lizards, the coracoids acting as a brace between sternum and glenoid fossa, while the resemblance is strengthened by the presence of the episternum. This same large development of the coracoids occurs in the young of some marsupials, but in the adults, as in the rest of the mammals, the coracoid is greatly

reduced, persisting only as a small projection, the **coracoid process**, ankylosed to the ventral end of the scapula, where it often forms a part of the glenoid fossa. The scapula is always well developed, and in the placental mammals bears a strong crest (**spina scapulæ**) on its external surface, terminating ventrally in an **acromion process**. The clavicle varies with the freedom of motion of the limb. Thus in rodents, insectivores, bats, some marsupials and the higher primates it forms a strong brace between shoulder and sternum. In ungulates, whales, and a few carnivores it has entirely disappeared, while in other mammals it persists as a rudiment without functional value. In development two small elements frequently intervene between the clavicles and the sternum (fig. 62). They are preformed in cartilage but eventually fuse with the sternum. Their homology is very uncertain. They have been called episternalia, suprasternalia, etc.

The Pelvic Girdle (Pelvis)

In its broader features the pelvis (*cf.* fig. 119) is much like the shoulder girdle, and in its full development, may be compared, part by part, with the anterior arch. Thus the **acetabulum** or socket where the appendage is attached, is comparable to the glenoid fossa. Dorsal to this is the **ilium** in the position of the scapula, while ventral and medial to the acetabulum are, on either side, an **os pubis** in front, an **ischium** behind, with a gap (**ischio-pubic fenestra**) between them, just as between coracoid and procoracoid. An important landmark is the point of passage of the obturator nerve through the pelvis. This may have its own (**obturator**) **foramen** through the pubic portion or the foramen may unite with the fenestra, the condition in the mammals, where the common opening is called the obturator foramen.

The phylogenetic history of the pelvis is more clearly indicated than is that of the pectoral girdle, for in many fossil fishes as well as in the sturgeon, there is little advance over *Cladoselache* (p. 113). The basalia of a side have fused to a single basal, often perforated for the obturator nerve, and bearing the radialia on its distal surface. The basalia of the two sides have not met, but there is frequently between them a pair of small cartilage plates, possibly the homologues of the epipubis of the tetrapoda (*infra*). There is no acetabular joint. In the other ganoid and in teleosts there is little advance, aside from ossification of parts, while no epipubic elements occur. A noticeable feature in many acanthopterygians is the forward migration of the

pelvic fins so that they come to lie in front of the pectorals (the old group of 'jugulares').

The elasmobranchs have a true girdle, but without separate elements as it does not pass beyond the cartilage stage. It consists of a continuous ischio-pubic bar, extending from one acetabulum to the other, and usually prolonged dorsally above the acetabulum by an iliac process.

In all fishes the pelvic girdle is free from the vertebral column, but in the tetrapoda, where the limbs have to support the body weight, the girdle becomes connected with the sacrum by the intervention of one or more sacral ribs (p. 63). In the interpretation of some of the pelvic elements there is some uncertainty.

In the stegocephals (fig. 125) ischium and ilium (and usually pubis) were distinct bones with apparently considerable cartilage be-

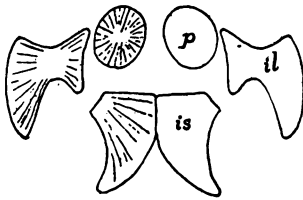


FIG. 125.

FIG. 125.—Pelvis of *Discosaurus*, after Credner. *il*, ilium; *is*, ischium; *p*, pubis.

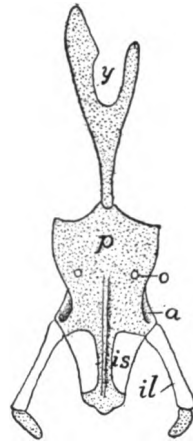


FIG. 126.

FIG. 126.—Ventral view of pelvis and ypsiloid cartilage of *Cryptobranchus*, after Wiedersheim. *a*, acetabulum; *il*, ilium; *is*, ischium; *a*, obturator foramen; *p*, conjoined pubes; *y*, ypsiloid cartilage.

tween them. In the urodeles the two ischio-pubic cartilages are usually united in the median line, but the ossifications vary in extent, the pubic region lagging behind the ischium and being at times indistinguishably fused with it. In some cases there is, as in *Necturus*, an extension of the median cartilage forward in an **epipubic process**, and frequently a **pectineal process** from the antero-lateral of each pubic. An interesting feature is furnished by the **ypsiloid cartilage** (fig. 126) formed independently of the pubis and extending forward in the linea alba through two or three somites. This occurs only in salamanders with functional lungs, where it furnishes attachment for muscles connected with respiration.

In the anura all three pelvic bones are present, and all participate in the formation of the acetabulum. Correlated with the leaping

habits the ilium is very long and the ischio-pubis is strongly compressed, obturator foramen and ischio-pubic fenestra being absent.

Omitting the extinct rhynchocephals, whose pelvis resembles that of the stegocephals, the reptiles have the pelvic bones more solid and distinct than do the ichthyopsida; the ilium is strong, with its dorsal end frequently expanded; the ischio-pubic fenestra is large; and ischium and pubis are united to their fellows directly, or by the intervention of the epipubic cartilage, or its modification, the **ligamentum medium pelvis**. As a rule all three bones meet in the acetabulum and there are large prepubic processes, though these are small in the lizards and are lacking in crocodiles.

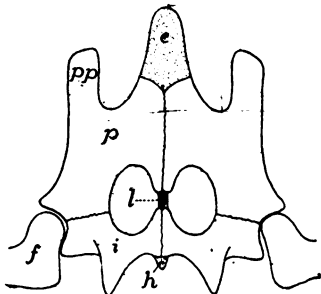


FIG. 127.

FIG. 127.—Pelvis of snapping turtle (*Chelydra*) from below. *e*, epipubis; *f*, femur; *h*, hypoischium; *i*, ischium; *l*, ligamentum medium pelvis; *p*, pubis; *pp*, pectineal process.

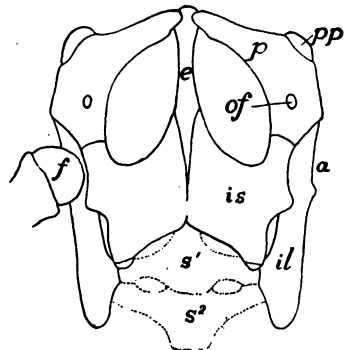


FIG. 128.

FIG. 128.—Pelvis of *Iguana tuberculata*, after Blanchard. *a*, acetabulum; *e*, epipubic cartilage; *f*, femur; *il*, ilium; *is*, ischium; *of*, obturator foramen; *p*, pubis; *pp*, prepubis; *s*, *s*², first and second sacral vertebrae.

Many theriomorphs have the pelvic bones fused much as in mammals. In *Sphenodon* and some turtles the epipubic cartilage bounds the fenestra on the median side, and *Sphenodon* and the plesiosaurs have a separate obturator foramen, but the two are merged in the chelonians. Most lizards have slender pubic bones, perforated by the foramen, and the part of the epipubis between the fenestræ reduced to a ligament, while the posterior part of this, behind the ischium, may ossify as a distinct bone (**os cloacæ** or **hypoischium**). In the footless lizards the pelvis is reduced, being represented in the amphibænans by rudiments of ischium and pubis, while all traces of the pelvis are lost in snakes, except the boas and some opoterodonts. The obturator foramen is very large in the crocodiles, the result of the oblique position of the pubes, which do not unite with each other; each is tipped with cartilage (? separate epipubes). All three bones

meet at the acetabulum which is perforate in recent species. The lower end of the ilium separates as a distinct bone (*pars acetabularis*).

The pelvis of the dinosaurs (fig. 129) has the same great extension of the ilium forward and back as is seen in the birds, and a corresponding increase of the sacrum (p. 59), the result of the partially upright position. The ischia are greatly elongate and are directed backward, being frequently united below. The pubic bones are remarkable in being directed forward and downward and in having strong post-

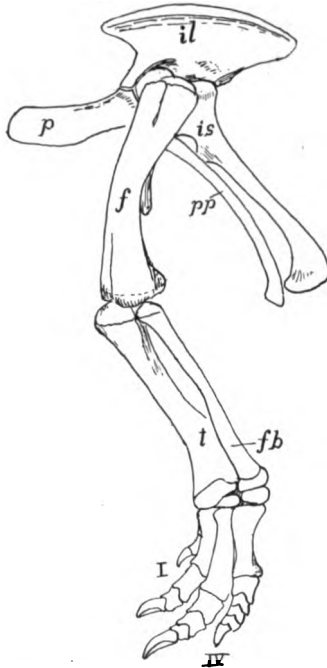


FIG. 129.—Pelvis and hind limb of *Comptosaurus*, after Marsh. *f*, femur; *fb*, fibula; *il*, ilium; *is*, ischium; *p*, pubis; *pp*, postpubis; *t*, tibia; *I-IV*, digits.

pubic processes which are parallel to the ischium. Frequently the ilium gives off an iliac spine near the acetabulum.

The pterodactyls had the same elongate ilium as the dinosaurs, the ischium being fused to it so as to exclude the pubis from the acetabulum, the latter¹ being usually loosely articulated to the ischium and meeting its fellow in the median line below. The pelvic opening was very small. The pelvic bones of the ichthyosaurs were weak, long and slender, and apparently were imbedded in the muscles.

¹ This pubis is sometimes regarded as a prepubis, the ischium being called an ischiopubis.

In recent birds (figs. 56, 60) the pelvic bones are fused. The ilium is greatly elongate and usually fused with the synsacrum (p. 59); ischium and pubis directed backward. The pubes, lying in the position of the postpubes of the dinosaurs, never meet below except in the ostriches. In the embryo (fig. 130), they are at first directed

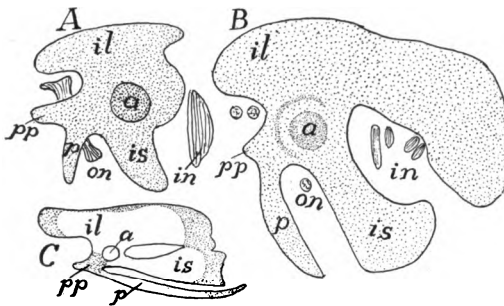


FIG. 130.

FIG. 130.—Development of pelvis of chick, after Miss Johnson. *A*, chick of 6 days. *B*, older; *C*, 20 days; cartilage dotted, bone white. *a*, acetabulum; *il*, ilium; *in*, ischiadic nerves; *is*, ischium; *on*, obturator nerve; *p*, pubis; *pp*, pectineal process.

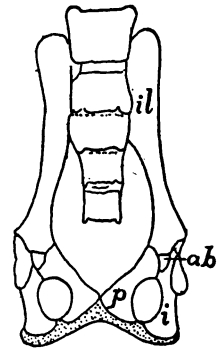


FIG. 131.

FIG. 131.—Pelvis of *Galeopithecus*, after Leche. *ab*, acetabular bone; *i*, ischium; *il*, ilium; *p*, pubis; cartilage dotted.

forward and only attain the final position later. A **pectineal process** arises from the acetabular region and extends forward, simulating the dinosaur pubis.

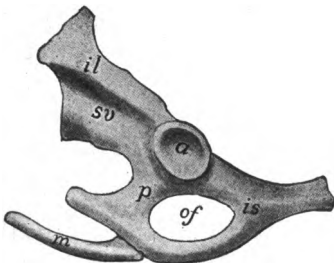


FIG. 132.—Left side of pelvis of duck-bill. *Ornithorhynchus*, *a*, acetabulum; *il*, ilium; *is*, ischium; *m*, marsupial bone; *of*, obturator foramen; *p*, os pubis; *sv*, sacral vertebra.

In the mammals, obturator foramen and ischio-pubic fenestra are united, the opening being bounded on the medial side by processes from ischium and pubis. All three bones may meet in the acetabulum, but more often the extension of ilium and ischium excludes the pubis from the fossa. A peculiarity is the common occurrence of an additional bone (fig. 131, *ab*) in the formation of the acetabulum (**acetabular** or **cotyloid** bone).

This lies between ilium and pubic bone and may fuse with any of the elements. In marsupials and monotremes the interpubic cartilage persists for some time, or through life, but elsewhere it disappears and the elements unite by symphysis.

The same groups of nonplacental mammals are characterized by the presence of **marsupial bones** (fig. 132). These are preformed in cartilage and extend forward from either pubis in the ventral abdominal wall. Their homology is very uncertain; but they are not the ypsiloid of the urodeles (p. 119).

The Free Appendages

These are of two kinds, the paired fins (**ichthyopterygia**) of the fishes and the legs or their modifications (**chiropterygia**) found in all classes of tetrapoda. The former is merely a mechanism for altering the

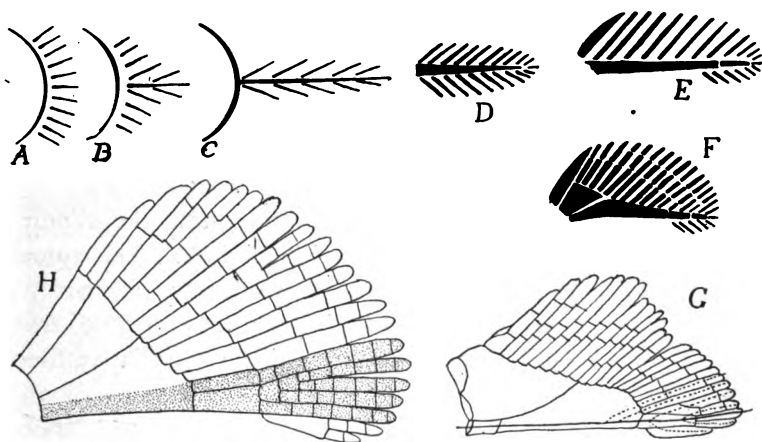


FIG. 133.—Diagrams illustrating theories of origin of appendages. A, B, C, origin of biserial appendage (C) from gill arch (A); D, biserial appendage (archipterygium); E, F, evolution of elasmobranch fin; G, dotted lines indicate parts involved in origin of leg from fin; H, dotted parts show another view of origin of elements of leg.

position of the body in the water, and requires a small amount of flexibility, being moved as a whole. The assumption of terrestrial habits necessitates the support of the body above the ground and its propulsion. Hence the chiropterygium must have a firmer skeleton, with at the same time joints for motion and intrinsic muscles to move the parts on each other. The chiropterygium was undoubtedly derived from the fish fin, but the problem of how the change was made has not been solved. Only paleontology can give the answer.

There are two views as to the origin of the chiropterygium, both based upon the loss of certain parts and the persistence of others in a modified form. One view assumes the persistence of a basal as the framework (humerus or radius) of the upper limb. Two proximal radials as that of the next limb segment, while the skeleton of ankle and foot is derived from a corresponding number of distal

radials on the anterior side of the fin. The 'archipterygial theory' of Gegenbaur assumes a biserial appendage (fig. 134) like that of *Ceratodus* (the 'archipterygium') as the type from which all legs and other fins have been derived, by a shortening of the axis and a loss of radials, chiefly on the preaxial side. The two views are illustrated in the adjacent sketches (fig. 133). No known facts of either embryology or paleontology throw any certain light on the matter.

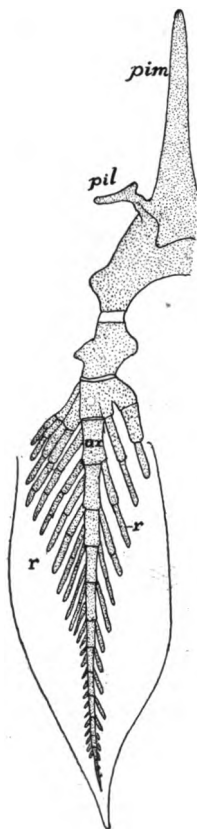


FIG. 134.

FIG. 134.—Pelvic fin and part of girdle of *Ceratodus*, after Davidoff. *a*, axial skeleton of fin; *pil*, iliac process; *pim*, processus impar; *r*, radialia.

Cladoselache (fig. 118) and the lower ganoids have what is apparently the most primitive type of fin with a large number of basalia which support a large number of radialia. From these, as we go upward in the scale, there is a reduction in the number of basalia, either by disappearance or fusion, while the other parts are variously modified. Thus in recent elasmobranchs the characteristic number of basalia is three in the pectoral, two in the pelvic fin. These are known, from in front backward as the **pro-meso-**, and **metapterygium**, the middle one being absent from the hind limb. The numerous radialia are jointed transversely (fig. 120), permitting more flexibility, and these may be arranged entirely on one side of the basalia (uniserial)

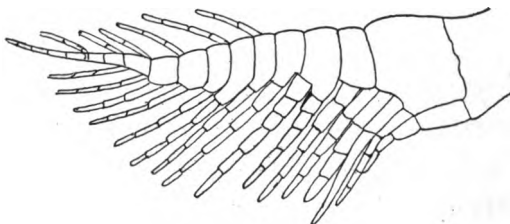


FIG. 135.

FIG. 135.—Skeleton of pectoral fin of *Xenacanthus*, after Fritsch.

or the metapterygium may be prolonged as an axis, and while most of the radialia are on the preaxial side, some may occur on the postaxial side (biserial) as seen in the carboniferous shark, *Xenacanthus* (fig. 135). In the recent species the skeleton of the fin is continued by actinotrichia. In the male elasmobranchs the pelvic fin is divided into two lobes, the medial, the so-called clasper (**mixipterygium**) being the longer and narrower. This is used in

copulation and is supported by the specialized terminal radialis of the metapterygium

In other ganoids and in teleosts the skeletal parts are more or less ossified, the basalia more numerous than in the higher elasmobranchs and are shortened and more closely associated with the girdles, while the numerous radii form most of the skeleton of the fin itself. It is not uncommon for the anterior element of the pectoral fin to form a strong defensive spine, not infrequently connected with a poison gland (fig. 23). In some teleosts, *e.g.*, eels, the pelvic fin may be lacking. The fins of the dipnoi are easily understood by comparison with a biserial fin like that of *Xenacanthus* (fig. 135). The axial part has been elongated and in *Ceratodus* it bears biserial radialis, while in *Protopterus* and *Lepidosiren* only the axis persists.

Embryology tells little as to the primitive condition of the ichthyopterygium, for in the procartilage stage the condensation of mesenchyme for the skeleton of the fin forms a continuum which later becomes broken into the separate parts (fig. 136).

The legs (chiropterygia) of all tetrapoda are essentially alike (fig. 119). Each consists of several regions, comparable in detail with each other. The proximal is the upper arm (**brachium**) or thigh (**femur**) containing a single bone, the **humerus** or **femur** in the fore and hind limb respectively. The next region, the forearm (**antebrachium**) or shank (**crus**), contains two bones, a **radius** or **tibia** on the preaxial and an **ulna** or **fibula** on the postaxial side. Next follows the **podium**, the hand (**manus**) in front, the foot (**pes**) behind, each consisting of three portions. The basal podial region, the wrist (**carpus**) or ankle (**tarsus**) consists of several small bones; the second division (**metapodium**) is the palm (**metacarpus**) or instep (**metatarsus**) and lastly come the fingers or toes (**digits**), each digit consisting of several bones, the **phalanges**. These separate parts are included in the accompanying table, in which the terms given to the separate elements of the wrist and ankle of man are included.

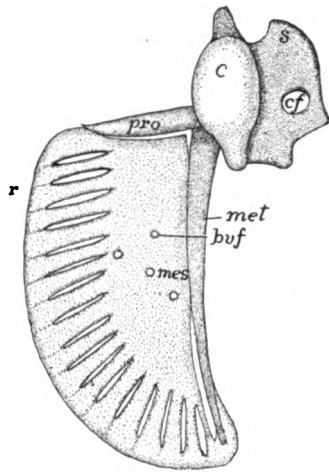


FIG. 136.—Cartilage skeleton of shoulder girdle and left pectoral fin of larval *Polypterus*, after Budgett, *buf*, foramina for blood-vessels; *c*, coracoid; *cf*, coracoid foramen; *mes*, mesopterygium; *met*, metapterygium; *pro*, propterygium; *r*, developing radialis; *s*, scapula.

FORE LIMB (ARM)		HIND LIMB (LEG)	
Upper arm (Brachium)	Humerus = Femur		Thigh
Fore arm (Antebrachium)	Radius = Tibia	Astragalus (Talus)	Shank (Crus)
	Ulna = Fibula		
Basi- podium Wrist (Carpus)	Naviculare (Scaphoid)	Radiale = Tibiale	Basi- podium Ankle (Tarsus)
	Lunatum	Intermedium = Intermedium	
	Triquetrum	Ulnare = Tibiale	
	Pisiforme	Centrale ¹⁺² = Centrale ¹⁺²	
	Multangulum majus (Trapezium)	Carpale ¹ = Tarsale ¹	
	Multangulum minus (Trapezoides)	Carpale ² = Tarsale ²	
	Capitatum	Carpale ³ = Tarsale ³	
	Hamatum	Carpale ⁴ = Tarsale ⁴	
		Carpale ⁵ = Tarsale ⁵	
	Palm (Metapodium)	Metacarpale ¹⁻⁵ = Metatarsale ¹⁻⁵	
Fingers (Phalanges)	Digits ¹⁻⁵ = Digits ¹⁻⁵	(Phalanges)	Toes

The basal podial region, which is nearly typical in some reptiles, urodeles (fig. 137) and man, consists of three rows of bones, a proximal of three bones, a **radiale** or **tibiale** on the anterior side, an **ulnare** or **fibulare** on the other, and an **intermedium** between them. The distal row consists of five **carpales** or **tarsales**, numbered from the anterior side.

The third row is composed of one or two **centrales** between the other rows. The **metapodials** and the **digits**, also numbered from one to five, have, in some cases special names, the thumb (digit I) being the **pollex**, the corresponding great toe being the **hallux**, the fifth digit being called **minimus**, the second in the hand, the **index**, the fourth the **annulus**.

From this typical condition all forms of **chiropterygia**—legs, arms, wings—are derived by modification, fusion and disappearance of parts. The more distal a part the more variable it is; reduction takes place on the margins of the appendage, the axial portions being the last to disappear. Occasionally in various groups (amphibia, mammals) there occur what are interpreted as rudimentary additional digits—**prehallux**, **prepollex**, **postminimus**—but their status is uncertain. There are also certain membrane bones developed in the

appendages, including the **patella** (knee-pan) in some reptiles, birds and many mammals, in the tendon that passes over the knee-joint, the **fabellæ** in the angle of the knee of a few mammals, and the **pisiforme** in the carpus of man and some other mammals.

In the ancestral chiropterygium, as exemplified in the urodeles, the basal joint was directed horizontally at right angles to the axis of the body, but higher in the scale it approaches the sagittal plane and in such a way that the angles of the fore and hind limbs open in opposite directions. Besides there is frequently a torsion of the bones of the forearm (fig. 138) or shank on each other. The lower amphibians have nearly typical legs (fig. 137), although, as in *Siren* and *Amphiuma*, they may be greatly reduced, while in some stegocephals and the gymno-phiones they are entirely lacking. In the anura the radius and ulna or tibia and fibula are frequently fused and the tarsals elongated.

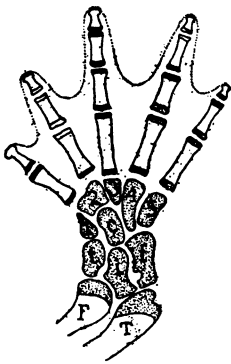

FIG. 137.

FIG. 137.—Tarsus of *Geotriton*, after Wiedersheim, showing the arrangement of the metapodial elements. *c*, centrale; *f*, fibulare; *F*, fibula, *i*, intermedium; *t*, tibia; *T*, tibia; 1-5, tarsals.

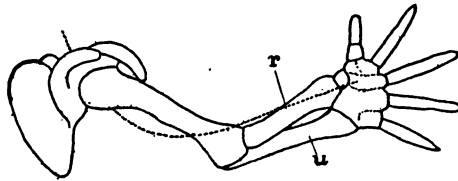


FIG. 138.

FIG. 138.—Torsion in developing human arm, after Braus. *u*, *r*, ulna and radius; dotted line, course of radial nerve.

The most marked feature of the reptilian limb is the occurrence of an intratarsal joint, the motion of the foot upon the leg being largely between the two rows of tarsal bones, instead of between tarsus and the bones of the shank (fig. 139), a condition duplicated in a way in the birds. There is also a greater range of form than in the amphibia. Limbs are lacking in snakes and some lizards; on the other hand there is a great increase in the number of phalanges, correlated with a shortening of the proximal bones, in the plesiosaurs, which reaches its extreme in the ichthyosaurs where there may be a hundred phalanges in a digit. The wings of the pterodactyls are remarkable for the great development of the fifth digit (elongation of the phalanges) as a support for the wing; the other digits are more normal.

The wings of birds (fig. 6o) are even more modified. Until the carpus is reached the structure is approximately normal, but the car-

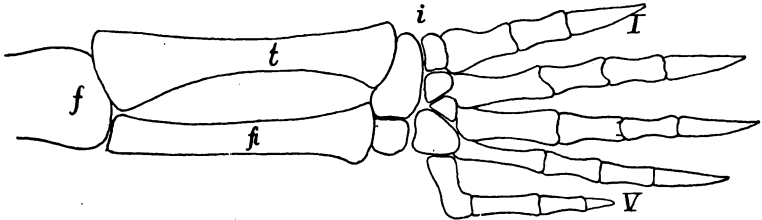


FIG. 139.—Hind leg of snapping turtle (*Chelydra*) showing intratarsal joint at *i*. *f*, femur; *fb*, fibula; *t*, tibia; I-V, digits.

pal bones are greatly reduced by fusion, while the metacarpals and digits, extensively modified, number only three. Development

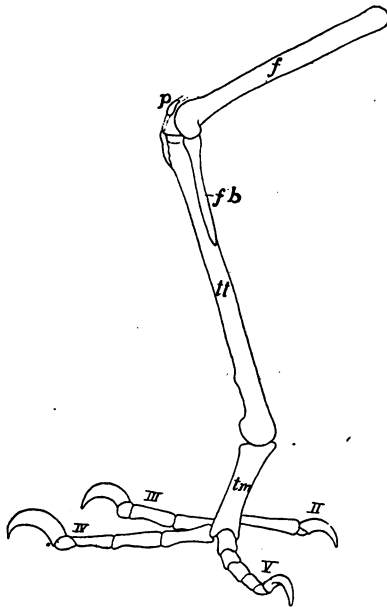


FIG 140.—Foot of parrot (*Psittacus amazonicus*), *f*, femur; *fb*, fibula; *p*, patella; *tm*, tarsometatarsus; *tt*, tibiotarsus; II-V; digits.

shows that the first digit is entirely lost and that the fifth metacarpal, which is present in the embryo, fuses early with the fourth, so that the digital formula is II, III, IV. There is also an extensive fusion of the bones of the tarsus and pes. The ankle-joint is markedly intratarsal, the basal row of tarsal bones fusing with the tibia (the fibula is reduced) to form a 'tibiotarsus,' while the tarsales have united in the same way with the fused metatarsals, forming a 'tarsometatarsus' (fig. 140). The toes are rarely more than four in number, the first apparently lacking, and, as a rule, the number of phalanges increases from two in digit II to five in digit V. Many birds have the toes reduced to three and in the true ostriches to two.

In the mammals, the limbs, especially the fore limbs, exhibit a considerable range of modification. Thus in the primates the skeleton is nearly typical, but there is a marked power of rotation of the foot and especially of the hand by the motion of the lower end of

the radius around the ulna. There also the appendages may form grasping organs, both features being found to a less extent in several lower groups. In the bats digits II to V are greatly elongated (either metacarpals or phalanges may be lengthened) to support the wing, the first digit remaining normal. In the whales and sirenians the basal parts of the fore limb are greatly shortened, while there is a multiplication of the phalanges, recalling that of the plesiosaurs. The hind limb is entirely lacking in the sirenians and some of the whales; in other whales there are two vestigial bones (?femur and tibia) imbedded in the muscles of the trunk.

The mammalian humerus is frequently perforated by a (**supra- or entepicondylar**) **foramen** passing through the inner lower end, a feature found elsewhere only in some theriomorphs. In many ungulates the ulna is reduced and may be fused with the radius; elsewhere it is well developed. Even where reduced it always bears on its proximal end a strong **olecranon process**, extending beyond the elbow-joint for the attachment of the extensor muscles of the forearm. The femur bears a varying number (up to three) of prominences or **trochanters** for the attachment of muscles. The fibula resembles the ulna in its tendency to reduction. The patella (p. 127) at the knee-joint is analogous to the olecranon process, though it never joins the other bones.

The details of the modification of the feet cannot be described here. The ankle-joint is never intratarsal but always between tarsal and crural bones. There is considerable variety in the extent to which the bones of the feet rest upon the ground. In the **plantigrade** foot, as in the bear and man, the sole of the foot includes the metapodial bones; in the **digitigrade** forms, like the dog and cat, the sole includes only the distal phalanges, while in **unguligrades** (cow, horse) the weight of the body is supported on the hoofs (p. 31) developed on the upper (anterior) surface of the distal phalanges. There is frequently a reduction of the digits, reaching its extreme in the horse where only digit III persists in a functional condition.

THE MUSCULAR SYSTEM

Practically all motion in vertebrates is caused by muscles which arise from the mesoderm. While other cells may have a certain power of changing shape, the muscle cells possess this in a marked degree, and so that they may cause the greatest amount of motion in the parts to which they are attached, they are very long, stimula-

tion causing them to contract in length and at the same time to increase in diameter.

There are two kinds of muscles which differ in origin, histological appearance, physiological action and distribution. The smooth muscles, the appearance of which has been described (p. 25), arise from the mesenchyme and are not under control of the will, but are innervated by the sympathetic nervous system. Their action is much slower than those of the other type. They are found in the skin, in the walls of blood-vessels and of the alimentary canal, and in the urogenital system. Occasionally they occur as isolated fibres, but frequently they form sheets or bands, sometimes of considerable thickness.

In the alimentary tract they are arranged in two layers in the straight parts of the tube, an outer layer of fibres which run longitudinally, and inside this a layer of circular muscles. In enlargements of the tube this regularity is interrupted and the course of the fibres is more irregular. The circular muscles, by their contraction, lessen the diameter of the canal, at the same time causing it to elongate, while the longitudinal fibres shorten it and cause it to increase in diameter. By the action of these two layers, **peristalsis** is produced, the food being moved forward and backward, thus aiding in its digestion and absorption. In the blood-vessels there are only circular fibres, the enlargement of the lumen being caused by the internal blood pressure.

The striped muscles are derived from the walls of the cœlom and hence are of mesothelial origin. Excepting those of the heart (to be mentioned below) and some of those at the anterior end of the alimentary canal, they are under control of the will and are supplied by the motor nerves of the brain and spinal cord. They are also able to contract more rapidly than the smooth muscles. The striped muscles make up the great mass of the musculature—the 'flesh'—of the body. They occur in the body walls, organs of locomotion, the head, diaphragm and the anterior part of the digestive canal.

The voluntary muscles are derived in part from the somites (myotomes), in part from the lateral plates, the latter furnishing the visceral muscles, including those of the head (except the eye muscles and the sternohyoid and its derivatives in the higher vertebrates) and those of the heart. The heart muscles, the development of which is traced in the account of the circulatory system, differ from the other striped muscles in the uninucleate condition of their short and

usually branched cells, while, physiologically, they are involuntary in character.

THE PARIETAL MUSCLES

After the myotomes are cut off from the rest of the cœlomic walls (p. 14) each consists of a closed sac, containing a part of the cœlom

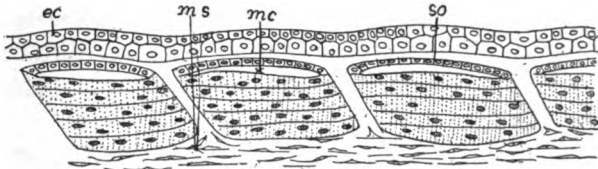


FIG. 141.—Myotomes of *Amblystoma* developing into muscle fibres. *ec*, ectoderm; *mc*, myocœle; *ms*, mesenchyme; *so*, somatic layer which will form corium.

(myocœle) and an inner (splanchnic) and an outer (somatic) wall. The more dorsal cells of the splanchnic wall (fig. 45) rapidly increase in number and size, thus tending to obliterate the myocœle. At the same time they become rearranged, so that, instead of forming a cubical or columnar epithelium, they have their long axis parallel to

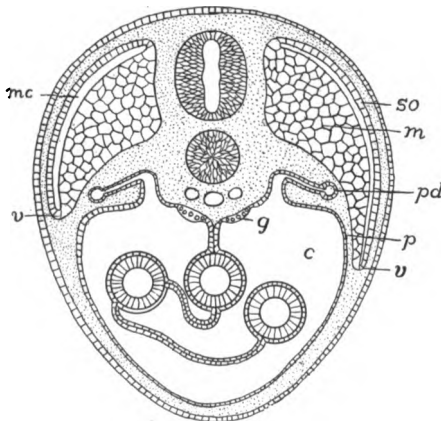


FIG. 142.—Diagram of descending myotomes. *c*, cœlom; *g*, gonad; *m*, splanchnic wall of myotome developing into muscles; *mc*, myocœle; *p*, peritoneum; *pd*, pronephric duct; *so*, somatic wall of myotome; *v*, ventral border of myotome.

the long axis of the body (fig. 141), each becoming multinucleate. Gradually the mass of the protoplasm becomes converted into contractile substance and the cell is converted into a muscle fibre, the nuclei being in the interior in the lower vertebrates, on the surface of the fibres in the mammals. In this way the splanchnic wall of each myotome is converted into a muscle; hence there are as many pairs of

these primitive muscles as there were of myotomes. The somatic wall of the myotome does not usually participate in the muscle formation, but is changed into mesenchyme and eventually gives rise to the corium of the skin. Mesenchyme also invades the spaces between the successive myotomes, develops into fibrous connective tissue, and forms the ligamentous connexions (**myosepta**, **myocommata**) between the muscles of a side. This primitive condition is readily recognized in the trunk and tail of the lower vertebrates, and even in the adults of the more modified birds and mammals the

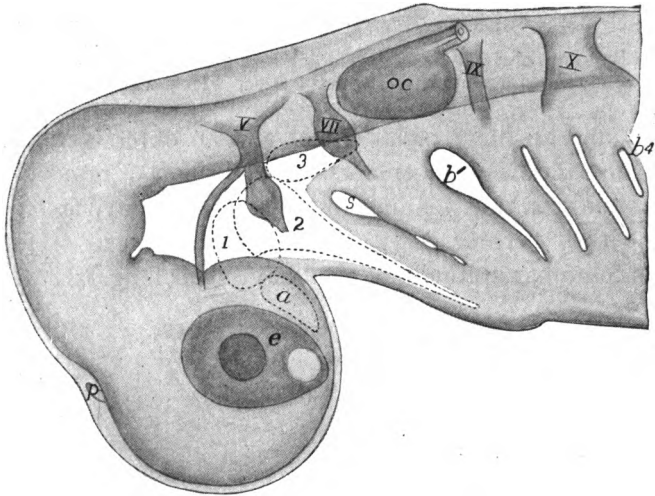


FIG. 143.—Head of embryo dogfish (*Acanthias*) seen as a transparent object, showing the preotic mesodermal somites, with dotted outlines, as *a*, 1, 2, and 3. *b*¹-*b*⁴, gill clefts, the fifth not yet open; *e*, eye; *oc*, otic capsule; *p*, epiphysial outgrowth; *s*, spiracle; *V*, trigeminal, *VII*, facial-acoustic; *IX*, glossopharyngeal; *X*, vagus nerves.

original segmentation can be traced in the intercostal and rectus abdominis muscles. At first the myotomes lie at about the level of the notochord and spinal cord, but with growth they extend upward and to a greater extent downward, insinuating themselves between the skin and the walls of the cœlom (fig. 142, right side) and thus forming part of the somatopleure. The downward growth continues until the muscles of the two sides all but meet in the mid-ventral line (fig. 10), the intervening space being occupied by connective tissue, the **linea alba** of the adult.

In the fishes the trunk and tail muscles formed in this way become divided horizontally into dorsal and ventral portions, the **epaxial** and **hypaxial** muscles, the line of division, which follows more or less

closely the lateral line, being marked by a horizontal partition of connective tissue already mentioned (figs. 10, 33). These plates of muscle do not retain their flat ends in the adult, but one end becomes conical and fits into a corresponding hollow in the next plate. In the tail of the amphibia epaxial and hypaxial muscles are clearly recognizable, but farther forward the hypaxials are greatly reduced, and in the amniotes the reduction is carried so far that the hypaxial muscles, greatly modified, can only be recognized in the cervical and pelvic regions, the 'tenderloin' being hypaxial.

In the head the developmental conditions are more complicated than in the trunk, our information being more complete with regard to the ichthyopsida. Here, in the region which develops into the head, ten cœlomic pouches are developed (in amniotes the number is apparently twelve). These are known by number, except that the most anterior, which was not known when the numbers were applied is called *A*. These cœlomic cavities (also known as **head cavities**) differ from the myotomes farther back in having no undivided portion of the cœlom below, corresponding to the hypomerall zone, a difference possibly due to the existence of visceral clefts in this region (fig. 143).

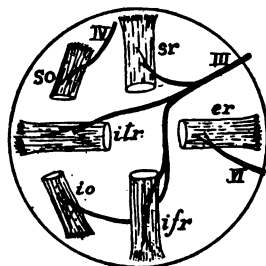


FIG. 144.—Diagram of the eye muscles of the right eye, seen from the medial side. *er*, lateral rectus; *ifr*, inferior rectus; *io*, inferior oblique; *iTr*, medial rectus; *so*, superior oblique; *sr*, superior rectus; *III*, oculomotor; *IV*, trochlearis; *VI*, abducens nerves.

Four of these cavities lie in front of the ear. Of these *A* disappears completely, its cells joining the mesenchyme, while the other three give rise to the 'eye muscles' which move the eye-ball (fig. 144). Without going into all of the details, 1, which lies in front of the mouth, gives rise to the **superior oblique muscle**; 2, which lies in the region of the jaws, forms four muscles, the **inferior oblique** and three of the **rectus muscles** while 3, in the hyoid region, develops the **lateral (external) rectus** (in some forms also a **retractor bulbi**). This method of origin explains the distribution of the eye-muscle nerves to be described later, each nerve supply only the derivatives of a single myotome (fig. 145). Several of the other head myotomes disappear in development, while the posterior form the so-called **hypoglossal musculature** (fig. 145).

In the above account there is given merely the origin of the con-

tractile tissue of the muscles. To this other parts of connective tissue are added. Mesenchyme cells invade the masses of muscle fibers, forming envelopes (**perimysium**) which bind the fibres into bundles (**fasciculi**) which, in turn, are united by other envelopes, the **fascia**. These connective-tissue envelopes are extended beyond the contractile tissue and form the cords or tendons by which the muscle is attached to other parts. One point of attachment, the **origin**, is fixed, that to the part to be moved is called the **insertion**. Tendons may be long and slender, allowing the muscle to lie in or near the trunk, while the part to be moved is in the appendage. Again they may form broad flat sheets (**aponeuroses**), and these may occur not only at the ends but in the middle of a muscle. Not infrequently parts of tendons may ossify, as in the patella or in the 'drum-stick' of the turkey. Small rounded ossifications of this kind are called **sesamoid bones**. In a few cases, as around the eye and mouth of mammals (fig. 149), the parietal muscles are without attachment, but form rings which are used to diminish the size of an opening (**sphincter muscles**).

Muscles vary greatly in shape. They are usually short and flat in the trunk, prismatic or spindle-shaped in the appendages. They may be simple or they may have several 'heads' or points of origin (biceps, triceps, etc.), or several points of insertion as in pinnate or serrate muscles. Again, there may be two or more contractile portions (bellies) in a muscle, separated by a tendon or aponeurosis.

Usually muscles are arranged in antagonistic groups, the action of one being the opposite of its antagonist. Thus there are **flexors** to bend a limb, **extensors** to straighten it; **elevators** to close the jaw, **depressors** to open it; **sphincters** working against **dilators**, etc.

Only a few points in the progressive modifications of the primitive musculature described above can be mentioned here, partly from lack of space, partly from deficient knowledge. There are great difficulties in tracing exact homologies through the different groups of vertebrates, on account of their very different functions in the separate classes and their great variability, even in the same family. The best test of homology is nerve supply, every muscle derived from any one myotome being innervated by branches of the nerve originally connected with the segment, as is beautifully illustrated in the case of the eye muscles as mentioned above. Next in importance are origin and insertion of the muscles, while the work done by the muscles is of little value. Differentiations from the primitive condition may take place in various ways. A single muscle may split into layers or it may divide longitudinally into two or more distinct

muscles, or transversely into two successive portions. On the other hand, two muscles, different in origin, may fuse; while, with loss of function of a part, its muscles may degenerate or entirely disappear. Muscles may wander far from their point of ontogenetic origin and become connected with parts widely remote, a condition strikingly illustrated in the facial muscles of the higher mammals, where nerve supply still shows the original history.

In the ichthyopsida the trunk muscles clearly show their myotomic origin, but even here there are tendencies to division and specialization. The ventral muscles on either side of the body cavity

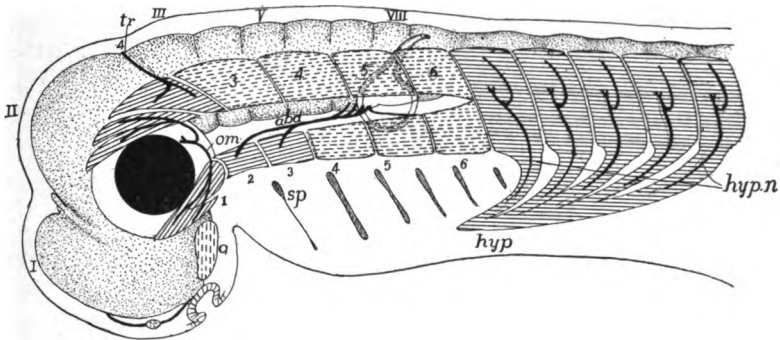


FIG. 145.—Diagram of muscle segments in head of embryo vertebrate, based upon a shark, after Neal. The anterior myotomes tend to divide into dorsal and ventral moieties; persistent myotomes lined, transient with broken lines; central nervous system dotted, nerves black. *a*, premandibular somite; *abd*, abducens nerve, *hyp*, hypoglossal musculature; *hypn*, hypoglossal nerves; *om*, oculomotor nerve; *sp*, spiracle; 1-6, first six somites (4, 5, 6, functional in *Petromyzon*); I-VIII neuromeres.

of the amphibia (fig. 147) are divided into a **lateral oblique** and a **medial rectus** system, the rectus muscles of the two sides being separated by the *linea alba* already referred to. The rectus muscles, in turn, become divided into successive groups, a **rectus abdominis** in the abdominal region, extending from the pelvis to the sternum; a **sternohyoid** from the sternum to the hyoid bone, and a **geniohyoid** from the hyoid to the tip of the lower jaw. The oblique region is also divided from the exterior to the peritoneal side, into three layers (**obliques** and **transversus**) characterized by the direction of the fibres. In the higher vertebrates, with the appearance of well-developed ribs, the oblique muscles furnish the two layers of **intercostal muscles**, extending from rib to rib, and in front of the ribs they form the **scalene muscles**, extending from the ribs along the side of the neck. In the non-placental mammals a strong **pyramidalis** mus-

cle extends, ventral to the rectus, from the inner side of the marsupial bones to the sternum, but disappears with the marsupial bones.

The dorsal muscles are more conservative, undergo less modification than those just mentioned, and always show, more or less clearly, their metameric nature. They become connected with various parts of the vertebræ and with the ribs, and are correspondingly divided into different groups. Thus the **spinales** connect the spinous processes, the **transversales** the transverse processes of the successive vertebræ, while the **transverso-spinales** extend from the transverse process of one vertebra to the spinous process of the next.

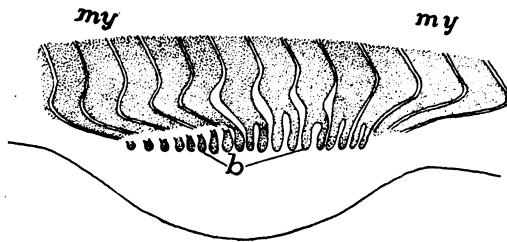


FIG. 146.—Budding of muscles of appendage from myotomes in *Pristiurus*, after Rabl.
b, muscle buds: my, myotomes.

In the higher vertebrates the anterior spinalis, connecting the first vertebra with the skull, is divided into several **rectus capitis** muscles. The **longissimus dorsi** group extends from the pelvis to the head, lying on either side in the angle between spinous and transverse processes. It may be differentiated into separate muscles—a **longissimus dorsi** proper in the lumbar region, an **ileo-costalis** inserted on the dorsal part of the ribs, and a **longissimus capitis** along the side of the neck to the temporal region of the skull.

The muscles which move the appendages are divided into the **intrinsic**, which are located in the limb itself and have their origin either from the bones of the limb or from the supporting girdle, and the **extrinsic**, which have their origin on the trunk and are inserted on the girdle or the base of the limb. The latter move the limb as a whole, while the intrinsic bend the limb on itself. As would be expected from the motions of the fins, the intrinsic muscles are hardly noticeable in the fishes, the various movements being accomplished by the extrinsic group. These latter are divided into **protractors** which draw the member forward; **retractors** which pull it back against the body; **levators** which lift it and **depressors** which pull it down.

In those vertebrates which are sufficiently known the first traces of the development of the musculature of the appendages are the appearance of two buds (fig. 146) from the ventral border of a varying number of myotomes in the region of the developing limb. These buds soon divide into inner and outer halves and each proliferates a cord of cells, the inner and outer series going respectively to the dorsal and ventral side of the appendage. The cells in the cords soon lose their distinctness and form a blastema from which the intrinsic muscles arise, the definitive muscles being innervated by as many spinal nerves as there are contributing myotomes. The extrinsic muscles arise directly from the myotomes.

With the development of the paired appendages into organs for the support of the body (tetrapoda) the skeleton of the leg is converted into a series of levers, and the intrinsic muscles are correspondingly differentiated and developed. Details cannot be given here as there are so many modifications, but they may be grouped as **flexors**,

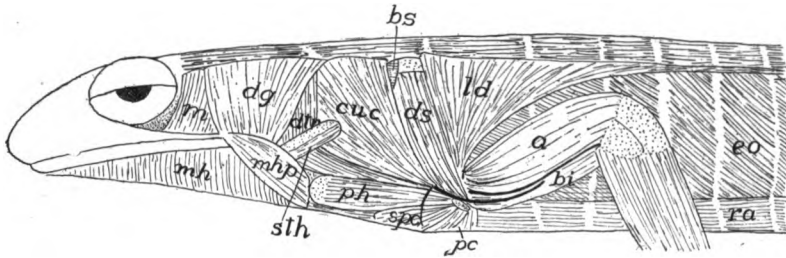


FIG. 147.—Superficial muscles of anterior part of *Salamandra maculata*, after Fürbringer. *a*, anconeus; *bi*, humero-branchialis inferior (biceps); *bs*, levator scapulae; *cuc*, cucularis; *dtr*, dorso-trachealis; *dg*, digastric; *ds*, dorsalis scapulae; *eo*, external oblique; *ld*, latissimus dorsi; *m*, petro-tympano-maxillaris (masseter); *mh*, mylohyoid; *mhp*, mylohyoid posterior; *pc*, pectoralis; *ph*, procoraco-humeralis; *ra*, rectus abdominis; *s pc*, supracoracoid; *sth*, sternohyoid.

which bend the limb or its parts; **extensors** which straighten it, and **rotators** which turn it on its axis. These undergo the most modification in the peripheral regions, the muscles of the upper arm and thigh being more constant in character and position. Even more constant are the extrinsic muscles, which may be grouped as in fishes. Most prominent of the levators of the fore limb are the **trapezius** and **levator scapulae** muscles, while the **pectoralis** and **serratus anterior** act as depressors; the **sternocleidomastoid** and the **levator scapulae anterior** act as protractors, the **pectoralis minor** and the **latissimus dorsi** are their antagonists. In the pelvic region the extrinsic muscles are less differentiated in function. The **pectineus** and **adductors** act as protractors, the **pyriformis** counteracts them; the limb is drawn toward the middle line by a **pubofemoralis**, while the **gluteus** muscle acts as a retractor and elevator.

THE VISCERAL MUSCLES

In the gill-bearing vertebrates a special system of muscles is developed in connexion with the visceral arches; these are to open and close the visceral clefts, including the mouth. With the loss of the gills some of these muscles disappear while others become changed in function, several retaining their connection with the hyoid. These visceral muscles may be divided into two sets according as they are derived from muscles which originally ran in a transverse (circular) or in a longitudinal direction.

To the first category belong the **epibranchial** muscles, the **sub-**

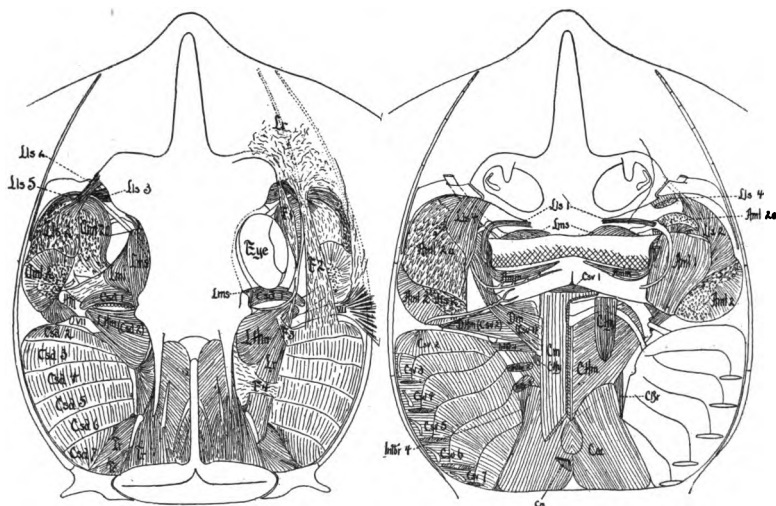


FIG. 148.—Dorsal and ventral head muscles of the skate (*Raia*), after Marion; the dorsal muscles more deeply dissected on the left side, the ventral on the right. *amd*, lateral mandibular adductors; *amm*, medial mandibular adductors; *csd*, *csv*, dorsal and ventral constrictors; *cm*, coraco-mandibularis; *chy*, coraco-hyoideus; *chm*, coraco-hyomandibularis; *cbr*, coraco-brachialis; *cac*, common coraco-arcual; *intbr*, interbranchials; *lms*, superior labial levators; *lmi*, levator of lower jaw; *lhm*, hyomandibular levator; *lr*, levator of rostrum; *tr*, trapezius; *VII*, seventh nerve; *dm*, depressor mandibulæ (digastric).

spinales and **interbasales**, which lie in the dorsal part of the branchial region, while the **coraco-arcuales** are in the ventral or hypobranchial half. The most anterior of the circular group are those which open (**digastric** or **depressor mandibulæ**) or close (**adductors**) the mouth, and the **mylohyoid** which extends between the two rami of the lower jaw. Usually there are several adductors, known as **masseter**, **temporalis**, **pterygoideus**, accordingly as they have their origin from different parts of the skull. The longitudinal muscles are largely confined to small slips which pass from one arch to the next. In the

amphibians these various muscles undergo considerable differentiation, while in the amniotes this is, in part, carried farther, in part they are reduced on account of the loss of branchial respiration and the degeneration of the parts connected with it. Hence the most noticeable of the visceral muscles in the higher groups are those connected with opening and closing the mouth.

THE DERMAL MUSCLES

The muscles already mentioned are connected with the skeleton, but in the higher vertebrates a dermal musculature appears in which the muscles are inserted in the skin, although they are derived from

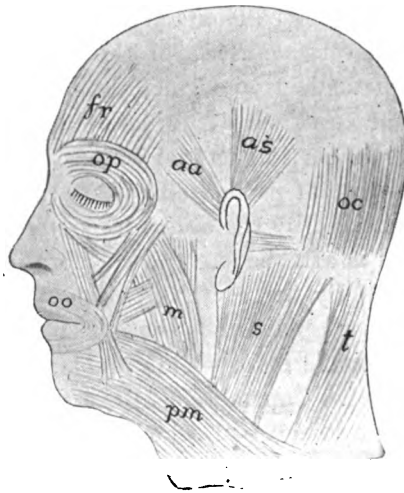


FIG. 149.—Principal dermal muscles of head of man. *aa*, *as*, auriculares anterior and superior; *f*, frontalis; *m*, masseter; *oc*, occipitalis; *oo*, orbicularis palpebrarum; *pm*, platysma myoides; *s*, sternocleidomastoid; *t*, trapezius.

the skeletal muscles. This system is poorly developed in the amphibia, and increases in the reptiles and birds, where it serves to move the scales, scutes and feathers. It is especially noticeable in the snakes, where it is largely concerned in the movement of the scutes in creeping.

The system acquires its greatest development in mammals. In the marsupials, for instance, there is an extensive dermal musculature, the **panniculus carnosus**, covering a large part of the body and the appendages. It is by means of this that various mammals twitch the skin to dislodge insects, etc., while armadillos and hedgehogs roll themselves into a ball by means of a part of the layer. In the pri-

mates the dermal muscles are restricted to the neck (**platysma myoides**) and the head, all parts of them being supplied by the facial nerve belonging primitively to the hyoid region. The **platysma** extends forward from the neck and by growth and division gives rise to the muscles of expression—the **orbiculares** which close the lips and eyelids, the muscles which lift lips, nose and lids and those which move the ears—muscles which as a whole have their highest development in man (fig. 149).

THE DIAPHRAGM

The **diaphragm** is a transverse voluntary muscle which crosses the body cavity of the mammals just behind the pericardium and lungs. Its muscles are in part derived from anlagen in the neck, in part from the rectus and transverse muscles of the lower surface. Various attempts have been made to recognize similar muscles in the lower vertebrates, in some cases with considerable success. Its development is outlined in the section on the cœlom (p. 18); it being only necessary to add here that parts are also contributed by the pleuro-peritoneal membrane and by the dorsal mesentery. The diaphragm is dome-shaped and is attached to the vertebral column and to the ribs. It is traversed by the œsophagus and the large arterial and venous trunks. In some mammals the muscular portion is confined to the margin, the centre being membranous; in others the muscle fibres extend across it. Contraction of the muscles flatten it, thus enlarging the pleural cavities and drawing air into the lungs, and so aiding in respiration. It is supplied by the phrenic nerve which, like the muscles, arises in the cervical region, a fact of interest when it is recalled that lungs and heart (anterior to the diaphragm) arise in the primitive head region, and later migrate into the trunk.

ELECTRICAL ORGANS

It is well known that the contraction of a muscle causes the discharge of a minute amount of electrical energy, so it is not surprising that in certain cases muscles are modified into electrical organs. The known cases occur only in elasmobranchs and teleosts. The discharge is weak in most species, but is strong in *Torpedo* and *Gymnotus*. In all but *Malapterurus* the electrical organs are clearly modified muscles, situated in the head in *Torpedo* and *Astroscopus*, in the trunk of *Gymnotus*, and in the tail of *Raia*, the nerve supply being correspondingly varied. Thus in *Torpedo* the seventh, ninth and tenth

cranial nerves are concerned, while in *Gymnotus* and the skates the supply is from the spinal nerves. *Malapterurus* is peculiar in that the organ is in the integument and has been supposed by some to arise from modified glands. It is more probable that here as elsewhere it is derived from the muscles, as the organ is under control of the will; the development has yet to be studied. This diversity of origin clearly shows that the electrical functions have been separately acquired in the different species.

The organs are composed of a large number of electrical plates (**electroplaxes**) arranged at right angles to the axis of the primitive

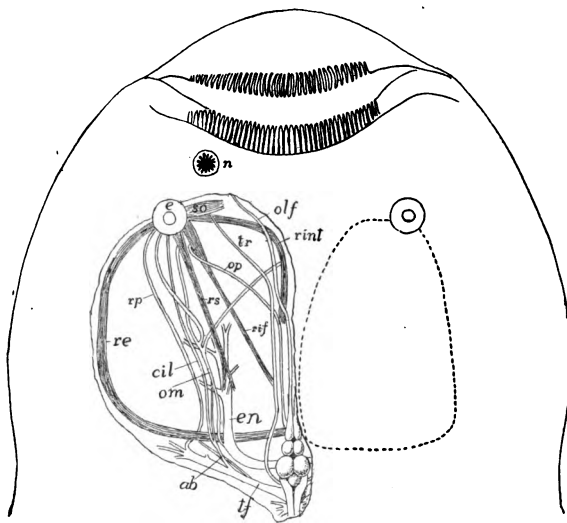


FIG. 150.—Head of *Astroscopus y-græcum*, after Dahlgren and Silvester. The dotted line on right shows extent of electric organ, on the left the eye muscles and nerves as forced out of place by the electric organ. *ab*, abducens; *cil*, ciliary nerve; *e*, eye; *en*, electric nerve; *n*, naris; *olf*, olfactory nerve; *om*, oculomotor; *op*, optic nerve; *re*, *rif*, *rint*, *rs*, external, inferior, internal and superior rectus muscles; *r ϕ* , palatine nerve; *so*, superior oblique muscle; *tf*, trigeminal-facial nerve; *tr*, trochlearis nerve.

muscle, each derived, where the history has been traced (*Torpedo*, *Raia*), from a primitive muscle cell. In the typical condition each plate consists of an outer electric layer, differentiated into a nervous side and a so-called nutritive side, with a middle striated layer between them, the latter in a few cases being weakly developed or absent. Nervous stimulation is always by motor roots leading to the nervous layer, the connexion corresponding to the nerve-end of a muscle cell. Numbers of these electroplaxes are included in a

connective-tissue compartment with a gelatinous substance between them and all with their nervous layer turned in the same direction.

In *Torpedo* the organ apparently is derived from part of the jaw muscles and the prisms of plates are arranged vertically. In *Astroscopus* (fig. 150) it is said that the tissue comes from some of the eye muscles, while in *Gymnotus* the ventral trunk muscles are concerned and the columns of electroplaxes are horizontal. In the same fish the discharge is always in the same direction, e.g., in *Torpedo* from below upward.

THE NERVOUS SYSTEM

Nervous and sensory structures are closely related to each other, and their distinction in the higher animals is the result of differentiation among cells which were originally both nervous and sensory in character, and it is in this broader sense that the term nervous structures is used in these introductory paragraphs.

The nervous system primarily has to inform the animal of the conditions, good and bad, in the environment, to correlate this information and to regulate the motions so that advantage may be had of this knowledge. These facts have determined several features of the nervous system. Thus they have determined its origin in the ectoderm, the outer layer of the body, which comes into relation with the external world. Since this information has to be carried to internal parts, conducting tracts or nerves have arisen, while the correlating function has been localized in the body of the cells where incoming and outgoing tracts meet.

Very important of the primitive functions was the determination of the character of the food, which would lead to the greater aggregation of the nervous tissue around the mouth. As we have seen (p. 12) the anlage of the central nervous system of the vertebrates occupies such a position around the blastopore, or mouth of the gastrula, in the form of the neural plate. As the external surface of the body is most exposed to injury, the nervous structures, with the closure of the blastopore, have been protected by removal to a deeper position, through the rolling of the plate into a tube. The closure of the blastopore brings the two halves of the plate into close association with each other, making it a bilateral structure. With bilaterality comes the tendency of one end of the animal to take the lead, resulting in the concentration of nervous and sensory structures at the anterior end, which first comes in contact with foreign objects. In

this way a brain has been specialized apart from the rest of the nervous system.

With the appearance of metamerism in the mesothelium and the development of muscles from the myotomes there results a serial repetition of motor nerves going to these, since each muscle must have its own nerve supply, while sensory nerves are the result of the sinking of the neural plate to a deeper position, as the sensory organs must be largely in the skin.

The close association of sensory and motor nerves in the trunk region of vertebrates is not yet satisfactorily explained. The fact that in *Amphioxus* the two kinds of nerves are independent of each other throughout their course shows that the vertebrate condition is not primitive.

The infolding of the nervous plate has been described (p. 12) and with that stage the present account begins. As the plate is broadest in front, the result is a larger anterior portion of the tube, the brain, while the rest of the tube gives rise to the spinal cord. Brain and cord constitute the **central nervous system**, while the nerves arising from the brain and cord form the **peripheral nervous system**.

CENTRAL NERVOUS SYSTEM

The **neural (or medullary) plate** (p. 12) is a thickened portion of the ectoderm which surrounds the line of closure of the blastopore.

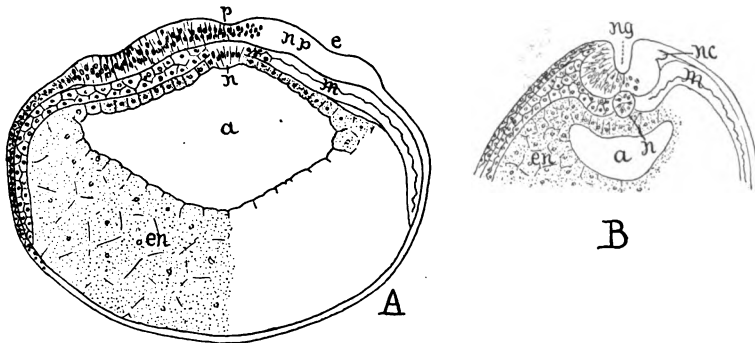


FIG. 151.—Earlier (A) and later (B) transverse sections of *Amblystoma* embryos, B being also more posterior. a, archenteron; e, optic pit; en, entoderm; m, mesothelium (with somatic and splanchnic layers; n, notochordal cells and (B) notochord; nc, neural crest; ng, neural groove; np, neural plate; p, primitive groove.

It is thinner in the middle line than elsewhere (**primitive groove**), and at the margins passes rather suddenly into the unmodified ectoderm which is to form the epidermis (fig. 151, A). With further development the edges of the plate are elevated as **neural folds** (fig. 151, B)

with a **neural groove** between them. The folding process continues until the folds meet above and the plate is rolled into a tube, the edges of the folds fusing, and the tube being then cut off from the rest of the ectoderm (fig. 153, *A*). The thinner portion of the primitive groove becomes the floor plate of the tube, while a similar roof plate is formed dorsally, where the neural folds met. The sides of the tube

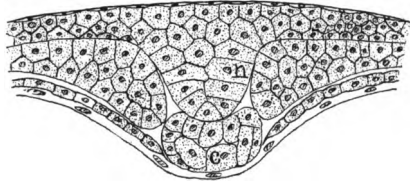


FIG. 152.—Section of embryo sea-bass (*Serranus*) after H. V. Wilson. *c*, notochord; *ec*, ectoderm, developing in the middle line a distinct keel, *n*, forming a solid cord in which a lumen appears later; *en*, entoderm; *m*, mesothelium.

are several cells thick, and the lumen of the tube is called the **central canal**. From the method of its formation it will be understood that the inner surface of the tube is homologous with the outer surface of the general epidermis of the body, a point of importance in connexion with the development of the eye.

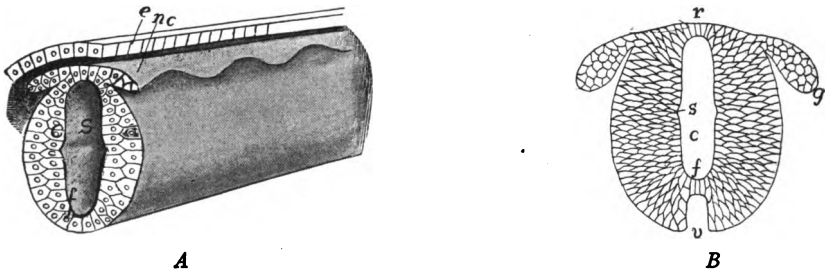


FIG. 153.—*A*, diagram of early spinal cord; *B*, later, showing increase in size and consequent ventral fissure. *c*, central canal; *e*, ectoderm; *f*, floor plate; *g*, anlage of spinal ganglion; *nc*, neural crest; *r*, roof plate; *s*, sulcus limitans (sulcus of Monro); *v*, ventral fissure.

This general account of the formation of the neural tube will not exactly apply to cyclostomes, teleosts and some ganoids. In these forms the neural plate thickens into a deep keel (fig. 152) dipping deep into the embryo. Later a central canal is formed in the keel, so that the final result is the same as that described above.

SPINAL CORD

From this simple tube, the brain and the spinal cord are differentiated. After the separation of the tube from the rest of the ecto-

derm, the cells of the side walls begin a rapid proliferation, while those of roof and floor plates do not. As a result the sides of the tube extend laterally and especially toward the ventral side so that the floor plate comes to lie at the bottom of a groove, the **anterior or ventral fissure** (fig. 153, *B, v*) running the whole length of the cord. At first the roof plate is carried upward by the increase in the sides of the cord, thus increasing the vertical diameter of the central canal.

Then the dorsal part of the canal closes—the exact steps are uncertain—and later the line of closure is invaded by connective tissue carrying blood-vessels, the result being a marked dorsal separation between the two halves of the cord, the **posterior or dorsal septum** (fig. 154, *Fp*).

The cells which line the inside of the cord—floor, roof and sides—retain their epithelial character through life and form the **ependyma** which is non-nervous in character. The other cells of the sides become differentiated in two directions. Some develop processes which surround and support the other cells, these forming the **neuroglia** ('glia'). The others form the **neuroblasts** which are to develop true nervous tissue.

In the early stages the neuroblasts are without connexions with distant parts and hence cannot function as nerve cells. These connexions are established by protoplasmic outgrowths from the neuroblasts which can extend to enormous distances. These form the afferent and efferent tracts or fibres of each neuron (p. 24). Some of these fibres produced in this way extend out from the cord as nerves (see below), but others run longitudinally for greater or less distances on the outside of the cord, thus forming an envelope of fibres (the **marginal layer**) on the outer surface. Since these fibres are medullated (p. 24) and are consequently white, the envelope forms what is known as the **white matter** of the cord, while the more internal parts, composed largely of the cell bodies, constitute the **gray matter**.

In the adult of the higher vertebrates the gray matter, in transverse section (fig. 154), is shaped something like the letter H, with the central canal in the middle of the cross bar. The uprights of the H form two pairs of ridges of gray matter which run lengthwise of the cord, known as the **posterior and anterior columns** (formerly cornua) of the cord. Where the cross bar meets the columns there is a third or **lateral column**, differing markedly in relations and function from the others. Since both anterior and posterior columns approach nearer the surface of the cord than does the rest of the gray matter,

they divide the white matter into three longitudinal tracts, the **funiculi** (formerly called column), dorsal, lateral and ventral in position (fig. 154). The location of the roots of the spinal nerves, to be described later, still further emphasizes the limits of the funiculi.

As the white matter is composed of longitudinal fibres, these funiculi serve as tracts by which the different parts of the central nervous system are connected with each other. Farther, there is a differentiation of the fibres. Those in the dorsal funiculus carry

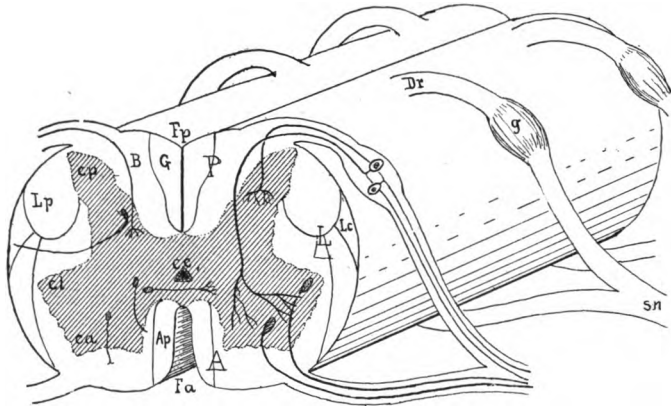


FIG. 154.—Diagram of spinal cord and nerve roots; gray matter shaded. *A*, *L*, *P*, ventral, lateral and dorsal funiculi; *Ap*, fasciculus cuneatus anterior; *B*, fasciculus cuneatus (Burdach); *cc*, central canal; *ca*, *cl*, *cp*, anterior, lateral and posterior columns of gray matter; *Dr*, dorsal root of spinal nerve; *Fa*, ventral fissure, *Fp*, dorsal septum; *G*, fasciculus gracilis (Goll); *g*, ganglion of dorsal root; *Lp*, fasciculus cerebrospinalis lateralis; *sn*, spinal nerve.

impulses toward the brain—are **ascending tracts**; while the ventral funiculus of either side is a **descending tract** and the lateral funiculi consist of fibres of both kinds and carries impulses in both directions.

The fibres in each of these funiculi are grouped in smaller bundles or fasciculi, each with its name, some of which are indicated in figure 154. As some of these fibres coming from the brain are distributed at different levels along the cord, and others, going to the brain, are added to the funiculi at different places, it follows that the size of the funiculi decreases with the distance from the brain, and that some of the bundles may disappear in the more distal parts of the cord.

In the higher groups the spinal cord is approximately cylindrical, but in the lower it is flattened dorso-ventrally, the flattening being greatest in the cyclostomes. In the lower groups there is also a difference in the shape of the gray matter, the H shape being less distinct (fig. 169).

In the fishes the cord tapers pretty regularly from the brain to the posterior end, but with the development of legs and an increase of the musculature, the

spinal cord becomes enlarged in the regions where the nerves for the limbs are given off; this reaching possibly the extreme in certain fossil reptiles where casts of the spinal canal indicate that there was an accumulation of nervous matter near the hind legs which exceeded the brain in size.

In the early stages the nerves leave the spinal cord at nearly right angles to its axis. Then there occurs an inequality in growth, the body increasing more in length than does the cord. As a result the more posterior nerves pursue a very oblique course and in the hinder part of the spinal canal of the higher vertebrates they form a bundle of parallel nerves, the *cauda equina* (horse-tail). Another result of the unequal growth may be the drawing out of the hinder end of the cord into a slender, non-nervous thread, the *filum terminale*.

THE BRAIN

A knowledge of the structure of the spinal cord throws light upon the greatly more complex brain, for the latter is primitively a tubular

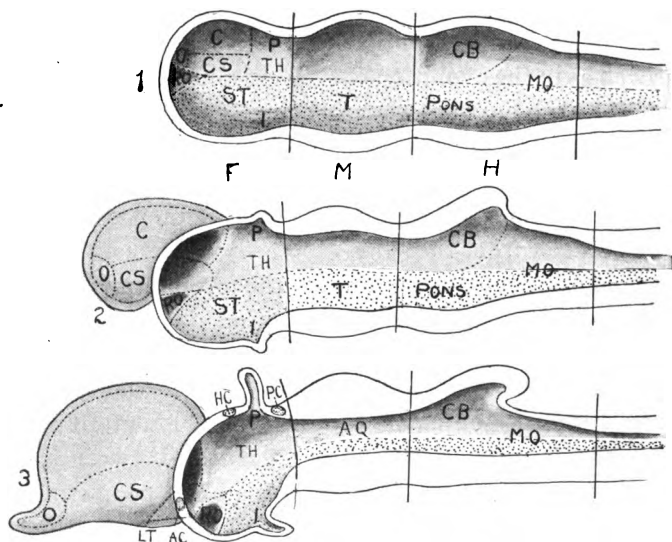


FIG. 155.—Diagrams of median sections of (1) primitive brain; (2) an intermediate stage, and (3) with the definitive parts. (Compare 3 with fig. 156). *AQ*, aqueduct, *AC*, anterior commissure; *C*, cerebral region; *CB*, cerebellum; *CS*, corpus striatum; *HC*, habenular commissure; *I*, infundibulum; *LT*, lamina terminalis; *MO*, medulla oblongata, *O*, olfactory region; *P*, epiphysial region; *PC*, posterior commissure; *RO*, optic recess; *ST*, subthalamica; *T*, tegmentum; *TH*, thalamus. Dorsal zone plain, ventral zone dotted; *F*, *M*, *H*, fore-, mid- and hind-brains.

structure, with roof, floor and sides, which at first closely resemble those of the cord. It has also nerves connected with it which recall those of the spinal cord, to be described later.

In its development, as stated above, the brain is, from the first, larger than the cord. Very early the brain tube develops three enlargements, separated from each other by two constrictions, the third of these enlargements passing gradually into the cord (fig. 155, 1). These enlargements are called, from the front end backward, the **fore-brain**, the **mid-brain** and the **hind-brain**, the constriction between mid- and hind-brains being the **isthmus**. From the anterior end a groove, the **limiting sulcus (S. of Monro)**, may run along the middle of the inner surface of the side walls of the tube, dividing it into a **dorsal** and a **ventral zone**. In front, the limiting sulcus ends in a small pit, the **optic recess**, wedged in between the two zones of either side, and the part of the roof plate immediately above the recess retains its non-nervous character through life and is known as the **lamina terminalis**.

This distinction of the two zones is of great importance, for the dorsal is to be connected with the sensory structures, the ventral will be motor in character. Also, the most noticeable changes in development, as well as in the evolution of the vertebrate brain, are concerned with the dorsal zone, the ventral being much more conservative. As in the cord, the side walls are the chief seat of nervous development, while roof and floor plates, for the most part, retain their non-nervous character, though in some places they may be invaded by nervous matter from the sides.

The dorsal zones of the two sides of the fore-brain give rise to several structures. The anterior part on either side grows out laterally and anteriorly (fig. 155, 2), the outgrowths increasing rapidly in size, eventually forming a pair of hollow vesicles, the **telencephalon (cerebrum, cerebral hemispheres)** with the lamina terminalis at the bottom of the interval (**longitudinal fissure**) between them (fig. 157, 1). In the wall of each hemisphere is a basal ganglionic portion, the **corpus striatum**, and an anterior area which grows out to join the ectoderm of the front of the head where the olfactory organs are to form, this part being the **olfactory lobe (rhinencephalon)**. The remainder of the wall of each vesicle forms the **pallium** or **mantle**.

The roof plate of the telencephalon does not become nervous, but from it are developed a thin-walled sac, the **paraphysis**, which extends outward from the brain, and behind this, an infolding of the roof as a **velum transversum**, usually recognized as limiting the cerebrum behind (fig. 158).

After the outgrowth of the telencephalon the remainder of the fore-brain forms the **diencephalon** ('twixt-brain, or **thalamencephalon**), this including the posterior part of the dorsal and the whole of the ventral zone of this region. The part below the limiting sulcus becomes the **hypothalamus**, while the dorsal zone forms two regions a more dorsal **epithalamus** and a larger and more ventral **thalamus**. The floor and roof plates of the 'twixt-brain behind the velum transversum form median structures; a ventral outgrowth, the **infundibulum**, and dorsally a parietal organ and an epiphysis (pinealis) which will be described below (p. 155-7).

In the mid-brain or **mesencephalon** there are but slight changes. The upper part of the side walls of the dorsal zone become thickened into a pair of prominences—the **optic lobes** or **corpora bigemina**

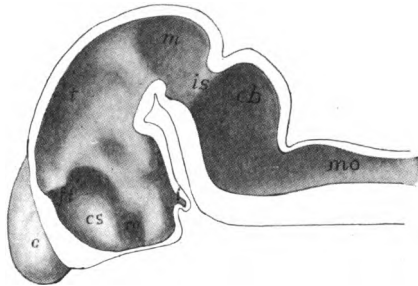


FIG. 156.—Half of model of brain of embryo pig, 15 mm. long. (Compare with fig. 155, 3.) *c*, cerebrum; *cb*, cerebellum; *cs*, corpus striatum; *i*, infundibulum; *is*, isthmus; *fi*, interventricular foramen; *m*, mesencephalon; *mo*, medulla oblongata; *t*, thalamus.

(in the mammals there are two pairs of such lobes—**corpora quadrigemina**) which protrude on the dorsal surface. The roof plate remains comparatively thin, but the floor plate becomes thicker and forms the **cerebral peduncle** (*crura cerebri*).

The isthmus is a constriction of the dorsal zone which separates sharply the mesencephalon from the hind-brain. In the latter region there are considerable modifications of the dorsal zone, the anterior part of which develops dorsally, forming an elevation of the surface, the **cerebellum** or **metencephalon**, the extent of which varies greatly in the different classes of vertebrates. The rest of the dorsal zone and the whole of the ventral zone of the hind-brain form the **myelencephalon** or **medulla oblongata**. The roof plate in the cerebellar region becomes thickened by the invasion of nervous material from either side, while behind the metencephalon the plate becomes greatly

expanded, because the development of the cerebellum forces the anterior parts of the two dorsal zones far apart, thus stretching the plate into a thin and broad sheet. The floor plate, on the other hand,

becomes greatly thickened and constitutes the **pyramids** which pass in front into the cerebral peduncles. Behind, the medulla passes gradually into the spinal cord, the line between medulla and cord being marked, not by any structural difference in the nervous tissues, but by the posterior limits of the skull.

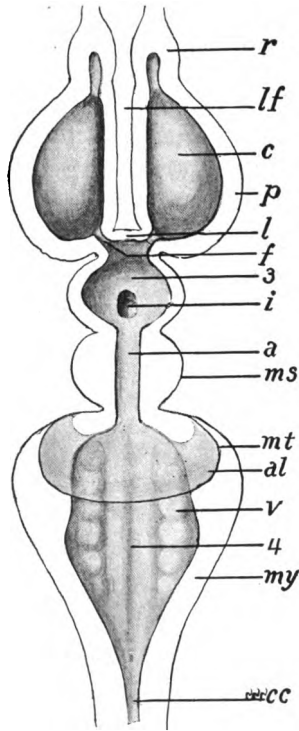


FIG. 157.—Diagram of lower half of brain, the cerebellum in position and represented as if transparent. *a*, aqueduct; *al*, acustico-lateralis lobe; *c*, corpus striatum in floor of lateral ventricle of telencephalon; *cc*, central cana of cord; *f*, interventricularforamen; *i*, infundibulum; *l*, lamina terminalis; *lf*, longitudinal fissure; *ms*, mesencephalon; *mt*, metencephalon; *my*, myelencephalon; *r*, rhinencephalon; *p*, pallium; *v*, visceral lobe; 3, third ventricle in diencephalon; 4, fourth ventricle.

Ventricles.—Thus there are formed from the three early divisions of the brain, five regions—telencephalon, diencephalon, mesencephalon, metencephalon and myelencephalon—which occur in all vertebrates. These usually retain in their interior the derivatives of the cavities of the original three divisions, which were but a continuation of the central canal of the spinal cord. By the outgrowth of the cerebral hemispheres the cavity of the fore-brain becomes divided into three chambers or **ventricles**, one lateral ventricle in each hemisphere, and one, the **third**, in the 'twixt-brain, the lateral ventricles being connected with the third by a pair of narrower canals, the **interventricular foramina (foramina of Monro)**. In the higher vertebrates the primitive ventricle of the mid-brain becomes reduced to a narrow tube, the **aqueduct** or **iter**, but in the lower vertebrates it remains large and may extend up into

the optic lobes where it is called the **epicœle**. The aqueduct is limited behind by the isthmus, but beyond this comes the very large **fourth ventricle** below the cerebellum and extending back into the medulla, where it gradually narrows to the central canal of the

cord. In many lower vertebrates the anterior part of the fourth ventricle may extend as a **metacoële** into the cerebellum (fig. 174).

Telæ Chorioideæ.—The brain, as well as the spinal cord, receives nourishment from blood-vessels distributed over the outer surface, but, in addition, extensions of these outer vessels carry the roof and floor plates of the fore- and hind-brains before them into the ventricles of these regions. These foldings of the plates are called **telæ chorioideæ** (figs. 158, 160) or **chorioid plexuses**, and by their means nourishment passes by osmosis into the ventricles and so to the inner surfaces of the brain. Usually the chorioid plexus of the fourth ventricle is torn away in removing the envelopes of the brain, leaving a large opening, the **fossa rhomboidalis**, into the cavity.

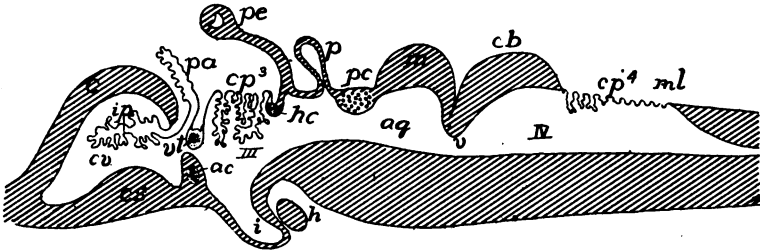


FIG. 158.—Diagrammatic longitudinal section of brain. *ac*, anterior commissure in lamina terminalis; *aq*, aqueduct; *c*, cerebrum; *cb*, cerebellum; *cp*, chorioid plexus; *cs*, corpus striatum; *cp*, cerebral ventricle; *h*, hypophysis; *hc*, habenular commissure; *i*, infundibulum; *ip*, inferior chorioid plexus; *m*, mesencephalon; *ml*, myelencephalon; *p*, pinealis; *pa*, paraphysis; *pc*, posterior commissure; *pe*, parietal eye; *v*, anterior medullary velum; *v*, velum transversum with aberrant commissure; *III* and *IV*, third and fourth ventricles.

Flexures.—Thus far the brain has been considered as if it were a continuation in a straight line of the spinal cord. In fact, by unequal growth of the two zones, it becomes flexed in the vertical plane. In the lower vertebrates these flexures are prominent only in the young and largely disappear in the adult. They are more developed in the higher vertebrates and persist throughout life. Most constant of them is the **primary flexure** in the mid-brain, by which the derivatives of the fore-brain are bent at a right angle (or even more) to the axis of the rest (fig. 159). Second to appear is the **nuchal flexure** in the hinder part of the medulla oblongata which bends in the same direction. The **pontal flexure**, in a plane with the cerebellum tends to counteract the effect of the other two as it bends in the reverse way. Nuchal and pontal flexures are at best, but weakly developed in the ichthyopsida where practically all flexures are obliterated.

ated in the adult, but in amniotes they are increasingly developed and persist throughout life.

Brain Stem.—In the higher vertebrates the parts of the brain already enumerated, cerebrum and cerebellum excepted, but usually including the corpora striata, are called the brain stem, because they are the part from which cerebrum and cerebellum project as well as the place where all of the fibre tracts are situated.

Medulla Oblongata.—Of all parts of the brain the medulla or myelencephalon most closely resembles the spinal cord. Viewed from above it is triangular in outline, the dorsal parts of its side walls being wedged apart, and then forced to turn abruptly toward the median line by the growth of the cerebellum. This brings about the great expansion of the roof plate of the fourth ventricle already men-

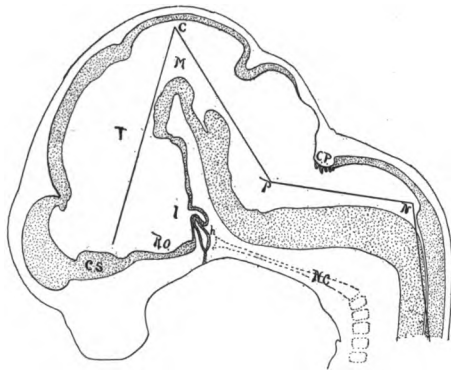


FIG. 159.—Median section of brain of pig 15.5 mm. long, showing flexures of the brain C, principal flexure; cs, corpus striatum; CP, chorioid plexus of fourth ventricle; h, hypophysis; i, infundibulum; M, mid-brain; N, nuchal flexure; nc, notochord and vertebræ; P, pontal flexure; RO, optic recess; T, 'twixt-brain.

tioned. The floor plate has lost its non-nervous character by the invasion of several **nerve centres** in the ventral side, these serving as places where nerve impulses, brought by efferent fibres, are redistributed to other neurons.

As a result of the expansion of the anterior end of the medulla oblongata, the fibre tracts of the dorsal and the dorsal part of the lateral funiculi are carried to the sides of the cerebellum, to enter which they must bend abruptly inward, thus forming a cord, the **corpus restiforme** (**inferior cerebellar peduncle**) on either side. The other fibre tracts form a pair of bands, the **pyramids**, on the ventral surface of the myelencephalon which are continued forward beneath the mid-brain as the **cerebral peduncles** (**crura cerebri**), the con-

tinuity being evident in the lower vertebrates, but somewhat obscured in the mammals by the development of the pons, soon to be mentioned.

Cerebellum.—The cerebellum or metencephalon is developed from the anterior part of the dorsal zone and roof plate of the hind-brain, the roof plate being invaded by nervous matter from either side. In front it is bounded by the isthmus, which, together with the anterior wall of the cerebellum, forms a transverse fold, the **anterior medullary velum (valve of Vieussens)**, which dips into the fourth ventricle. In the lower vertebrates there is but a single part to the cerebellum, which corresponds to the **vermis** of the mammals. In the higher reptiles and birds a small lateral outgrowth on either side, the **flocculus** (fig. 179) appears near the ventral portion. In the mammals a large **cerebellar hemisphere** is developed on either side, between vermis and flocculus, the latter being thus forced to the lower surface.

In the lower vertebrates a few fibres from either side of the cerebellum pass across the ventral surface of the pyramids to reach the other side. In the mammals the number of these is greatly increased, so that a large transverse band, the **pons (Varolii)** is developed on the lower surface of this part of the brain stem. These fibres, as they enter or emerge from the cerebellum, form the **middle peduncle** or **brachium pontis**. In front, the cerebellum is connected with the mid-brain by a longitudinal tract, the **anterior peduncle** or **brachium conjunctivum**. This starts, in the mammals, from a large nerve centre, the **nucleus dentatus**, in either cerebellar hemisphere.

Mesencephalon.—The mesencephalon is practically the mid-brain of the early embryo. It undergoes little modification except that, on the dorsal surface, two lateral swellings, the **optic lobes** are developed, these being transversely divided in the mammals into four, the **corpora quadrigemina** (fig. 167, *ol*). On either side the optic lobe is connected with fibres coming from the eye of the *opposite* side. The floor is greatly thickened by the fibres of the pyramidal and cerebral peduncular tracts, and the floor plate disappears. In the higher groups the primitive ventricle of the mid-brain has been reduced to the aqueduct, but in the fishes it remains large and extends, as the **epicœle**, into the optic lobes (fig. 174). At the anterior end of the dorsal part of the mid-brain, there is a band of nerve fibres which crosses from one side to the other (fig. 160, *pc*). Such cross connexions are called **commissures** and they serve to connect the two

sides of the central nervous system. In the spinal cord the cross fibres are numerous (fig. 169, which shows them beneath the central canal). In the brain there are several yet to be mentioned. From its position this one at the junction of mid- and 'twixt-brains is called the **posterior commissure** (figs. 160, 167, *pc*).

Diencephalon.—The 'twixt-brain is limited behind by the posterior commissure, in front by the velum transversum above, and the lamina terminalis below (fig. 160); its cavity is the third ventricle, to the region of the optic chiasma.

The side walls are thick while roof and floor plates, though much modified, still retain to a very large extent their primitive non-nervous character. The fibre tracts connecting the cerebrum with the

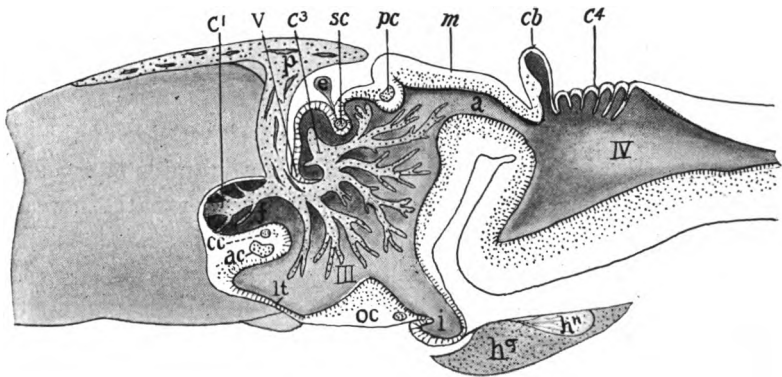


FIG. 160.—Sagittal section of brain of *Ichthyophis*, after Burckhart. *a*, aqueduct; *ac*, anterior commissure; *c*¹⁻⁴, chorioid plexuses of lateral, third and fourth ventricles; *cb*, cerebellum; *ec*, pallial commissure; *f*, interventricular foramen; *e*, epiphysis; *hg*, *hn*, glandular and nervous parts of hypophysis; *i*, infundibulum; *u*, lamina terminalis; *m*, mid-brain; *p*, paraphysis; *oc*, optic chiasma; *pc*, posterior commissure; *sc*, superior commissure; *III*, *IV*, third and fourth ventricles.

parts farther back pass in the side walls; the dorsal ones go through the **thalamus** where there is a large nerve centre, while the ventral tracts are the cerebral peduncles already mentioned. As already explained, the thalamus is developed from the dorsal zone, and above and in front of it is the **epithalamus**, which contains a nerve centre, the **habenula** (fig. 167, *h*). In the hypothalamus of the ventral zone are two pairs of centres, the **tuber cinereum** in front and the **mammillary bodies** behind. Epithalamus and hypothalamus are connected with the sense of smell and are relatively larger in the lower than in the higher vertebrates. Just behind the velum transversum is the **superior (habenular) commissure** (fig. 160, *sc*).

Under the head of **epiphysial structures** are included several

parts developed in the roof plate of the primitive fore-brain. At the junction of cerebral hemispheres and 'twixt-brain (fig. 158) there is an internal epithelial fold, the **velum transversum**, depending from the cerebral roof. In front of this an outgrowth, the **paraphysis**, arises on the top of the brain in nearly all vertebrates (figs. 158, 160). It is non-nervous and apparently is an extraventricular chorioid plexus with secretory functions. The other epiphysial structures belong to the 'twixt-brain and consist of a parietal organ and a pinealis. Both arise from the roof between the habenular ganglion and the posterior commissure, at the boundary between 'twixt- and mid-brains, sometimes as two distinct structures (fig. 161), sometimes as

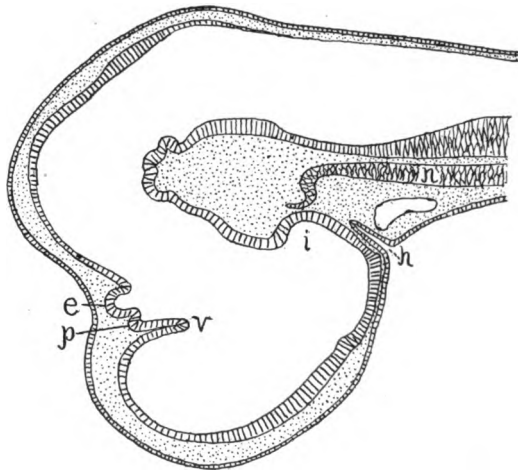


FIG. 161.—Section through brain of an *Acanthias* embryo, 15 mm. long, showing the early appearance of two epiphysial structures, the parietal organ (*p*) which is already degenerating, and the pinealis (*e*), *h*, hypophysis, growing in from the oral epithelium; *i*, infundibulum; *n*, notochord; *v*, velum transversum.

the result of division of a single outgrowth of the roof. The anterior of these is the **parietal organ** or eye; the other the **pinealis organ** or epiphysis proper. The two vary in development in different vertebrates, the parietal eye being well-marked only in cyclostomes, *Amia*, teleosts and most lizards, while the pinealis is almost invariably present.

In its fullest development in lizards (fig. 162) and *Sphenodon* the parietal organ extends as a slender stalk, hollow at first, through the parietal foramen of the skull, expanding beneath the skin to a vesicle, above which the integument is usually thin and transparent, forming a physiological cornea. The distal wall of the vesicle is thickened in

the middle, forming a lens, while the cells of the proximal side elongate, each becoming differentiated into a distal, rod-like end and a proximal portion which contains the nucleus and is connected with a nerve fibre. Pigment is deposited between these cells so that the whole forms a retina. An important point, to be better appreciated after the consideration of the paired eyes, is the fact that these parietal eyes are like those of most invertebrates in having no inversion of the retina. How far these eyes are actually functional is not settled. Even in *Sphenodon*, where it is best developed, experiments have resulted in no decided reactions.

In other vertebrates the parietal organ does not pass outside the skull, and even may not appear transitorily in development. The

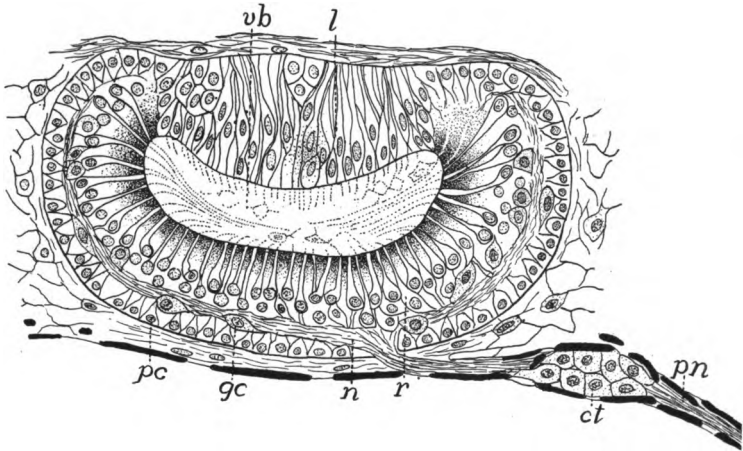


FIG. 162.—Parietal eye of *Anguis fragilis*, after Nowikoff. *ct*, connective-tissue cells around nerve; *gc*, ganglion cells; *l*, lens; *n*, nerve fibres; *pn*, parietal nerve; *pc*, pigment cells; *r*, retinal cells; *vb*, vitreous body.

pinealis to some extent may take its place and often shows, as in certain elasmobranchs and lizards, traces of a visual structure. In the anura its tip approaches the skin and later is cut off from the brain by the development of the skull, forming the so-called **frontal organ** or 'brow spot,' visible from the exterior. Pineal and parietal organs differ in their nerve supply, the parietal being connected with the superior commissure of the 'twixt-brain, the pinealis and its derivatives with the posterior commissure. In the higher vertebrates the epiphysial structures are completely covered by the backward growth of the cerebrum. The large parietal foramina in many extinct reptiles and stegocephals (figs. 92, 99, 100, 103) would seem to

indicate that they had well-developed parietal or pineal organs. The roof of the brain in this region, behind the lamina terminalis, also gives rise to a chorioid plexus like that of the fourth ventricle, a part of which invades the third ventricle and another portion, the **inferior plexus**, sends branches through the foramina interventriculares into the ventricles of the hemisphere, thus providing for a blood supply on the interior of these structures (fig. 160).

The floor of the diencephalon remains thinner behind the optic recess, a portion of it becoming funnel-shaped and pushing out from the ventral surface toward the roof of the mouth. This is the **infundibulum**, which meets an ectodermal diverticulum, the **hypophysis**. This arises, in the cyclostomes from the ectoderm between the nostril and the mouth (fig. 212, *h*); in other vertebrates from the roof of the oral cavity (figs. 159, 161). It retains its connexion with the parent epithelium for a time, the point of ingrowth being known as **Rathke's pocket**.

Later the stalk disappears, and the infundibulum and hypophysis, closely associated, lie just beneath the brain in the sella turcica on the floor of the skull (p. 68). In the hypophysis (**pituitary body**) two parts are distinguished (fig. 160, *hg*, *hn*) rich in blood- and lymph-vessels and forming a gland of internal secretion whose action is

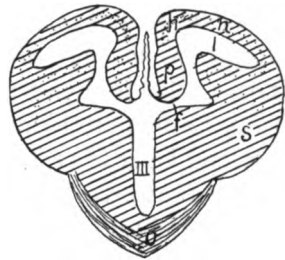


FIG. 163.—Section through brain of embryo *Sphenodon*, just behind the lamina terminalis, after G. Elliot Smith. *f*, interventricular foramen; *h*, region of hippocampus; *l*, lateral ventricle; *n*, neopallial region; *p*, paraterminal body; *s*, corpus striatum.

connected with the fat-storing powers of the animal. The infundibulum may be a simple pit, as in most vertebrates, or its lateral walls may become enlarged and folded, blood-vessel lying in the folds, and the whole forming the so-called **saccus vasculosus**. The paired eyes are also connected with the 'twixt-brain, their nerves crossing the ventral surface (**optic chiasma**) just in front of the infundibulum, on their way to their termination in the optic lobes. Associated with the optic chiasma may be a **postoptic commissure**, connecting the ventral parts of this region of the brain.

Cerebrum.—The cerebrum or telencephalon consists of two hemispheres separated in front by the longitudinal or intercerebral fissure, which is slight in fishes, but well marked in the other groups. It is the extreme anterior part of the brain and is bounded posteriorly by the velum transversum and the optic chiasma. Hence (see fig. 163)

it really contains a part of the third ventricle as well as the lateral ventricles in the hemispheres. Each hemisphere consists of a ganglionic mass, the corpus striatum, in or near the floor, and a part, the pallium, covering the ventricle. This latter part undergoes the greatest modification in the different groups. In front the cerebrum proper passes into or connects with the olfactory lobe, into which a part of the ventricle may extend.

In most vertebrates the pallium is relatively thin, compared with the corpora striata, and in the teleosts it is reduced to a very thin, non-nervous wall to the ventricle. In the mammals it is greatly increased, forming in the higher groups by far the greater part of the whole brain, a development which is correlated with the greater mental development. The increase is also accompanied by structural alterations in the pallium. In the ichthyopsida the gray matter (nerve cells) is confined to the ventricular surface, the outer surface being white matter (fibres). In the reptiles there is the beginning of a second layer of cells at some distance from the ventricular surface. This is increased in birds while in the mammals it forms a marked layer (cerebral cortex) over almost the whole of the surface of the pallium.

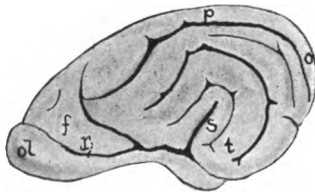


FIG. 164.—Lateral view of left cerebral hemisphere of dog, showing lobes, gyri and sulci. *f*, frontal lobe; *o*, occipital lobe; *ol*, olfactory lobe; *p*, parietal lobe; *s*, fissure of Sylvius; *t*, temporal lobe.

This increase in cerebral cortex is accommodated in part by longitudinal growth of the cerebrum, but there is a limit to such growth, so in most mammals the posterior ends of the hemispheres bend downward and then grow forward, so that the (morphologically) posterior end of each hemisphere is brought in close spatial relations with the olfactory region (fig. 164), covering up a portion of the side wall of the hemisphere (the insula), the bending being indicated by a deep lateral cerebral fissure (fissure of Sylvius) (fig. 164, *s*), found in most mammalian brains at the bottom of which is the *insula* (of Riel). In the lower mammals the general surface of the cerebrum is smooth, but in the higher it is thrown into a number of folds (fig. 164) or convo-

lutions (**gyri**) separated by grooves (**sulci**), the number of these being greatest in man. By this a greater amount of cortical gray matter is provided for, the cortex covering, not only the tops of the gyri, but dipping beneath every sulcus.

By the bending there are differentiated several regions or lobes in the cerebrum (fig. 164). In front is the **frontal lobe**, the **occipital lobe** is at the posterior end of the brain, the **parietal** is between frontal and occipital, and the **temporal lobe** is on the lower outer side, behind and below the lateral fissure. This bending also involves the lateral ventricles, portions (horns) entering each lobe.

The two cerebral hemispheres are connected by commissures. In all vertebrates there is one of these transverse bands (**anterior commissure**) in the lamina terminalis (fig. 158, *ac*), but as low as the am-

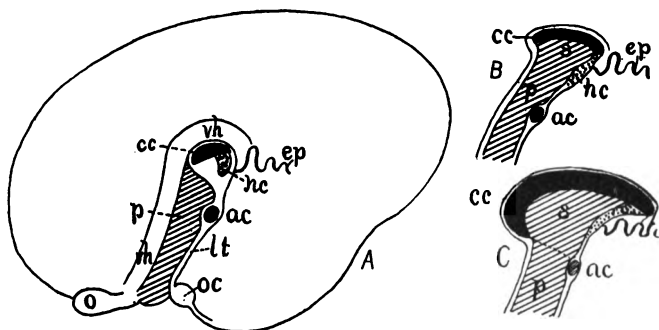


FIG. 165.—Diagram of the development of the corpus callosum and septum pellucidum in man, after G. Elliott Smith. In *A* the hemisphere is outlined. *ac*, anterior commissure; *cc*, corpus callosum; *ep*, epithelial roof of third ventricle; *hc*, hippocampal commissure; *lt*, lamina terminalis; *o*, olfactory lobe; *oc*, optic chiasma; *p*, paraterminal body; *s*, septum pellucidum; *vh*, vestigial pre- and supracallosal hippocampus.

phibia a second tract, the **pallial commissure**, appears dorsal to this, which increases in size in the sauropsida and monotremes (fig. 181, *HC*). This serves, in the lower groups chiefly as a connexion between the hippocampal areas of the two sides. In the higher mammals it becomes differentiated into two commissures (fig. 165), a more dorsal and anterior **corpus callosum**, and a more posterior and ventral **hippocampal commissure**, the callosum being the connexion between the cortical layers of the two sides of the cerebrum. As the cortex is the seat of mentality, it follows that the callosum reaches its greatest development in man.

The development of the corpus callosum brings about a stretching of the gray matter (**paraterminal body**) immediately adjacent to the terminal lamina, eventually expanding it, in the higher mammals,

dorsally on either side into a thin translucent membrane, the **septum pellucidum** (figs. 165, 167), the space between the two septa (formerly called the fifth ventricle, though it has no relation to the other ventricles) is the cavity of the septum.

There are two tracts of nervous matter which run back, on the medial side of either hemisphere, from the olfactory lobe to the hinder end of the cerebrum. One of these, the **hippocampus** (fig. 166), passes dorsal, the other, the **olfactory tract** goes ventral to the foramen of Monro. These two and the associated olfactory matter make up practically all of the pallium (the **archipallium** it has been called) in the lower vertebrates, for in these the whole cerebrum is accessory to the sense of smell. But in the mammals, and possibly as low as the reptiles, a part has been added to receive impressions from other somatic senses. This is the **neopallium** which has grown out lateral to the hippocampus (fig. 163, *n*) and has become especially large in the higher mammals, in man forming by far

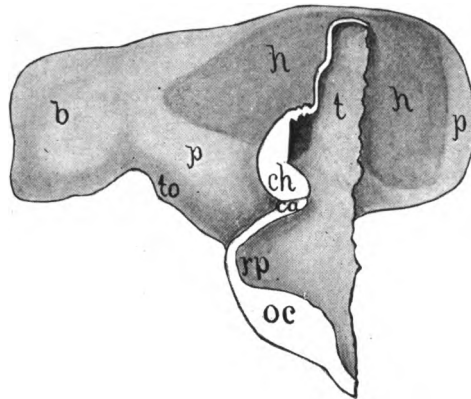


FIG. 166.—Medial side of right hemisphere of turtle (*Chrysemys*) embryo of 17 mm., modified from Johnston. The hippocampal area (*h*) is darker than rest. *b*, olfactory bulb; *ca*, anterior commissure; *ch*, hippocampal (pallial) commissure; *h*, hippocampus; *oc*, optic chiasma; *p*, general pallium; *rp*, preoptic recess; *t*, thalamus, *to*, olfactory tubercle.

the greater part of the cerebrum. Its great development has forced the olfactory parts to the medial and lower surfaces where they are not exposed at the first glance and parts of them can only be found by dissection. Besides, it has made a part of the original hippocampus vestigial (fig. 165).

Beginning in the amphibia and reappearing in the reptiles is a tract of fibres on either side, which connects the posterior part of the cerebrum (where the hippocampus ends) with the hypothalamus. In the mammals, by the flexure of the cerebrum, this same band of fibres, here called the **fornix**, is obliged to take a circuitous course. Starting at the hippocampus on the medial side of the temporal lobe, the fornix runs up, then forward, below the corpus callosum, (fig. 167), and then down, in front of the interventricular foramen to end in a protuberance, the **corpus mammillare**, on the floor of the hypothalamic region.

Neuromeres.—In its development the brain shows evident traces of having once been a segmented structure, consisting of a series of

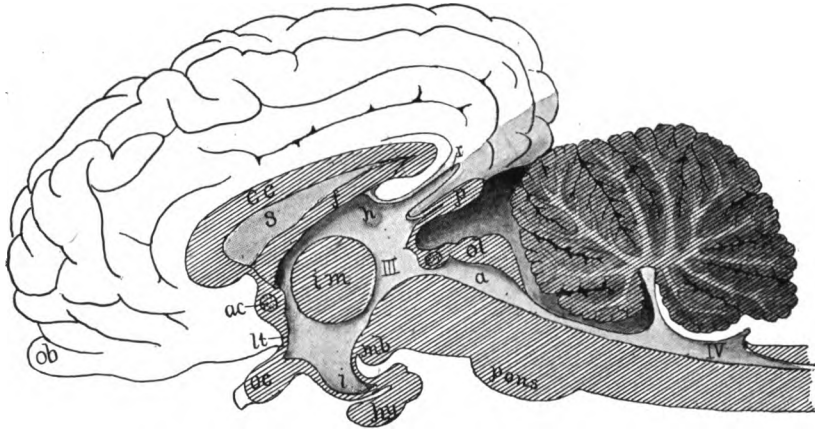


FIG. 167.—Median section of brain of calf, based on a figure by Bütschli. *a*, aqueduct; *ac*, anterior commissure; *cc*, corpus callosum; *f*, fornix; *h*, habenula; *hy*, hypophysis; *i*, infundibulum; *im*, intermediate mass ("soft commissure"); *mb*, mammillary body; *ob*, olfactory bulb; *oc*, optic chiasma; *ol*, optic lobes; *p*, pinealis; *pc*, posterior commissure; *r*, recessus suprapinealis; *s*, septum pellucidum; *III*, *IV*, third and fourth ventricles.

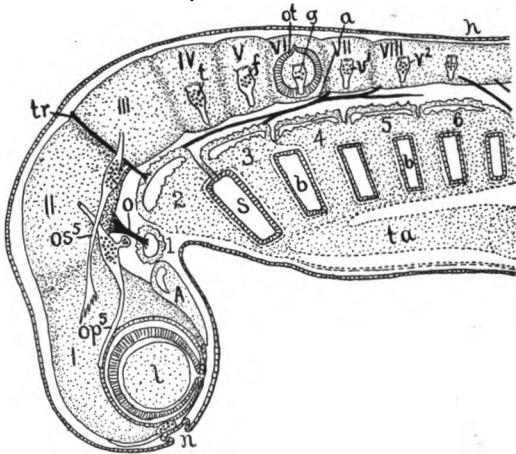


FIG. 168.—Diagram of the segments (neuromeres, myotomes, etc.) of the head, after Neal. *A*, anterior myotome; *a*, abducens nerve; *b*, branchial clefts; *f*, facial nerve; *g*, glosso-pharyngeal nerve; *h*, hypoglossal nerve; *l*, lens, surrounded by layers of eye; *n*, nasal pit, near it the terminalis nerve; *o*, oculomotor nerve; *op*, ophthalmic profundus part of fifth nerve; *os*, ophthalmic superficialis part of fifth nerve; *ot*, otocyst; *s*, spiracular cleft; *t*, trigeminal nerve; *ta*, truncus arteriosus; *tr*, trochlear nerve; *I-VIII*, neuromeres; *1-6*, myotomes.

segments or neuromeres metamerically arranged. Concerning the number of these and their relations there has been an enormous dis-

cussion and a great lack of unanimity of opinion. Apparently there is the best support for the following statement. There are at least eight neuromeres in the brain (figs. 145, 168), five in front of the ear, one corresponding to the ear in position, and at least two behind that organ. The first of these gives rise to the fore-brain and the parts arising from it, as described on page 148. The second develops into the mid-brain; the third is in the region of the cerebellum, while the fourth and fifth are at the anterior end of the medulla oblongata where the trigeminal and facial nerves arise. The sixth, besides being related in position to the ear, gives off the glossopharyngeal nerve, and the rest are connected with vagus nerve. Some claim two fore-brain neuromeres and a larger number for the postotic region.

ENVELOPES (MENINGES) OF THE CENTRAL NERVOUS SYSTEM

Both brain and spinal cord are surrounded by envelopes (**meninges**) of connective tissue which support and protect them, and

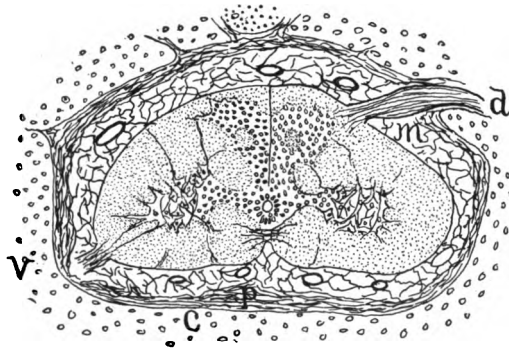


FIG. 169.—Section of spinal cord of dogfish (*Acanthias*). The section is a little oblique, passing through a dorsal root of a spinal nerve (*d*) on one side and a ventral root (*v**) on the other. *c*, cartilage of the vertebral column; *m*, meninx primitiva; *p*, perichondrium (endorhachis of the spinal canal). In the cord are shown the distribution of white and gray matter, the central canal and some of the divisions of the white matter into fibre tracts.

also, by carrying blood-vessels, provide for their nourishment. These meninges become more complicated with ascent in the vertebrate series. The canal of the vertebral column and the cavity of the skull are lined with a layer of connective tissue, the **endorhachis**, which is really the periosteum or perichondrium of the skeletal parts and hence not a true meninx. In the fishes (fig. 169) there is a single envelope, the **meninx primitiva**, which bears the blood-vessels and lies close upon the spinal cord. Between it and the endorhachis is a

perimeningeal space, somewhat broken by strands of tissue passing from meninx to endorhachis, and filled, like all meningeal spaces, with a **cerebrospinal fluid** containing albumen.

From the urodeles upward there is an increasing division of the meninx primitiva into two layers, a **pia mater** bearing the blood-vessels and lying close to the cord, and a **dura spinalis**, separated from the pia by a **subdural space**, the perimeningeal space now being known as the **peridural**. In the mammals the pia becomes invaded by cavities separating a delicate **arachnoid membrane** from its outer surface, so that there is another space, the **subarachnoid**, in these forms.

There may be slight differences in the region of the brain in the higher groups where the dura presses against and finally unites with the endorhachis, forming the **dura mater** of human anatomy, thus obliterating the subdural space. In the mammals and to a less extent in birds the dura mater forms two strong folds. One of these is longitudinal and presses into the longitudinal fissure between the two cerebral hemispheres as a firm membrane, the **falx cerebri**. The other fold, the **tentorium**, is transverse, and is inserted between cerebrum and cerebellum. It is occasionally ossified and united to the skull.

The Brain in the Separate Classes

CYCLOSTOMES.—The brain differs greatly in the two subdivisions of cyclostomes. In both the flexures (fig. 170) are never as marked as in the gnathostomes and are entirely lost in the adult, where the brain has a primitive, almost embryonic appearance.

In the lampreys (fig. 170) the brain is long and slender, and its roof is epithelial, even in the mid-brain region, there being large everted chorioid plexuses in the roof of mid-brain and medulla (removed in the figures). The small telencephalon is indistinctly divided into so-called olfactory lobes and cerebral hemispheres, but in reality olfactory bulbs in front and olfactory lobes behind, the whole being subsidiary to the sense of smell. There are two epiphysial outgrowths from the roof of the 'twixt-brain (removed in the figure). The posterior (upper) of these is clearly the pinealis, but the homologies of the other are uncertain and it has been called the **parapinealis**. The weakly developed infundibulum has associated with it a median sac, probably representing the vascular sacs of the ichthyopsida. This is closely connected with the hypophysis, which develops, not from the oral (ectodermal) epithelium as in other vertebrates, but by an inpushing (fig. 212) between nasal and oral invaginations (see also p. 157). Mid- and hind-brains are relatively broad, and the cerebellum is reduced to a narrow cross band, much like that of amphibia. The ventricular cavities are large and well developed.

The myxinoid brain (fig. 171) is shorter and broader and is marked by a groove running the whole length of the dorsal surface. The medulla oblongata

is distinct and of the usual type, but in front of this are four pairs of lobes which are interpreted by Retzius as, first, a pair of olfactory lobes, connected with the enormously developed nasal capsule (p. 83); second, the cerebral hemispheres; third, the mid-brain (the 'twixt-brain being covered); and fourth, the cerebellum, which covers the fossa rhomboidalis. Lying in the median groove is a prominence which is regarded as the habenula. In both genera

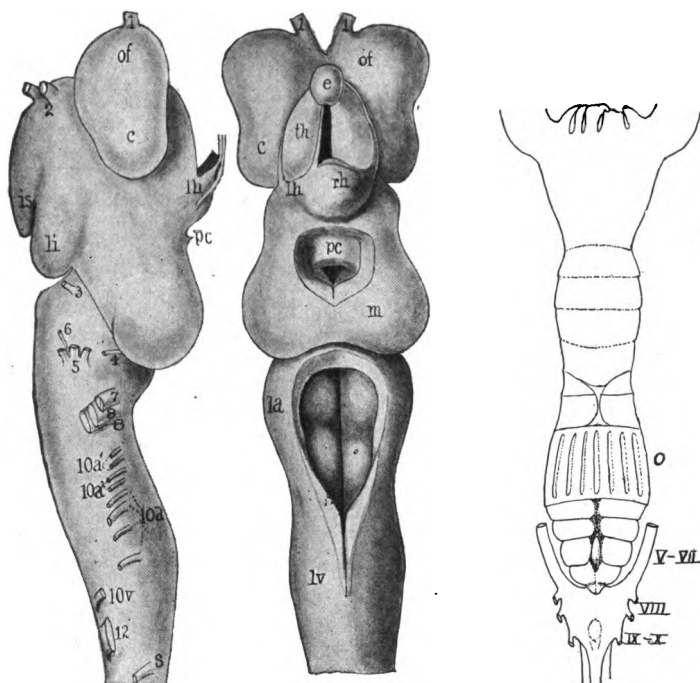


FIG. 170.

FIG. 171.

FIG. 170.—Dorsal and lateral views of the brain of *Petromyzon planeri* after Ahlborn. The telæ chorioideæ removed, and the epiphysial structures not shown in the side view. *c*, cerebrum; *e*, epiphysial structures; *is*, saccular part of infundibulum; *la*, acoustic lobe; *lh*, left habenular ganglion; *li*, lobular part of infundibulum; *lv*, lobe of vagus; *m*, mid-brain; *of*, olfactory lobe; *pc*, posterior commissure; *rh*, right habenular ganglion; *s*, first spinal nerve; *th*, thalamus; 1-12, cranial nerves.

FIG. 171.—Brain of *Bdellostoma* (Princeton, 2204). *o*, skeleton of olfactory organ, the brain behind this; V-X, nerves.

(*Myxine* and *Bdellostoma*) the ventricular cavities are greatly reduced, the aqueduct ending blindly in the mid-brain, in front of which is only the third ventricle, completely cut off from the rest.

ELASMOBRANCHS (figs. 172, 193) usually have the brain somewhat compact, but in a few it is long and slender. The more striking features are the slight development of the intercerebral fissure, the large hemispheres being lateral expansions just in front of the diencephalon. The optic lobes are large and the large cerebellum overlaps both lobes and the fossa rhomboidea. The olfactory lobes arise from the antero-lateral angle of each hemisphere; their

length varies between wide limits. The epithelial roof of the 'twixt-brain is wide and bears a pinealis which often penetrates the roof of the skull, but the parietal organ is lacking. The hypophysis and infundibulum are provided with large inferior lobes and a well-developed saccus vasculosus. The cerebellum has a longitudinal groove and usually one or more transverse grooves, dividing the upper surface into paired lobes. The medulla differs in the sharks and the skates, being very short in the latter, much longer in the former. In both the corpora restiformia are large folds on either side of the cerebellum, in front of and lateral to the fossa rhomboidea.

In most elasmobranchs the ventricular system is well developed, but in some the paired and third ventricles are not well separated, while in the Myliobatidæ there is no cavity in the cerebrum. There is a large epicæle extending upward from the aqueduct into the optic lobes and a similar cavity usually enters the cerebellum.

TELEOSTOMES.—There is a wide range of form in the brain of ganoids and teleosts. It is usually small in proportion to the size of the animal and is noticeable for the small size of the telencephalon and the usually non-nervous character of the pallium, which in the teleosts is purely epithelial. Consequently the cerebrum consists largely of the corpora striata (fig. 173) and the intercerebral fissure is slightly developed. The paired ventricles are small, but they extend into the olfactory lobes. The 'twixt-brain, at a lower level than the rest, has a large infundibulum, saccus vasculosus and inferior lobes. On its roof is a large pinealis which reaches the skull in a few ganoids. The cerebellum is large, much larger than appears from the surface, since a considerable part, the valvula, projects into the ventricle of the mid-brain. In the medullary region there is sometimes an enormous development of the lobes of the vagus (fig. 173).

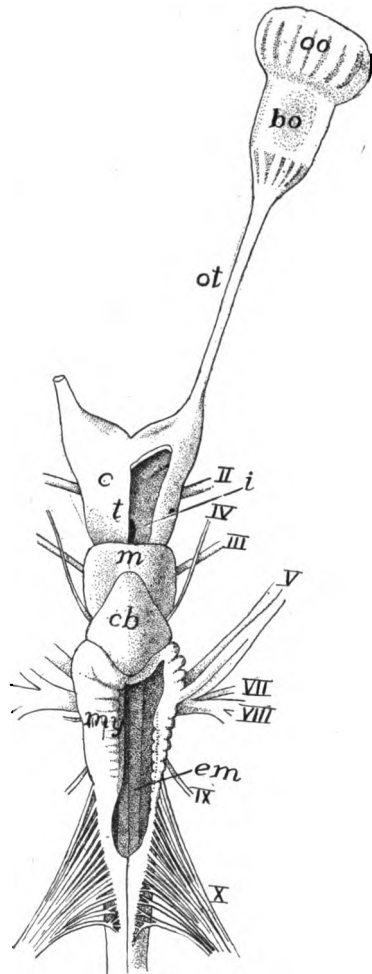


FIG. 172.—Brain of *Heptanchus*, after Gegenbaur. *bo*, bulbus olfactorius; *c*, cerebrum; *cb*, cerebellum; *em*, eminentia teretes; *i*, infundibulum; *m*, mesencephalon; *oo*, olfactory organ; *ot*, olfactory tract; *my*, myelencephalon; *t*, 'twixt-brain; II–X cranial nerves.

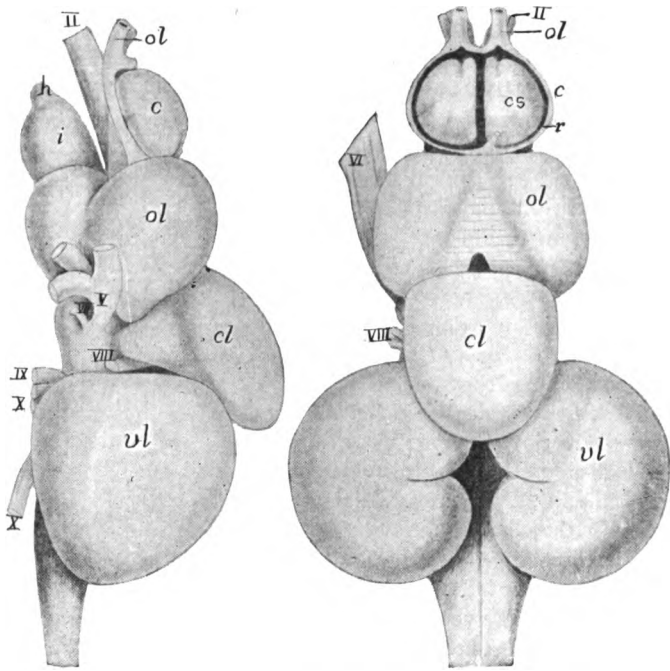


FIG. 173.—Dorsal and side views of brain of buffalo fish (*Carpiodes tumidus*), after Herrick. *c*, cerebrum; *cl*, cerebellum; *cs*, corpus striatum; *h*, hypophysis; *i*, infundibulum; *o*, olfactory lobes; *ol*, optic lobes; *p*, pallium; *v*, ventricle; *vl*, vagus lobes; II-X, nerves.

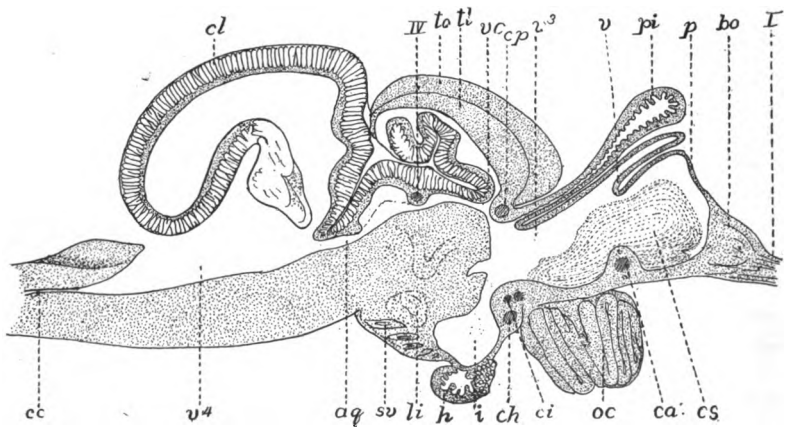


FIG. 174.—Sagittal section of brain of trout, after Rabl-Rückhard. *aq*, aqueduct; *bo*, bulbus olfactorius; *ca*, *ch*, *ci*, *cp*, anterior, horizontal, inferior and posterior commissures; *cc*, central canal; *cl*, cerebellum; *cs*, corpus striatum; *h*, hypophysis; *i*, infundibulum; *iv*, trochlearis nerve; *oc*, optic chiasma; *p*, pallium; *pi*, pinealis; *sv*, saccus vasculosus; *tl*, torus longitudinalis; *to*, tectum of optic lobes; *v*, velum transversum; *v*¹, *v*⁴, ventricles; *vc*, valvula cerebelli.

The brain of *Polypterus* differs from that of other ganoids in several respects. There is no differentiation of cerebral hemispheres; the optic lobes and the cerebellum are moderate, the latter being thin in the median line and the valvula smaller. The medulla oblongata has thin walls and the ventricle is large. The brain has a primitive appearance, but it shows little resemblance to those of the amphibia or of the dipnoi.

DIPNOI.—The brains of *Lepidosiren* and *Protopterus* differ considerably from that of *Ceratodus*. In all the cerebrum is larger than the optic lobes and the olfactory bulb is separated from the cerebrum by a long olfactory tract. In *Ceratodus* the hemispheres are united above by a part of the chorioid plexus, while internally they are separated from the diencephalon by a well-marked velum. The pinealis is long and rests upon a large 'zirbelpolster,' developed as an outgrowth of the roof of the third ventricle in front of the superior commissure. The optic lobes are separated into two hemispheres, while the cerebellum is scarcely more than a transverse plate and is, together with the fossa rhomboidea, covered with a complicated chorioid plexus. In *Protopterus* (fig. 175)

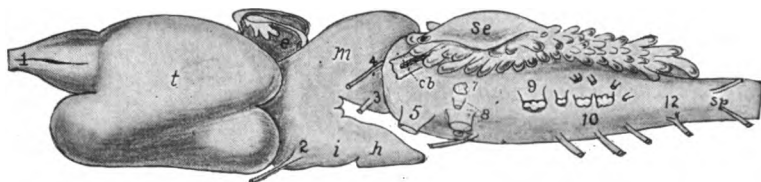


FIG. 175.—Brain of *Protopterus*, after Burckhardt. *ch*, cerebellum; *e*, epiphysia structures; *h*, hypophysis; *i*, infundibulum; *m*, mid-brain; *se*, saccus endolymphaticus *sp*, spinal nerves; *t*, cerebrum; 1-12, cranial nerves.

the elongate hemispheres are parallel, the pinealis and its 'polster' are smaller and the mid-brain has but a single rounded lobe.

AMPHIBIA.—The brain of the amphibia, which shows considerable resemblance to that of the dipnoi, has the parts more distinct than is usual in the vertebrates, and, except in the gymnophiones, the flexures have disappeared in the adult. The hemispheres are separated by a deep longitudinal fissure, but in the anura the two halves of the cerebrum are secondarily connected by a transverse band, just behind the olfactory lobes, leaving a gap farther back. The telencephalon is relatively larger than in fishes, the increase being due in part to the invasion of the pallium by nervous matter, the medial wall being the thicker, while the corpus striatum is in the outer wall. The pallium has the nerve cells in the inner side, the outer being composed of fibres, and there is no trace of a cortex (fig. 176). The diencephalon, broad in the anura, narrower in the urodeles (fig. 176) and cæcilians, is visible from above. Infundibulum and hypophysis are well developed, but the saccus vasculosus and inferior lobes are smaller than in fishes. In the gymnophiones, owing to the pontal flexure (fig. 160) the hypophysis is brought beneath the medulla oblongata. Both paraphysis and pinealis are present, the latter not reaching the cranial roof except in the anura, the conditions in this group having already been mentioned (p. 156). The optic lobes are large and in the anura and to a less degree in the gymnot

phiones, they are paired, but the mid-brain is without external division in the urodeles. The cerebellum is very small, a mere transverse fold on the anterior border of the fossa rhomboidalis, which is scarcely covered in front.

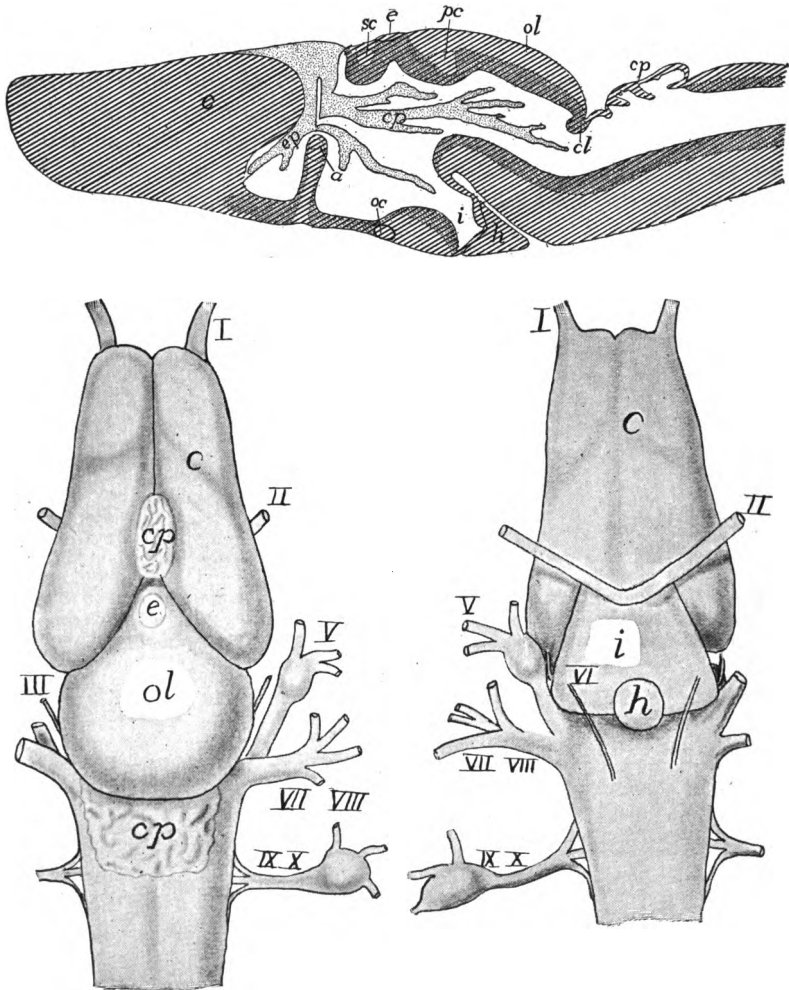


FIG. 176.—Dorsal and ventral views and sagittal section of brain of *Desmognathus*, after Fish. *a*, anterior commissure and rudimentary corpus callosum; *c*, cerebrum; *cl*, cerebellum; *cp*, chorioid plexuses; *e*, epiphysis; *h*, hypophysis; *i*, infundibulum; *oc*, optic chiasma; *ol*, optic lobes; *p*, paraphysis; *pc*, posterior commissure; *sc*, superior commissure; I-X, nerves.

REPTILES.—In the reptiles the brain shows a considerable range of structure, all showing an advance over the amphibia, especially in the greater relative size of the cerebrum, which exceeds the mid-brain, and in the development of a cortex in the pallium. Something is retained of the pontal and nuchal flexures (fig. 178, side view). The cerebral hemispheres are oval or triangular and often

show the beginnings of a temporal lobe (see fig. 178 near *III* and *IV* nerves). The olfactory lobes are merged in the hemispheres and the nerve extends forward from them (see p. 183). The corpora striata are large, reducing the lateral ventricles to slit-like spaces. The great development of the cerebrum and the optic lobes partially covers the roof of the diencephalon, which may develop both the parietal organ and the pinealis, the latter in some forms (e.g., *Sceloporus*) showing an eye-like structure. The parietal eye is well developed in all

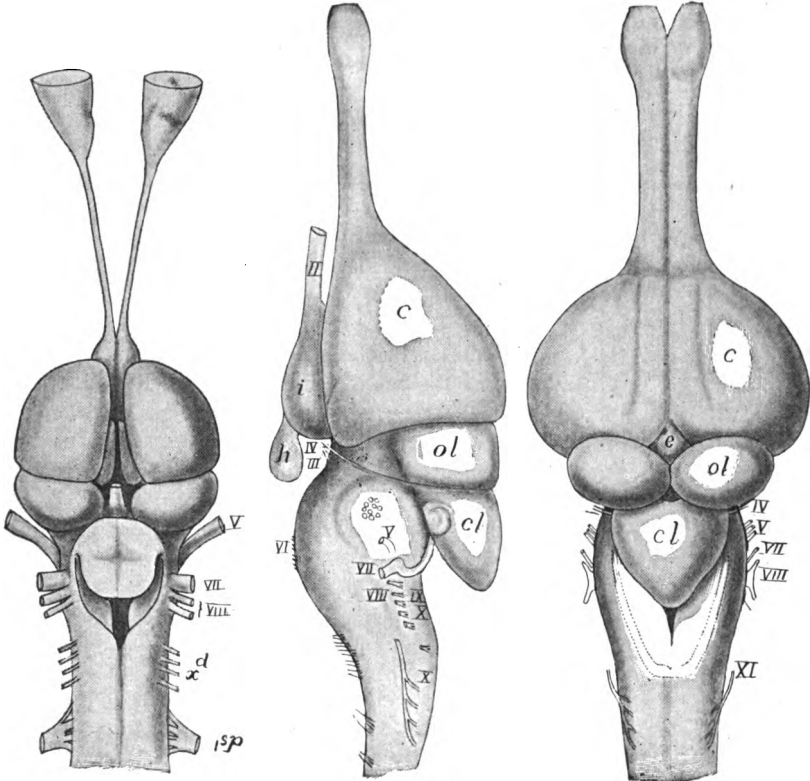


FIG. 177.

FIG. 178.

FIG. 177.—Brain of *Iguana tuberculata* (Princeton, 2293). Compare fig. 194.

FIG. 178.—Side and dorsal views of brain of young alligator, after Herrick. *c*, cerebrum; *cl*, cerebellum; *e*, epiphysial structures; *h*, hypophysis; *i*, infundibulum; *ol*, optic lobes; *II-XII*, cranial nerves.

lacertilia, its position being readily recognized on the top of the head. In other groups it is rudimentary. The great development of the thalami reduces the third ventricle to a vertical slit, and in some groups the walls of the two sides may unite across the median line near the middle of the ventricle, forming an 'intermediate mass' (soft commissure) which reappears in the mammals. The mid-brain bears paired optic lobes. The cerebellum has a considerable range of form. In the alligators it develops on either side a lobe (shown to the

left of the letters *d* in the side view of the alligator brain, fig. 178) which is the first appearance of the flocculus.

AVES.—The brain of the bird is short, broad and more highly specialized, and it retains all three flexures to some extent throughout life (p. 151). The cerebrum is triangular and high, and is usually marked on the dorsal surface by a groove, the vallecule (fig. 179). Its size is largely due to the development of the corpora striata, in which there is an evident differentiation of parts. The hemispheres reach back nearly to the cerebellum, thus forcing the optic lobes to a lateral position so that in some they are invisible from above. This extension of cerebrum and cerebellum results in the covering of the 'twixt-brain so that it cannot be seen in a dorsal view, though the rudimentary pinealis which it bears is seen in the angle between the cerebral and cerebellar hemispheres (fig. 179). The cerebellum is large and its medial portion is transversely furrowed, this part constituting the vermis, while the lower lateral parts form the flocculi. The medulla oblongata is very short and the fossa rhomboidalis is entirely covered by the hinder end of the cerebellum.

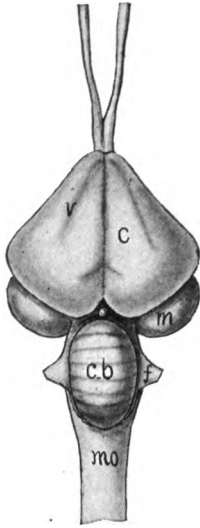


FIG. 179.—Brain of hen. *c*, cerebrum; *cb*, cerebellum; *f*, flocculus; *m*, optic lobes (mid-brain); *mo*, medulla oblongata; *v*, vallecule; the epiphysis shows between cerebrum and cerebellum.

MAMMALS.—The mammalian brain is characterized by the increase in the size of the cerebrum and cerebellum and the relative diminution of di- and mesencephalon, the cerebral increase being almost wholly in the pallium (neopallium) in correlation with the advance in mentality. In the lower mammals the olfactory lobes are at the tip of the cerebrum, but in the higher, the pallial increase causes a forward growth of the frontal lobes (p. 159) so that the olfactory lobes are brought to the lower surface, they and their posterior extensions being separated from the rest of the cerebrum by a rhinal fissure (fig. 164, *r*) on either side. Behind, the cerebral hemispheres always cover the 'twixt-brain, but in the non-placentals and in some lower orders more or less of the mid-brain is uncovered (fig. 180). Still higher in the scale, cerebrum and cerebellum all but meet, and in the primates the cerebrum has grown so far back that it partially or completely covers the cerebellum.

In the lower groups (some rodents, edentates, etc.) there is no development of a temporal lobe, and but little if any folding of the cerebrum. Higher in the scale, and even in the monotremes and marsupials, the pallial increase causes a folding so that the morphologically postero-ventral end of the cerebrum, lateral to the pyriform lobe, is brought below and to the outside of the lateral parts of the hemispheres, the line of folding being marked by a deep fissure of Sylvius, at the bottom of which the covered parts of the side of the hemisphere form the so-called island of Riel. This folding brings the pyriform or hippocampal lobe to the medial side of the temporal lobe, where it may, in part, be visible in a side view (fig. 181) or, as in man, it may be so covered as not to

be seen without a partial dissection. The four lobes of the cerebrum—frontal, parietal, occipital and temporal—are regions rather than sharply limited parts.

The olfactory lobes are enlarged at the end into an olfactory bulb and in mammals with well-developed powers of smell an extension of the lateral ventricle extends into each bulb; but in the aquatic mammals (whales, sirenians and seals) and in the primates the whole olfactory lobe is reduced.

Of the two tracts connecting the olfactory lobe with the regions farther back (p. 160) the ventral or olfactory tract persists, extending back to the hippocampal or pyriform lobe. The more dorsal or hippocampal tract is well developed in the monotremes (fig. 181, *fd*), but higher, with the development of the corpus callosum, it becomes correspondingly reduced and is, in large part, rudimentary in man (fig. 165). The cerebral commissures need no farther mention (see p. 159), but the great development of the neopallium has introduced a new set

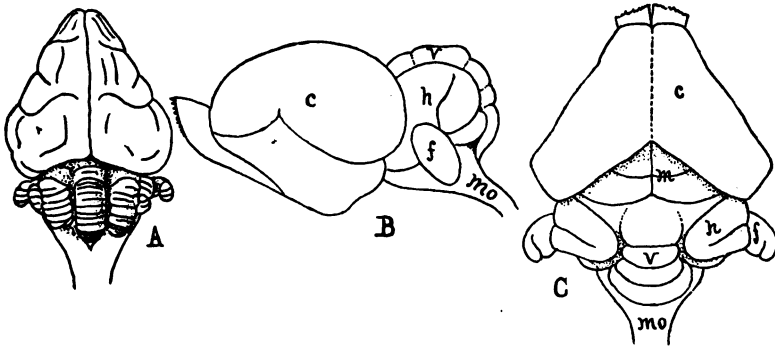


FIG. 180.—A, Dorsal view of brain of kangaroo (*Macropus rufus*), after Ziehen. B and C, lateral and dorsal views of brain of a bat (*Vespertilio murinus*) after Haller. *c*, cerebrum; *f*, flocculus; *h*, cerebellar hemisphere; *m*, mid-brain (*Corpora quadrigemini*); *mo*, medulla oblongata; *v*, vermis.

of fibres, the **corona radiata**, which connect the cortex with the more posterior parts of the brain.

The rich development of fibres connected with the cerebral cortex causes an increase in the thickness of the thalamic region of the diencephalon, as the connexion is made through this region with the parts farther back. One result is the narrowing of the third ventricle, which is farther reduced by the development of an intermediate mass, which, however, is largest in the lower mammals (fig. 181). Prominent among the epiphysial structures is the pinealis (**conarium**) which is completely covered by the cerebrum and can have no visual value. Its stalk is hollow for a distance, but the distal portion contains no nervous matter. In some mammals there is a dorsal outgrowth of epithelium (of the roof plate) just in front of the pinealis (fig. 167). The paraphysis appears in development, but is lost in the adult.

The mid-brain is peculiar dorsally in the presence of two pairs of optic

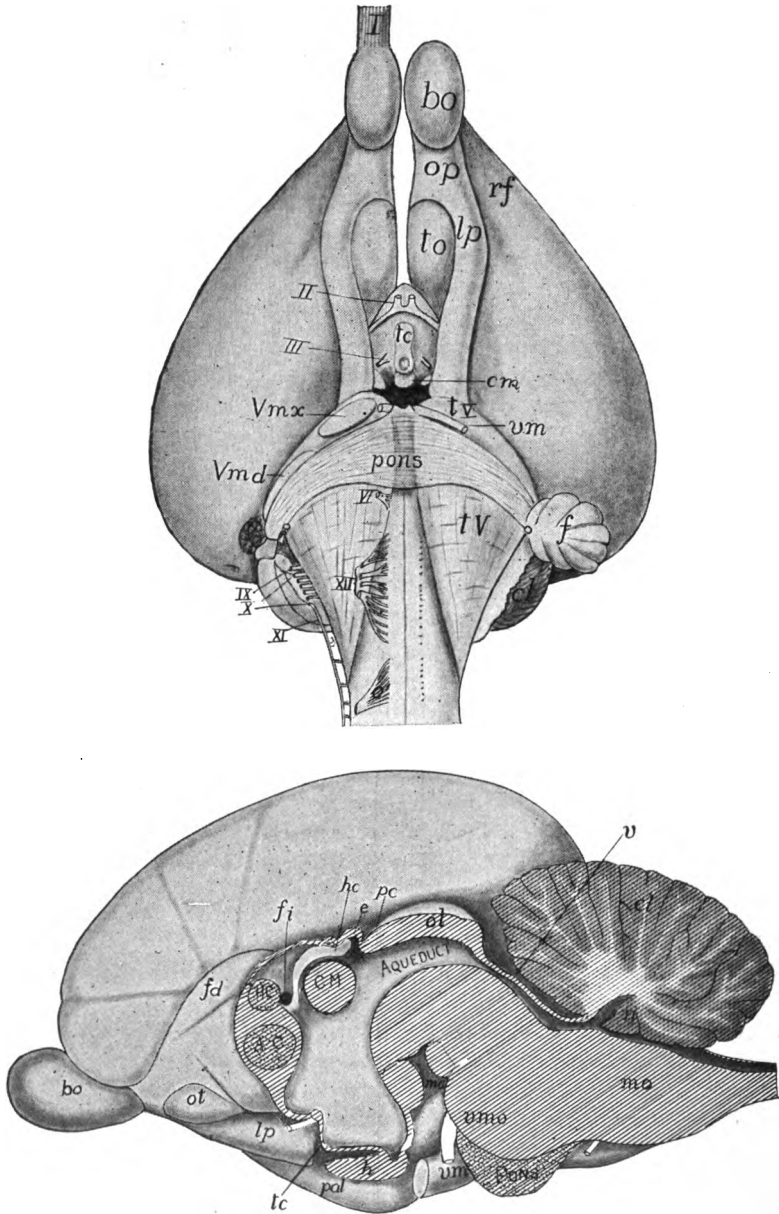


FIG. 181.—Ventral view and median section of the brain of *Ornithorhynchus*, after G. Elliot Smith. *AC*, anterior commissure; *bo*, olfactory bulb; *c*, first cervical nerve; *cl*, cerebellum; *CM*, massa intermedia; *e*, epiphysis; *f*, flocculus; *fd*, fasciculus dentatus (anterior part of hippocampal tract); *fi*, interventricular foramen; *h*, hypophysis; *hc*, habenular commissure; *HC*, pallial (hippocampal) commissure; *lp*, pyriform (hippocampal) lobe; *mc*, mammillary bodies; *mo*, medulla oblongata; *n*, nodulus; *ol*, olfactory lobe; *ot*, olfactory tubercle; *pal*, pallium (temporal lobe); *pc*, posterior commissure; *rf*, rhinal fissure; *tc*, tuber cinereum; *tV*, tuberculum quinti; *v*, velum medullare anterius; *mv*, motor root of V nerve; *vmd*, mandibularis root of V; *vmx*, maxillary root of V.

lobes, the **corpora quadrigemini**, only the anterior pair of which are connected with the optic nerves, the posterior pair being a centre connected with audition. The aqueduct is small in diameter. Behind the mid-brain the roof of the aqueduct is epithelial and is called the **velum medullare anterius** (fig. 181, *v*). The cerebellum is large, and its surface is increased by an extensive folding, the gray matter being on the surface, so that in longitudinal section (figs. 167, 181), it presents a strikingly dendritic appearance, the so-called **arbor vitæ**. The size is largely due to the great development of the cerebellar hemispheres, the vermis and the flocculi (the latter usually subdivided into flocculus and **paraflocculus**) being less conspicuous.

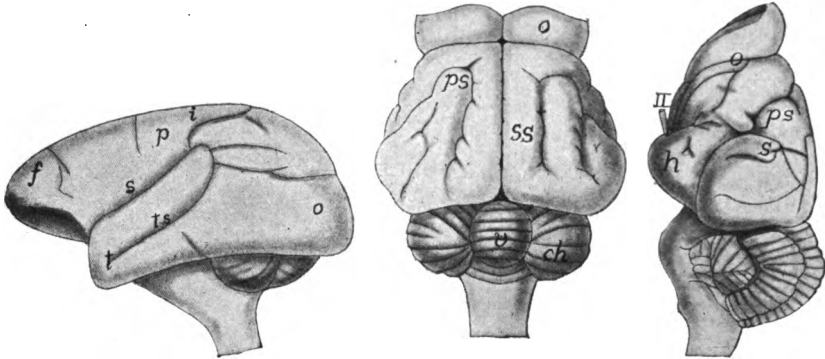


FIG. 182.

FIG. 183.

FIG. 182.—Brain of *Chrysothryx sciureus*, after Weber. *f*, frontal lobe; *i*, interparietal fissure; *o*, occipital lobe; *p*, parietal lobe; *s*, Sylvian fissure; *t*, temporal lobe, *ts*, sulcus temporalis.

FIG. 183.—Brain of *Mani javanica*, after Weber. *ch*, cerebellar hemisphere; *h*, hippocampal lobe; *o*, olfactory lobe; *ps*, presylvian fissure; *s*, Sylvian fissure; *ss*, sulcus sagittalis; *v*, vermis; *II*, optic nerve.

THE PERIPHERAL NERVOUS SYSTEM

THE SPINAL NERVES

The spinal nerves are metameric structures, connected with the spinal cord by two separate portions or roots which differ greatly from each other in development, structure and function. At the time of the closure of the neural tube a band of cells occurs on either side of the neural plate at the junction of neural and epidermal areas. With the closure of the tube these form two bands, the **neural crests**, one on either side of the dorsal surface of the cord (fig. 153). By unequal growth each crest soon develops a series of metameric enlargements, the portions of the crest between these gradually disappearing, while the enlargements form the ganglia of the dorsal roots of the nerves. Each of the cells (neuroblasts), of which each ganglion is composed, like those of the cord, sends out processes, one of which grows medially and enters the cord in the region of the posterior column, where it

sends fibres which extend longitudinally in either the dorsal or the lateral funiculi of the cord; the other process extends peripherally to the skin or viscera, these processes constituting the **dorsal root** of the nerve, the ganglion forming an enlargement upon it, near its connexion with the cord.

The other or **ventral root** is formed by fibres which grow out in a similar way from neuroblasts in the ventral horn of the cord and leave it between the anterior and lateral funiculi, to extend to the muscles, glands, etc. As these ganglion cells are inside the cord, there is no ganglion on the ventral root. Except in the lampreys, the dorsal and ventral roots unite soon after leaving the cord, the combined trunk being a typical spinal nerve (figs. 154, 188).

Physiologically the roots differ in that the dorsal roots are mainly composed of sensory fibres, while the ventral roots contain only motor fibres. That is, on stimulation of the parts to which they are

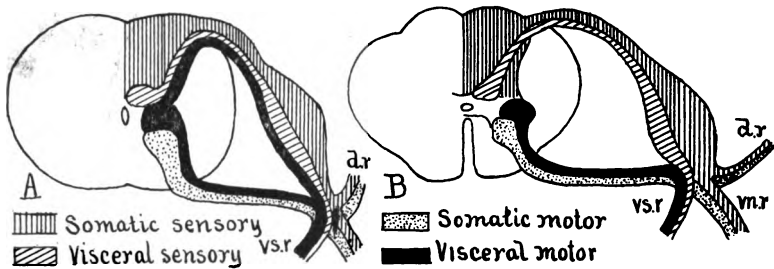


FIG. 184.—Diagrams of spinal cords of (A) fish, and (B) man, after Johnston, showing the relations of the components of the spinal nerves. *dr*, *vn.r*, *vs.r*, dorsal, ventral and visceral rami of spinal nerve.

distributed the dorsal roots and their fibres carry nervous impulses to the cord—they are **afferent**—while the impulses in the ventral roots are carried in the opposite direction by **efferent** fibres. In the latter stimulation arises in the central nervous system and the impulse is carried outward to the parts to which the fibres are distributed, causing these to act—muscles to contract, glands to secrete, etc. Hence the ventral roots are called **motor roots**. Their fibres are without sensory functions, while sensory fibres are equally unable to cause action in any peripheral part (Bell's law).

After a longer or shorter course, each **spinal nerve**, formed by the union of dorsal and ventral roots; divides into three branches, each of which receives both sensory and motor fibres. These are known as the **ramus dorsalis**, **ramus ventralis** and **ramus visceralis** or **intestinalis**. The first goes to the skin and muscles of the dorsal region; the

second to those of the sides and ventral parts of the body; while the visceral branch descends to the roof of the coelom, near the insertion of the mesentery, where it connects with the sympathetic nervous system to be described below (fig. 184).

Recent physiological and histological analysis shows the existence of two groups of nervous elements in both sensory and motor nerves (fig. 184). There are **somatic sensory** and **somatic motor fibres**, distributed to the skin and most of the external sense organs and to the voluntary muscles, and there are also **visceral fibres** of both kinds, supplying the viscera (alimentary canal, excretory and reproductive organs) and the circulatory system. The dorsal and ventral rami contain mostly somatic fibres with a few of the visceral type, while the visceral rami are composed of visceral fibres alone. The farther subdivision of these nerves will be considered later.

To the statement that the dorsal roots are purely sensory the exception must be made that in the lower vertebrates some of the visceral motor fibres, arising in the neighborhood of the lateral column, pass out from the cord through the dorsal root (fig. 184, *A*). In the mammals they are said to leave by the ventral roots like all other motor fibres (fig. 184, *B*).

Spinal nerves are grouped in description according to the region of the vertebral column in which they leave the spinal cord. They are numbered within each region from the vertebra which succeeds them, except that the first nerve behind the skull is the first cervical, with the result that in the cervical region there is one more nerve than the number of vertebræ.

In the regions of the appendages the spinal nerves usually form networks or **plexuses**, branches of a varying number of ventral rami interlacing in a complicated manner before entering the appendage (fig. 185 *B*, *C*). In the lower vertebrates there are two plexuses on either side, a cervico-brachial for the fore limb and a lumbo-sacral for the posterior appendage, these dividing in the higher groups into cervical, brachial, lumbar and sacral plexuses, these receiving their names from the neck, fore limb, and lumbar and sacral regions respectively.

The number of nerves which enter a plexus varies between wide limits, the largest number (about twenty-five) being found in the skates, in correlation with the great development of the pectoral fin. It is of interest that in the snakes and limbless lizards there is a plexus, an indication that these have descended from limbed ancestors, though no other traces of limbs occur in development. From the plexus arise the nerves which enter the limb, there being dorsal and ventral branches for the two sides of the limb. In the

tetrapoda these are grouped into a single chief trunk on either side in the lower groups, while in the mammals there is an additional one on the ventral side.

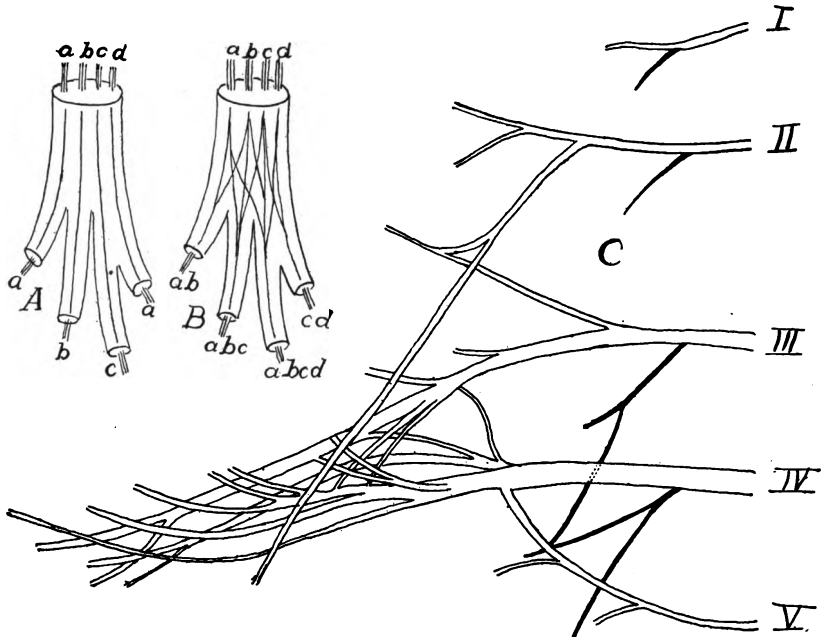


FIG. 185.—A, diagram of collector nerve; B, of a nerve plexus, after Braus; C, branchial plexus of *Salamandra maculata*, after Fürbringer.

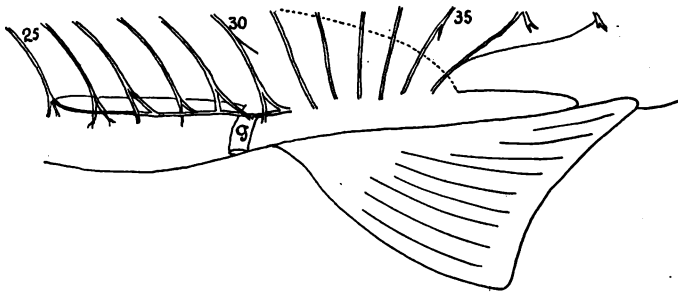


FIG. 186.—Nerves no. 25-37 of a *Mustelus* embryo 24 cm. long, with collector nerve after Punnett. Dotted line shows limit of coelom; g, pelvic girdle.

In the fishes the lumbo-sacral plexus and its nerves is reinforced by a collector nerve which extends from and connects some of the more anterior segmental nerves with the appendage, though without such an exchange of fibres as are found in a plexus. Besides, in the

fishes, some of the spinal nerves may enter the appendage directly without the intervention of a collector or a plexus. The collector disappears in the amphibia.

THE SYMPATHETIC SYSTEM

The sympathetic nervous system possesses much physiological and anatomical individuality. It is entirely removed from control of the will and its function is largely the regulatory control, either directly or indirectly, of the various viscera, glands, blood-vessels, and respiratory and reproductive organs. Much of this control is accomplished by its stimulation or inhibition of the smooth muscle cells of the walls of the blood-vessels, thus, by their enlargement or contraction, regulating the amount of blood supplied to any part. (Not all involuntary activities of the body are directly controlled by it.) Besides, it contains sensory structures, but the stimulation of these does not necessarily result in conscious states.

This close relation of the sympathetic system with the smooth muscles and with the blood-vessels necessitates the extension of parts of the system to all parts of the body, many of the nerve trunks paralleling the blood-vessels; but the main parts are near the mid-dorsal line of the body cavity and are more or less closely associated with the dorsal aorta.

The system is connected with the spinal nerves by the visceral rami (p. 174). As the spinal nerves develop by outgrowths from the spinal ganglia and the neuroblasts of the spinal cord, cells are carried down with them from both sources and these are aggregated in a series of metameric sympathetic ganglia near the aorta. As is seen in figs. 184, 188, the visceral rami are composed of nerve fibres, both motor and sensory, of the visceral series, and by means of these the sympathetic system is in communication with the central nervous system. From this first series, the so-called **chain ganglia**, the system is extended farther by the development of a **prevertebral series of ganglia**—sometimes single, sometimes paired—lying ventral to the aorta (fig. 188) and connected with the chain by metameric nerves. Some of these prevertebral ganglia in the higher groups are of considerable size and have received special names—**cardiac, pelvic and hypogastric ganglia** and **solar plexus**.

In the lampreys the chain ganglia are not connected with each other and they are confined to the region of the body cavity. In the elasmobranchs and perennibranch amphibia a network of fibres

extends from one ganglion to the next, but in many teleosts and in the higher groups (figs. 187, 188) the chain ganglia of a side are connected by a longitudinal **sympathetic trunk nerve**. In these there is also an extension of the system into the head.

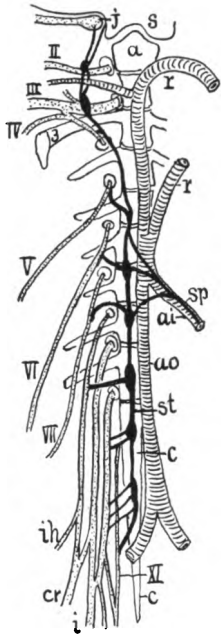


FIG. 187.—Sympathetic system of right side of a frog, after Gaupp. Somatic nerves dotted, sympathetic black. *a*, atlas; *ai*, common intestinal artery; *ao*, aorta; *c*, coccyx; *cr*, crural nerve; *j*, jugal ganglion; *i*, sciatic nerve; *r*, radices aortae; *s*, base of skull; *sp*, splanchnic nerve; *st*, sympathetic trunk; *ih*, iliohypogastric nerve; *II-XI*, second to eleventh trunk nerves.

In the teleosts the cephalic sympathetic ganglia lie beneath the floor of the cranium and are associated with the ganglia of the fifth, seventh, ninth and tenth cranial nerves; there is also an extension of the system to the tip of the tail, the nerves lying in the hæmal arches of the vertebræ. In the perennibranchs the cephalic part of the system extends as far forward as the seventh nerve, its connexion with the more posterior parts being in part by a separate trunk, **Jacobson's commissure** (fig. 189) extending forward from the ninth-tenth roots. In the anura (fig. 187) the cephalic extension reaches only to the tenth nerve. In the amniotes the cephalic part of the system is well developed and is connected with several well-developed ganglia (**cervical, sphenopalatine, otic, submaxillary**, etc.), which also receive nerves from the regular cranial nerves.

In the sympathetic system, besides the visceral sensory and motor elements already referred to, there are elements which may be grouped as purely sympathetic. The ramus visceralis carries fibres which arise either from ganglion cells in the dorsal ganglion or from those in the lateral column (cornu) of the cord (fig. 184). These develop their axons and dendrites which interlace with motor and sensory ganglion cells lying in the chain ganglia (fig. 188, *cg*). From these some nerve fibres extend out to the viscera, while others run backward to course in the dorsal and ventral rami of the spinal nerves to reach the blood-vessels and smooth muscle fibres in the peripheral parts of the body. These purely sympathetic fibres are non-medullated and hence are gray in color, and in the mammals the trunk carrying these from the chain ganglia to the dorsal and ventral branches is called the **gray ramus** (fig. 188, *gr*).

In development some of the cells brought from the spinal cord or ganglion of the dorsal root migrate from the sympathetic parts and pass to various regions of the body, being usually closely associated with the glands of so-called internal secretion—hypophysis, carotid gland, suprarenals, etc. These cells possess a peculiar affinity for chromic acid salts and have been called **chromaffine cells**. Little is known of their function.

THE CRANIAL NERVES

The nerves which arise from the brain and pass out through the foramina in the skull are known as the cranial nerves. While in a general way they resemble the spinal nerves, they have been specialized and modified in many respects in correspondence with the specialization of the head itself, some consisting of sensory fibres alone, some of motor fibres only, while others are mixed, that is, contain both kinds of fibres. One striking difference is that none of the

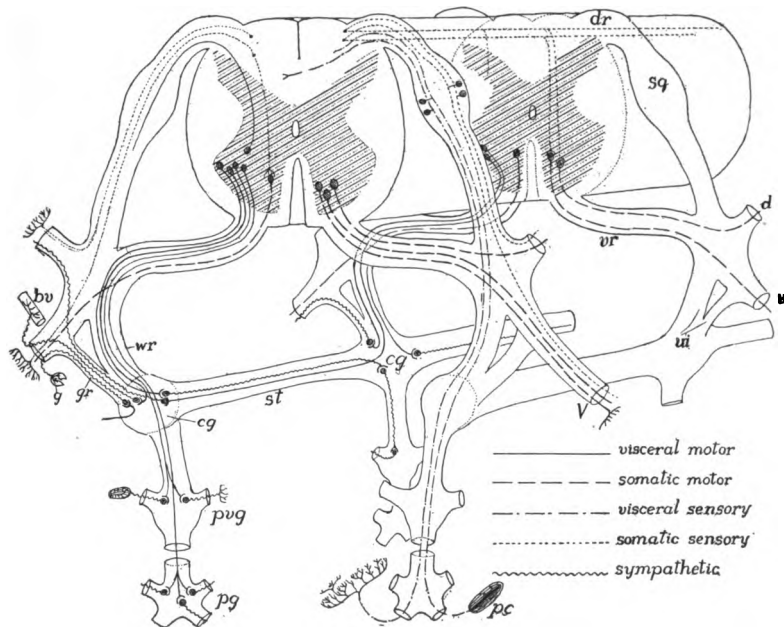


FIG. 188.—Diagram of the relations of the sympathetic system, based on Huber. The character of the different fibres is shown by conventional lines. *bv*, blood-vessel; *cg*, chain ganglion; *d*, dorsal ramus; *dr*, dorsal root; *g*, gland; *gr*, gray ramus; *pc*, Pacinian corpuscle; *pg*, peripheral ganglion; *pv*, prevertebral ganglion; *sg*, ganglion of dorsal root; *st*, sympathetic trunk; *v*, ventral ramus; *vi*, visceral ramus; *vr*, ventral root; *wr*, white ramus.

cranial nerves has two roots, and while those which carry sensory fibres have a ganglion near the root, the purely motor nerves have no such enlargement. In the earlier stages of development one of these nerves (the hypoglossal) has both dorsal and ventral roots, but with later stages the dorsal root and its ganglion are lost. In the ichthyopsida there are ten cranial nerves; in the amniotes two more are added at the hinder end of the brain, giving a total of twelve in the higher groups.

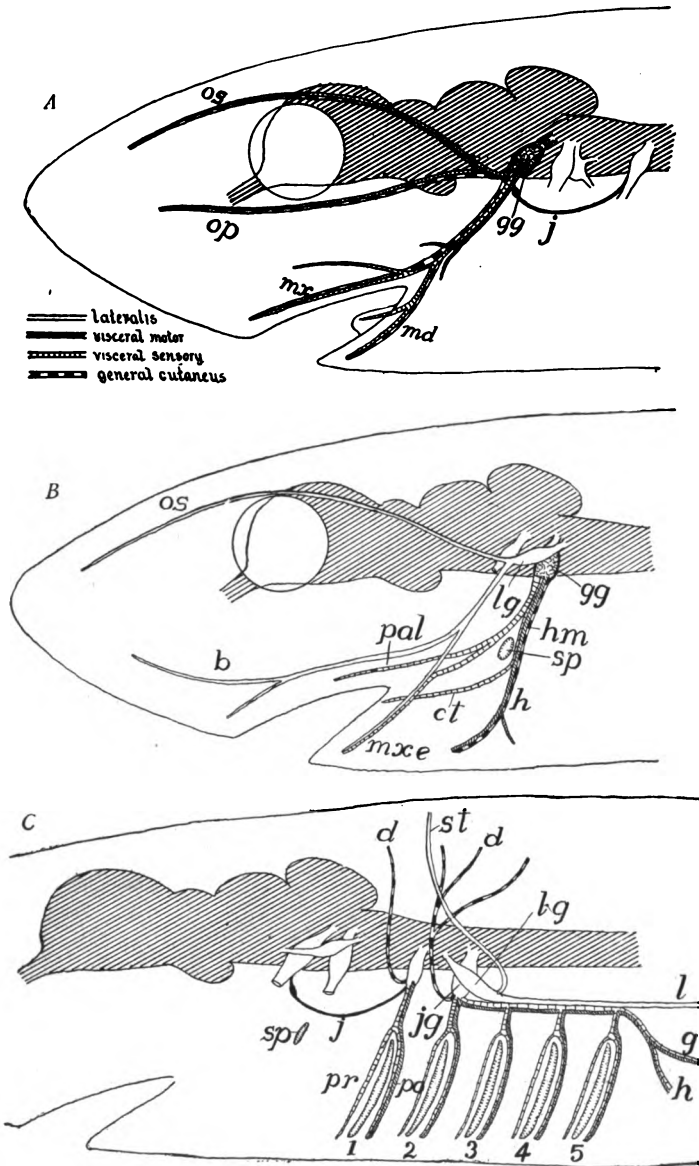


FIG. 189.—Diagrams of the branches and components of (A) the trigeminal, (B) facial, and (C) glossopharyngeal and vagus nerves of a lower vertebrate. *b*, buccalis nerve; *ct*, chorda tympani; *d*, dorsal rami of IX and X; *g*, gastric nerve; *gg*, in A, Gasserian ganglion, in B, geniculate ganglion *h*, hyoid nerve; *hm*, hyomandibular trunk; *j*, Jacobson's commissure; *ig*, jugular ganglion; *l*, lateralis, nerve of X; *lg*, lateralis ganglion; *md*, mandibular nerve; *mx*, maxillaris nerve; *mxe*, maxillaris externus nerve; *op*, ophthalmic profundus nerve; *os*, superficial ophthalmic nerve; *pal*, palatine nerve; *po*, *pr*, post- and pretrematic rami; *sp*, spiracle; *st*, nerve to supratemporal lateral line organs; 1-5, gill clefts.

All of the components of a spinal nerve (somatic sensory, somatic motor, visceral sensory and visceral motor) are distributed among the cranial nerves, and in addition two other components occur—a lateral system and the nerves of special sense, giving a total of six different kinds of conducting tracts. Regarding these a few words may be said. The somatic sensory nerves (called in the head the general cutaneous) terminate in the skin, either as free nerve ends or in special tactile sense organs. The visceral sensory fibres end in taste organs, usually inside the mouth, but in teleostome fishes these may be distributed over the surface of the body. The lateral elements are sensory and terminate in peculiar collections of sense cells, known as **sense hillocks** or **neuromasts** in the ear and in the lateral line organs (p. 195) of the lower (branchiate) ichthyopsida.

Taking components and other facts into consideration, the cranial nerves may be arranged in several groups. Some of these contain but a single component, others are more mixed in character. The constitution of these latter may be seen in general outlines in fig. 189; further details concerning them should be sought in special papers. These groups are as follows:

1. Nerves of special sense—olfactory and optic. These arise from the primitive fore-brain and go respectively to the nose and eye. In several points they are without parallel among the spinal nerves.

2. The eye-muscle nerves—oculomotor, trochlear, and abducens—are somatic motor (with some visceral sensory and motor fibres in the oculomotor). These control the muscles of the eye (p. 133). The hypoglossal is also in the purely somatic motor group, while the accessory is visceral motor.

3. The **acustico-lateralis** system. This includes the acoustic nerve of all vertebrates, and in the branchiate ichthyopsidans, portions of the seventh and tenth nerves which are distributed to the peculiar sense organs of the lateral lines of the head and body. These nerves have a separate centre in the upper anterior end of the medulla oblongata.

4. The fifth, seventh, ninth and tenth nerves, which approach more nearly to a spinal nerve in character. These arise from the medulla, each has only dorsal roots, is ganglionated and contains at least somatic sensory (usually called **general cutaneous** in the head) and visceral sensory and motor components. In addition, as indicated under 3, the seventh and tenth may also include lateral elements. Of these the ninth (fig. 190, IX) is the simplest. It arises

from the dorsal side of the medulla, and just beyond its ganglion it divides into two branches, one (**pretrematic**) going in front of the gill cleft, the other (**posttrematic**) passing behind that opening. In the seventh nerve the same conditions are repeated, the spiracle being but a reduced gill cleft (fig. 143). In the same way the fifth nerve has its pretrematic (maxillary) and posttrematic (mandibular) branches, the mouth in this case being the opening above which the nerve

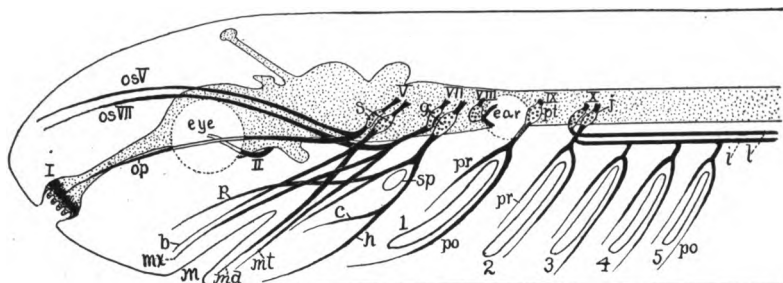


FIG. 190.—Diagram of cranial nerves of lower vertebrate. Eye-muscle nerves omitted; central nervous system dotted, fifth nerve represented as composed of two nerves; lateralis nerves separated from the ninth and tenth nerves. I–X, cranial nerves; 1–5, gill clefts; *b*, buccalis nerve; *c*, chorda tympani; *g*, geniculate ganglion; *h*, hyoid nerve; *i*, intestinal (pneumogastric) nerve; *j*, jugal ganglion, *l*, lateral line nerve of X; *m*, mouth; *md*, mandibular nerve; *mt*, mentalis nerve; *mx*, maxillary nerve; *op*, ophthalmicus profundus nerve; *opV*, *opVII*, superficial ophthalmic nerves of V and VII; *p*, palatine nerve; *po*, posttrematic nerves; *pr*, pretrematic nerves; *pt*, petrosal ganglion; *s*, semilunar (Gasserian) ganglion; *sp*, spiracle.

divides. The tenth, which supplies all of the remaining gill clefts may be regarded as a complex of as many nerves as there are clefts, behind the first, though there is no embryological evidence of distinct roots and ganglia.

The ten (ichthyopsida) or twelve (amniotes) cranial nerves are known by name and by number, the numbers being given in approximate accordance with the exits of the nerves from the brain. Because of their great importance the cranial nerves are described in some detail.

I. The **olfactory nerve (Nervus olfactorius)** extends from the olfactory lobe of the brain (rhinencephalon) to the sensory (olfactory) epithelium of the nose. It differs from all other cranial nerves in that it consists of prolongations (axons) of the sensory cells themselves, and in having no ganglion separate from those cells.

Close analysis shows that two different structures are frequently confused under the term olfactory nerve. The true nerve consists of the fibres (**olfactory threads**) which run back from the olfactory epithelium and terminate posteriorly

in telodendra which interlace with dendrites from (mitral) cells in the olfactory lobe, the interlacings forming oval bodies (**glomeruli**) in the lobe. The position of the glomeruli varies (fig. 191). In elasmobranchs, some teleosts, ganoids, snakes, some lizards, and mammals, the nerve is very short (fig. 191, *A*), while

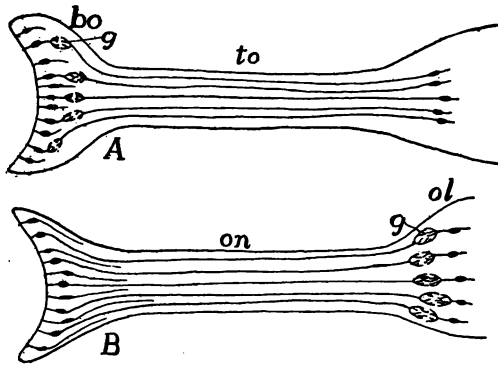


FIG. 191.—Diagrams of the different kinds of olfactory bulb, tract, and nerve. *bo*, olfactory bulb; *g*, glomeruli; *ol*, olfactory lobe; *on*, olfactory nerve; *to*, olfactory tract.

the lobe is drawn out and differentiated into a distal enlargement, the **olfactory bulb** containing the glomeruli, and a slender **olfactory tract**, the bulb being closely applied to the olfactory surface. In some teleosts, amphibia, some lizards and

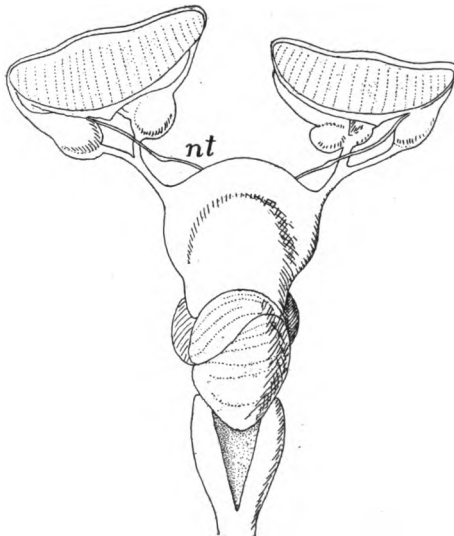


FIG. 192.—Brain and olfactory and (*nt*) terminalis nerves of *Scoliodon* after Locy.

turtles (fig. 191, *B*) the nerve is long and the olfactory lobe is not differentiated into regions. In the gymnophiones the olfactory nerve has two roots, though these are not to be compared with the dorsal and ventral roots of a spinal nerve.

The **terminal nerve** (*Nervus terminalis*) is a very recent discovery (first found in dipnoi and now known to occur in all classes of vertebrates, including man). The terminal (or preoptic nerve, fig. 192), leaves the brain near the base of the olfactory nerve, has its ganglion, and terminates in the mucous membrane of the nose. Its cerebral connexions (it has been traced into the hypothalamus) are uncertain and nothing is known of its functions.

II. The **optic nerve** (*Nervus opticus*) arises from the floor of the diencephalon and extends to the eye, where its branches are distributed over the inner surface of the retina, in the inner layer of which are its ganglion cells. On the floor of the 'twixt-brain the fibres from the right eye pass to the left side of the brain and those of the left eye to the right side, forming a crossing or **chiasma** on the lower surface. From thence the fibres run dorsally and backward and enter the optic lobes. In most vertebrates the chiasma is plainly seen from the outside, but in the cyclostomes it is imbedded in the brain. In the lower vertebrates the chiasma is complete, and the nerves may simply overlap, or the fibres may be variously interlaced. In the mammals the chiasma can only be analyzed by microscopic methods, while in this class the crossing is incomplete, there being crossed and uncrossed fibres, a peculiarity connected with binocular vision.

Several peculiarities of the optic nerve can be understood only on the basis of its development. The eye grows out from the dorsal zone of the fore-brain, the details of the development being given in connexion with that of the eye (p. 214). This outgrowth forms a cup, the distal surface of which is to form the retina. The 'inner' (distal) cells of the cup proliferate the nerve fibres which grow from this point, through a gap in the wall of the cup (the chorioid fissure), back along the stem of the cup to the brain. A continuation in this course results in the chiasma and the connexion with the mid-brain, although the eye starts from the 'twixt-brain.

Both the optic and the olfactory nerves are frequently stated to be outgrowths from the brain, but in the broader sense, neither of them is. The older view was that the stalk of the cup was directly transformed into the optic nerve, a belief which led to the usual statement.

A small **thalamic nerve**, arising between the di- and mesencephalon, has been described in the embryo of some elasmobranchs. It disappears without leaving a trace, unless it contributes nervous material to the ciliary ganglion.

III, IV, VI. **Nervi Oculomotorius, Trochlearis and Abducens.**—These three nerves supply the muscles which move the eye in its socket and, as the **eye-muscle nerves**, may be treated here together (figs. 144, 193). The **oculomotor nerve** arises from the ventral surface of the mid-brain and supplies the superior, medial and inferior

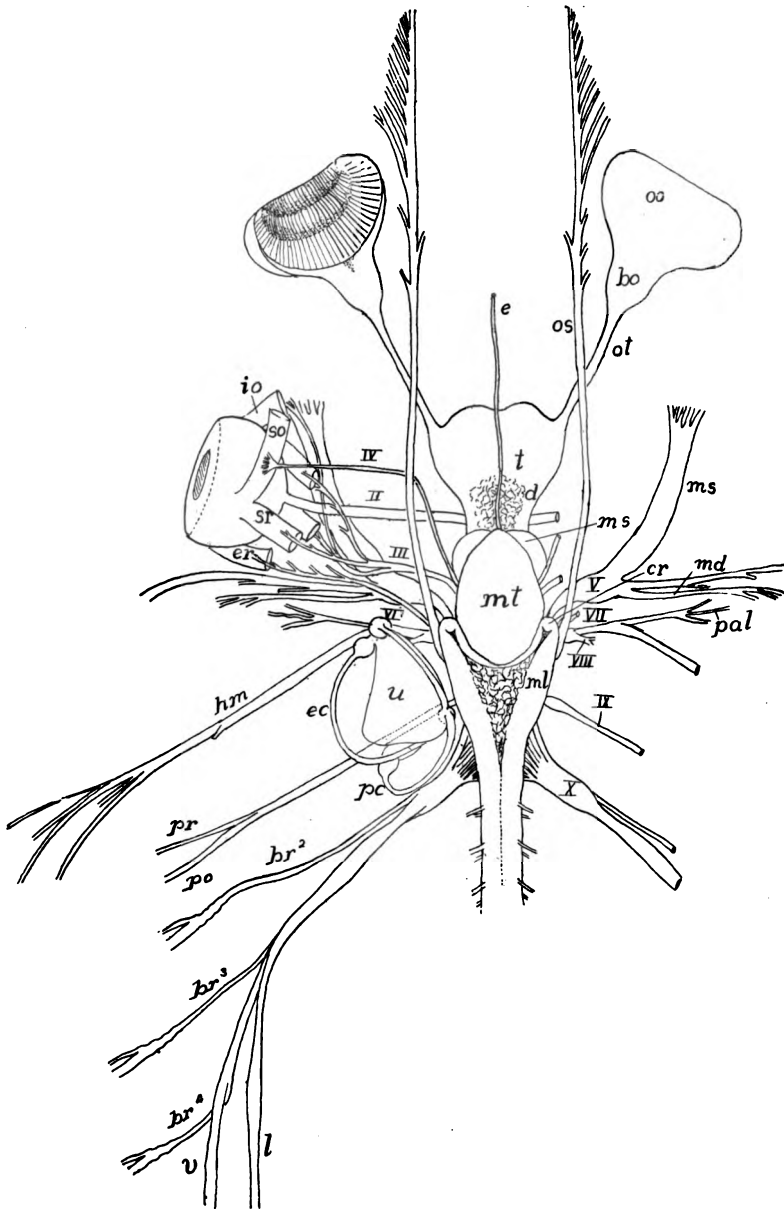


FIG. 193.—Brain and cranial nerves of *Carcharias littoralis* (Princeton 310), natural size. *bo*, olfactory bulb; *br*¹⁻⁴, branchial nerves; *cr*, corpus restiforme; *d*, diencephalon; *e*, epiphysis; *ec*, external canal of ear; *er*, external rectus; *eo*, external oblique; *hm*, hyomandibular nerve; *io*, inferior oblique; *l*, lateral nerve; *md*, mandibular nerve; *ml*, myelencephalon; *ms*, mesencephalon, also, maxillaris superior; *mt*, metencephalon; *oo*, olfactory organ; *os*, ophthalmicus superficialis nerve; *ot*, olfactory tract; *pal*, palatine nerve; *pc*, posterior canal; *po*, posttrematic branch; *pr*, pretrematic branch; *so*, superior oblique; *sr*, superior rectus; *t*, telencephalon; *u*, utriculus; *v*, visceral branch of X; I-X, cranial nerves.

rectus and the inferior oblique muscles. The **trochlear nerve** leaves the dorsal surface of the hinder margin of the mid-brain and goes to the superior oblique muscle. The **abducens nerve** comes from the inferior surface of the medulla and supplies the lateral rectus muscle. In most vertebrates these nerves are readily traced, but not infrequently the abducens is united near its origin with the fifth nerve, while in *Petromyzon* it has not been found, and it is said that all of the eye-muscle nerves are absent from the adult *Bdellostoma*.

The peculiarities and inequalities of the distribution of the three eye-muscle nerves receive their explanation in the development of the eye muscles. These arise from three myotomes (p. 133 and fig. 145), one somite forming three of the rectus and the inferior oblique muscles, the other two somites forming one muscle each. With the division of the myotome into four parts, the oculo-motor nerve continued its distribution to each of the derivatives.

The trochlear nerve is peculiar among all motor nerves in that it leaves the dorsal surface of the central nervous system. It is farther peculiar in having a chiasma in the dorsal surface of the mid-brain, from which its fibres extend downward to the ganglion cells in the floor of the mid-brain. The eye-muscle nerves are the only somatic motor nerves in the head of the lower vertebrates.

V. Nervus Trigeminalis.—The trigeminal is one of the largest cranial nerves. It arises (fig. 193, *V*) from the antero-lateral angle of the myelencephalon (dorsal zone) and bears a large **semilunar** or **Gasserian ganglion** near its origin. This may lie either within or outside the skull. In the higher vertebrates the nerve divides just beyond the ganglion into three main trunks, the **ophthalmic**, **maxillary**, and **mandibular nerves**, whence its name. In the lower vertebrates the maxillary and mandibular are united for some distance.

In the fishes there are two branches of the ophthalmic nerve, an **ophthalmicus superficialis** of the fifth and an **ophthalmicus profundus**. Both are purely sensory. In the higher vertebrates (tetrapoda) only the profundus persists. The chief distribution of the superficialis is the skin of the top of the head and the tip of the snout. The profundus goes between the eye muscles and the eye, sends branches to the eyelids and conjunctiva, and extends to the mucous membrane of the nose. In its course it is connected with the **ciliary ganglion**, of problematic relationships, which receives also sympathetic fibres and sends nerves to the iris and the ciliary muscle of the eye.

The **superior maxillary** nerve runs along the margin of the upper jaw, supplying the face, the lower side of the orbit and the teeth.

In cases where the profundus is reduced the maxillary nerve extends into its territory. In the higher vertebrates it comes into relations with the sphenopalatine ganglion which also receives sympathetic fibres.

The mandibular nerve, going to the lower jaw, runs on the outer side of Meckel's cartilage; in the higher forms, with the development

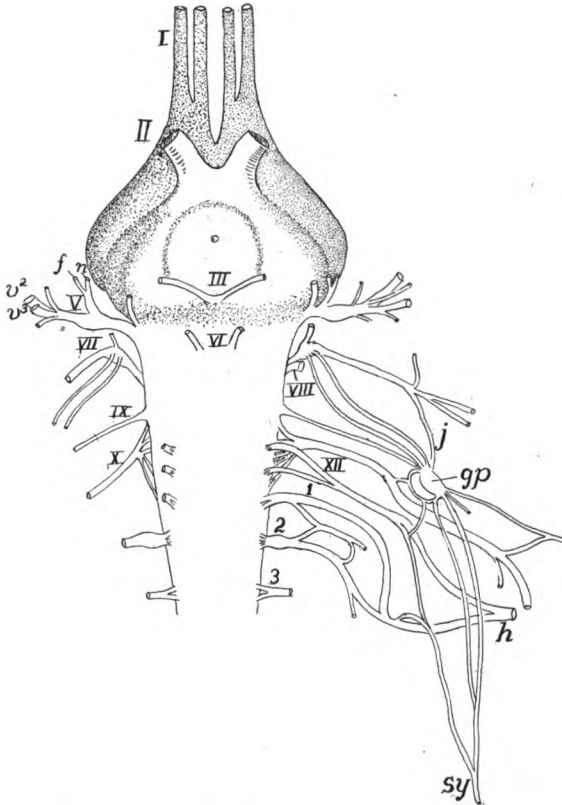


FIG. 194.—Ventral view of brain and cranial nerves of *Iguana*, after Fischer. I–XII, cranial nerves; 1–3, first three cervical nerves; *gp*, petrosal ganglion; *j*, Jacobson's commissure; *h*, hypoglossal; *n*, nasalis ramus of V; *rf*, ramus frontalis of V; *sy*, sympathetic.

of bone, it becomes enclosed in the jaw. It carries motor elements which innervate the muscles of the jaw and also sensory fibres which supply the lips, teeth and, in the mammals, part of the face, and in mammals and some reptiles it sends a branch (**lingual nerve**) into the tongue. In the mammals there is associated with it an **otic** and a **submaxillary ganglion**, with contributions from the sympathetic system.

A number of facts go to show that the ophthalmic branches of the trigeminal nerve really form a distinct nerve, and so it has been represented in figure 190. Among these features the most prominent is that, while the centre of the rest of the fifth nerve lies in the medulla, the fibres of the ophthalmic are traced into the mid-brain (fig. 168).

In teleosts the fifth nerve often sends a nerve backward (the **recurrent or lateralis of the fifth**) along the dorsal side of the body near the dorsal fin. This receives branches from the spinal nerves. In a few fishes this goes also to the paired fins.

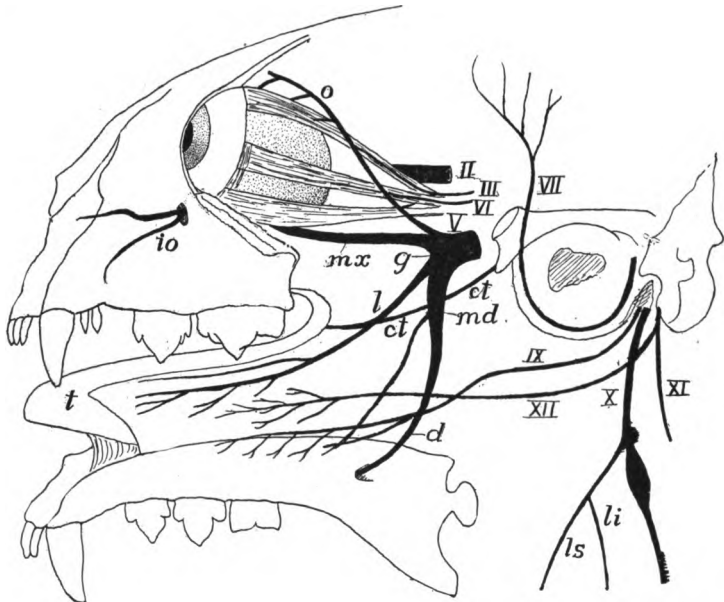


FIG. 195.—Diagram of cranial nerves of a cat, the lower jaw reflected, after Mivart. II–XII, cranial nerves; *ct*, chorda tympani; *d*, dentary nerve; *g*, Gasserian ganglion; *io*, infraorbital nerve; *l*, lingual nerve; *li*, *ls*, laryngeus inferior and superior; *md*, mandibularis nerve; *mx*, maxillaris nerve; *o*, ophthalmic nerve; *t*, tongue.

VII. The **facial nerve (Nervus facialis)** arises from the medulla oblongata just in front of the ear. In the forms with a lateral line component it bears two closely associated ganglia (fig. 190, VII), but in all others only a single **geniculate ganglion**, these being closely associated with the Gasserian ganglion of the fifth nerve in the ichthyopsida. The true facial nerve gives off a **palatine nerve** which runs in the roof of the mouth, and then it divides, just above the spiracle into a pretrematic nerve which goes into the lower jaw, and a posttrematic branch, called the **hyoid nerve** in comparative anatomy. It is the **facial nerve** of man. In the higher vertebrates this hyoid gives off a small nerve, the **chorda tympani**, which soon

unites with the mandibular branch of the fifth nerve and then its fibres enter the lingual branch of the fifth and go to the taste organs of the tip of the tongue. The rest of the facial is largely motor, its fibres controlling the muscles of the neck and those which open the mouth. In the mammals, with a greater development of the facial musculature (p. 139), the facial gains a greater distribution in the facial region, extending to almost all parts of the face.

The *lateralis* element of the seventh has its own ganglion, beyond which the nerve divides into three branches. Of these the **superficial ophthalmic** of VII usually unites with the similarly named nerve of the fifth and supplies the lateral line organs and related structures of the top of the head, dorsal to the eyes. The second branch, the **buccal nerve**, supplies the organs below the eye and along the line of the upper jaw. The last, the **external mandibular nerve**, is connected with the lateral-line organs of the operculum (where present) and the lower jaw. The *buccalis* usually is closely associated with the maxillary nerve and the external mandibular is similarly related to the mandibular ramus of the fifth.

In the higher vertebrates, where the lateral-line organs never appear, the corresponding nerves are not even outlined in the embryo, and in the anura and the salamandrine amphibia, where both organs and nerves are present in the larva, they are lost at the time of metamorphosis.

VIII. The **auditory nerve** (*N. acusticus*) is always closely related to the facial, their ganglia being fused, although the roots are distinct. This nerve is wholly sensory, its two branches (the cochlear and the vestibular nerves) being distributed to the sensory structures of the inner ear. Both the central relations of the nerve and the peculiarities of the ear proclaim that the acoustic nerve belongs with those of the lateral line. In the higher vertebrates this is all that is left of that system.

IX. The **glossopharyngeal nerve** (figs. 190, 193) is the first of the postotic nerves and is more like a spinal nerve than those in front of the ear. It arises from the medulla oblongata close to the tenth nerve and in the amphibia its roots and its ganglion (the **petrosal**) fuse with those of the vagus. In the branchiate vertebrates the nerve goes to the first gill cleft, dividing above it into pre- and post-trematic rami, the pretrematic going to the region of the hyoid arch, the oral cavity and in teleosts to the pseudobranch. The posttrematic branch is larger, supplying the muscles of the first cleft and sending a

lingual branch to the taste organs. In the amniotes the conditions are much the same, although the cleft is closed. The posttrematic branch, here called the pharyngeal nerve, is much the larger.

In the lampreys, elasmobranchs and some ganoids a dorsal nerve is given off from the glossopharyngeal near the petrosal ganglion (fig. 189, *d*) which recalls that of a spinal nerve. It is somatic sensory, supplying the skin on the upper side of the head. In the mammals the **auricular** nerve is similar to this in its general relations. In the ichthyopsida the ninth is connected with the fifth nerve by a trunk called **Jacobson's commissure** (fig. 189, *j*).

X. The **vagus nerve** (fig. 189) is apparently a composite of several metameric nerves like the ninth, with the addition, in the ichthyopsida of a part of the lateralis system. The nerve differs considerably in the ichthyopsida and the amniotes, so, for convenience of description the ichthyopsidan condition will be considered first.

In all vertebrates which respire by gills the vagus arises by a number of rootlets and has two closely associated ganglia, an anterior **lateralis** and a posterior **jugular**, the latter containing both somatic and visceral sensory cells. From the jugular ganglion a single **branchio-intestinal** nerve arises which sends branches to each gill cleft behind the first, these varying in number from four in most forms to six in the lower sharks and lampreys and an uncertain number (see p. 255) in the myxinoid *Bdellostoma*. In lampreys and elasmobranchs each of these branchial nerves bears an **epibranchial ganglion**, but in the teleosts these are fused in the main trunk. Beyond the ganglion each branchial nerve divides above the gill cleft into pre- and posttrematic branches like those of the ninth. Beyond the nerve going to the last cleft the trunk continues as the **intestinal nerve** (**pneumogastric** of human anatomy) to the heart, stomach and air bladder (when present).

The **lateralis** part of the nerves separates from the rest and follows the lateral-line organs of the body back to the tail, running in the partition between the epi- and hypaxial muscles, sometimes near the vertebral column, sometimes just beneath the skin, and sending small nerves to the lateral sense organs. Like the lateralis nerves of the seventh, that of the vagus occurs in all ichthyopsida which have gills, but in the anura and caducibranch urodeles lateral-line organs and nerves are lost at the time of metamorphosis, though they are retained throughout life in the perennibranchs.

In all vertebrates branches of the intestinal nerve enter into close relations

with the sympathetic system. In the myxinooids the intestinal nerves of the two sides unite dorsal to the alimentary canal and continue in that position back to the anus. In some teleosts (plectognaths) the lateralis nerve is greatly reduced. In those bony fishes where the sense organs of the lateral line have migrated above the division between epi- and hypaxial muscles, they may be accompanied by a second, the **superficial lateralis trunk**.

With the absence of gills in the amniotes and their loss in the higher amphibia the lateralis elements disappear and the branchial nerves are reduced, though parts are present as **pharyngeal nerves**. On the intestinal nerve is a **nodose ganglion** (fig. 196, *n*) which may be the equivalent of the epibranchial ganglion of teleosts. In *Sphenodon* the intestinal trunk gives off a series of three metameric nerves (fig. 196) which, in their relations to the aortic arches, recall

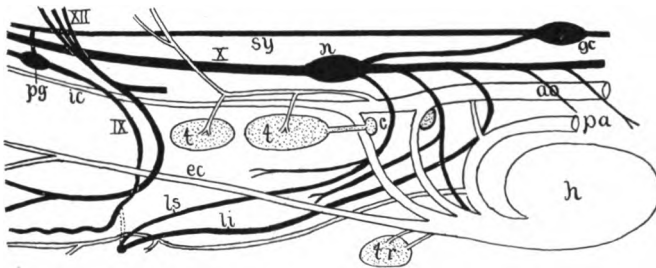


FIG. 196.—Diagram of the neck region of *Sphenodon*, after Van Bemmeln. Arteries white, pharyngeal derivatives dotted, nerves black. *aa*, dorsal aorta; *c*, carotid gland; *ec*, external carotid; *gc*, cervical ganglion of sympathetic; *ic*, internal carotid; *li*, *ls*, inferior and superior laryngeal nerves; *n*, ganglion nodosum; *pa*, pulmonary artery; *pg*, petrosal ganglion; *sy*, sympathetic trunk; *t*, thymus; *tr*, thyreoid.

the branchial nerves of fishes. Apparently the first and third of these are represented in the mammals by the **superior and inferior laryngeal nerves**.

In the tetrapoda the intestinal branch supplies not only the stomach and heart as in the ichthyopsida, but the lungs as well, a point of interest in connexion with the theories of the origin of lungs. The dorsal ramus of the lower fishes is retained as the **auricular nerve** which unites with the similarly named branch of the ninth. In the higher, as in the lower vertebrates, the vagus is connected at several points with the sympathetic system besides the connexion at the jugular ganglion. It may be noted here that, since the vagus is a cranial nerve, its distribution to heart, stomach and lungs, shows that these structures belong morphologically to the head, although they may be far removed from it in the adult.

XI. Accessory Nerve.—This and the next are regarded as cranial nerves occurring only in the amniotes; but in the elasmobranchs nerves are given off from the vagus which innervate the trapezius muscle, and much the same conditions are found in the amphibia. In these classes the centre of the nerve is in the medulla oblongata. In the amniotes the centre of the accessory nerve is in both medulla and spinal cord, parts of it so far back that the posterior rootlets may emerge from the cord near the seventh cervical nerve. These rootlets unite in a trunk which runs forward, inside the cranium, between the dorsal and ventral roots of the spinal nerves, and leaves the skull with or near the vagus. The accessory is a motor nerve and in the amniotes supplies the trapezius and sternocleidomastoid muscles which move the shoulder girdle.

XII. The hypoglossal nerve acquires its full development in the amniotes, though apparently it has its equivalents in the ichthyopsida. In the adult it is purely motor, but in its development in several mammals ganglionated dorsal roots occur which later disappear. The rootlets of the adult are usually two or three in number, sometimes more. They unite to form the hypoglossal nerve which usually unites with the anterior cervical nerves to form a cervical plexus, from which the main trunk goes to the hypoglossal muscles and to the retractors of the tongue (in birds to the syrinx as well).

In many fishes there are small **occipital nerves** which leave the skull behind the vagus, these sometimes having (notidanid sharks) a ganglion on a dorsal root, roots and ganglia reappearing in the embryonic stages of some elasmobranchs, to be lost in later development. These occipital nerves pass backward, dorsal to the gill clefts and then forward to innervate the hypobranchial (hypoglossal) muscles developed from the myotomes at the posterior end of the head (fig. 145, *hyp. n*). They also supply some of the muscles of the pectoral fin. These occipital nerves are the probable homologues of the hypoglossal nerves of the amniotes, which have been taken into the cranium in the higher group.

THE SENSORY ORGANS

The sensory organs are to receive information both from without and from various parts of the body—alimentary tract, muscles, joints, etc.—and to transform it into stimuli to be carried by the nerves to the ganglia, usually those of the central nervous system. This information varies in character and the organs consequently differ in structure according to the impressions they are to receive.

With very few exceptions the characteristic portions of the organs,

the sensory cells, arise from the ectoderm, but accessory parts, chiefly of mesodermal origin, may be so abundant as to form the bulk of the organ. In some cases the organs may remain in connexion with the surface of the body (the parent ectoderm) throughout life, but frequently they sink to a deeper position and become surrounded with a protective sense capsule, while those connected with the sympathetic system may be scattered throughout almost the entire body.

The recipient structures may be of two kinds. In the one (fig. 197) the ends of the nerve receive the impressions from without, often aided by various accessory structures. In the other there are specialized sense cells (fig. 198), the peripheral ends of which bear different kinds of cuticular percipient parts—hairs, bristles, rods, cones, etc.—

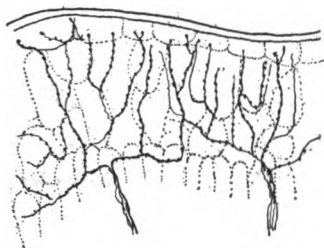


FIG. 197.—Free nerve terminations in the skin of *Salamandra*, freely after Retzius.

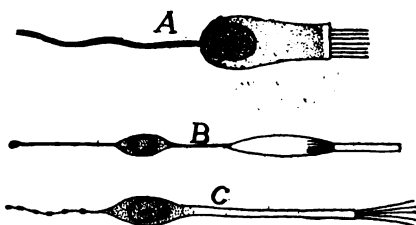


FIG. 198.—Sensory cells, after Fürbringer. A, crista cell of ear; B, rod cell of eye; C, olfactory cell.

while the basal ends of the cells are connected with the terminations of nerve cells which act as the conducting elements. The distinction between the two is one of convenience rather than one of physiological or morphological importance, for the 'nerves' of the first are in reality but the prolongations of sensory cells.

NERVE-END APPARATUS

In many cases—skin, alimentary tract, muscles, etc.—the ends of the sensory nerves lose their medullary sheath and break up into fine fibrillæ which terminate, without special accessory structures, among the cells of the tissue to which they are distributed (**free nerve terminations**). On the other hand, there are numerous **end organs**, especially among the terrestrial vertebrates, in which accessory parts are present. For details of these reference must be made to histological text-books; only a mention of some of the kinds can be made here.

In the simple **tactile corpuscle** the nerve terminates with a cup

in which is seated a lenticular tactile cell (fig. 199, *A*). Somewhat allied are **Grandry's (Merkel's) corpuscles** in which two or more tactile cells are enclosed in a connective-tissue sheath, while the nerve, losing its medullary sheath as it reaches the capsule, expands to plates which are inserted between each two tactile (fig. 199, *B*) cells. In another series of sensory structures the end of the nerve is club-shaped and is surrounded by a connective-tissue sheath, either simple (**cylindrical corpuscles**), or in **Pacini's (Vater's, fig. 200)** and **Herbst's corpuscles**, the sheath is formed by layers of cells, recalling the coats of an onion, while immediately around the club is a layer of cubical cells. Still another variant is found in **Krausse's (corpusculum bulboideum)** and **Meissner's corpuscles**, where the nerve,

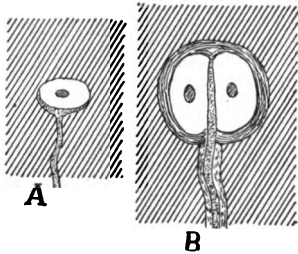


FIG. 199.—*A*, tactile corpuscle; *B*, Grandry's corpuscle.

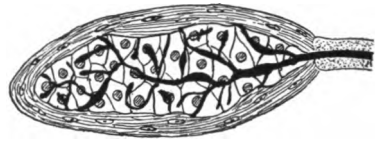


FIG. 200.—Vater-Pacini corpuscle.

on entering the corpuscle, breaks up into numerous branches which surround an axial core of large cells.

It is impossible at present to state with certainty the function of each of these and other nerve-end apparatuses and to say which are connected with the different senses—tactile, pressure, pain, heat and cold, muscular, etc.—which are commonly confused under the term 'touch.'

LATERAL-LINE ORGANS

The lateral-line organs occur only in the ichthyopsida and here only during the branchiate stages. They arise as thickenings of the ectoderm on either side of the head in the neighborhood of the ear. From here the thickenings extend in definite lines which determine the series of organs in the adult. At points on these lines the sensory areas are developed by the differentiation of two kind of cells, the supporting cells, which extend through the epidermis from the corium to the free surface, and the sensory cells, which reach from the surface only part way to the base. The latter are pear-shaped and bear

cuticular hairs or bristles on their free ends (fig. 201), while the deeper ends are embraced by the non-medullated fibrils of the lateralis system of nerves, which follow the lines of organs, and in development keep pace with their extension. These sensory areas are the nerve hillocks or neuromasts already referred to (p. 181).

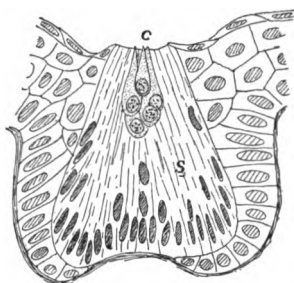


FIG. 201.

FIG. 201.—Sense organ of lateral line of *Diemyctylus* (aquatic form) freely after Kingsbury, *c*, cone cells; *s*, spindle cells.

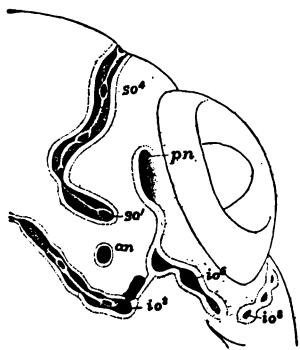


FIG. 202.

FIG. 202.—Developing lateral line organ on one side of head of *Amia*, showing method of closure of grooves to canals, after Allis, *an*, anterior naris; *io*, *so*, infra- and supraorbital lines; *pn*, posterior naris.

In the cyclostomes and aquatic amphibia each sensory patch sinks into a separate pit (fig. 201), but in all other ichthyopsida the *lines* of organs sink in the same way, the patches being connected by

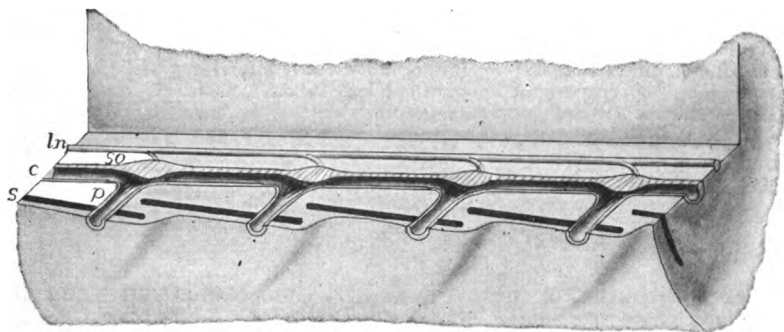


FIG. 203.—Stereogram of lateral-line organs of a fish. *c*, lateral-line canal; *ln*, lateralis nerve; *p*, pores connecting with the exterior; *s*, scales in skin; *so*, sense organs of lateral line.

grooves. In *Chimera* these grooves remain open, but in all others they are closed except at certain points where pores connect the canals formed by the closed grooves with the exterior. In this way the sensory areas come to lie in canals beneath the surface, water

obtaining access to them through the pores. In many teleosts (fig. 203) the pores pass through notches or openings in the scales, while on the head the canals themselves frequently run through some of the cranial bones.

Of considerable morphological importance, especially in connexion with the morphology of the ear, are the facts that the sensory areas multiply by elongation, followed by division, and that the pores themselves increase in the same way (fig. 202); the pore elongates and then its margins meet in the middle, thus producing two pores. There has been much discussion as to the development of the lateralis nerves, especially that of the trunk, some thinking that it

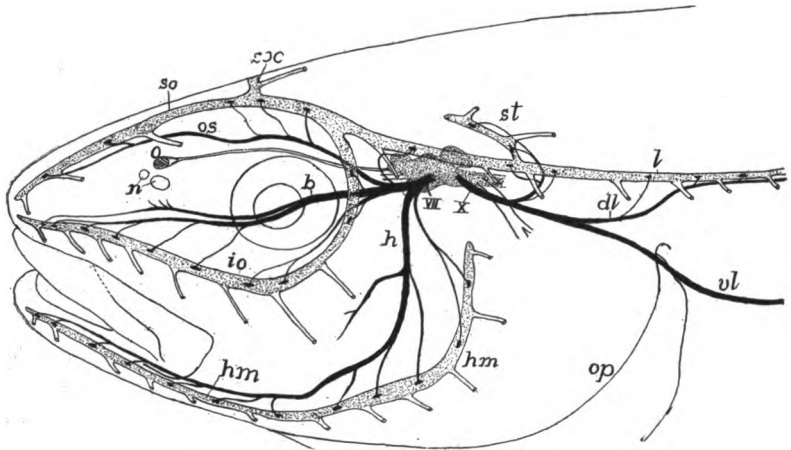


FIG. 204.—Head of pollack, showing lateral-line canals and nerves of the lateralis system, after Cole. Lateralis nerves black, canals and brain dotted. *b*, buccalis ramus of VII nerve; *dl*, dorsal ramus of lateralis of X nerve; *h*, hyomandibularis nerve; *hm*, hyomandibular line of organs; *io*, infraorbital line; *l*, lateral-line canal; *n*, nares; *o*, olfactory lobe; *op*, operculum; *os*, ophthalmicus superficialis nerve; *soc*, commissure connecting lines of the two sides; *so*, supraorbital line of organs; *st*, supratemporal part of lateral line; *vl*, ventral ramus of lateralis of X nerve; *x*, visceralis part of X nerve.

increases by additions from the ectoderm of the skin. It appears more probable that all of its material is derived from the nerve and that there are no additions from other sources.

The distribution of these organs and their canals varies considerably. The most constant lines are the following (fig. 204): A **supraorbital line** running forward from the region of the ear, above the eye, to the tip of the snout and innervated by the superficial ophthalmic branch of the seventh nerve; an **infraorbital line** running in the same way beneath the eye and supplied by the buccalis nerve; a **hyomandibular line** extending along the lower jaw (and the operculum when present), and innervated by the mandibularis externus;

and lastly the **lateral line** proper (sometimes double) which runs back on either side to the tail and is supplied by the lateralis of the tenth nerve. Frequently the systems of the two sides are connected by a **supratemporal line** extending across the hinder part of the skull, from one side to the other (fig. 204, *soc*).

The lateral-line organs appear in the larvæ of all amphibia, but on the assumption of a terrestrial life they sink beneath the skin and usually degenerate, all traces of them and the lateralis nerves being lost in the adult. In a few cases (*Triton*, *Amblystoma*, etc.) they are said not to be entirely lost, but to reappear at the surface when the animals return to the water for oviposition. Various functions have been assigned to the lateral-line organs. Since they contain much mucus they were long called slime organs. Then they were recognized as sensory and a 'sixth sense' was attributed to them. Recently it has been made very probable that they are to recognize vibrations of a slow rate in the water and thus, among other things, to determine currents, etc.

Closely allied to the lateral-line organs in nerve supply are the **ampullæ** of **Savi** and **Lorenzini** which occur in the head of elasmobranchs. Each consists of a long tube, opening by a pore at the surface of the skin and ending with a chambered enlargement, the ampulla, at the deeper end. The tube is filled with a crystal mucus and the ampulla is embraced by fibres of the lateralis nerve. The organs have been supposed to be connected with a pressure sense.

THE AUDITORY ORGANS

Both in character of innervation and in certain peculiarities of development, the sensory parts of the vertebrate ears are closely related to the lateral-line organs. In their most complete expression three parts are recognized in the auditory organs, the outer, middle and inner ears. Of these the last is the essential portion and occurs in all vertebrates, the middle ear first appearing as such in the amphibia and the outer ear, more or less completely developed, is found only in the amniotes.

The Inner Ear arises as a circular area of thickened ectoderm on either side of the head, between the seventh and ninth nerves (fig. 143, *oc*). This soon becomes cup-shaped and then the cup closes in to form an **auditory vesicle** (fig. 205), the cavity of which is connected with the exterior by a slender tube, the **endolymph duct**, the result of incomplete closure. As one portion of the medial wall of the vesicle

develops an area of sensory epithelium like that of the lateral-line system, this stage may be compared to an isolated canal organ with a single pore.

In the amphibia and some of the ganoids, where there is a two-layered ectoderm from the early stages, there is never an open auditory cup. The lower, so-called nervous layer of the ectoderm is alone concerned in the formation of the auditory vesicle, while the outer layer extends as an unbroken sheet across the cup. In the elasmobranchs the endolymph ducts open to the exterior throughout life, the external pores being recognizable on the top of the head. Elsewhere they later lose their external openings, and the distal end of each usually expands into an enlargement, the **sacculus endolymphaticus**, but in the amphibia the ducts of the two sides may unite dorsal to the brain,

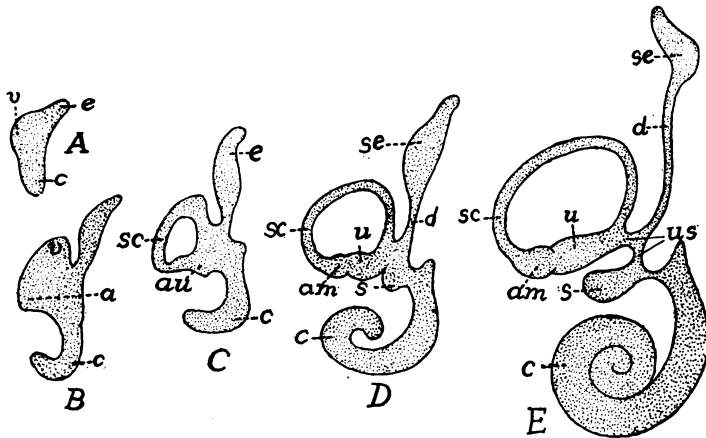


FIG. 205.—Diagram of developing human labyrinth from 6 to 30 mm. long, after Streeter. *am*, ampulla; *c*, cochlear region and cochlea; *au*, ampullo-utricular region; *d*, endolymph duct; *e*, endolymph region; *sc*, semicircular canal; *se*, endolymph sac; *s*, sacculus; *u*, utricle; *us*, utricle-sacculus canal; *v*, vestibule.

while other parts may branch and grow in a root-like manner, in the canal of the spinal cord, sending diverticula (frog) into the so-called calcareous glands, which surround the basal parts of the spinal nerves.

The next stage in the auditory vesicle is its differentiation by a constriction into two chambers, an upper **vestibulum** or **utricle** and a lower **sacculus** (fig. 205), the two connected by a narrow **sacculo-utricular canal**. The sensory area becomes divided between the two. The anterior, posterior and lateral walls of the utricle now produce flattened outgrowths, the lateral in the horizontal, the others in vertical planes, and parts of the sensory areas extend into each. Next, the walls of these diverticula become pinched together so that each pocket is converted into a tube or canal, open at either end into the

utricleus, and hence approximately semicircular in outline (fig. 206). In one end of each of these **semicircular canals** there is a patch of sensory epithelium and the wall expands around this into an **ampulla**, the ampullæ of the anterior and external canals being side by side, that of the posterior canal at its lower end.

In the lower ichthyopsida there is little differentiation in the sacculus, but in the higher a pocket, the **lagena**, is given off from its posterior side, a portion of the sensory epithelium extending into it.

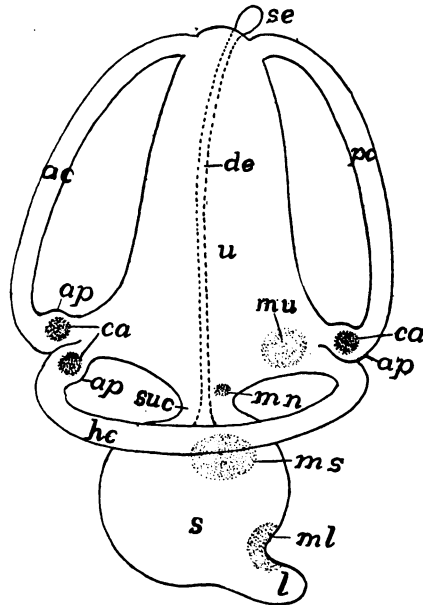


FIG. 206.—Diagram of the membranous labyrinth of a vertebrate, the sensory areas dotted. *ac*, anterior semicircular canal; *ap*, ampullæ; *ca*, cristæ acusticæ in the ampullæ; *de*, ductus endolymphaticus; *hc*, horizontal (external) canal; *l*, lagena; *ml*, *mn*, *ms*, *mu*, maculæ (of lagena, neglecta, sacculi and utriculi); *pc*, posterior semicircular canal; *s*, sacculus; *se*, saccus endolymphaticus; *suc*, sacculo-utricle canal; *u*, utricleus.

With increasing powers of hearing the lagena becomes greatly elongate, until in the mammals it acquires a peculiar development and is known as the **scala media**, the structure and relations of which are described below.

In the cyclostomes utricleus and sacculus are not differentiated. In the myxinoïds there is but a single semicircular canal, with, however, an ampulla at either end. In the lampreys there are two canals, both in the vertical plane, and each with an ampulla at its lower end.

These parts of the internal ear form the **membranous labyrinth**

With the formation of canals, lagena, etc., the sensory epithelium divides into separate areas (fig. 206), some of which (**maculæ acusticæ**) have sensory cells with short hairs or bristles, while others (**cristæ acusticæ**), characteristic of the ampullæ, have cells with longer hairs. The membranous labyrinth is filled with a fluid, the **endolymph**, in which are solid particles, the **otoliths**. These are usually microscopic crystals of calcium carbonate which give the endolymph a milky appearance, but in the teleosts the lime is

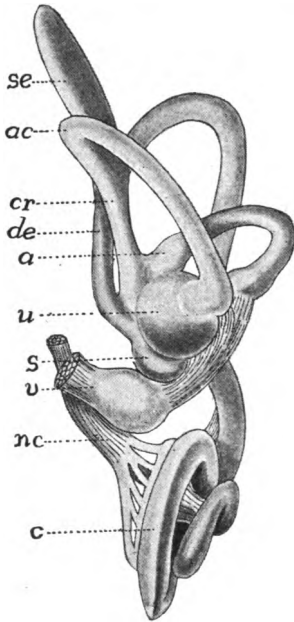


FIG. 207.

FIG. 207.—Labyrinth of human embryo, 30 mm. long, after Streeter. *a*, ampulla; *ac*, anterior canal; *c*, cochlea; *cr*, crus; *de*, endolymph duct; *nc*, cochlear nerve; *s*, sacculus; *se*, endolymph sac; *u*, utriculus; *v*, vestibular nerve.

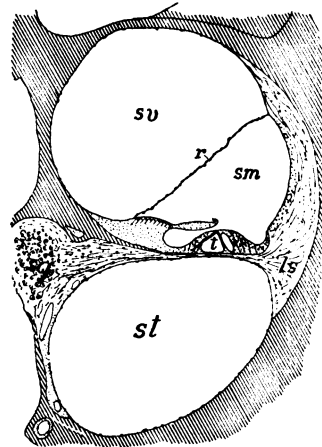


FIG. 208.

FIG. 208.—Section through one of the coils of cochlea of guinea pig, after Schneider. Bone lined; *ls*, spiral ligament; *r*, Reissner's or vestibular membrane; *sg*, spiral ganglion; *sm*, *st*, *sv*, scalæ media (ductus cochlearis), tympani and vestibuli; *t*, tunnel.

aggregated into one or more 'ear stones' of considerable size. In animals with open endolymph ducts (sharks) sand from the exterior may form part of the otoliths.

With the appearance of cartilage the membranous labyrinth becomes enclosed in a protecting otic capsule (p. 67), which usually follows pretty closely the divisions and canals of the epithelial parts, thus forming the **skeletal labyrinth**, separated from the membranous labyrinth by a slight gap filled with fluid (the **perilymph**). When

ossification occurs the skeletal labyrinth is converted into the several otic bones (p 75). Sometimes the perilymph space is separated from the brain cavity by membrane alone, but usually firmer structures intervene, interrupted only by foramina for the passage of nerves and blood-vessels, for the endolymph duct and for a similar **perilymph duct** which extends downward. On the other hand, in all vertebrates in which the middle ear is developed the lateral part of the skeletal wall has two openings into the middle ear. The lower of these (fig. 210), the **fenestra tympani (f. rotunda)**, is closed by membrane. In the upper (**fenestra ovale** or **vestibuli**) the membrane supports a small cartilage or bone, the **stapes** (p. 81).

One part of this compound skeletal and membranous labyrinth of the mammals becomes very complicated. The **lagena** becomes greatly

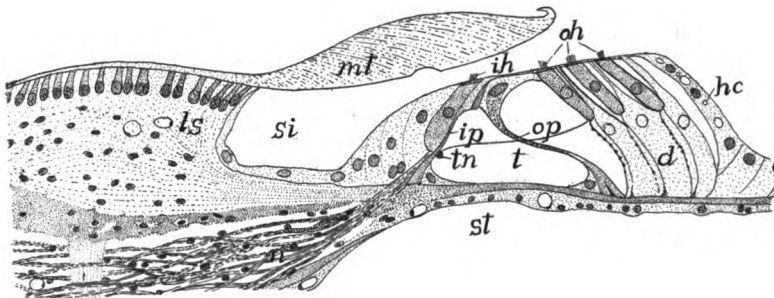


FIG. 209.—Organ of Corti of guinea pig, after Schneider. *d*, Deiter's cells; *hc*, Henson's cells; *ih*, inner hair cells; *ip*, inner pillar cells; *ls*, limbus spiralis; *mt*, membrana tectoria; *n*, nerve fibres; *oh*, outer hair cells; *op*, outer pillar cells; *si*, inner sulcus; *st*, scala tympani; *t*, tunnel; *tn*, tunnel nerve.

elongated and in order to accommodate its length it is coiled in a spiral (fig. 207, *c*), its sides reaching the walls of the skeletal labyrinth on either side. In this way the perilymph space is divided into two spiral tubes (fig. 208), called **scalæ**, from their resemblance to spiral stairways. The upper of these is the **scala vestibuli**, the lower the **scala tympani**, while the **scala media** or **cochlear duct** is formed by the lagena. This whole part of the inner ear is the **cochlea**, so-called from its resemblance to a spiral shell.

The sense organ of the scala media is very specialized and is known as the **organ of Corti** (fig. 209). In general it may be said that the scala diminishes in width from apex to base of the cochlea, and is accompanied in its coils by a branch (**cochlear**) of the acoustic nerve. The sensory structures consist of **hair cells** and **Deiter's cells**, regularly arranged, and a series of **pillar cells**, inclined to each

other like the rafters of a roof, in an A-like manner (fig. 209, *ip*, *op*). As the A's diminish in width from apex to base of the cochlea, this part has been thought to play a part in the recognition of pitch. There is also a cuticular structure, the **membrana tectoria**, which extends from the medial wall out over the hair cells, and this may be the intermediate organ of stimulation and may have to do with the recognition of sound waves of different rapidity. It has recently been shown that the membrana tectoria is connected with the hairs of the hair cells. The fact that in birds, where pitch is certainly recognized, there is no organ of Corti, renders all speculation doubtful.

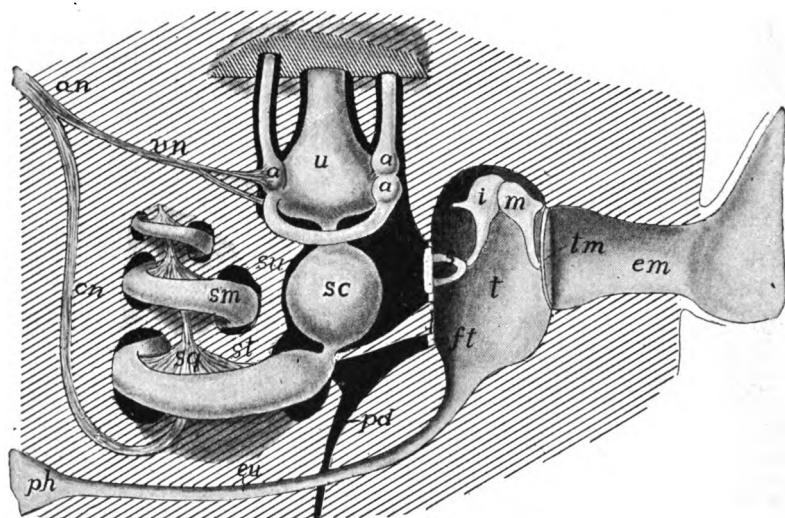


FIG. 210.—Diagram of mammalian ear. *a*, ampullæ of semicircular canals; *an*, acoustic nerve; *cn*, cochlear nerve; *em*, external auditory meatus; *eu*, Eustachian tube; *ft*, fenestra tympani; *i*, incus; *m*, malleus; *p*, perilymph space (black); *pd*, perilymph duct; *ph*, pharynx; *s*, stapes; *sc*, sacculus; *sg*, spiral ganglion; *sm*, *st*, *su*, scalæ media, tympani et vestibuli; *t*, tympanic cavity; *tm*, tympanic membrane; *u*, utricle; *un*, vestibular nerve.

The **Middle Ear** or **tympanum** (fig. 210) first appears in the anura. It consists of a cavity (**cavum tympani**) in front of and below the otic capsule, connected by a slender duct, the **Eustachian** or **auditory tube**, with the pharynx. Externally it is separated from the outer world by a thin partition, the **tympanic membrane**, from which a chain of bones, the ossicula auditus (p. 80), extends across the cavity to the fenestra ovale, and serves to transmit the sound waves to the inner ear. The tympanic cavity is the homologue of the spiracular cleft of the elasmobranchs (see respiration), but it never breaks through. The tympanic membrane, covered externally with ecto-

derm, on the inner surface with entoderm, represents the imperforate wall of the cleft, while the Eustachian tube is the narrowed internal end of the spiracle. The chain of ear bones has already been described. It is to be noted that the chain consists of columella and stapes in anura and sauropsida, while in the mammals columella is replaced by incus and malleus. In the urodeles and gymnophiones, where no tympanic cavity is developed, the quadrate articulates with the stapes.

The External Ear.—In the anura and in many reptiles the tympanic membrane is flush with the surface of the head, but in other reptiles and in birds it is at the bottom of a canal, the **external auditory meatus**, the simplest expression of an external ear. In the mammals (whales, sirenians and some seals are exceptions) an **external conch** is developed behind the meatus to collect the sound waves and to direct them to the inner parts. In some birds the feathers are arranged around the meatus so as to play the same part. The conch is strengthened by cartilage and is moved by muscles (fig. 149). There is evidence which points to the conch being homologous with either the operculum of fishes or with the first external gill of amphibians.

Functions.—The vertebrate ear is primarily an organ of equilibration by which the animal recognizes all changes of position. Though the purposes of the various parts are not accurately known, the following conclusions seem warranted. Every movement of the head affects the endolymph and the contained otoliths, causing them to move (by gravity or by momentum, or by both) over the *cristæ acusticæ* in the ampullæ and the *macula utriculi* and thus to stimulate the sense cells and nerves. The position of the semicircular canals in approximately the three dimensions of space would seem to afford a means for the recognition of the directions and amounts of the components of any motion. The *maculæ*, and especially that of the *lagena*, are probably concerned in the recognition of sound. In the fishes the *lagena* is poorly developed, and while some fishes have been proved to hear, others have given negative results. With the terrestrial vertebrates the sound percipient functions of the ear are beyond a doubt, while they still retain their equilibrational use. The sound waves strike the tympanic membrane, are carried across the middle ear by the auditory ossicles, and set the perilymph in motion and thus affect the parts of the membranous labyrinth.

ORGANS OF TASTE

The sense of taste is resident in groups of cells known as **taste buds**. These differ morphologically from the lateral-line organs in having each sensory cell extend the depth of the bud, ending at the basal membrane, while the majority of the supporting cells are on the outer side of the bud. Each sense cell bears a short, bristle-like percipient structure on its free end, while the basal end is embraced by the fibrillæ of the nerve. According to some accounts of the development the taste buds are derived from the entoderm, the only case apparently established for the origin of sense organs except from the ectoderm, but this has not been demonstrated beyond a doubt. In the higher vertebrates the organs are restricted to the cavity of the mouth where (mammals) they occur on the tongue, especially on and near the circumvallate papillæ, on the soft palate and on the epiglottis. In the fishes the distribution is much wider, for they are found in the pharynx, on the gills, and in many species on the surface of the body, even upon the tail. The barbels about the mouth of many forms are richly supplied with these organs.

The taste organs are supplied by different nerves. Apparently those of mammals are supplied by the chorda tympani and the lingual branch of the ninth nerve. In the fishes those of the pharyngeal region are supplied by the posttrematic branches of the glossopharyngeal and vagus; those of the mouth by the palatine and mandibular branch of the seventh; while those on the head of teleostomes are supplied by the ophthalmic and maxillary branches of the fifth; and those of the trunk by the 'nerve of Weber' formed by fibres from the seventh and sometimes of the tenth nerves.

OLFACTORY ORGANS

While the senses of smell and taste are closely associated physiologically, being what might be called the chemical senses, the organs concerned differ considerably in structure and relations. The olfactory epithelium is always restricted to one or two patches at the anterior end of the head and differs from the taste buds in histological structure. Both sensory and supporting cells of the olfactory organs are variously constituted. The supporting cells are the stouter, some being ciliated, some muciparous at their free ends. The sense cells (fig. 198, C) are thread-like or rod-like, being greatly expanded around the spherical nucleus, while the basal end of each contracts to a nerve fibre which extends back to the olfactory tract (p. 183), where

the dendrites, interlacing with those of the olfactory lobe, form the glomeruli. In the higher vertebrates a third kind of cells, the basal cells, occur at the base of the olfactory epithelium.

The olfactory epithelium arises as part of the surface ectoderm of the top of the head, but with growth it changes its position. For protection it sinks beneath the surface as an **olfactory sac**, connected with the external world by (usually) a pair of openings, the external nares. The growth of the dorsal side of the head carries the nares toward the tip of the snout and, in the elasmobranchs, to the ventral side of the head.

The accessory parts of the olfactory organs are the skeletal nasal capsules (p. 69), which are always present; in the tetrapodous forms glands to keep the epithelium moist, and the organ of Jacobson. The involution of the nasal sacs necessitates some mechanism for bringing the external medium (water or air) to the sensory cells. These will be described in connexion with the several groups below. The **organ of Jacobson** is a kind of accessory olfactory organ, first appearing in the amphibia, supplied by the first and fifth nerves and apparently serving to test the character of the food while in the mouth. The position of the organ near the internal nostrils lends probability to this view of the function.

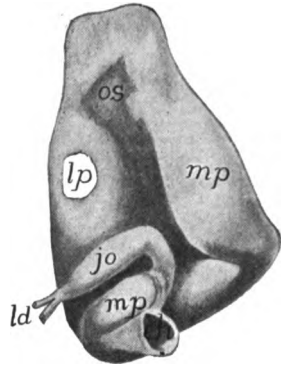


FIG. 211.—Nasal organ of caecilian (*Epicrionum*), after Sarasin. *ch*, choana; *jo*, organ of Jacobson; *ld*, lacrimal duct; *lp*, sateral cavity; *mp*, middle passage; *os*, olfactory sac.

The cyclostomes differ markedly from the other vertebrates in their olfactory organs. The unpaired area of olfactory epithelium develops in the region of the anterior neuropore (p. 12) and becomes carried in with the involution for the hypophysis (fig. 212) so that there is but a single external opening, serving for both olfactory organ and hypophysis. Hence cyclostomes, having but a single nostril, are called monorhinal, in comparison with all other vertebrates which have two nostrils (amphirhinal). The median opening or naris of the cyclostomes connects with a **naro-hypophysial duct**, on the upper, posterior wall of which is the olfactory sac, formed of pairs of lateral folds (fig. 213) covered with the olfactory epithelium and supplied by a pair of olfactory nerves. The lower part of the duct, now purely hypophysial, descends to the hypophysis on the ventral side of the brain, where it either ends blindly (petromyzons) or opens into the dorsal part of the oral cavity (myxinoids). In the latter group the olfactory organ is surrounded by a complicated nasal capsule of enormous size (fig. 171).

All other vertebrates have paired olfactory areas, and paired nostrils (nares) are developed in connection with them, and they have at no time any relation to the hypophysis. The mechanism for bringing the water or air to be tested to the olfactory surface differs accordingly as the animals are air or water breathers. In all fishes,

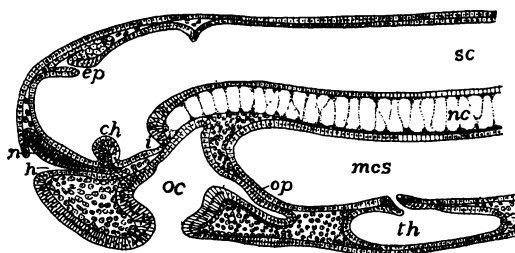


FIG. 212.—Longitudinal section of head of 19 day *Petromyzon* embryo. *ch*, optic chiasma; *ep*, epiphysal outgrowth; *h*, hypophysal ingrowth; *mes*, mesenteron; *n*, nasal epithelium; *nc*, notochord; *oc*, oral cavity; *op*, oral plate; *sc*, canal of spinal cord; *th*, thyroid.

with the exception of the dipnoi, the sensory surface is at the bottom of a pit with no connexion with the alimentary canal. In the elasmobranchs, in order that water may flow more readily through this pit, a fold is developed on one side of each naris, which practically divides it into two. In many teleosts there is an actual division of

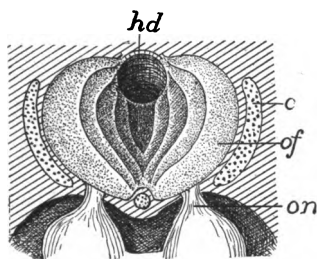


FIG. 213.

FIG. 213.—Nario-hypophysial region of *Petromyzon*, from above. *c*, cartilage of nasal capsule; *hd*, nario-hypophysial duct; *of*, folds of olfactory membrane; *on*, olfactory nerve.

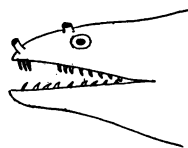


FIG. 214.

FIG. 214.—Head of *Murana*, after Jordan and Evermann, showing double nostrils.

each primitive nostril into two, which may be at some distance from each other, often at the ends of prominent tubes (fig. 214). Inside the nasal capsule the olfactory epithelium is variously folded in order to increase the sensory surface, often forming a labyrinth of considerable complexity (fig. 215).

In air-breathing vertebrates, beginning with the dipnoi, means are

developed for drawing air over the sensory surface, the first traces of which are seen in the elasmobranchs. These frequently have an

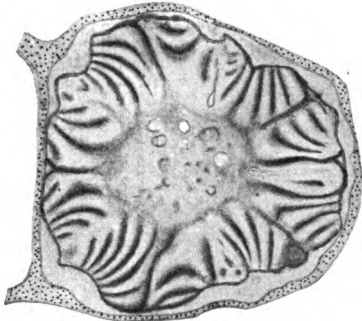


FIG. 215.

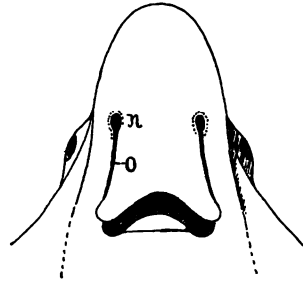


FIG. 216.

FIG. 215.—Section through one nasal labyrinth of *Polypterus*. The nerve runs through the centre.

FIG. 216.—Head of skate (*Ætobatus*) after Jordan-Evermann, showing oronasal groove (o) leading from naris (n) to mouth.

oronasal groove, leading from each naris to the angle of the mouth (fig. 216). In some species this groove is practically converted into

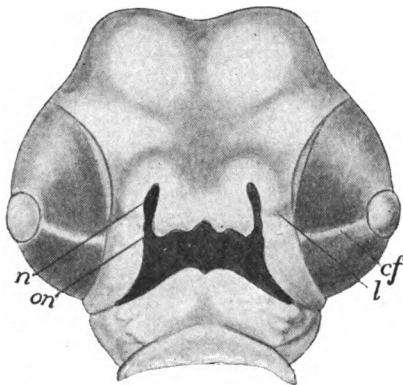


FIG. 217.

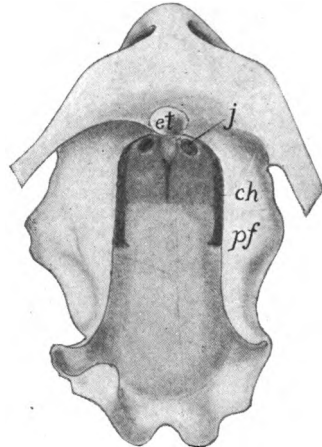


FIG. 218.

FIG. 217.—Head of chick of 5½ days, showing development of oronasal canal, after Keibel. *cf*, chorioid fissure; *l*, thickening for lacrimal duct; *n*, nasal pit; *on*, oronasal groove.

FIG. 218.—Model of mouth of *Echidna* embryo, after Seydel, showing method of ingrowth of palatal folds (*pf*) to cut off secondary nasal passages. *ch*, primitive choanæ; *et*, egg tooth; *f*, opening of Jacobson's organ.

a tube by the meeting of the walls below. Beginning with the dipnoi and continuing with the amphibia and amniotes (fig. 217) a similar groove is formed on either side before the formation of skeletal parts

This closes in, the edges of each groove uniting, so that a tube or duct is formed, leading from the naris into the oral cavity, where an **internal naris** or **choana** occurs (fig. 218, *ch*). Later maxillary and premaxillary bones arise ventral to the narial passage, so that the ducts appear to run through the skull. The position of the choanæ varies considerably, being just inside the jaws in the amphibia and lower reptiles, farther back in the higher reptiles and the birds and mammals, the nasal passages being cut off from the roof of the primitive mouth by the ingrowth of the palatal processes of the maxillary bones and higher, by similar extensions of the palatines, and in some cases, of the pterygoids (fig. 218).

Incomplete closure of the oronasal groove results in the deformity known as 'hare-lip' externally, while 'cleft-palate' is the result of failure of palatines and sometimes of maxillaries to meet below the nasal passages.

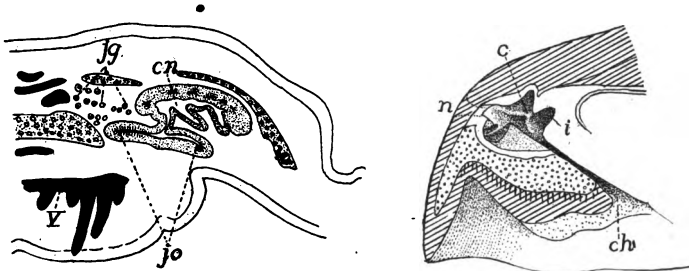


FIG. 219.

FIG. 220.

FIG. 219.—Section through the nasal region of *Siren*, after Seydel. *cn*, nasal cavity, *ig*; Jacobson's gland; *jo*, organ of Jacobson; *v*, vomer.

FIG. 220.—Section of nose of *Chelonia cauwana*, after Gegenbaur. *c*, concha; *ch*, choana; *i*, inner olfactory groove; *n*, projection of naris between dotted lines.

In the dipnoi the olfactory membrane forms a few large folds on the dorsal side of the respiratory duct formed from the oronasal tube. In the amphibia the sensory surface has a similar position on the upper medial surface (fig. 219), with frequently a lateral pocket lined with sensory epithelium, the beginnings of an organ of Jacobson. In the same group glands (inner and outer **Jacobson's glands**) occur for moistening the olfactory epithelium. Usually there is little complication of the olfactory surface, but in a few urodeles (*Plethodon*) there is a projection from the lateral wall, the first indication of the **conchæ** which acquire such development in the higher groups. There is frequently a differentiation of the nasal passage into a ventral **respiratory duct** lined with ordinary and a more dorsal **olfactory duct** lined with sensory epithelium. In the lower urodeles the diverticulum representing the organ of Jacobson is on the medial

side of the nasal cavity; a little higher it is ventral, while in the highest urodeles it has rotated to the lateral side. It may be noted that some of the amphibia have smooth muscles to close the external nares.

Aside from the varying position of the choanæ the changes from amphibia to reptiles in the olfactory organs are comparatively slight.

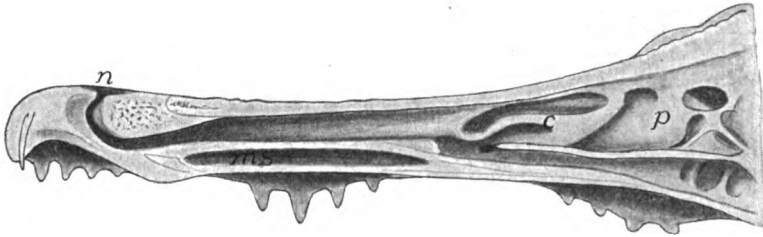


FIG. 221.—Longitudinal section of nasal region of alligator, after Gegenbaur. *c*, concha; *ms*, maxillary sinus; *n*, naris; *p*, pseudoconcha.

The olfactory region becomes more distinct from the respiratory tract and the latter shows a tendency to be differentiated into an anterior atrium or vestibule, a middle area connected with the olfactory region, and a posterior **naso-pharyngeal duct** between the basis cranii and the roof of the mouth. This latter duct varies in length accordingly

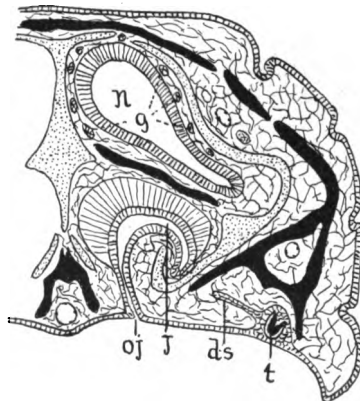


FIG. 222.—Section through nasal region of *Lacerta*, after Schimkewitsch. Bone black, cartilage dotted. *ds*, dental shelf; *j*, Jacobson's glands; *j*, Jacobson's organ; *n*, main cavity of nose; *oj*, opening of Jacobson's organ; *t*, tooth germ.

as the choanæ are anterior or posterior in position, the extreme being reached in the crocodiles, where by ingrowth of palatines and pterygoids, the internal nares are carried back nearly to the hinder end of the skull. A single concha, supported by bone, is developed in the lateral wall of the reptilian nose. It is weak in the turtles (fig. 220), but is larger elsewhere, and in the crocodiles (fig. 221) it becomes

divided in front, while a 'pseudoconch' (its homology with the superior concha of birds is uncertain) is developed above and behind the true concha. Jacobson's organ occurs only in the squamata, where it forms a simple pocket in the primitive position, ventral and medial to the nasal cavity, near the nasal septum (fig. 222).

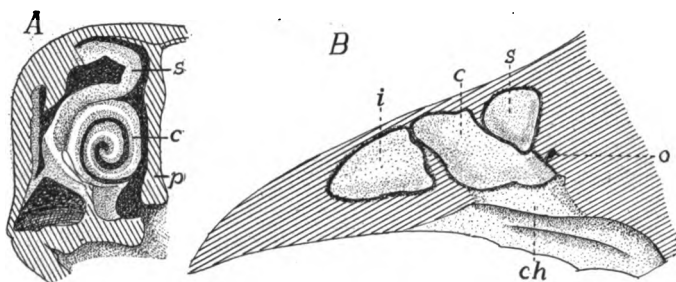


FIG. 223.—Olfactory region of hen in longitudinal and transverse section, after Gegenbaur. *c*, middle concha; *ch*, choana; *i*, inferior (anterior) concha; *o*, connexion of air cavity of head; *p*, septum of nose; *s*, superior concha.

Three folds are developed on the wall of each nasal cavity in birds, an anterior and inferior concha vestibuli, a middle and a superior fold, the middle supported by the maxillo-turbinal, the superior by the naso-turbinal bones (fig. 223). The vestibular conch lacks ol-

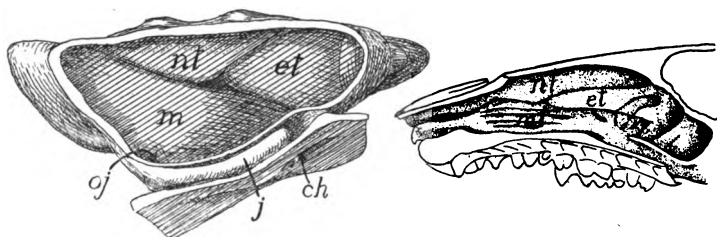


FIG. 224.

FIG. 225.

FIG. 224.—Model of the nasal cavity of a rabbit embryo, $13\frac{1}{2}$ mm. head length, after Peter. *ch*, choana; *et*, first ethmo-turbinal; *j*, organ of Jacobson; *oj*, opening of same; *mi*, maxillo-turbinal; *nl*, naso-turbinal.

FIG. 225.—Nasal cavity of *Erinaceus*, after Paulli, showing the foldings of the maxillo-turbinals (*mi*) and the naso-turbinals (*nl*); *et*, ethmo-turbinal.

factory epithelium at all times, while it disappears from the middle one after hatching, leaving the upper conch as the sole seat of smell in the adult, which corresponds with the limited olfactory sense in these animals. Jacobson's organ is never developed in the adult, through traces of it appear in the embryos.

With the great increase of the sense of smell in the mammals the nasal labyrinth undergoes a corresponding complication, and is

farther characterized by the great length of the naso-pharyngeal duct, and by the position of the olfactory area below a part of the brain cavity. The folds of the labyrinth may be supported by processes, more or less complicated, of three bones or cartilages; the **ethmo-turbinals**, the **naso-turbinals** and the **maxillo-turbinals** (fig. 224), the purpose of these folds being to increase the amount of sensory surface, while the skeletal supports keep the folds from touching each other. With diminution of the powers of smell the folds are correspondingly reduced, even to a loss of the turbination of the bones concerned.

The maxillo-turbinals and naso-turbinals arise from the lateral wall of the nasal cavity (the former as a distinct **turbinal bone**), the ethmo-turbinals as outgrowths from the ethmoid bone, appearing first at the upper hinder part of the septal wall and extending to the lateral wall. The result is that the ethmo-turbinal tends to insinuate itself between the hinder ends of the other two (figs. 224, 225). Each of these may be subdivided, with corresponding subdivision of the epithelial covering, and in the case of the ethmo-turbinals the subdivisions may be of varying heights (fig. 226), the **ecto-** and **entoturbinals**. The naso-turbinals often disappear in the adult, while the epithelium of the maxillo-turbinals is not sensory in character, this part of the nose being apparently to warm and moisten the air in its passage to the lungs.

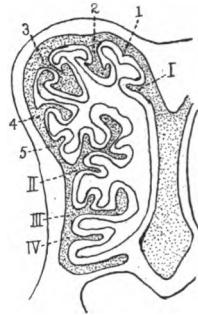


FIG. 226.—Section through the nasal cavity of a new-born dog, after Paulli, I-IV, entoturbinals; 1-5, first to fifth ectoturbinals.

The homologies of the various parts of the nasal labyrinth in different amniotes are thus stated (Peter).

- I. Concha of the anterior epithelium: concha vestibuli (birds).
- II. Conchæ of the primitive sensory epithelium:
 - 1. Arising from the lateral wall (conchæ laterales).
 - A. Anterior:
 - (a) Primary, ventral: concha of reptiles; middle concha of birds; maxillo-turbinals of mammals.
 - (b) Secondary, dorsal: Upper or posterior of birds; naso-turbinals of mammals (? pseudoconch of crocodiles).
 - B. Arising from the posterior part: conchæ obtectæ of mammals.
 - 2. Arising from the primitively median wall: ethmo-turbinals of mammals, numbered from in front backward.

Jacobson's organ (**vomero-nasal organ**) is laid down in the embryo of most mammals as a groove or pocket on the lower medial side of each nasal cavity, opening in rodents and in man near the duct of Stenson's gland; in other mammals, so far as known, its duct becomes cut off from the nasal cavity and opens into the naso-palatal canal. Its medial wall is covered with sensory epithelium, supplied by a branch of the olfactory nerve. In the primates the organ is more or less degenerate in the adult.

There are two kinds of glands in the nasal cavity, the smaller and scattered **Bowman's glands** and the larger **Stenson's gland** lying in the lateral ventral wall and opening into the vestibule. There are usually several sinuses in the bones of the skull, connected with the nasal cavities by foramina. Chief of

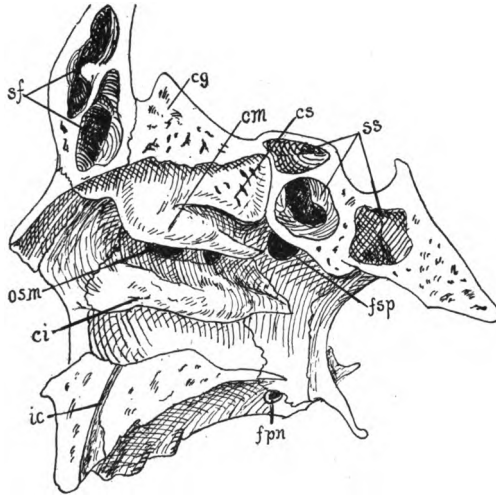


FIG. 227.—Lateral wall of nasal cavity of man, after Corning. *cg*, crista galli; *ci*, *cm*, *cs*, inferior, middle and superior conchæ; *fjn*, foramen palatinum majus; *fsp* sphenopalatine foramen; *ic*, incisive canal; *osm*, opening of maxillary sinus; *sf*, frontal sinus; *ss*, sphenoidal sinus.

these are the **maxillary sinuses** (**antra of Highmore**), the **frontal** and **sphenoidal sinuses** in the corresponding bones, the relations of which are shown in fig. 227. Others may occur in other bones of the face.

Mammals are characterized by an external fleshy nose, supported by the nasal bones and by cartilages, developed in part from the ethmoid cartilage of the embryo, in part from paired cartilages, a new acquisition of the mammals. Beyond these skeletal parts is the fleshy portion which may form a proboscis of considerable size (swine, elephant shrew, elephant).

In most mammals the sense of smell is well developed, but it is comparatively slight in the seals, whalebone whales and in the primates, while it is completely lost in most of the toothed whales where even the olfactory nerve may disappear.

THE EYES

The sensory part of the eyes comes from the ectoderm of the neural plate, and in several embryos the regions which are thus destined may be recognized on its dorsal surface before it is infolded to form the vesicles of the brain (fig. 151, *e*). The accessory parts of the eye are derived in part from the general ectoderm, in part from mesoderm of both kinds.

As the neural plate closes up to form the brain (p. 12), the optic areas begin to grow outward from the fore-brain toward the sides of the head, each forming at first a hollow outgrowth, the **optic vesicle**, connected with the brain by a hollow **optic stalk**. The next phase is the involution or invagination of the distal side of the vesicle so that it is converted into a double-walled **optic cup**

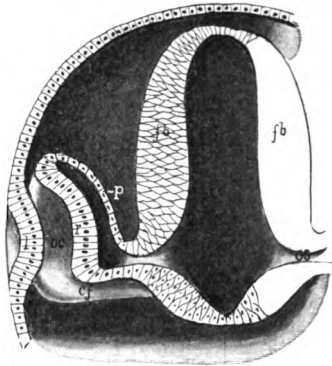


FIG. 228.—Stereogram of developing eye. *cf*, chorioid fissure; *fb*, cutwall of fore-brain; *l*, anlage of lens; *oc*, optic cup; *cs*, optic stalk; *p*, layer for pigmented epithelium; *r*, retinal layer.

(fig. 228). There thus results a differentiation of parts in the optic outgrowth and a partial obliteration of the cavity of the vesicle. The distal wall, which forms the inside of the cup is called the **retinal**

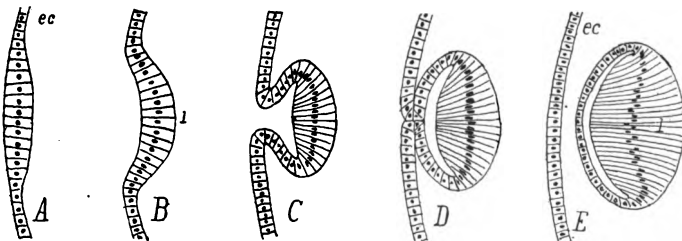


FIG. 229.—Sections of successive stages in the development of the lens of the eye from the first thickening of the ectoderm (*ec*) to the complete separation of the lens, *l*.

layer; the outer wall the **pigment layer**, in anticipation of their development into the corresponding parts of the adult.

The involution of the retina is not easily described, but may be understood from fig. 228. It occurs on the lower distal side so that

the cup is not complete but is interrupted by a deep notch, the **choroid fissure**, below, and this is extended as a groove on the ventral side of the optic stalk. Later the fissure closes (fig. 217), but not until some of the changes described below have occurred.

Opposite the distal part of each optic vesicle the ectoderm of the side of the head thickens, then becomes invaginated (fig. 229), the mouth of the invagination closes, and the hollow ball thus formed is cut off from the rest of the ectoderm and sinks into the mouth of the optic cup, where it forms the **lens** of the eye. From the first the cells of the two sides of the lens differ in size, those of the outer wall being cubical, those of the other being elongate, while the cavity is a narrow cleft. Later the cavity is obliterated, while the lens is increased in

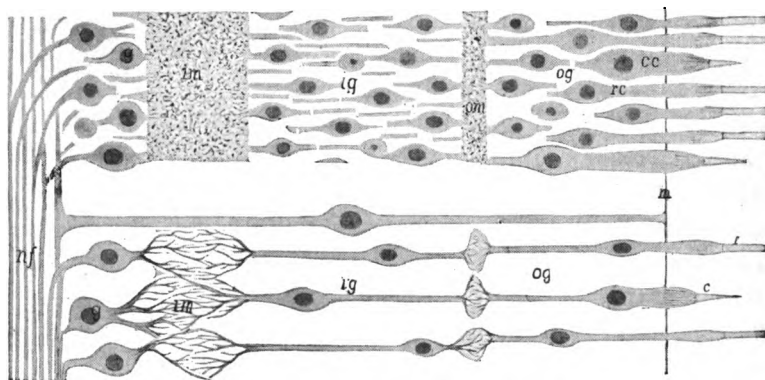


FIG. 230.—Mammalian retina; above the general appearance, below the diagrammatic relations; the lens toward the left. *c*, cone; *cc*, cone cell; *g*, ganglion cells; *ig*, inner granular layer; *im*, inner molecular layer; *m*, basal membrane; *mf*, nerve fibres; *og*, outer granular layer; *om*, outer molecular layer; *r*, rod; *rc*, rod cell.

size by the addition of new cells, like the coats of an onion, by budding from the equatorial zone of the lens.

The Retina (fig. 230) consists of several layers which constitute the ganglion and the sensory cells, the latter being on the outer surface, *i.e.*, that which is turned away from the lens. Each sensory cell bears on its outer end the percipient structure, **rod** or **cone**, which has given these the name of **rod** (fig. 198, *B*) and **cone cells**. These rods and cones project through the basal membrane, which encloses the retina, into the pigment layer shortly to be described. The bodies of the cells with their nuclei are inside the basal membrane, where they form the so-called **outer granular (nuclear) layer**, separated by an outer 'molecular' (reticular) layer of interlacing dendrites from the **inner granular layer**. This is ganglionic in character and is con-

ned by the inner molecular layer with the rest of the ganglionic layer which lines the inside of the retinal cup.

In order to understand the latter layer and the relations of the optic nerve, an account of the development is necessary. At first the retinal layer is comparatively thin, but it increases in thickness, in part by a multiplication of cells, in part by their increase in length and the development of the dendrites of the molecular layers. Each cell of the inner layer (the one turned toward the lens) also develops an axon which runs over the free surface of the cells to the chorioid fissure, passes through this and along the ventral groove of the optic stalk to the diencephalon.

As will readily be understood, it is these fibres and not the optic stalk which form the optic nerve (p. 184). When the chorioid fissure closes, the nerve appears to leave through the centre of the retina, and as this part contains no sense cells, the point of exit constitutes the 'blind spot' of physiological works. Besides the cells already mentioned the retina contains supporting or **radial cells**, like other sense organs or like the brain itself (neuroglia). These extend through from the nerve fibres to the basal membrane. Either rods or cones may be absent in isolated groups of vertebrates. Usually there is a spot, the **macula lutea** (yellow spot) or **fovea centralis** at the centre of the retina where vision is most distinct. Here the rod and cone cells are shorter and more crowded than elsewhere.

Here may be mentioned a point of morphological importance. It will be recalled (p. 144) that the ependymal surface of the brain corresponds to the external surface of the ectoderm of the rest of the body. Therefore, as a glance at fig. 228 will show, the rods and cones are on the primitively outer and the ganglion cells and nerve fibres are on the deeper surface of the ectoderm. Hence rods and cones correspond to the percipient cuticular structures of other sensory organs like the lateral line, taste buds and the like. Before it can affect the sensory cells the light has to traverse the whole of the retina and then the nervous impulses have to pass back through the same layers to reach the optic nerve. This constitutes an 'inverted eye' which, with the exception of a few molluscs, is unknown, except in the vertebrates. A comparison with the parietal eye of reptiles (fig. 162) is very instructive.

The cavity between lens and retina is filled with a semisolid **vitreous body**, the origin of which is in dispute. In mammals blood-vessels and mesenchymatous cells enter the optic cup through the chorioid fissure before its closure. Some suppose that the vitreous body arises from a modification of these cells, some regard it as an exudate from the blood-vessels, and others think it a retinal secretion.

The fact that the blood-vessels mentioned do not occur in birds is of interest in this connexion. In mammals, when the chorioid fissure closes, the vessels appear to enter through the centre of the optic nerve (**central retinal artery and vein**—fig. 231). In the early stages the retinal artery divides inside the cup, one branch (**hyaloid artery**) going through the vitreous body to the neighborhood of the lens, the other being distributed over the inner surface of the retina. Later, the hyaloid artery disappears, while retinal arteries are rare except in mammals.

The outer wall of the optic cup forms the **pigmented epithelium** of the eye, developing a large amount of black pigment which eventually surrounds and isolates the rods and cones, so that each can be

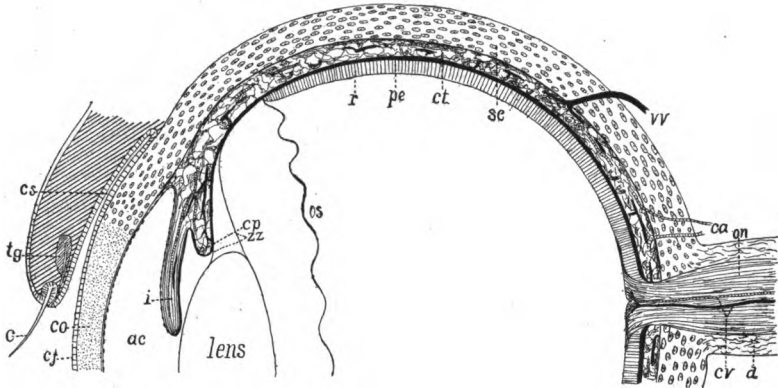


FIG. 231.—Diagrammatic section of half a mammalian eye. *ac*, anterior chamber; *ca*, ciliary arteries; *c*, eyelash (cilium); *cj*, conjunctiva; *co*, cornea; *cp*, ciliary process; *cv*, central retinal artery and vein; *cs*, conjunctival sac; *ct*, chorioid tunic; *d*, dura of optic nerve; *i*, iris; *on*, optic nerve; *os*, ora serrata; *pc*, posterior chamber; *pe*, pigmented epithelium; *r*, retina; *sc*, sclera; *tg*, tarsal gland; *v*, vortucose vein; *zz*, zonula zinii.

affected only by the light which falls directly upon it. As will readily be understood the side of the pigment layer away from the retina corresponds to the deeper surface of the skin and so comes into relation with the connective tissue. From this is developed the envelopes of the eye—**tunica vasculosa**, **sclera**, etc.

Surrounding the retina and pigmented epithelium and extending forward over the lateral parts of the lens is the **tunica vasculosa**, in which two parts are recognized, the iris and the chorioid. The whole is richly vascular, and the **chorioid**, supplied by the ciliary arteries which enter at the side, is the chief source of nourishment for the rod and cone cells. To the vascular part certain other portions are added in some groups. Thus just outside the blood-vessels

there may be a large lymph space, and outside of this, in most fishes and some amphibia and turtles, there is an **argenteal layer** containing calcic crystals which give the layer a whitish appearance. On the other hand, the side toward the retina frequently develops a somewhat similar **tapetum lucidum**, with a metallic lustre, which reflects light strongly and is the cause of the apparent shining at night of the eyes of many selachians and some other fishes and carnivore mammals. In a few teleostomes (those with a pseudobranch) there is a so-called **chorioid gland** just outside the vascular layer, near the entrance of the optic nerve. It partakes of the nature of a rete mirabile.

The chorioid extends as far forward as does the retina, when its anterior edge is produced into a circular **ciliary process**, which is best developed in the amniotes, though appearing here and there in the ichthyopsida. This process is muscular (**ciliary muscles**) at its base and is connected at its margin with the delicate capsule surrounding the lens by a double fenestrated membrane, the **zonula ciliaris** (**Zinnii**). By the action of the muscles the lens is moved toward or away from the retina, while variations in tension may slightly alter its shape, thus changing its focal point (accommodation of the eye).

Beyond the ciliary process the vascular tunic continues in front of the lens as the **iris**, a circular curtain with a central opening, the **pupil**. Pigment in the posterior layer (**uvea**) of the iris renders it opaque, while in many fishes the outer surface is silvery owing to the continuation of the argentea into this region. The rest of the iris is muscular, the muscles increasing in extent from the lower to the higher forms. They are arranged in two groups. The circular muscles (**sphincter pupillæ**), by their contraction, diminish the size of the pupil; the radial (**dilator pupillæ**) are antagonistic and effect an enlargement of the opening in the iris. In the sauropsida these iridial muscles are cross banded, in amphibia and mammals of the smooth variety.

Surrounding all of the structures of the eye so far described is the sense capsule, which differs from all other sense capsules (p. 69) in not being connected with the rest of the skull, as a result of its necessity for movement. In the capsule two parts are distinguished, the **sclera** which covers the proximal side of the eye, and the **cornea**, perfectly transparent, through which light passes to reach the lens. The cornea, covered externally by the **conjunctiva** (the modified epidermis of the front of the eye) consists of connective tissue; the sclera is usually white. In most of the lower vertebrates and in the

monotremes it is partly or wholly cartilaginous, but in other mammals, and in the lampreys it consists of fibrous tissue. In the stegcephals and in many reptiles and birds portions of the sclera ossify as a ring of **sclerotic bones** (figs. 75, 103).

Sclerotic bones are lacking in snakes, plesiosaurs and crocodiles. In the sturgeon and many teleosts two or more dermal bones develop upon the sclera, but neither these nor the calcifications to be found in some sharks and teleosts are to be confused with true sclerotics.

Between cornea and lens is a cavity which is partially divided by the iris into **anterior** and **posterior chambers** which connect with each other through the pupil. These are filled with a refracting fluid, the **aqueous humor**.

The parts so far described form the eye-ball (**bulbus oculi**) which is more or less freely movable in its socket in the side of the head. It is moved by the six muscles (p. 133) which are constantly present. Others may occur here and there. Thus in the amphibia a distinct muscle (**retractor bulbi**) is developed from the external rectus to pull the ball back into the socket, while portions of the jaw muscles may be set apart as elevators and depressors of the ball. In the elasmobranchs a cartilaginous rod, the **optic pedicle**, extends from the ball to the skull. This is replaced in the teleosts by a fibrous band, the **tenaculum**, but its equivalent is not found in the higher groups.

Among the accessory parts of the eye are the **lids**, of which there may be three, the upper and the lower lids so familiar in the higher vertebrates and the third lid, the **nictitating membrane**, a transparent sheet which may be drawn horizontally across the front of the eye from the inner (anterior) angle of the eye or from beneath the lower lid. All three lids are folds of the skin. The upper and lower are poorly developed in the ichthyopsida, but appear in the amniotes. They are lined on the side next the eye by a continuation of the conjunctiva, which continues beyond the edge of the lid as the epidermis. The nictitating membrane appears in some sharks, again in the amphibia, and receives its highest development in the sauropsida, while in the mammals it is reduced to a rudimentary fold, the **plica semilunaris**, at the inner angle of the eye.

There are no glands connected with the eyes in cyclostomes or fishes, but in the urodeles a series of glands is developed from the conjunctival lining of the lower lid. In the amphibia they show little differentiation, but in all sauropsida (glands are lacking from a few reptiles—crocodile tears are non-existent) they become divided into

two groups. One becomes aggregated near the inner angle and forms what is known as **Harder's glands** (*glandula membrana nictitans*); the other migrate toward the outer angle of the eye and constitute the true **lacrimal** or **tear gland**. In the mammals the migration continues until the gland comes to lie beneath the upper lid, where it shows its multiple nature by the numbers of ducts by which it pours its secretions into the conjunctival sac. In most mammals Harder's gland degenerates. The tears secreted by the glands pass over the conjunctiva and are collected at the inner angle of the eye, where they are drained by the **lacrimal duct** into the cavity of the nose. This duct is formed as a thickening of the epidermis which later becomes perforated. It follows the course of an earlier groove (fig. 217) leading from the orbit to the nasal invagination and which was formerly thought to form the duct.

The eyes of the cyclostomes are degenerate. In the larval (*Ammocoetes*) stage of *Petromyzon* the eye is buried under a thick skin, but this thins out in the adult. In the myxinooids the lens and eye muscles are lacking, and iris, cornea and sclera are not differentiated.

Fishes have eyes with a very flattened cornea, a spherical lens and very long retinal rods. A peculiar feature in many fishes is the **falciform process**, a vascular and muscular structure which enters the retinal cup through the chorioid fissure and extends to the lens where it bears an expansion, the **campanula Halleri**. The whole is supposed to act as a means of accommodation, there being no ciliary muscles. In most fishes the eyes are so placed on the sides of the head that there must be monocular vision. In the flat fishes (*Heterosomata*) one of the eyes migrates during development, so that both eyes come to lie on one side of the head.

Most sauropsida are characterized by the development of a process from the inner retinal surface which reaches its extreme in the **pecten** of the birds. In the reptiles it is a small conical process arising from the point of entrance of the optic nerve, but in the birds this expands distally into a quadrangular plate, folded like a fan, to which various functions have been ascribed. It has recently been shown to be rich in sense cells. The shape of the eye of the bird is peculiar, but is not easily described. It consists of a hemispherical posterior part, followed by a conical portion, and this surmounted by a hemispherical corneal region, the whole being somewhat telescopic in shape. The whole is very large in proportion to the size of the animal.

The pecten is said to be outlined in the foetal stages of some mammals. The pupil of the mammals is not always circular, but is a vertical slit in the cats, a horizontal opening in the whales, many ungulates, etc. During development the lids fuse for a time, separating in some cases, only after birth. The edges of the lids are fringed with short hairs, the eye-lashes or **cilia**, and internal to these are the ducts of sebaceous glands (**tarsal** or **Meibomian glands**), the glands themselves being in the substance of the lids. The whales have an enormously thick

sclera which, here as elsewhere, appears as a continuation of the dural sheath of the optic nerve. In the ungulates there is a retractor muscle of the ball and in most mammals the superior oblique muscle of the eye passes through a loop (trochlea) before it is attached to the ball. The eyes are greatly reduced in some mammals, especially the moles (*Talpa*), the blind mole-rat (*Spalax*), reaching the extreme in the blind marsupial, *Notoryctes* of Australia. In the moles the reduction may consist only in a fusion of the lids, while in *Notoryctes* there is no lens and no differentiation of sclera, cornea and chorioid, and the retina lacks rods and cones.

THE DIGESTIVE ORGANS

Few articles of food, as they come to a vertebrate, are in shape to be taken immediately into the organism and to be used, without modification, as a source of energy or as material for the construction of new tissue or the repair of old. They have to be altered so that they are soluble and so able to pass by osmosis into the blood-vessels (proteids, carbohydrates), or they must be broken up (hydrocarbons) so as to be taken up by the absorptive vessels (lacteals) of the lymphatic system. These changes in the food, which are the result of the action of the secretions of the digestive glands, constitute the process of digestion. The **digestive tract** or **alimentary canal**, where these changes take place, also has to provide for the passage of the digested food into the blood-vessels, to be carried by them to all parts of the body. It is, therefore, richly supplied with blood- and lymph-vessels.

The alimentary canal, which is **complete** (*i.e.*, has both mouth and vent), is largely entodermal in origin, but small portions at either end are derived from the ectoderm. The entodermal portion, the **mesenteron**, consists of the wall of the archenteron (p. 10) after the separation of the notochord, the mesothelium, and a few less prominent structures. The ectodermal parts are a **stomodeum** at the cephalic end and a **proctodeum** behind.

In the early stages of all vertebrates the mouth is lacking, the cephalic end of the archenteron abutting directly against the ectoderm of the ventral side of the head, so that an **oral (pharyngeal) plate** is formed, consisting of both ectoderm and entoderm. Next this plate is pushed inward, either as a pocket (fig. 212) or as a solid plug, carrying the entoderm before it. This ingrowth constitutes the **stomodeum**, and the site of its ingrowth forms the mouth opening of the adult. Later the oral plate breaks through, placing the stomodeum and mesenteron in communication.

In the majority of vertebrates the blastopore closes behind, so that the anus is a new formation, although it arises in the line of closure. In the amniotes this opening is preceded by the formation of a pocket, the **proctodeum**, similar to the stomodeum, and opening later into the mesenteron in the same way. In the adult it is impossible to find any lines separating the three regions, stomodeum, mesenteron and protodeum.

The protodeum lies wholly behind the entrance of the urogenital ducts into the cloaca. The ectoderm of the stomoderm extends inward as far as the posterior teeth, following the outline of the jaws. On the dorsal side of the oral cavity two pits persist for some time, the limits of ectoderm and entoderm passing between them. The posterior of these, **Seessel's pocket**, is of unknown significance. The other, **Rathke's pocket** (fig. 282), lies just in front of the oral plate. It marks the point of invagination of the hypophysis (p. 157) and remains open for a time as the hypophysial duct (fig. 159).

In some teleosts, where the stomodeal ingrowth is slight, the mouth appears at first as a pair of perforations in the oral plate, these later coalescing to form the permanent mouth. This condition lends plausibility to the view that the vertebrate mouth has arisen from the coalescence of a pair of gill clefts.

Except in the higher mammals the entodermal part of the alimentary canal contains a large amount of food yolk in the early stages. In the sauropsida this is so abundant that the whole cannot be contained in the body walls, and hence it causes the ventral side of the canal to protrude as a **yolk-sac** (fig. 329), which is gradually absorbed with the digestion and removal of the yolk by the blood-vessels.

The first differentiation in the mesenteron is the development of a ventral diverticulum, the anlage of the liver, which arises just caudal

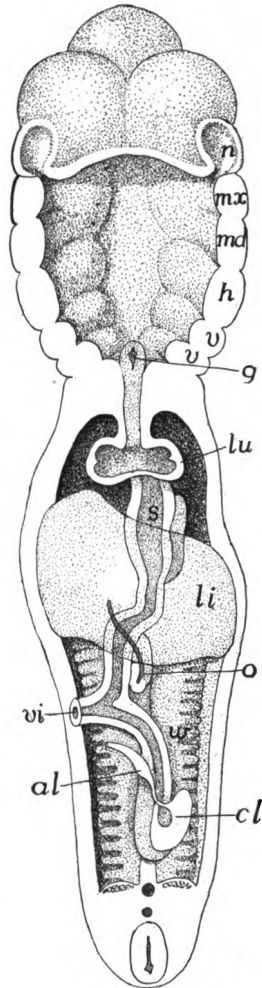


FIG. 232.—Reconstruction of alimentary canal of human embryo, after His. *al*, allantois stalk; *cl*, cloaca; *g*, glottis; *h*, hyoid arch; *li*, liver; *lu*, lung; *md*, *mx*, mandibular and maxillary arches; *n*, nasal pit; *o*, omphalomesenteric vein; *s*, stomach; *v*, visceral arches; *vi*, vitelline stalk; *w*, Wolffian body.

to the head. This divides the alimentary canal into **pre- and post-hepatic** portions (fig. 233). From the anterior of these is formed part of the cavity of the mouth with the salivary glands, the pharynx, œsophagus, stomach, and duodenum; the posthepatic portion gives rise to large and small intestines, rectum and cloaca, as well as to the urinary bladder. Of these parts the pharynx will be considered in connexion with the respiratory organs, the bladder with the urogenital system. Mouth and pharynx belong primitively to the head, but by unequal growth the pharynx may be carried apparently to some distance behind the brain and other characteristically cephalic structures.

In the following account stress is laid upon the epithelial lining (entoderm), the characteristic tissue of the digestive tract, but it must

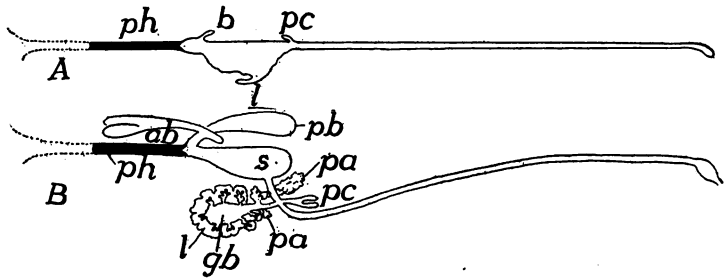


FIG. 233.—Diagrams of the alimentary canal in embryos of 6 and 8 days of *Gymnarchus niloticus*, after Assheton. *ab*, air bladder; *b*, early diverticulum for air bladder; *gb*, gall bladder; *l*, liver; *pa*, pancreas; *pb*, posterior part of air bladder; *pc*, pyloric cæca; *ph*, pharynx; *s*, stomach.

not be forgotten that the wall contains other tissues of mesenchymatous origin. That part of the canal which runs through the body cavity has the following layers. The lining epithelium is supported by a layer of connective tissue, containing the capillary absorptive vessels; outside of this are two layers of smooth (involuntary) muscles, the inner with the fibres running in a circular, the other in a longitudinal direction. By the action of these antagonistic muscles the **peristalsis** or movement of the digestive tract is effected, by which the food undergoing digestion is churned and thoroughly mixed with the digestive fluids, and all parts of it are brought into contact with the absorptive surfaces. The outer surface of stomach, intestine and associated glands is covered with the **serous coat**, the lining of the peritoneal cavity, but this is lacking from those parts (pharynx, œsophagus, etc.) which are outside the region of the coelom.

THE ORAL CAVITY

The cavity of the mouth is limited anteriorly by the line of the stomodeal involution and extends back to the pharynx. It is lined in part by ectoderm, in part by entoderm, the line between the two, as stated above, not being recognizable in the adult. In the amphibia the lining is ciliated, the cilia extending back to the stomach. In the cyclostomes the oral cavity is funnel-shaped, with a circular or quadrangular opening supported by a cartilaginous ring and has the name of **oral hood**. It is permanently open, there being no jaws capable of closure (see skeleton, p. 84), thus furnishing a marked contrast to all other vertebrates in which there are jaws and which are consequently known as gnathostomes. (Development gives little support to the view that the cyclostome tongue is the homologue of the lower jaw of the gnathostomes).

In development the vertebrate mouth arises on the ventral side of the head, some distance from the anterior end of the body. This position is retained throughout life in most elasmobranchs and in the sturgeons; but elsewhere, by the development of the bony upper jaw in front of the pterygoquadrate (p. 77) and the concomitant extension of Meckel's cartilage, the mouth opening is gradually transferred to the anterior end and becomes terminal.

In most lower gnathostomes (the holocephali and other isolated forms are exceptions) the mouth opening is bounded by folds of epithelium which meet when the mouth is closed. Usually these folds are soft and are supported below by connective tissue, but in birds, turtles and monotremes they are cornified. It is only in the mammals that true lips occur. These are fleshy folds around the mouth and their development in this group is correlated with the presence of the dermal facial muscles (p. 140), by which they are moved. With the development of lips there is formed a space between lips and teeth, the **vestibule** of the mouth, which sometimes (*e.g.*, some rodents) forms cheek pouches, lined with hair, of considerable size.

TEETH

The primitive function of the teeth was apparently to hold the prey taken into the mouth and this is their sole use in many forms. In other species they have become efficient organs for the comminution of food, either by cutting or by crushing it.

There are two types of teeth, much alike in function, but differing

markedly in structure and development and without genetic relationships. The typical vertebrate teeth are comparable to placoid scales; they arise as a calcareous secretion at the junction of ectoderm and mesenchyme and are a product of both layers. The other type contains purely cuticular teeth, formed by a cornification of the epithelium and have their analogues in many invertebrates.

True Teeth.—The ability to form scales is characteristic of the skin of many vertebrates. The primitive type of these scales is the placoid (p. 44), consisting of a basal portion of dentine capped with enamel and the apex projecting through the integument as a spine. When invaginated to form the stomodeum, the skin retains this capacity of forming hard structures and hence any portion of the stomodeal walls may secrete scale-like plates. In fact, in the teeth of some elasmobranchs (*Raja*, *Mustelus*, *Trygon*, etc.) the placoid scale can be recognized with scarcely a modification. In the ichthyopsida teeth may form anywhere in the oral cavity where there are skeletal parts—cartilage or bone—to support them. Thus they may occur, not only on the margins of the jaws, but on vomers, palatines and parasphenoid, and in some teleosts on the tongue, where they are attached to the hyoid. In the amniotes (some squamata excepted) teeth occur only on the margins of the jaws. Teeth are lacking here and there, in various families of vertebrates as well as from all turtles and living birds, but some extinct birds had teeth. In the embryos of both chelonians and aves the dental ridge is formed (*vide infra*), but it soon completely disappears, an indication of their descent from toothed ancestors.

In the development of a tooth, as of a placoid scale, there is first a thickening of the ectoderm, the basal layer of which pushes into the corium and at the same time the mesenchyme cells of the latter layer multiply beneath the centre of the ectodermal ingrowth, pushing it outward, so that the basal layer forms a cup with the opening toward the deeper tissues (fig. 234). The mesenchyme within the cup forms the **dental papilla**, while the ectoderm cells lining the cup form the **enamel organ**. With farther development the outer cells of the papilla are converted into **odontoblasts**, so-called from their function of forming a bone-like substance, the **dentine** or **ivory** of the tooth. This, in accordance with the method of its formation by secretion from the ends of the odontoblasts, has a prismatic structure (fig. 237). The basal surface of the enamel organ secretes a denser substance, the **enamel**, which lies like a cap, firmly united to the top and

sides of the dentine. By continued additions to the deeper portions of the dentine the tooth is gradually forced up through the epithelium so that its tip or **crown** comes into position for use (eruption of the tooth).

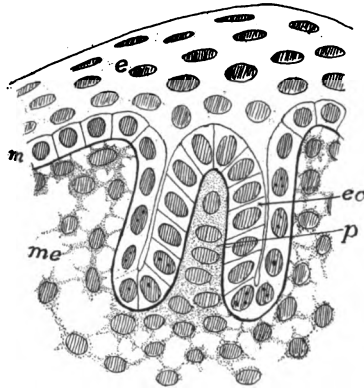


FIG. 234.—Section of developing tooth germ of *Amblystoma*. *e*, epidermis; *eo*, enamel organ; *m*, Malpighian layer; *me*, mesenchyme; *p*, pulp of tooth.

In the lower vertebrates there may be a separate invagination of the ectoderm for each tooth, but in the mammals there is a continuous ingrowth, the **dental ridge** (fig. 235) along the margin of the jaw. Later this becomes differentiated into separate enamel organs and dental papillæ, the separate teeth developing much as in other groups. From the posterior side of this dental ridge there

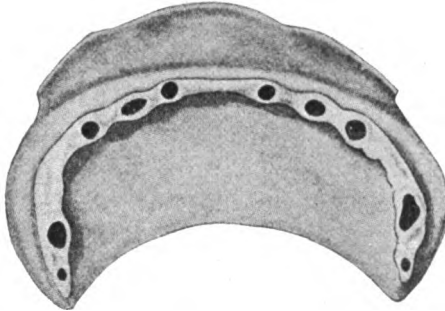


FIG. 235.—Model of ectodermal parts of jaw of human embryo 40 mm. long, after Röse, showing the dental ridge with the germs of the teeth.

arises a continuous projection, the **dental shelf** (fig. 236) which later gives rise to the enamel organs for the second or permanent dentition (*infra*).

The dental papilla persists throughout life as the pulp of the tooth, continuing to occupy the space (**pulp cavity**) in which it first appeared. Nerves (branches of the trigeminal) and blood-vessels enter the cavity through the base of the tooth. Usually, when the tooth is

fully formed, the odontoblasts cease to act, but exceptionally, even in mammals (tusks of elephants, incisors of rodents) they function through life and the tooth continues to grow. In the mammals an additional layer of modified bone, the **cement**, is formed around the root of the tooth and may extend on to the crown.

Just as the scales are arranged in quincunx on the surface of the body, so are the teeth in the mouths of skates and some other elasmobranchs, where they form a tessellated pavement above and below, the teeth being flattened and used for crushing the molluscs in which these animals feed. More commonly the teeth are flattened in the anteroposterior direction and have sharp cutting edges. In such



The text in this section is extremely faint and largely illegible due to heavy scanning artifacts and noise. It appears to contain several lines of descriptive text, possibly detailing the structure and function of the teeth shown in the diagrams above.

marsupial *Myrmecobius*, where the permanent dentition is greatly reduced, and in some of the insectivores and rodents, a prelacteal dentition has been observed in the embryo, while Röse has described traces of a prelacteal and a post-per-

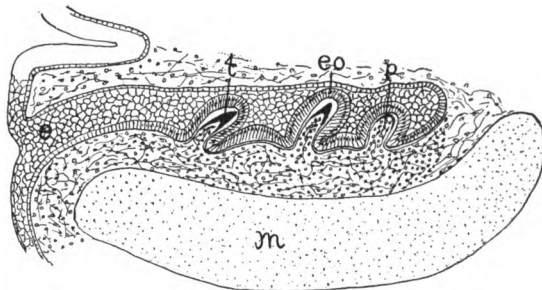


FIG. 238.—Developing teeth of *Acanthias*. *e*, ingrowth of ectoderm of lower jaw; *eo*, enamel organ; *m*, Meckel's cartilage; *p*, pulp of *t*, tooth.

manent dentition in man. In a number of mammals (guinea pigs, many bats, etc.) the milk dentition is lost before birth.

Only a few fishes (adult *Acipenser*, *Coregonus*, etc.) lack teeth, while in most they extend to the lining bones of the mouth and in

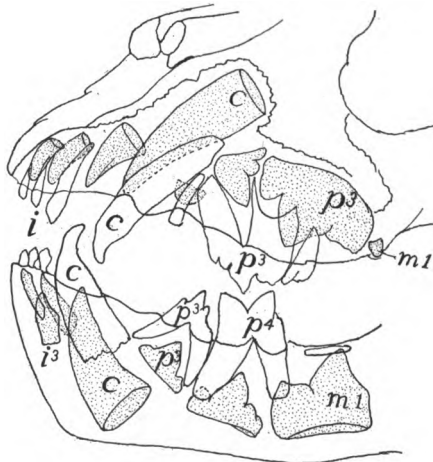

FIG. 239.—Jaws of a six month lion, after Weber. Milk teeth white, permanent dotted. *i*, incisors; *c*, canines; *m*, molars; *p*, premolars.

some to the hyoid and branchial arches (pharyngeal bones). Usually they are conical, but they may be flattened and pavement-like or even form large plates, apparently by the coalescence of numbers of primitive teeth (dipnoi). In the amphibians the teeth are not so widely distributed in the mouth, occurring on the margins of the jaws

and on the palatines and vomers, rarely on the parasphenoid, while they are entirely lacking in *Bufo* and *Pipa*.

Among the reptiles the turtles and some of the pterodactyls are toothless; most of the others have the teeth confined to the margin of the jaws, though they occur on the palatines and pterygoids in the snakes and lizards, and rarely (*Sphenodon*) on the vomer. While the conical shape prevails, the teeth present a great variety of forms, some of the theriomorphs closely simulating the mammals in their heterodont dentition. The teeth may be anchylosed to the summit of the jaws (**acrodont**); applied to their inner side (**pleurodont**, fig. 106, *d*); or have their roots implanted in grooves or sockets or **alveoli** (**thecodont**). Mention must also be made of the poison fangs of certain serpents. These are specialized teeth borne on the maxillary bones and are either permanently erect (**proteroglypha**) or the bone may turn, as on a pivot, so that when the mouth is closed the teeth lie

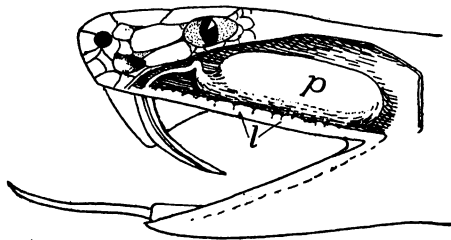


FIG. 240.—Poison gland and fang of rattlesnake, *Crotalus horridus* (Princeton, 1904).
p, poison gland; *l*, labial glands.

along the roof of the mouth, but when it is opened, they are brought into position for striking the prey (vipers, rattlesnakes—**solenoglypha**). Correlated with the fixed or movable condition is a modification in the teeth themselves. In the **proteroglypha** a groove runs along the anterior side of the fang by which the poison is conducted from the poison gland into the wound. In the **solenoglypha** the groove is rolled into a tube with openings near the base and apex of the tooth (fig. 240). In these **solenoglyphous** snakes only a pair of fangs are functional at a time, but there are reserve teeth which can come into use on the loss of the first.

The great variation is found in the teeth of mammals, the heterodont dentition being the rule. Four kinds of teeth are recognized. These are the **incisors** in the premaxillary bones, followed by a single **canine** at the anterior end of each maxillary bone. This resembles the incisors and differs from the other maxillary teeth in

its conical shape and single root. Behind the canines come the **premolars** (the **bicuspid**s of the dentists) which have two roots and complicated crowns and appear in both milk and permanent dentitions. Lastly are the **molars**, like the premolars in form, with several roots, but appearing only in the permanent dentition. The corresponding teeth in the lower jaw have the same names.

In a few mammals, like the whales, all of the teeth are of a simple conical shape, but in the majority the crown of the molars is marked by projections—cones, tubercles, crests, etc.—which are variously arranged. When the teeth are adapted for cutting they are called **secodont** (cats, fig. 239); for crushing, **bunodont** (man); when marked by transverse ridges, **lophodont** (elephants); when there are longitudinal crests, more or less crescentic in outline, they are **selenodont** (horse, fig. 241, *E*).

In the **triconodont** tooth there are three prominences in the crown arranged in a straight line, parallel to the axis of the jaw. The middle and more prominent of these in the upper jaw is the **protocone**, with a smaller **paracone** in front and

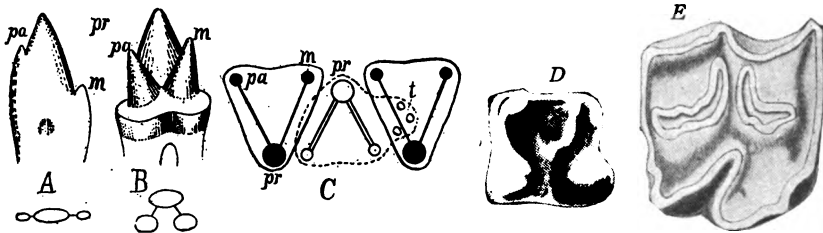


FIG. 241.—*A*, triconodont tooth of *Dromatherium*; *B*, tritubercular tooth of *Spalotherium*; *C*, interlocking of upper (dark) and lower (light) tritubercular molar teeth (after Osborn); *D*, molar of *Erinaceus*; *E*, of horse (selenodont type); *c*, cingulum; *m*, metacone (metaconid); *pa*, paracone (paraconid); *pr*, protocone (protoconid); *t*, talon.

a **metacone** behind. In the lower jaw the corresponding terms are **proto-**, **para-**, and **metaconid**. In a **tritubercular** tooth the three cones are arranged in a triangle, in such a way that they alternate in the two jaws, the protocone being on the inner side, the protoconid on the outer. Tritubercular teeth may have a lower projection (**talon**) on the hinder side. When this develops into a prominent tubercle (**hypocone**, **hypoconid**) the tooth becomes **quadritubercular**. Then crests or **lophs** may develop, connecting the cones, so that the crown becomes **ridged** rather than tubercular.

In the **homodont** dentition the number of teeth may be very large, varying from 100 to 200. With the **heterodont** dentition the number is smaller, the full dentition in the placental mammals including 44 teeth. From this number reductions may occur by the loss of teeth of any kind. The number of teeth and of those of each kind is important in systematic work, and a **dental formula** has been devised to express this. As the number of teeth in the two sides of each jaw is the same, only one side is represented in the formula, while the teeth of the upper and lower jaws are represented as fractions. The number of incisors, canines, premolars and molars of man are represented by

$i_{\frac{2}{2}}^2, c_{\frac{1}{1}}^1, pm_{\frac{2}{2}}^2, m_{\frac{3}{3}}^3$; that of the opossum by $i_{\frac{5}{4}}^5, c_{\frac{1}{1}}^1, pm_{\frac{3}{3}}^3, m_{\frac{4}{4}}^4$.

Not infrequently the enamel is lacking from the teeth of mammals, as in whales, dugongs and edentates, or it may be restricted to one side of a tooth, as in

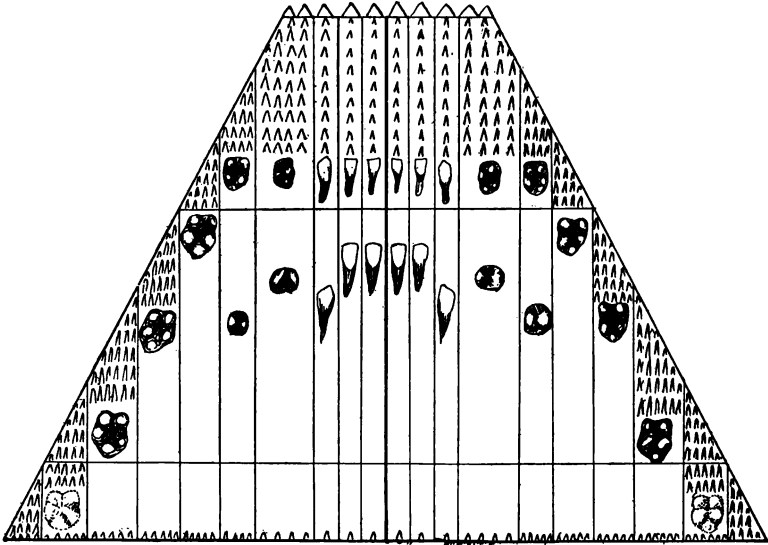


FIG. 242.—Diagram of the relation of the human teeth to the primitive dentition, after Röse.

the incisors of rodents. Sexual differentiations occasionally occur in mammals, certain teeth (usually canines or incisors, more rarely premolars) being better developed in the males than in the females of the same species.

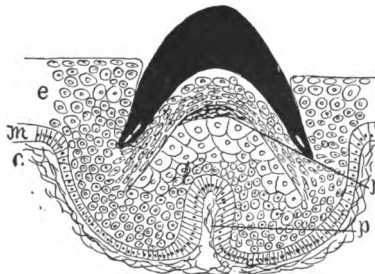

FIG. 243.—Epidermal tooth (black) of lamprey, after Warren. *c*, corium; *e*, epidermis; *m*, Malpighian layer; *p*, papilla of corium in epidermis; *r*, replacement tooth developing.

There are two views as to the way in which the complicated molars of the mammals have arisen. Both start with the conical tooth as the primitive condition. One theory is that the fusion of such simple teeth is sufficient to account for the multiplication of roots and tubercles in all of their varying forms (figs.

242, 244). The other hypothesis is that parts have been developed in the primitive cone, giving, first, the triconodont shape. Next these three cones have been shifted to the tritubercular position (fig. 241, A,B,C); and later other parts—hypocone, lophs, etc.—have been added and these have been modified in different directions. Each view has much in its favor. Embryology is not at all decisive, while paleontology favors the latter view. In *Dugong* there is a fusion of enamel organs for the molar teeth.

Epidermal Teeth occur in cyclostomes and in larval amphibia and in embryonic monotremes. In the cyclostomes they are cones of cornified epithelium covering an underlying core of the integument; they are differently arranged in the lampreys and myxinoids. In the latter they are few, there being a single tooth on the 'palate' and two chevron-shaped rows on the tongue. In the lampreys nearly the whole inner surface of the oral hood is lined with these teeth of varying shape, and there are a varying number upon the tongue. These teeth are used as a means of fastening the animals to their



FIG. 244.

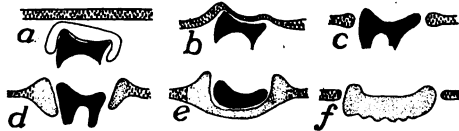


FIG. 245.

FIG. 244.—Teeth of *Chamydoselache* (after Röse), showing a triconodont tooth arising from the fusion of three simple teeth.

FIG. 245.—Diagram of development of teeth in *Ornithorhynchus*, after Thomas and Poulton. *a*, tooth covered with enamel organ, beneath oral epithelium; *b*, just before eruption; *c*, tooth erupted; *d*, edges of epithelium cornified; *e*, horny plate formed, contains the tooth; *f*, tooth lost, plate separated from its surroundings.

prey, and those of the myxinoid tongue are used for boring into the fishes on which these animals feed.

In the larval anura (the larval *Siren* is said to resemble them) the edges of the jaws are armed with cornified papillæ, serving as teeth, the arrangement of which varies in different genera. They are frequently aggregated in dental plates, used in scraping the algæ from submerged objects. They are not related to the teeth of cyclostomes.

In the embryo monotreme teeth are formed as in other mammals, of a multituberculate type, with a normal enamel organ (fig. 245), but these are lost before birth. During their eruption the adjacent epidermis becomes cornified, gradually extends beneath each tooth and after the loss of the true tooth this forms a horny plate, used, like those of many birds, in holding and crushing the food.

In this connexion mention may be made of the **baleen** or 'whale-bone' of the balenid whales. This takes the form of large plates of horny material, attached in series to the margins of the upper jaw, so that with their fringed ends and edges they serve as strainers to extract the plankton (minute floating life) from the sea. This baleen is formed by the agglutination of enormously developed cornified papillæ.

Egg Teeth.—In the embryos of certain lizards and snakes one of the median teeth of the first dentition of the premaxillary region projects from the mouth and is used for the rupture of the egg shell, thus allowing the escape of the young. In the turtles, *Sphenodon*, crocodiles, birds, and monotremes an egg tooth is formed on the upper surface of the beak which is used for the same purpose. However, it differs greatly as it is but a thickening, often calcified, of the epidermis (fig. 218).

THE TONGUE

The tongue as it occurs in its more primitive condition in the fishes is merely a fleshy fold developed from the floor of the mouth between the hyoid and mandibular arches, the hyoid frequently extending into and supporting it. It is incapable of motion, except as moved by the supporting skeleton, for it lacks intrinsic muscles. It is sensory, having both tactile and gustatory functions. It is often papillose, and in a few teleosts it bears teeth.

The tongue in the cyclostomes is considerably different. Here it is thick and fleshy and is supported by a cartilaginous skeleton (p. 84) and is moved by appropriate protractor and retractor muscles at the base, developed from the postotic myotomes and innervated by the hypoglossal nerve. With its terminal armament of epidermal teeth it serves as the boring organ with which the myxinoids obtain entrance into their prey, while in the lampreys it serves as a rasping organ and also as part of the sucking apparatus.

In the amphibia there is a greater range of structure. In a few anura (aglossa) the tongue is practically absent; in the perenni-branches it is scarcely more advanced than in the fishes, but elsewhere it contains intrinsic muscles (innervated by the hypoglossal nerve) and is extremely mobile. It consists of a small basal portion corresponded ing to the tongue of the fish, to which is added a large glandular part arising between the copula and the lower jaw. This secretes the slime, so useful in capturing the prey. In the anura the tongue is attached at the margin of the jaw, its free end, when at rest, being folded back on the floor of the mouth. In urodeles the base

of attachment is more extensive and embraces the anterior margin of the tongue and part of the ventral surface as well. The supporting skeleton (fig. 94) consists of the median portion (copula) with usually two pairs of cornua, largely formed from the ventral ends of the hyoid and first branchial arches (see p. 72).

The reptilian tongue includes not only the parts found in the amphibia (the fold above the basihyal), but also a median growth, the **tuberculum impar** (fig. 247), arising between the basihyal and the lower jaw, and also a pair of lateral folds lying above the first visceral (mandibular) arch (*Lacerta*). With the development of these parts, the trigeminal nerve also supplies the tongue, in addition to the hypoglossal and glossopharyngeal of the lower groups. In the turtles and crocodiles the tongue lies on the floor of the mouth and is not protrusible. In the squamata it can be extended from the mouth, and in snakes and many lizards there is a sheath into which it is withdrawn. In many snakes the tongue is two-pointed at the tip; in the lizards its shape varies greatly, the differences being used in classifying these animals. In the reptiles (fig. 246) with retractile tongue the hyoid apparatus extends into the tongue, its unpaired anterior portion being called the **os entoglossum** (copula or basihyal), while the two cornua (usually hyoid and first branchial) afford attachment for the retractor muscles. In addition to the usual lingual nerve (glossopharyngeal) the tongue also receives a lingual twig from the mandibular branch of the fifth nerve.

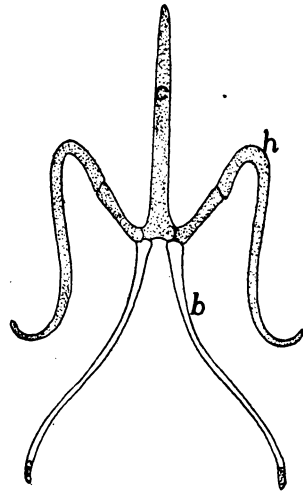


FIG. 246.—Hyoid apparatus of *Heloderma*, after Cope. *b*, first branchial; *c*, copula; *h*, hyoid.

In birds the tongue has lost the lateral parts of the reptilian tongue and with this the trigeminal branch. It contains no intrinsic muscles. In its form it varies greatly, but usually it is slender and is covered with retrorse horny papillæ. Its skeleton is also reduced (fig. 111) and consists of an os entoglossum, bearing in front a pair of elements (**paraglossæ**) and on the sides a pair of cornua (first branchials) and in the median line behind, a **urohyal** portion. This skeleton has a marked development in the woodpeckers, where the cornua curve around the base of the skull and over its dorsal side to

the neighborhood of the nostril, a condition correlated with the use of the tongue in these animals.

Among the mammals, the whales excepted, the tongue is very mobile, reaching the extreme in this respect in the ant-eaters. This mobility is largely due to the intrinsic muscles, derivatives in large part, from the hypobranchial musculature. The tongue is developed from the **unpaired tubercle** (*tuberculum impar*), from two thickenings on the mandibular arch (fig. 286) and its hinder portion from fleshy ridges above the hyoid arch (fig. 247). The line between anterior and posterior parts is largely obliterated in the adult, but it is close to the circumvallate papillæ (p. 204) and the **foramen cæcum**, a pit connected with the development of the thyroid gland (p. 265).

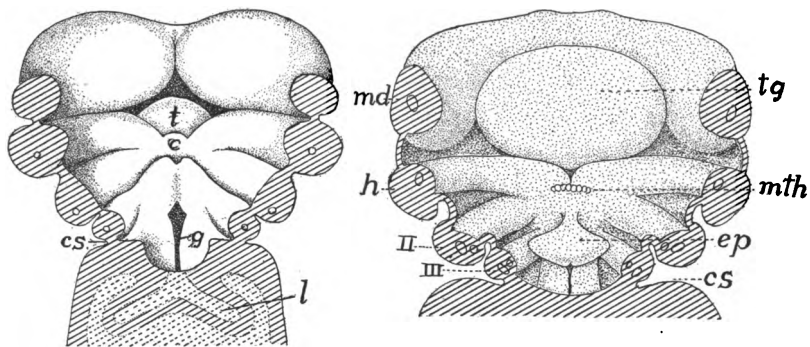


FIG. 247.—Two stages in developing tongue and pharyngeal floor of man, after His, *c*, copula (basihyal element); *cs*, cervical sinus; *ep*, epiglottis; *g*, glottis; *h*, hyoid arch; *md*, mandibular arch; *mth*, median anlage of thyreoid; *t*, tuberculum impar; *tg*, tongue.

Thus the mammalian tongue is similar to that of reptiles and exceeds that of birds in having mandibular components.

There are two views as to the relations of the mammalian and amphibian tongue. In the one the amphibian tongue is unrepresented in the mammals, unless it be by the **sublingua**, a fleshy fold beneath the tongue of marsupials and lemurs (fig. 248), traces of which occur in other mammals, even in man, as folds (*plicæ fimbriatæ*) beneath the tongue. In some cases (*Stenops*) the sublingua is supported by cartilage, which may be the entoglossum (p. 106). Others think that the amphibian tongue is represented in the anterior part of that of the amniotes, and these regard the **lyssa** (a vermiform mass of cartilage, muscle and connective tissue (fig. 249) lying ventral to the median septum of the tongue) as the equivalent of the entoglossum and its associated structures.

The tongue varies considerably in shape in the different mammalian orders, but the differences are of little morphological importance. The dorsal surface is usually covered with a soft epithelium

with numerous mucous glands, and is developed into papillæ of varying shapes, some sensory, and in some cases they become cornified and efficient organs of rasping (monotremes, cats).

The skeleton of the mammalian tongue (hyoid apparatus) varies considerably. In its most complete development it consists of a body (copula of the hyoid and first branchial) in the median line, which bears two pairs of cornua. The anterior pair (lesser horns of human anatomy) are usually elongate, and consist of a series of ossicles (p. 80) connecting the body with the otic region of the skull. The second pair (greater cornua of man) are occasionally absent. In man

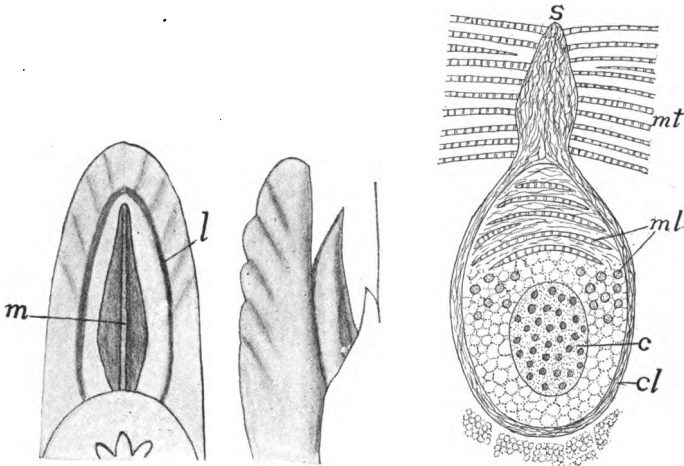


FIG. 248.—Ventral and side views of tongue of *Stenops gracilis*, after Weber. *l*, lateral margin of sublingua; *m*, plica mediana.

FIG. 249.—Section through lyssa of late dog embryo, after Nussbaum. *c*, cartilage of lyssa, *cl*, capsule of lyssa; *mt*, muscles of tongue; *ml*, longitudinal and transverse muscles of lyssa; *s*, septum of tongue.

the greater part of the anterior cornua is represented by the stylohyoid ligament, the proximal portion being fused to the skull as the styloid process.

ORAL GLANDS

In the cyclostomes there is a large, so-called, 'salivary gland' of unknown function, opening into the mouth on either side below the tongue. With this exception, glands are lacking from the mouths of aquatic ichthyopsida. With the assumption of pulmonate respiration and more terrestrial habits, the mouth is no longer constantly bathed with water and glands appear, increasing in number and com-

plexity in the higher forms. The secretion of these glands aids in moistening the food, and not infrequently it is adhesive and is used in capturing the prey. In the mammals true salivary glands appear. The saliva secreted by them contains not only mucus, but also a digestive ferment (**ptyalin**) which changes starch into sugar. The names of the various oral glands (labial, buccal, lingual, retrolingual, etc.) are roughly indicative of their position.

In the terrestrial amphibia, snakes (fig. 240) and lizards, there are **labial glands**, opening at the bases of the teeth, and an **intermaxillary** or **internasal gland** in the septum between the nasal cavities, as well as **palatal glands** near the choanæ (the internasal gland is lacking in the cæcilians). Many reptiles also have a **sublingual gland** on either side (fig. 250). In many snakes a pair of the labial glands are greatly de-

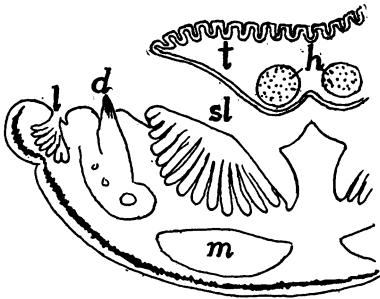


FIG. 250.—Transverse section of tongue and lower jaw of *Lacerta*, after Gegenbaur. *d*, tooth; *h*, hyoid cartilage; *l*, labial glands; *m*, muscles; *sl*, sublingual gland; *t*, tongue.

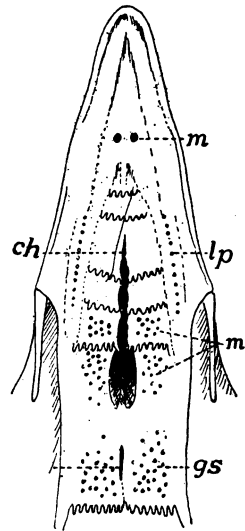


FIG. 251.—Palatal surface of anterior end of choana; *gs*, openings of sphenopterygoid glands; *lp*, *m*, openings of lateral and medial palatine glands; *m*, opening of gl. maxillaris monostomatica.

veloped and have migrated into the zygomatic ligament, where they have become modified into the well-known poison glands (fig. 240), the ducts of which connect with the poison fangs (p. 228). In the only known poisonous lizard (*Heloderma*) the sublingual glands furnish the poison. Oral glands are poorly developed in the sea turtles and the crocodilians.

Birds lack the labial and internasal glands, but they have numerous other glands opening separately into the roof of the mouth (fig. 251) as well as anterior and posterior sublinguals and frequently an

'angle gland' at the angle of the mouth, which may be the last remnant of the labial glands of the other sauropsida.

Besides numerous smaller glands (labials, buccals, linguals, palatines) imbedded in the mucous membrane and opening separately into the mammalian mouth, the **salivary glands**, though absent from the cetacea, form a distinguishing feature of the group. These salivary glands are usually in the neighborhood of the mouth, but one or more of them may be carried back into the neck (fig. 252), but in all cases the homologies are decided by the openings of the ducts. The salivary glands include the submaxillary and sublingual of the lower groups, and in addition the **parotid gland**, apparently a develop-

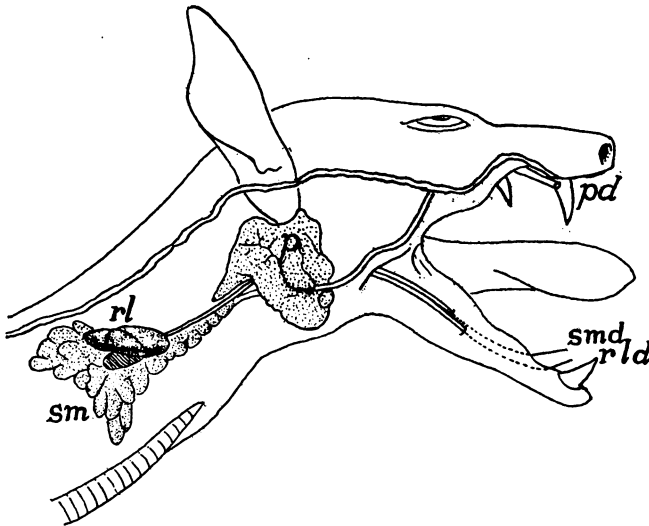


FIG. 252.—Salivary glands of fruit bat, *Pteropus conspicillatus* (Princeton, 2065). *p, pd*, parotid gland and duct; *rl, rld*, retrolingual gland and duct; *sm, smd*, submaxillary gland and duct.

ment within the class. The **submaxillary** normally lies in the lower jaw beneath the mylohyoid muscle, and its duct (**Wharton's duct**) opens near the lower incisor teeth. Near this is frequently a **retro-lingual gland**, its duct opening near the former. The sublingual gland occurs between the tongue and the alveolar margin of the lower jaw and usually empties by numerous duct. The parotid gland has its normal position near the ear, and its duct (**Stenon's duct**) pours the secretion out near the molars of the upper jaw. Other oral glands are occasionally present, like the **molar glands** of ungulates and the **orbital glands** of dogs, both of which have ducts leading into the mouth.

PHARYNX

The pharynx is the division of the alimentary canal intervening between the cavity of the mouth and the œsophagus and is characterized by being at once alimentary and respiratory. From its walls are developed the gill clefts and lungs as well as a number of derivatives of these, and it also receives the internal openings of the nasal passages. Hence it is best described in connexion with the respiratory system.

THE ŒSOPHAGUS

That part of the digestive tract between the pharynx and the entrance of the bile duct (fig. 233) develops into œsophagus, stomach and that part of the intestine known as the duodenum. Stomach and duodenum are separated by the pyloric valve described below, but it is difficult to draw a clear line between œsophagus and stomach. In general it may be said that the œsophagus is the tract immediately succeeding the pharynx, lying in front of the body cavity and thus lacking a serous coat; that it is smaller than the stomach, and that there are no digestive glands in its walls; but all of these statements have exceptions.

The œsophagus varies in length with the length of the neck of the animal, being short in the ichthyopsida, longer in the reptiles, and reaching its extreme in the birds. In some its internal lining epithelium is smooth, but more commonly it bears longitudinal folds, while in the chelonians it is provided with cornified papillæ pointing backward. Outside of the epithelium its walls contain muscles, those at the cephalic end being striped and these may extend back, in some instances, even on to the stomach. They are apparently derivatives of the pharyngeal region. Usually the œsophagus is of the same diameter throughout, but frequently in birds it has a marked dilatation, the *ingluvies* or *crop*. This may be an expansion of one side of the tube, or, as in pigeons, it may consist of a median and a pair of lateral chambers. The extreme of development of the crop occurs in *Opisthocomus*, where the organ is extremely muscular and has numerous longitudinal folds.

The crop, which is usually supported by the furcula, may be either a reservoir for food, or it may be a glandular organ, its secretions serving to moisten the food or even to initiate its digestion. In the pigeons at the breeding season the secretion is a milky fluid and is used in feeding the young.

THE STOMACH

The stomach is apparently a new acquisition in the vertebrates, possibly arising as a place for the storage of food. This view is supported by several facts. In the embryo vertebrate and in the adult of *Amphioxus* the duct from the liver immediately follows the pharynx, opening just behind the last gill cleft; while the innervation from the

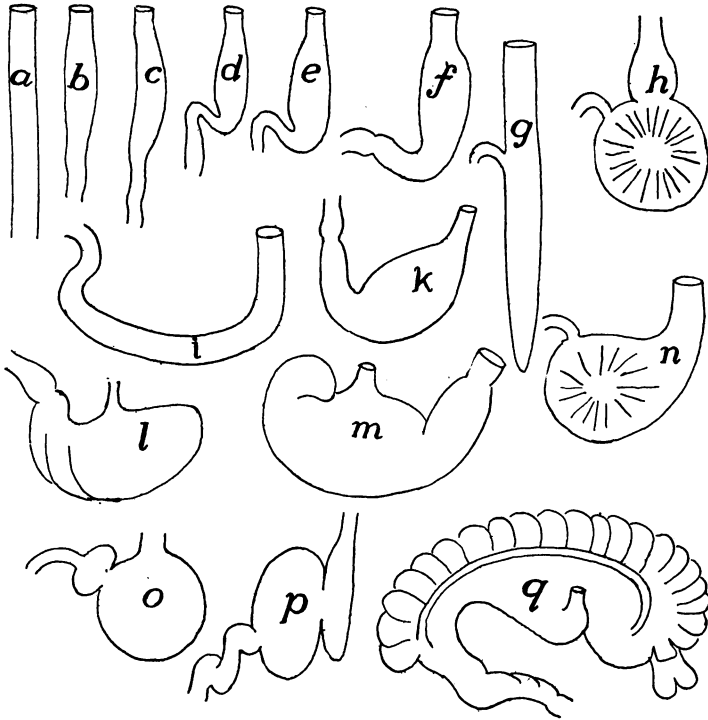


FIG. 253.—Different shapes of stomachs, mostly after Nuhn (Keibel). *a*, *Belone*; *b*, *Proteus*; *c*, *Tropidonotus natrix*; *d*, *Gobius*; *e*, shark; *f*, *Phoca vitulina*; *g*, *Polypterus*; *h*, *Fulica atra*; *i*, *Testudo graeca*; *k*, land tortoise; *l*, rabbit; *m*, pig; *n*, owl; *o*, crocodile; *p*, *Delphinus*; *q*, *Halmaturus*.

tenth nerve shows that both stomach and oesophagus are parts of the pharynx greatly drawn out (fig. 233).

The pylorus, which limits the stomach behind, is a fold of the lining mucous membrane projecting into the interior and reinforced by a circular (sphincter) muscle, which by its contraction, closes the tube so that no food can pass from the stomach until it is properly acted upon by the gastric fluids. The anterior end of the stomach is not so well marked. Usually it is differentiated from the oesophagus

by its greater diameter, but in some of the fishes (fig. 253, *a*) there is no distinction in size. The stomach lies in the cœlom and hence is covered externally by the serous membrane (peritoneum), but the œsophagus usually extends a short distance into the body cavity and then its lower end has the same coat.

The true stomach is characterized by the presence of glands, developed from the mucous layer and emptying into the lumen. Of these glands there are at most (mammals) three kinds: **cardiac**, near the entrance of the œsophagus, which secrete an albuminoid fluid; **pyloric**, near the pylorus, which form mucus; and the most characteristic, the **fundus glands**, which secrete a digestive ferment, **pepsin**. (For the structure of these glands reference should be made to histological text-books.) Tested by glands, many vertebrates (dipnoi, cyprinoids) lack a true stomach, while the sturgeons have the gastric glands extending into the œsophagus. On the other hand, a part of the enlargement called the stomach in mammals often includes a part of the œsophagus (fig. 254, *A, E*).

The shape of the stomach is to some extent dependent upon the shape of the body. In the elongate species it lies in the axis of the trunk, especially in the lower vertebrates (fig. 253, *a*), but with increase in the body width it becomes more transverse. This involves a bending and a torsion of the tube, always to the right, and results in two faces or 'curvatures,' a lesser or **anterior**, and a **greater** or **posterior**, the greater curvature often expanding into a so-called **fundus region**. The end of the stomach which connects with the œsophagus is nearest the heart and hence is called the **cardiac** end.

In the fishes the stomach may be either straight (fig. 256), or saccular, often assuming the form of blind sac (fig. 253, *g*). The line between œsophagus and stomach is not well marked, as the œsophageal folds may continue into the stomach. The teleosts exhibit the greatest variety in shape, in correlation to the differences in food. All gastric glands are lacking in the cyprinoids, while *Amia* has both cardiac and pyloric glands, and, like many teleosts, has the stomach ciliated. In the amphibians and reptiles the distinctions between œsophagus and stomach are more marked, most in the crocodiles. In the amphibians the ciliation of the mouth is continued into the stomach.

In the birds there is a differentiation of the gastric region into two regions, an anterior glandular stomach or **proventriculus**, and a posterior muscular **gizzard**. The proventricular glands secrete a digestive fluid, and the food, mixed with this, is passed on to the gizzard. The walls of the latter have their muscles developed into a pair of discs with tendinous centres, while the glands of the gizzard form a

secretion which hardens into a horny (keratoid) lining, sometimes developing into tubercular structures, of great use in grinding the food, thus in part making good the absence of teeth. In the grain-eating birds small pebbles are taken into the gizzard and are used in triturating the food. (In the fossil pterodactyls small clusters of stones are sometimes found in such a position as to lead to the supposition that these reptiles also had a gizzard.) The gizzard is best developed in the grain-eating birds and is weakest in the birds of

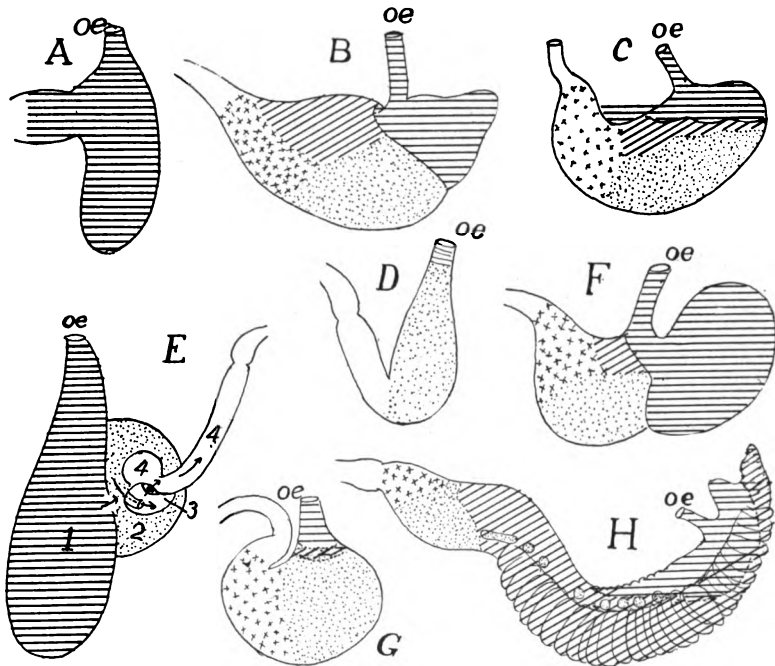


FIG. 254.—Outlines of the stomachs of several mammals (various authors), after Oppel, to show the distribution of the different glandular regions. Horizontal lines, oesophageal; oblique, cardiac; dots, fundus; crosses, pyloric; A, *Ornithorhynchus*; B, gray rat; C, tapir; D, seal; E, whale (*Lagenorhynchus*); F, mouse; G, dog; H, kangaroo (*Macropus*).

prey. In one species of pigeon part of the wall of the gizzard is ossified.

The mammalian stomach shows the greatest range of form (figs. 253, 254) and the greatest development of different kind of glands. It may be a simple sac or it may be subdivided into a series of chambers. In some cases (*Ornithorhynchus*, fig. 254, A) it is almost or entirely oesophageal in character. Occasionally the cardiac glands are absent. It may be a simple sac, longitudinal or transverse in

position, or it may be divided into chambers, reaching the extreme in this respect in the ruminants (fig. 255) and the cetacea (fig. 254, *E*) where four compartments are recognized. In the ruminants two of these, the **rumen** or **paunch** and the **reticulum** or **honeycomb**, are expansions of the œsophagus and serve as reservoirs for food. When feeding the herbage is swallowed and passes into these. Then it is regurgitated into the mouth for mastication, and when it is swallowed again it passes at once into the other parts of the stomach, following the course of the dotted lines of figure 255 to the **psalterium** (**omasus** or **manyplies**), and the **abomasum** or **rennet** for gastric digestion).

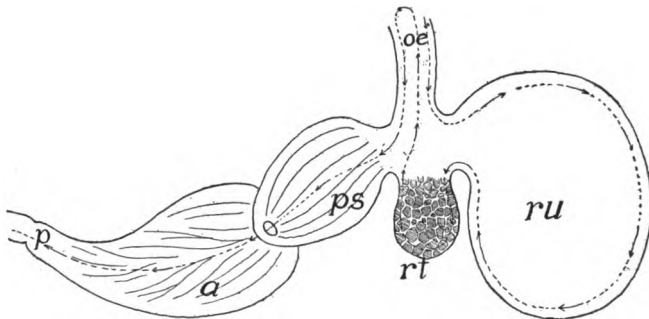


FIG. 255.—Diagram of ruminant stomach, the dotted line showing the course of the food. *a*, abomasum; *oe*, œsophagus; *p*, pylorus; *ps*, psalterium (omasus, manyplies); *rt*, reticulum (honeycomb); *ru*, rumen (paunch).

INTESTINE

The remainder of the prehepatic portion of the alimentary canal, extending from the pylorus to the entrance of the bile duct, is considered as part of the intestine, this region, together with the first part of the posthepatic tube being called the **duodenum**. It is espe-

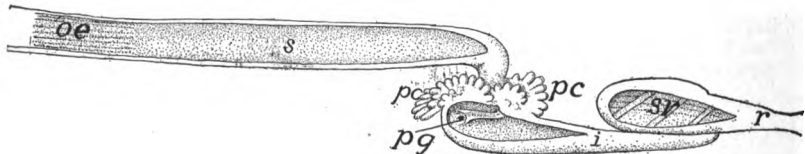


FIG. 256.—Digestive tube of garpike, *Lepidosteus* (after Gegenbaur). *i*, small intestine; *oe*, œsophagus; *pc*, pyloric cæca; *pg*, pylorus; *r*, rectum; *s*, stomach; *sv*, spiral valve.

cially noticeable in many ganoids and teleosts (figs. 256, 259) where it may bear from one to two hundred blind digestive tubes, the **pyloric cæca**. The same region in a few elasmobranchs may have a pair of these cæca or (*Galeus*) it may be expanded into a pouch ('**bursa Entiana**').

The posthepatic intestine is the seat of most of the digestive processes and of absorption of the products of digestion. Here the food, coming from the stomach, is mixed with the bile from the liver and with the pancreatic juice and with the secretions of numerous small glands in the intestinal wall. The increase of surface needed for adequate digestion and absorption is provided in several ways.

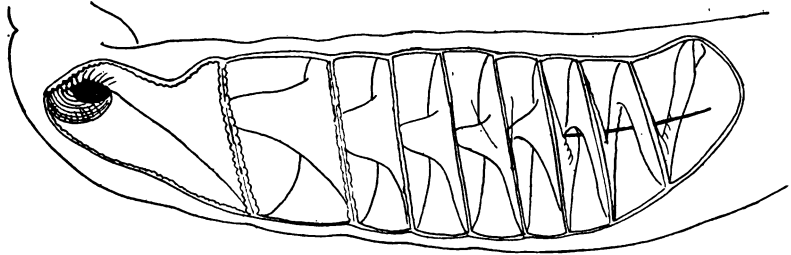


FIG. 257.—Spiral valve of *Raia*, after Mayer.

There may be an elongation of the tube which results in its becoming coiled in the body cavity; the mucous lining may develop folds, both longitudinal and circular; or the folds may break up into numerous minute, finger-like processes (**villi**) which give the surface a velvety appearance. The food undergoing digestion is moved back and forth (**peristaltic motion**) by the antagonistic action of the muscles of the intestinal wall (p. 130); bringing all of it in contact with the absorptive surface.

The length of the intestine is roughly related to the food, being longer in the plant-eating than in the carnivorous species. This is strikingly shown in the frogs, where the tadpole (larva) has a very long intestine, correlated with the vegetable food, while the adult flesh-eating frog has a canal hardly longer than that of the tadpole of half the size.




FIG. 258.—Diagram of spiral valve of *Carcharias*.

In the intestine there are two divisions, an anterior small intestine and a posterior large intestine, terms adapted from the digestive tract of man, though not always appropriate in the lower groups. The line between the two may be marked externally by the development of one or two blind pouches or **cæca** at their junction or by a circular fold or a pair of internal folds of the lining, constituting an **ileo-colic (ileo-cæcal) valve**, both valve and cæca coexisting in many cases. Both large

and small intestines may be subdivided, chiefly by differences in their walls. Thus in the small intestine there are recognized in different groups a **jejunum**, a spiral valve region and an **ileum**, while the large intestine may furnish a **colon**, a **rectum** and a **cloaca**, the latter being the part of the canal into which the urogenital organs open.

In the cyclostomes but two regions occur, the intestine and the rectum, differentiated externally by the larger size of the latter. In the petromyzonts there is an internal fold of the intestine which pursues a slightly spiral course, constituting a **spiral valve**, a structure which reaches its highest development in the elasmobranchs.

In the elasmobranchs the intestine is nearly straight, but its differentiation has proceeded farther. At the junction of small and large intestine is a dorsal blind sac, the **rectal** or **digital gland**. Its function is unknown, but it may correspond to the cæca of the higher groups. In the 'small' intestine is the spiral valve which has two forms, both leading to increase of surface. In most species a fold, carrying blood- and lymph-vessels, arises in a spiral line from the wall of the tube, and its free edge projects into the lumen like a spiral stairway (fig. 257). In a few forms (Carchariidæ, *Galeocерdo*) the line of origin of the fold is straight and its free margin is coiled like a roll of paper (fig. 258). In the large intestine rectum and cloaca are recognized, the **cloaca** being that part which receives the ends of the excretory and reproductive ducts and thus is both digestive and urogenital in character.

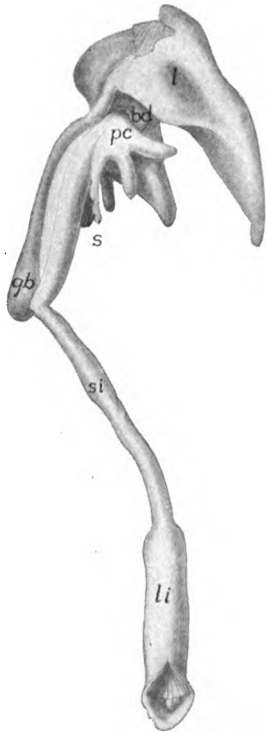


FIG. 259.—Digestive tract of scup (*Stenostomus chrysops*—Princeton 296). *bd*, bile duct; *gb*, gall bladder; *l*, liver; *li*, large intestine; *pc*, pyloric cæca; *si*, small intestine.

Ganoids and dipnoi (fig. 256) also have the intestine nearly straight and a spiral valve, least developed in *Lepidosteus*. In the teleosts the canal may be straight (fig. 259) or may make more or fewer coils, the predaceous species being simplest, while in the mullet (*Mugil*) there may be thirteen or fourteen turns. In the teleosts the line between small and large intestine is often marked by an ileo-colic valve and a few species have a cæcum or rectal gland. A spiral valve rarely occurs in teleosts and a cloaca is never found.

In a few teleosts, in correlation with the translation of the ventral fins, the anus may lie in front of the pectoral girdle.

The intestine is straight in the cæcilians, has a few coils in the perennibranchs and more in the salamanders, while the anura have a greatly convoluted intestine. (Reference has already been made to the differences between the

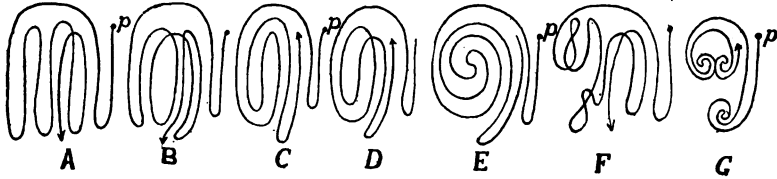


FIG. 260.—Types of coiling of the intestines of birds, after Gadov. *A*, isocœlous; *B*, anticœlous; *C*, antipericœlous; *D*, isopericœlous; *E*, cyclocœlous; *F*, plagiocœlous; *G*, telogyrous; *p*, pylorus.

intestines of the larval and adult frogs, p. 243.) The line between small and large intestine is frequently marked by an ileo-colic valve and in a few forms (*Rana*, *Salamandra*) there is a rudimentary cæcum. The rectum is larger than the rest of the intestine and a cloaca is always present in the amphibia.

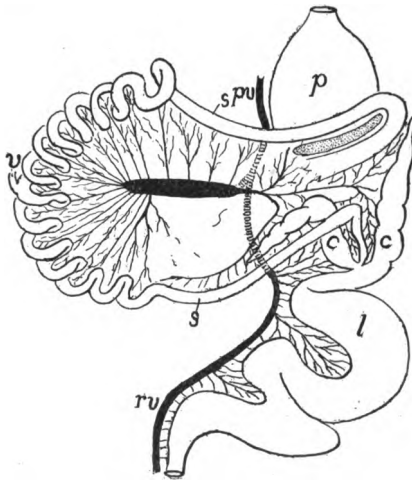


FIG. 261.—Alimentary canal of *Chauna*, after Mitchell. *c*, cæca, *l*, large intestine; *p*, proventriculus; *spv*, portal vein; *rv*, rectal vein; *s*, small intestine; *v*, remnant of vitelline duct.

The reptiles have the intestine coiled (nearly straight in amphisbænans) and usually of about the same diameter throughout. Small and large intestine are separated by an ileo-colic valve, and except in crocodiles a cæcum is usually present, while the cloaca constantly occurs. The spirally twisted coprolites of the ichthyosaurs have been supposed to indicate the existence of a spiral valve, but since in other groups the fæces are formed in the rectum, this is not conclusive.

The intestine is longer in the birds than in the reptiles, but there is considerable difference in the group in this respect. The great increase comes in the colon which is coiled in different ways, which may be reduced to seven plans or combinations of loops and spirals (fig. 260). In a few forms (woodpeckers, parrots, etc.) there is no cæcum, but usually the junction of large and small intestine is marked by one or two cæca (fig. 261). In some cases these cæca are lined with villi, or portions may be ciliated, while the very large cæcum of the ostrich is spirally coiled. Many birds have a pocket, the **bursa Fabricii**, of unknown functions, developed from the dorsal part of the cloaca. It arises from the entodermal portion and extends forward, dorsal to the rectum (fig.

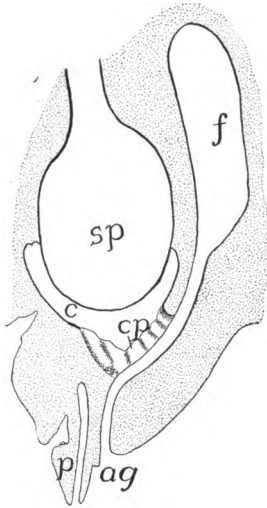


FIG. 262.

FIG. 262.—Diagrammatic longitudinal section of the cloacal region of a duck embryo at the twenty-second day of incubation, after Poindyer. *ag*, anal groove; *c*, cloaca; *cp*, cloacal plate; *f*, bursa Fabricii; *p*, phallus, with caecal duct; *sp*, stercoral pouch of rectum.

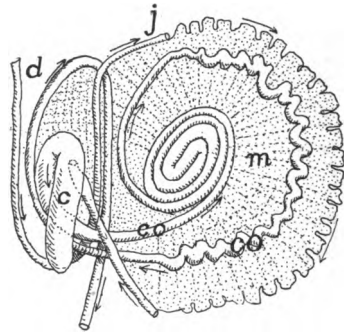


FIG. 263.

FIG. 263.—Semidiagrammatic course of intestine of new-born deer *Cervus canadensis*, after Weber. *c*, cæcum; *d*, duodenum; *co*, colon; *j*, jejunum; *m*, mesentery.

262) later connecting with the ectodermal (proctodeal) part of the cloaca. In some cases it degenerates in the adult.

The limits of large and small intestine in the mammals are usually marked by an ileo-colic valve and a single cæcum, but there are two cæca in some edentates, while some edentates, bats, carnivorous mammals and many whales lack either cæcum or valve. The cæcum is larger in the herbivorous forms and frequently there is a relation between the development of cæcum and stomach. The cæcum becomes enormous in certain rodents and marsupials (sometimes longer than the body) and plays an important part in digestion, being sometimes lobulated or furnished with internal folds, those of the rabbits being arranged in a spiral manner. In man and the anthropoids and some other forms, as is well known, the distal part of the cæcum degenerates to a

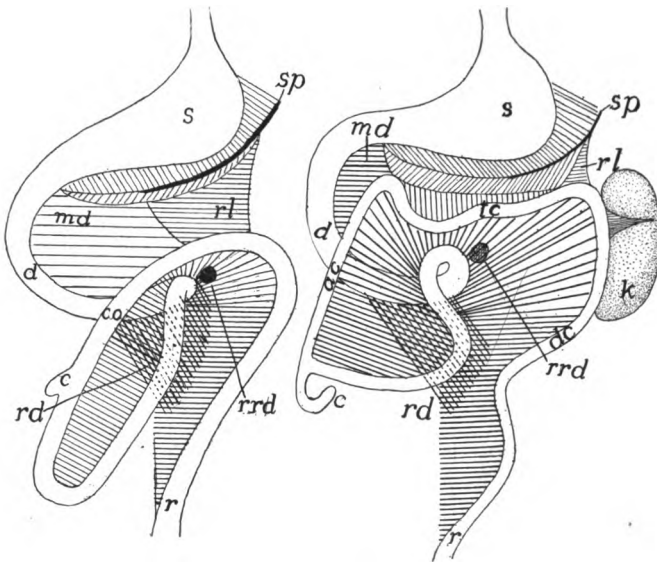


FIG. 264.—Scheme of alimentary canal and mesenteries in human embryos, 30 and 50 mm. long, after Klaatsch. *ac*, ascending colon; *c*, cæcum; *co*, colon; *d*, duodenum; *dc*, descending colon; *k*, kidney; *r*, rectum; *rd*, recto-duodenal ligament; *rl*, recto-lienal ligament; *rrd*, recto-duodenal recess; *s*, stomach; *sp*, spleen; *tc*, transverse colon.

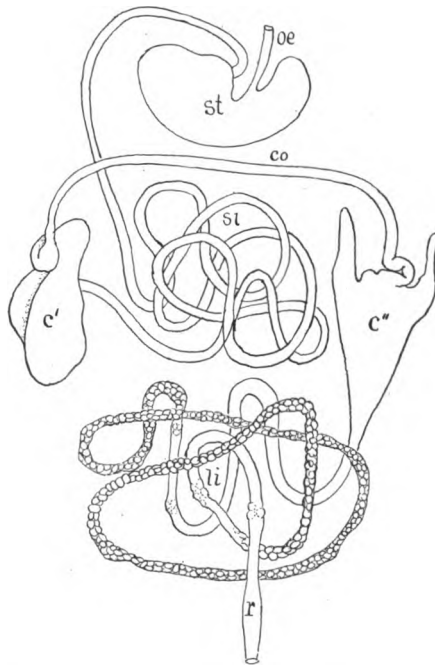


FIG. 265.—Digestive tract of *Hyrax*. *c'*, normal cæcum; *c''*, caeca peculiar to *Hyrax*; *co*, colon; *li*, large intestine; *oe*, oesophagus; *r*, rectum; *si*, small intestine; *st*, stomach.

rudiment, the vermiform appendix, the lumen of which tends to become obliterated with increasing age.

Both small intestine and colon are at first straight, but with growth they become longer, involving convolutions varying in pattern and extent in different groups, the patterns of the colon being of some systematic value. The full history has been worked out only for man, two stages being represented in fig. 264. The genus *Hyrax* is remarkable for a pair of cæcal diverticula arising from the colon (fig. 265). In the monotremes the rectum terminates in a cloaca as in the sauropsida, and the same condition occurs in the young of all higher mammalia. In the later stages, however, the urogenital and digestive openings become separated by the formation of a perineal fold between the two.

THE LIVER (HEPAR)

The liver, the largest gland in the body, has several functions. It secretes the **bile (gall)** and forms several internal products such as glycogen, urea and uric acid, of great importance in the animal economy. The bile is passed to the intestine by the **bile duct (choledochal or hepatic duct)**, but other products are carried away by the blood (internal secretion).

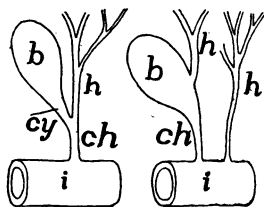


FIG. 266.

FIG. 266.—Diagram of two types of bile ducts. *b*, gall bladder; *ch*, choledochal duct; *h*, hepatic ducts; *i*, intestine.

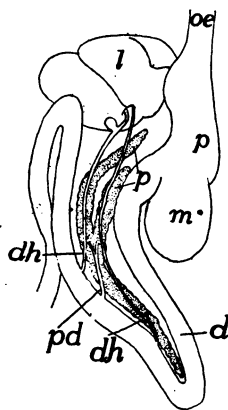


FIG. 267.

FIG. 267.—Liver and pancreas of American ostrich (*Rhea*), after Gegenbaur. *ch*, choledochal duct; *d*, duodenum; *dh*, bile ducts; *l*, liver; *m*, stomach; *oe*, oesophagus; *p*, pancreas; *pd*, pancreatic duct; *s*, stomach.

The anlage of the liver is a ventral diverticulum (fig. 268) from the archenteron (p. 221), which grows forward from its point of origin, branches again and again, the ultimate branches forming the glandular part of the organ, the proximal parts of the outgrowth giving rise to the bile duct (occasionally multiple) which empties into the intestine. As a result of this method of formation the liver is to be regarded as a compound tubular gland, the lumens of the tubules forming the **gall capillaries** which eventually empty into the duct. This tubular condition is readily recognized in the ichthyopsida, but it is masked in the amniotes and especially in the mammals, in part by the

anastomosis of the tubules, in part by the interrelation of the bile and blood-vessels.

With development the liver grows cephalad from its point of origin, but this forward growth is limited by the presence of the blood-vessels which develop the sinus venosus and the hepatic veins and also contribute to the septum transversum (see circulation), and so its later increase must cause it to grow in the opposite direction. As it increases in size there is an immigration of mesenchyme between the lobules and with these the blood-vessels enter. At the same time the liver grows away from the alimentary canal, carrying the peritoneum before it so that it receives an outer serous coat.

Usually the bile duct (when there are several ducts only one is concerned) forms a lateral diverticulum, the **gall bladder**, which serves as a reservoir for the bile. This is usually placed on the dorsal side of the liver, but it may be immersed in the substance of the gland. In some cases, even in mammals, the gall bladder may be lacking. When a gall bladder is present, three regions may be recognized in the bile ducts. Those parts which lead from the liver to the connexion with the bladder are called **hepatic ducts**; these are met by the **cystic duct** leading from the bladder, and the

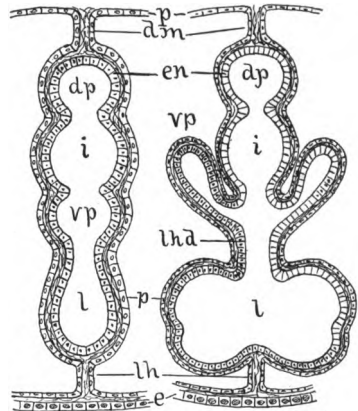


FIG. 268.—Diagrams of the development of liver and pancreas, based on Schimkewitsch. *dm*, dorsal mesentery; *dp*, dorsal pancreas; *e*, ectoderm; *en*, entoderm; *i*, intestine; *l*, liver; *lh*, falciform ligament of liver; *lhd*, hepato-duodenal ligament; *p*, peritoneum; *vp*, ventral pancreas.

common duct, formed by the two and which empties into the intestine is the **choledochal duct** (fig. 266). The shape of the gland is in part determined by the shape of the body, being long in elongate species, sometimes consisting of two consecutive lobes. Another modifying factor is the shape and size of the adjacent organs, stomach, etc. Usually the liver is divided into right and left halves, these corresponding to the first division of the anlage, but these halves are hardly indicated in some of the teleosts. Frequently, and especially in mammals, the halves become subdivided into lobes of varying size, which are arranged in various ways. The liver is relatively larger in the ichthyopsida than in the amniotes, but the cyclostomes have a small

liver, that of the myxinoids being in two parts. It is larger, too, in the flesh-eating than in the herbivorous species. The blood supply, chiefly through the portal vein and to a less extent by the hepatic artery (see circulation), is very large. The color of the gland is very variable, especially in teleosts, where it may be brown, yellow, purple, green and even vermilion.

THE PANCREAS

The second largest of the digestive glands, the pancreas, secretes digestive ferments of great strength (trypsin, steapsin, amylopsin), which digest both proteids and carbohydrates. In some respects it resembles the salivary glands and so compensates in part for the absence of them in the lower vertebrates (p. 235). The pancreas arises by diverticula from the wall of the intestine close to the liver

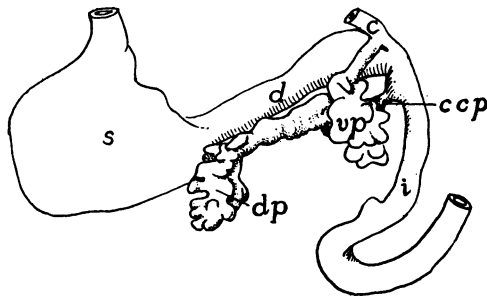


FIG. 269.—Diagram of developing pancreas of cat, after Thyng. *c*, ductus coledochus; *d*, duodenum; *dp*, dorsal pancreas; *ccp*, its duct; *i*, small intestine; *s*, stomach; *vp* ventral pancreas.

(fig. 268). There are usually three of these diverticula, one dorsal and two ventral, the ventral soon uniting (fig. 269), but in the sharks there is only a single dorsal diverticulum, while in the sturgeon there are two dorsal and two ventral. In a general way these develop much like the liver, the distal portions of the divisions forming the glands, which are of the acinous type; the proximal portions form the ducts. Of these ducts all may persist; all but one may disappear, while in the lampreys all may be lost. In many mammals two ducts persist, the ventral forming the main pancreatic duct (Wirsung's duct), the dorsal, the accessory or Santorini's duct. The ducts may remain distinct; they may unite before entering the intestine or one of them may unite with the bile duct.

For a long time it was supposed that a pancreas was lacking in

certain vertebrates (some teleosts, dipnoi, cyclostomes), but recent studies have shown its presence in many of these. In the case of some teleosts it occurs as a slender tube in the mesentery; in the dipnoi it is outside of the muscles in the intestinal wall, while in the cyclostomes it is partly concealed at the insertion of the spiral valve, partly (myxinoids) in the liver. In these forms, owing to the complete disappearance of the duct it becomes a gland of internal secretion. The pancreas may be elongate, compact, or sometimes extremely lobulated. Usually (fig. 267) it lies in a loop of the duodenum. From certain peculiarities of structure the question has arisen as to whether two distinct structures are included in the pancreas.

THE RESPIRATORY ORGANS

The respiratory organs have for their purpose the exchange of gases between the blood and the surrounding medium—water or air—carbonic dioxide being given off and oxygen being absorbed by the circulating fluid. In order that the exchange be readily effected it is necessary that the organs be richly vascular, that the walls between the blood and the surrounding medium be extremely thin so as to permit rapid osmosis, and that the osmotic surface be as great as possible. Further, there must be an adequate mechanism for passing the oxygen-containing medium over the respiratory surfaces.

In the vertebrates the organs of respiration are developed in more or less intimate connexion with the cephalic portion of the digestive tract, just behind the cavity of the mouth. This part of the alimen-

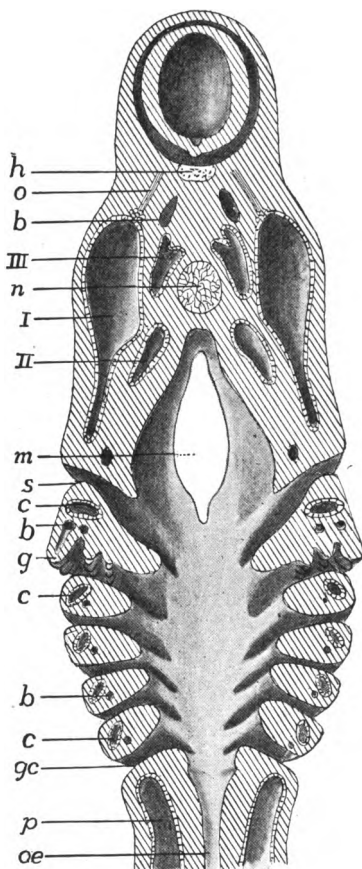


FIG. 270.—Pharyngeal region of a young *Acanthias* embryo. *b*, blood-vessels; *c*, coelomic cavities of gill arches; *g*, developing gills; *gc*, gill clefts; *h*, hypophysis; *m*, mouth; *n*, notochord; *o*, oculomotor nerve; *oe*, oesophagus; *p*, peritoneal cavity; *s*, spiracular cleft; *I-III*, first to third head cavities.

tary canal, which thus serves for the passage of food and for the performance of respiratory functions is called the **pharynx**. The organs themselves may take the form of gills or branchiæ, adapted for aquatic respiration, or of lungs (**pulmones**) fitted for breathing air. In this connexion must be considered the cases of certain fishes, amphibia, and turtles where respiration is effected in part by the skin, the pharyngeal epithelium, or the digestive tract. There are also a number of other structures—air bladder, thymus and thyroid glands, etc., which are derived from the pharynx, though they are without respiratory functions.

GILLS OR BRANCHIÆ

The typical gills or branchiæ are developed on the walls of some of the **visceral clefts** (**gill or branchial clefts**) which are formed in the

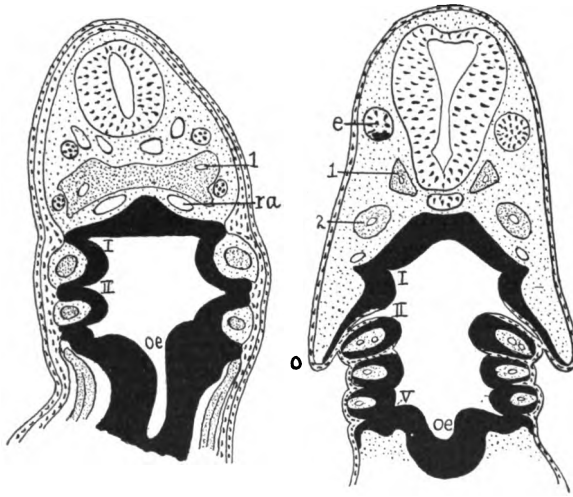


FIG. 271.—Two stages in the development of the gill-clefts of *Ceratodus*, after Greil. Entoderm, black; mesoderm stippled. *o*, operculum; *oe*, oesophagus; *ra*, radix aortæ; 1, 2, first and second somites of Van Wijhe; I-V, visceral pouches, not yet broken through. Noticeable are the ingrowths of ectoderm in the line of the future clefts.

sides of the pharynx. These clefts arise as paired pouches or grooves of the entoderm of the pharynx (figs. 232, 271). They extend laterally, pushing aside the mesoderm, until they reach the ectoderm, ectoderm and entoderm then fusing to a plate. This in most cases becomes perforated, so that the cavity of the pharynx is connected with the exterior by a series of openings (fig. 270), the clefts developing in succession from the cephalic end backward.

These **visceral pouches** develop in all vertebrates, but in the mammals only a few or even none of them break through to the exterior. In the adult amniotes the pouches may disappear without leaving a trace, aside from the Eustachian tube (p. 202) and the various ductless glands mentioned below (p. 264). The largest number of clefts in any true vertebrate (there are more in *Amphioxus* and *Balanoglossus*) is fourteen pairs in some specimens of *Bdellostoma*. Other cyclostomes have seven (Dohrn thinks there are traces of more in *Petromyzon*), eight to seven in notidanid sharks, five or six in teleostomes, amphibia and reptiles, and five in birds and mammals. In this numbering the oral cleft is not included, though there is some evidence that the mouth arose by the coalescence of a pair of gill clefts (p. 221).

There is some difference between the serial repetition of the gill clefts (**branchiomerism**) and the other segmentation of the body, and possibly the metamerism of the head is not of the same character as the branchiomerism.

The appearance of branchial pouches or clefts and the relation of the aortic and branchial arches in the amniotes, where gills are never developed, can best be explained by the assumption that these animals have descended from branchiate ancestors.

Between each two successive gill clefts is an **interbranchial septum**, covered externally with ectoderm, internally with entoderm, and with an axis of mesoderm, the latter, in the early stages containing a diverticulum of the coelom. Later, blood-vessels (aortic arches) and skeletal elements (visceral arches, p. 69), are developed in each septum, the visceral arches forming on the splanchnic side of the coelom and hence are not comparable to girdles or ribs (p. 110).

In cyclostomes and fishes the **gills** proper are developed on the anterior and posterior walls of the interbranchial septa. The gills are either filamentous or lamellar outgrowths of epithelium, each containing a loop of a blood-vessel, so that between the blood and the water there are but two extremely thin layers, a matter of importance in the exchange of gases. Each cleft is thus bounded in front and behind by gill plates or filaments (fig. 274) those on a side forming a **demibranch**, the two demibranchs of a septum constituting a **gill**, while each cleft is bounded by demibranchs belonging to two gills. In the young elasmobranch and in the young of a few teleosts before hatching, the gill filaments protrude from the clefts as long filaments (**external gills**), but they are absorbed later. These are partly

respiratory in character, but, in some cases at least, they also serve for the absorption of food from the egg or the uterine fluids.

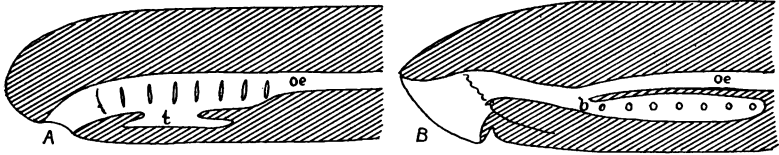


FIG. 272.—Diagram of relations of oesophagus and respiratory tracts in (A) *Myxine* and *Ammocetes*, and (B) *Petromyzon*: *b*, branchial duct ('bronchus'); *oe*, oesophagus; *t*, thyroïd gland.

In the cyclostomes and notidanid sharks the first cleft (between the mandibular and hyoid arches) bears gills like the rest, but elsewhere it differs. In most elasmobranchs and a few ganoids (sturgeon, *Polypterus*) it becomes reduced in size by closure beginning below (fig. 143) so that the persisting part of the original opening is on the dorsal side of the head, forming the **spiracle**. In other vertebrates, including the chimæroid and many true sharks, the spiracle is closed in the adult, but in the anurous amphibia and the amniotes its inner portion persists as the tympanic cavity and the Eustachian tube of the ear (p. 202).

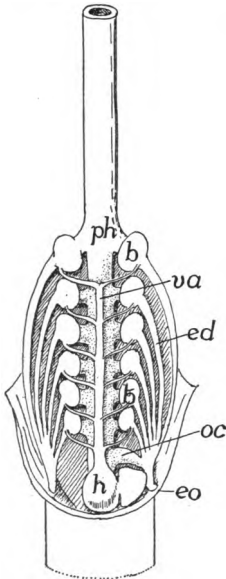


FIG. 273.—Gill pouches and blood-vessels of *Myxine*, after Müller. *b*, gill pouches; *ed*, efferent ducts; *eo*, external gill opening; *h*, heart; *oc*, oesophago-cutaneous duct; *ph*, pharynx; *va*, ventral aorta.

Usually the series of gills begins with the demibranch on the posterior face of the hyoid arch, but there is never a demibranch on the posterior wall of the last cleft. In some cases the series of gills is still farther reduced by the loss of demibranchs from other arches, the reduction reaching the extreme in the symbranchiate genus *Amphipnous*, where there are no gills on the first and fourth branchial arches and only one demibranch on the second.

In cyclostomes the gill clefts in the adult are some distance behind the mouth, partly as the result of the great development of the lingual apparatus. In the larvæ of *Petromyzon* (*Ammocetes*) the seven clefts are nearly typical, the demibranchs extending inward nearly to the pharyngeal wall, each cleft having a short efferent duct leading to the exterior, while the oesophagus begins at the hinder end of the respiratory region (fig. 272, A). With the metamorphosis

to the adult condition the œsophagus grows forward, dorsal to the gill clefts, as far as the anterior end of the pharynx, so that there is cut off a ventral respiratory tube, the **branchial duct** or 'bronchus' (fig. 272, *B*). At the same time the gill-bearing part of each cleft becomes separated from the branchial duct by a short **afferent duct**, while the part of the cleft containing the gills is transformed into an oval pouch (much as in *Myxine*, fig. 273), in allusion to which the cyclostomes are often called marsipobranchs (pouched gills).

In the myxinoids the tract between the mouth and the pharynx is longer and the pharyngeal region is never differentiated into œsophagus and branchial duct (fig. 272, *A*). *Myxine* has six pairs of gills; *Bdellostoma* has from seven

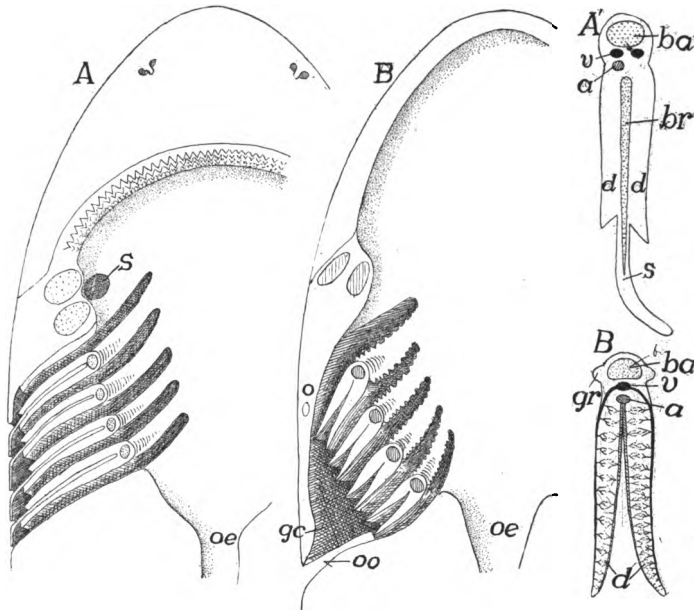


FIG. 274.—Diagram of gill clefts in (*A*) elasmobranchs and (*B*) teleosts. *A'* and *B'*, a single gill of each. *a*, artery; *ba*, branchial arch; *br*, branchial ray; *d*, demibranch; *gc*, atrial chamber; *gr*, gill raker; *o*, operculum; *oe*, œsophagus; *oo*, opercular opening; *s*, spiracle, in *A'*, septum; *v*, veins.

to fourteen, the number varying even on the two sides of our Pacific coast species, *B. dombeyi*. In *Bdellostoma* and the lampreys the efferent ducts of the gill pouches open separately to the exterior; in *Myxine* (fig. 273) they unite to a common duct on either side, with a single external opening. In both *Bdellostoma* and *Myxine* an **œsophageo-cutaneous duct** leads from the left side of the œsophagus, either into the common efferent duct or directly to the exterior. It resembles a gill cleft in all except the unpaired condition and the absence of gills.

Fishes have two types of gills and associated structures (fig. 274). With the exception of the chimæroids, the elasmobranchs have the interbranchial septum greatly developed (fig. 274, *A*), so that it ex-

tends some distance beyond the demibranchs, thus differentiating an excurrent canal in the cleft. This prolongation of the septum bends caudally at the outer end, thus protecting the delicate gills from injury (fig. 274, *A*).

In all other fishes (teleostomes and chimæroids) the posterior end of the hyoid septum grows back as a broad fold over the clefts behind, thus forming a **gill-cover** or **opercular apparatus** (fig. 274, *B*, *o*) which encloses an **extrabranchial** or **atrial chamber** into which all the clefts empty and which, in turn, opens by a single slit (*oo*) behind the operculum. This opercular opening is usually long in the vertical direction, but it is reduced to a circular opening on either side in a few teleosts, while in the symbranchiates there is a single opening in the mid-ventral line for the two sides of the body.

Correlated with the protection of the gills by an opercular apparatus is the reduction of the interbranchial septum (cf. fig. 274, *A'*, *B'*), so that it forms




FIG. 275.

FIG. 275.—Head of *Chlamydoselache*, after Garman; *f*, opercular fold.

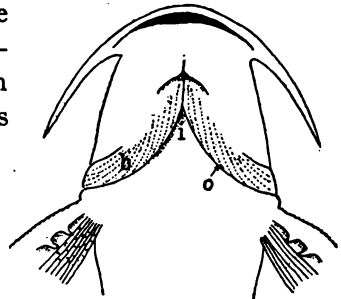


FIG. 276.

FIG. 276.—Ventral side of *Schilbeodes*, after Jordan and Evermann, *b*, branchiostegal membrane; *i*, isthmus; *o*, opening from atrial cavity.

only a slender bar, from which the demibranchs project far into the atrial chamber. Usually the two opercular folds are continuous beneath the pharynx, which points to the beginnings of an operculum in the oldest living shark, *Chlamydoselache* (fig. 275). In the chimæroids, as has just been said, there is a well-developed opercular fold which is strengthened by cartilaginous rays arising from the hyoid arch. In the teleosts and ganoids two parts are differentiated in the opercular apparatus, the **operculum** or **gill-cover** proper, supported by a series of large cartilages or bones (p. 85), and a more ventral part, the **branchiostegal membrane** (fig. 276) which is very flexible and has a skeleton of slender **branchiostegal rays**. In these cases the ventral wall of the pharynx is reduced to a slender bar, the so-called **isthmus**.

In all cases the gills and accessory structures are such that an almost continuous stream of water is passed over them, thus bringing

the oxygen needed by the blood. As a rule this water is drawn into the mouth by the enlargement of the oral cavity, and by its contraction it is forced out through the clefts, passing over the gills on its way. In the myxinoids the œsophageo-cutaneous duct is supposed to act as the incurrent passage when these animals have the front of the head immersed in the flesh of a fish. In the lampreys the water is said to be taken and forced out through the gill clefts when these animals are attached to some object. In many of the elasmobranchs the spiracle serves as an incurrent opening, and it is provided with a valve developed from the anterior wall, which closes and prevents any backflow. Both sturgeons and *Polypterus* have spiracles throughout life.

In the amphibia the gill pouches are formed in the same way as in the fishes, but the first and the fifth never break through, and all clefts are usually closed in the adult, the exceptions being the perennibranchs and the derotremes, where from one to three external openings persist through life. In cæcilians and urodeles there is a



FIG. 277.—External gills of young *Amphiuma*, partially covered by opercular fold.

reduced operculum which never is prominent, being merely a fold of integument in front of the gill area. In the larval anuran the opercular fold is well developed, though it never has any skeletal support. Before the time of metamorphosis this fold grows backward over the gill clefts, the gills, and the fore limbs, and fuses with the sides and the floor of the body behind the latter. In this way these parts are enclosed in an **atrial chamber**, the chambers of the two sides being in communication below the pharynx. During larval life the atrial chambers open to the exterior in most anura by a single excurrent pore, usually on the left side, but in the larval aglossate amphibia (*Pipa*, *Xenodactylus*, etc.) right and left excurrent openings occur.

The gills of the amphibia are certainly of ectodermal origin. In the early larva usually three pairs of external gills are formed before the clefts break through. These are covered with ciliated epidermis. They arise on the outer surface of the third, fourth and fifth arches and are supplied by the corresponding aortic arches of the blood system. They have no skeletal support and vary considerably in

form, being pectinate, bipinnate, dendritic, etc. (fig. 277), and in one species of cæcilian (where but a single pair occurs) they are large leaf-like lobes. In the perennibranchs these external gills persist throughout life (they are said to be absorbed and reformed in *Siren*), and no gills are developed in the clefts. Elsewhere, in the amphibia, in when the clefts break through, there is an ingrowth of ectoderm into each cleft, from which the internal gills are developed, so that, for a time, in the anura there coexist both external and internal gills (fig. 278, right side). In all derotreme and salamandrine urodeles the external gills are absorbed at the time of metamorphosis (the process in the derotremes, fig. 277, being accompanied by an overgrowth by

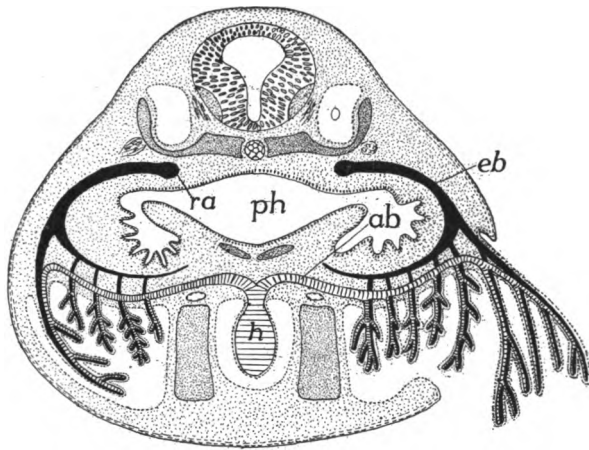


FIG. 278.—Diagram of the relations of external and internal gills in the anuran tadpole, after Maurer. *ab, eb*, afferent and efferent branchial arteries; *h*, heart; *o*, ear cavity; *ph*, pharynx; *ra*, radix aortæ.

the opercular fold). In the anura (fig. 278) as the operculum grows over the clefts, the external gills, so prominent in the earlier stages, are folded into the atrial chamber where they are gradually reduced, while those developed from the walls of the clefts become functional, water taken in by the mouth, passing over them in its way to the exterior via the atrial chamber. Then, when the metamorphosis is completed, the clefts are closed and the gills are absorbed, and at the same time the tail is reduced and the fore legs are freed and the tadpole (larva) assumes the adult shape.

For many years the gills of the fishes were regarded as entodermal in origin, and from this it followed that the gills of fishes and those of the amphibia were different in character—were not homologous.

In recent years considerable doubt has been thrown on the entodermal character of the piscine gills. In the first place, the amphibian gills are certainly ectodermal, and it is improbable that structures so similar as the gills of these two groups should have developed in two different ways in the vertebrate phylum. In several fishes there is evidence that the ectoderm grows inward along the line where the cleft is later to open (fig. 271), and this makes it probable that similar conditions exist in all ichthyopsida, although the evidence presented by *Petromyzon* points in a different direction. The matter is one of great difficulty, and cannot be regarded as settled.

One of the most prominent differences between the sharks and the skates is in the position of the gill clefts—on the sides of the 'neck' in the former, on the lower surface of the body in the latter—differences brought about by the union of the anterior appendages with the head in the skates.

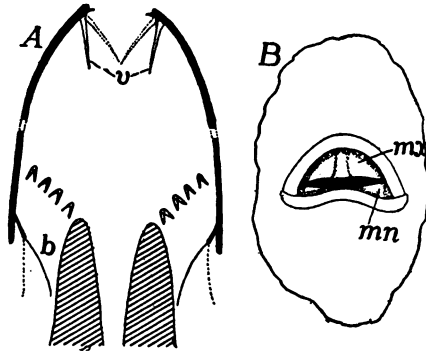


FIG. 270.—Breathing valves of teleosts, after Dahlgren. *A*, schematic figure, the anterior half in the vertical, the posterior in the horizontal plane; *B*, mouth of sunfish (*Eupomotis*); *b*, branchiostegal valve; *mn*, *mx*, mandibular and maxillary valves; *v*, oral valves.

In the sea horses and pipe fishes (lophobranchs) the gills form small rounded tufts in the gill chamber. In the labyrinthine fishes, many of which can live for some time in the air, there is a complicated bony structure—the **labyrinth**—in the gill chamber. This is covered by a richly vascular folded membrane which is used in aerial respiration. In some of the symbranchii there is a sac between the hyoid and the first branchial arch which extends back as far as the shoulder girdle and is supplied with venous blood from the branchial vessels, while in the siluroid *Saccobranchus* a somewhat similar diverticulum from the branchial chamber extends back along side the vertebral column even to the abdominal region. In both the walls are very vascular and the organ is respiratory.

Many of the teleosts have **breathing valves**. Of these, the anterior pair are at the mouth opening, attached to the margins of the jaws, and permitting the ingress but not the outflow of water. The second pair is formed by the

branchiostegal membrane which closes the opercular opening and permits only the water to flow out. The current is caused by the alternate enlargement and constriction of the oral cavity. The action of the valves is easily understood from figure 279.

In some fishes with an operculum (*Acipenser*, *Lepidosteus*, *Polyodon*, *Polypterus* many teleosts), an opercular gill with respiratory functions is developed as a series of lamellæ on the inner surface of the operculum. In some elasmobranchs, even those in which the spiracle is closed, vertical folds (pseudobranchs) are developed on the anterior wall of the cleft. These are homologous with gills, and from their position must be regarded as the demibranch of the posterior

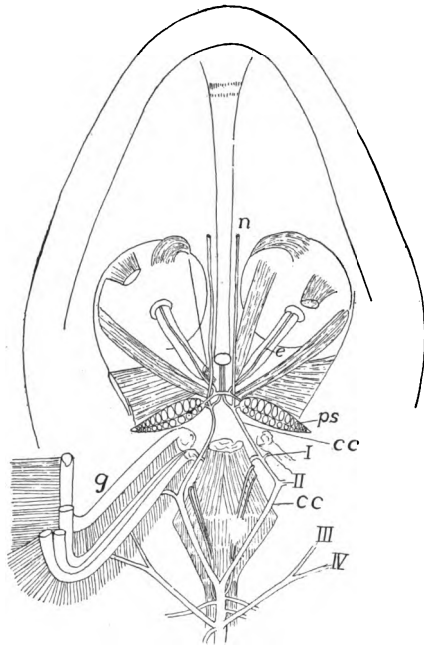


FIG. 280.—Dissection of pseudobranchs (*ps*) and cephalic circle in pike (*Esox*), after Maurer. *cc*, cephalic circle; *e*, vessels to eyes; *g*, gills; *n*, vessels to palate and nose; *I-IV*, efferent branchial arteries.

side of the mandibular arch. On the other hand, they are not respiratory, as they receive arterial blood, which passes from them to the chorioid coat of the eye and in some cases to the brain.

Pseudobranchs are common in teleosts, usually lying on the medial side of the hyomandibular bone, but sometimes carried up to the floor of the skull. When free they are gill-like in appearance, but in some species they are covered by muscles and connective tissue (fig. 280), when they have a blood-red, glandular appearance. They occur also in *Lepidosteus*, most sturgeons and in *Ceratodus*, but none are found in *Amia* or *Protopterus*.

In addition to what was said above regarding the amphibian gills, may be

added that some of the stegocephals in the larval stages, had gills supported by gill arches, the probabilities being that these were functional.

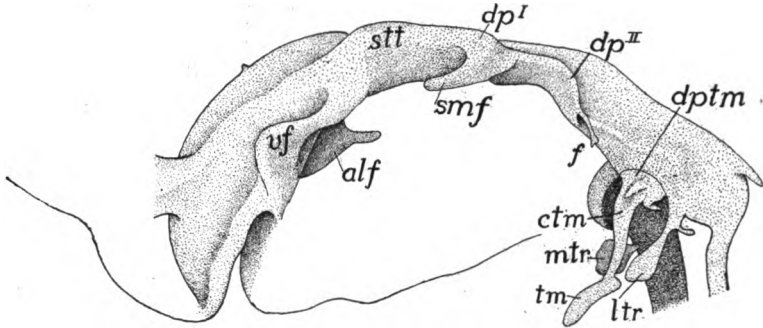


FIG. 281.—Cast of oropharyngeal region of pig embryo, 17 mm. long, after Fox. *alf*, alveo-lingual fold; *ctm*, cervical cord of thymus; *dp^I*, *dp^{II}*, dorsal apex of first and second pharyngeal pouches; *dptm*, dorsal plate of thymus; *f*, filiform appendix of second pouch; *mtr*, median thyroideus; *ltr*, lateral thyroideus; *smf*, submeckelian fold; *stt*, sulcus thyroideus; *tm*, thymus; *uf*, vestibular fold of mouth.

Gills are never developed in the amniotes, but in the embryos the paired visceral pouches are formed (figs. 232, 281) five in reptiles,

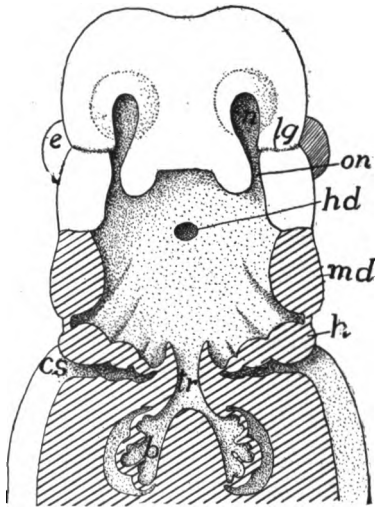


FIG. 282.—Head of human embryo with pharyngeal floor removed, after Hertwig. Cut surfaces lined. Compare with fig. 247; *b*, lung; *cs*, cervical sinus; *e*, eye; *h*, hyoid arch; *hd*, hypophysial duct (Rathke's pocket); *l*, lung; *lg*, lacrimal duct; *md*, mandible; *n*, naris; *on*, oronasal groove; *tr*, trachea.

four in birds and mammals—in the same way as in the fish-like forms. Some of these never break through to form clefts (in man only the first), although their position is indicated by grooves on the outside

of the neck. The process of obliteration of these external grooves is interesting. The anterior arches, especially the hyoid, enlarge and slide back over those more posterior, so that at least the external branchial grooves lie in a pocket, the cervical sinus (figs. 282, 286). Later a process from the hyoid arch extends over and closes the sinus, a process recalling the history in the anura. Internally the entodermal branchial pouches, with the exception of the first, disappear, but the first persists as the tympanic cavity and the Eustachian tube described in connexion with the ear (p. 202).

PHARYNGEAL DERIVATIVES

Several structures arising in the pharyngeal region, some from gill clefts, some from other parts of the walls of the pharynx, naturally comes for mention here, though none of them are respiratory in character.

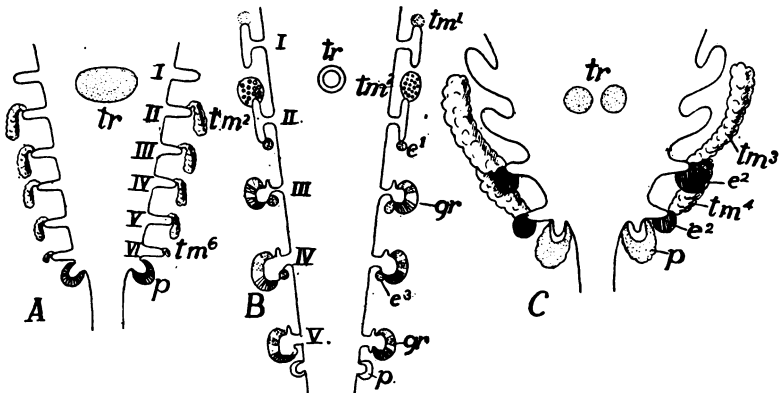


FIG. 283.—Schemes of the origin of several pharyngeal derivatives in (A) *Raia*, (B) anuran and (C) chick, after Verdun. *cd*, carotid gland; *e*, epithelial body; *gr*, gill-remnants; *p*, postbranchial body; *tm*, thymus; *tr*, thyreoid; I-VI, gill pouches or clefts.

Among these are the **thymus glands**, the functions of which are as yet very obscure. They arise as solid outgrowths from the dorsal angle (the ventral angle in mammals) of a varying number of gill pouches. Usually they are regarded as entodermal, but a few observers claim that there is an ectodermal contribution to them.

In the cyclostomes apparently all seven (lampreys) clefts are concerned in their development. In the elasmobranchs (fig. 283, A) clefts 2-6 and possibly the spiracle contribute; in some instances the sixth does not. In teleosts and cæcilians the numbers are 2-6; in urodeles 1-5, the first and second degenerating. In the anura (fig. 283, B) permanent contributions come from

clefts 1 and 2, while in the amniotes (fig. 283, C) clefts 3 and 4 are the only sources of thymus material.

These ingrowths result in a richly vascular organ which, by the intrusion of connective tissue, may assume an acinous form. Its form and position vary rather widely in the various groups of vertebrates.

In *Myxine* a number of lobules behind the gill region have been interpreted as a thymus by some, by others as pronephric in origin. In the fishes the thymus is an elongate, much lobulated organ behind the dorsal ends of the gill arches (usually the fourth arch in teleosts). In most amphibia it is small and lies behind the angle of the jaw and the tympanic cavity, but in the cæcilians (and snakes) it consists of a series of elements corresponding to the clefts in position, the original

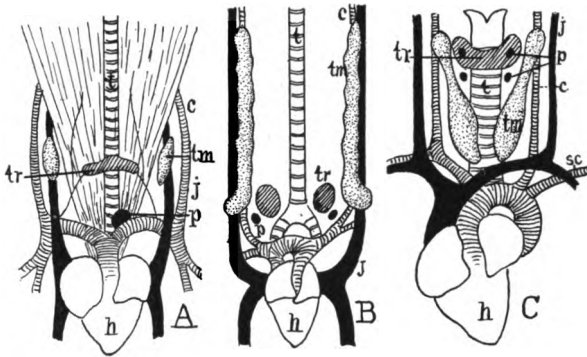


FIG. 284.—Pharyngeal derivatives in (A) lizard, (B) hen, and (C) calf, after de Meuron. *c*, carotid artery; *j*, jugular vein; *h*, heart; *p*, parathyroid; *sc*, subclavian artery; *t*, trachea; *tm*, thymus; *tr*, thyreoid.

branchiomic character being retained. In the reptiles it is in the sides of the neck (fig. 284, A), where it often consists of two or three sections. In the birds it is more elongate and band-like (fig. 284, B). In the mammals it is at first in the sides of the neck (fig. 284, C), but in the adult it has been carried back into the thorax, from which it more or less extends forward. The thymus glands of several domestic animals are sold in the markets as 'throat sweetbread.' With increase in age, the gland in mammals (the whales and seals excepted) tends to grow (in man) until about the fifteenth year, after which it becomes smaller. It was formerly said to reach its maximum at the second year, and then gradually to atrophy by conversion into fatty tissue, but it retains its functional structure until middle life.

Closely related to the thymus glands in origin, but not in func-

tion, are a series of little-known bodies which have been described under several names: **epithelial bodies**, **parathyreoids**, **postbranchial bodies**, **suprapericardial bodies**, **gill remnants**, **ultimobranchial bodies**, etc. These arise from parts of the visceral clefts, separate from their parent tissue, and, enveloped in connective tissue, sink to a deeper position.

First of these to be mentioned are the **parathyreoid bodies**, which apparently are the equivalents of the epithelial bodies. These arise from the ventral side of the gill pouches, except in the mammals where there are more dorsal in position (fig. 285, *e*). Of their functions little is known except that their extirpation or disease causes

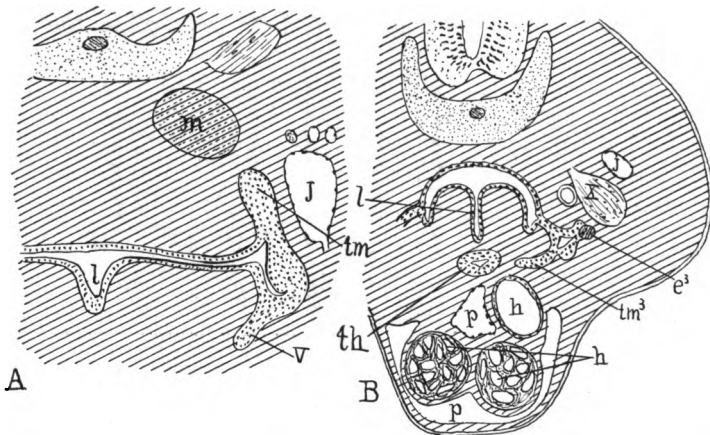


FIG. 285.—Sections (*A*) of lizard and (*B*) of monotreme embryos, after Maurer. *e*, third parathyreoid anlage; *h*, parts of heart; *j*, jugular vein; *l*, larynx; *m*, muscle; *p*, pericardial cavity; *th*, thyreoid anlage; *tm*, thymus anlage; *v*, ventral diverticulum which forms thymus in mammals; *X*, tenth nerve.

effects recalling eclampsia. They are closely related in position to either the thymus or the thyreoids, even coming in mammals (fig. 284, *C*), to be enveloped in the thymus gland.

In the cyclostomes cells arise at both the dorsal and ventral sides of the gill pouches which may be the homologues of the parathyreoids. None are known in fishes. In the amphibia the cells are budded from two or three clefts (fig. 283, *B*); in the amniotes there are usually two contributing clefts (fig. 283, *C*), though in some there is but one.

Even less is known of the **postbranchial** or **ultimobranchial bodies**. These arise from the last gill pocket and come to lie above the anterior end of the pericardium.

The **carotid glands**, occurring in amphibia and amniotes, arise at the forking of the common carotid artery into its external and internal branches. Accord-

ing to some authors the second gill pouch in reptiles, the third in amphibia, contributes to them, but this is denied by others. In the birds and mammals they are described as products of the vascular walls, with no epithelial contributions. Of their function in the amniotes nothing is known. In the adult amphibia they lose their plexiform character and form a muscular thickening which projects into the vessel, and it has been suggested that this serves as an accessory heart.

The **thyreoid** is a ductless gland in the pharyngeal region of all vertebrates, ventral to the alimentary tract. In the lower vertebrates it arises as an unpaired pocket in the floor of the pharynx in the region of the second to fourth gill clefts (fig. 283), and in the larval (*Ammocœetes*) lamprey this retains its connexion with the

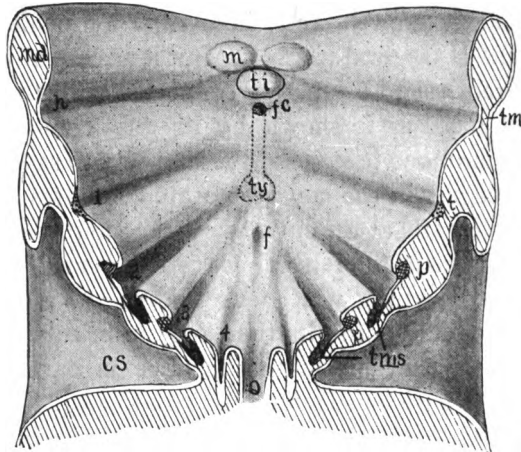


FIG. 286.—Diagram of the floor of the mouth of an embryo mammal showing the early stages of the tongue and pharyngeal derivatives. *cs*, cervical sinus; *fc* foramen cæcum; *h*, hyoid cleft; *m*, mandibular part of tongue; *md*, mandibular arch; *o*, cesophagus; *p*, anlage of parathyreoid; *t*, anlage of tonsil; *ti*, tuberculum impar; *tm*, tympanic membrane; *tms*, anlage of thymus; *ty*, thyreoid anlage; 1-4, branchial clefts.

pharynx (fig. 211) until metamorphosis when it loses its duct and eventually becomes a complex of follicles. In other vertebrates it arises as a pocket between the first and second clefts and lies primitively just in front of the pericardium. It takes the form of a vesicle which sends out solid cords which later become follicular.

Usually the thyreoid is markedly bilateral, and in amphibia and birds (fig. 284) it divides into two glands. In the elasmobranchs it lies between the anterior end of the ventral aorta and the symphysis of the lower jaw. In teleosts the paired groups of follicles lie around the ventral aorta, extending laterally along the anterior aortic arches. The gland lies just behind the second arch in urodeles, and in anura

it is on the hinder margin of the thyreoid process of the hyoid plate. In reptiles it is ventral to the trachea (at about its middle in lizards—fig. 284, *A*—nearer its division in other groups), while in birds (fig. 284, *B*) the two glands occur at the base of the bronchi. In mammals it is usually near the larynx, and, while it is usually two-lobed (fig. 284, *c*, *C*), in some cases (monotremes, some marsupials, lemurs, etc.) it is paired. The remains of the place of its involution can often be distinguished through life as a pit, the **foramen cæcum** (fig. 286, *fc*) at the base of the tongue.

Like the other ductless glands the thyreoid supplies the blood with substances necessary to the well-being of the organism—in the case of the mammals at least, an albumen containing iodine. In the young it stimulates growth, and the extirpation or degeneration of the gland results in cerebral trouble. In the ancestral vertebrate the thyreoid apparently had a function connected with the collection or metabolism of food, as is shown by its late connexion with the pharynx in the ammocoete stage of the lamprey, to say nothing of the probable homologues in the non-vertebrate chordates.

In the pharynx and at the entrance of the mouth into the pharyngeal cavity (**isthmus of the fauces**) are certain lymphoidal structures called **tonsils**, concerning which our knowledge is very deficient. According to the older accounts they arise from subepithelial mesoderm; more lately they are stated to arise in part from the oral epithelium. The true tonsils (**tonsillæ palatinæ**), at the isthmus of the fauces arise as thickenings of the epithelium of the first gill cleft (fig. 286, *t*). They consist of an adenoid ground substance and become follicular after birth and contain numerous lymph cells. Less is known of the **lingual tonsils** at the base of the tongue.

Both lingual and palatine tonsils occur only in the mammals. Besides these there are **pharyngeal tonsils**, inconstant in mammals, but well developed in reptiles and birds, where they lie behind the choanæ. They may be the same as certain lymphoid structures occurring in the pharyngeal roof of amphibians.

THE SWIM BLADDER

While the air or swim bladder of fishes (**pneumatocyst**) is not a respiratory organ, it is included here from its possible relations to the lungs. It occurs only in teleostomes, and while found in most species (frequently absent from bottom-feeding forms—pleuronectids, etc.), is it lacking here and there, even among species classed as physostomous (*Loricaria*, etc.). In the young of a few sharks (*e.g.*, *Scyllium*)

there is a pouch on the dorsal side of the œsophagus which suggests the possible origin of the organ.

The swim bladder lies dorsal to the alimentary tract, outside of the peritoneum (which frequently covers only its ventral surface), immediately below the vertebræ and excretory organs (mesonephroi). In some instances it extends the whole length of the body cavity and (clupeids) may even send diverticula into the head. In other species

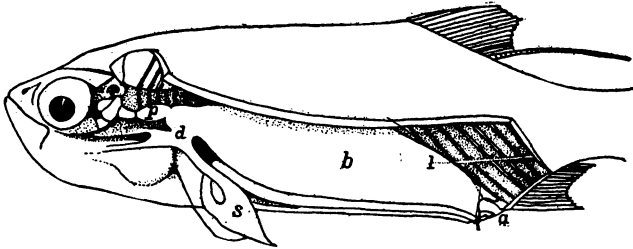


FIG. 287.—Air bladder of *Megalops cyprinoides*, after de Beaufort. *a*, anus; *b* air bladder; *d*, pneumatic duct leading from the œsophagus; *l*, ligament; *p*, anterior part of bladder extending to skull; *s*, stomach.

it may be much shorter. In development it arises as a diverticulum of the alimentary canal (fig. 233), and in the ganoids and one group of teleosts (physostomi) it is connected with the digestive tract throughout life by the pneumatic duct (fig. 288). This usually empties into the œsophagus, but it may connect with the stomach. In most teleosts, however, the duct becomes closed at an early date and the bladder loses its connexion with the digestive tract (physoclisti).

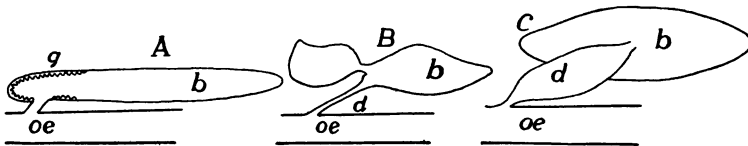


FIG. 288.—Swim bladders of physostomous fishes; *A*, pickerel (*Esox*); *B*, carp (*Cyprinus*); and *C*, eel (*Anguilla*) after Tracy. *b*, swim bladder; *d*, duct; *g*, red gland; *oe*, œsophagus.

The swim bladder is usually unpaired (paired in most ganoids) and may be simple or divided into two (rarely three) connecting sacs (fig. 288). It is usually regular in outline, but diverticula of all kinds are common, the form being most varied in the physoclistous species. Internally the walls may be smooth and the cavity simple, or it may be subdivided by septa (fig. 289), or, as in *Amia* and *Lepidosteus* (fig. 290, *B*), it may be alveolar, recalling the condition in the lungs

of higher vertebrates. The walls sometimes contain striated muscle, and in some siluroids and cyprinoids they are more or less calcified, partly by the inclusion of processes from the vertebræ.

The blood supply is arterial, coming from either the aorta or the cœliac axis, in some instances different portions receiving blood from both. In the walls the arteries break up into networks of minute vessels ('rete mirabile'), these frequently making 'red spots' variously distributed on the inner surface. From the retia the blood

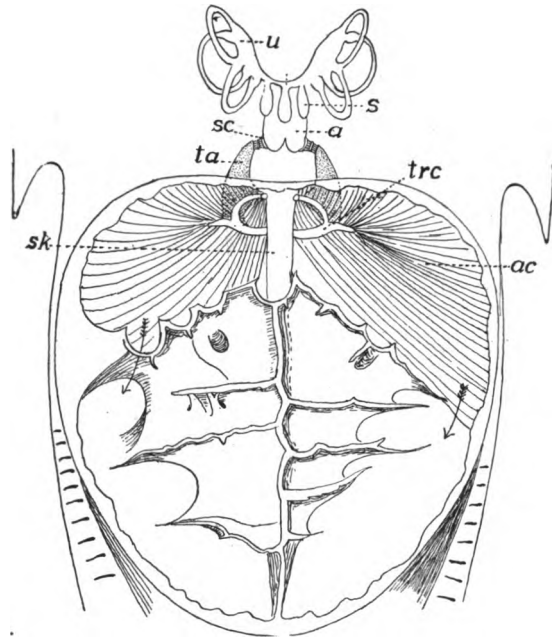


FIG. 289.—Ventral view of opened air bladder and Weberian apparatus of *Macrones*, combined from Bridge and Haddon. *a*, atrial cavity; *ac*, anterior chamber of air bladder the arrows showing the connexion with the posterior chamber; *s*, sacculus; *sc*, scaphium; *sk*, subvertebral keel; *ta*, *trc*, anterior and crescentic processes of tripus; *u*, utriculus.

passes to the body veins (postcardinal, hepatic or vertebral). In the ganoids and phystomous species, especially those with a wide pneumatic duct, the gases contained in the swim bladder may be obtained directly from the air or water, but in the physoclists this is impossible and the red spots may be the place of its secretion, the probability being increased by the greater abundance of the spots in species with closed ducts.

The gases in the air bladder consist of oxygen, nitrogen and carbon dioxide, the oxygen usually being in greater relative amount than in the air. It is most abundant in fishes from deep water, rising in some cases to over 90 per cent. of

the gases in the bladder. (This is possibly to be explained by the rapid dissociation of the oxyhæmoglobin of the blood on account of a reduction of pressure resulting from a quick transfer from deep water to the surface.) In the physostomous fishes the gases escape through the mouth. In the physoclists there is usually a thinner region—the so-called *oval*—in the dorsal wall of the air bladder where the gases may be absorbed, passing into the adjacent blood-vessels.

While the pneumatic duct usually connects with the dorsal side of the alimentary canal (fig. 290, *A*), it enters the left side in *Erythrinus* (*C*), and in the mid-ventral line in *Polypterus* and *Calamoichthys*. In *Polypterus* there are paired swim bladders, the right being the longer. The blood in this genus comes from the efferent branchial arteries and consequently is arterial.

The swim bladder is supposed to have hydrostatic functions, aiding in the recognition of differences of pressure due to changes in depth. In the clupeids the air bladder sends a diverticulum into the head, there giving a branch to each ear. In some physostomes (siluroids, cyprinids, gymnonoti) parts of the anterior vertebræ are modified into a chain of bones—the **Weberian apparatus**—adapted to convey differences of bladder pressure to the internal ears. One pair of bones is connected with the dorsal wall of the air bladder, a second with a diverticulum (*sinus impar*) of the internal ear, while others are intercalated between these two (fig. 289). Changes in the distention of the bladder are thus conveyed to the inner ear and probably affect the sense organs.

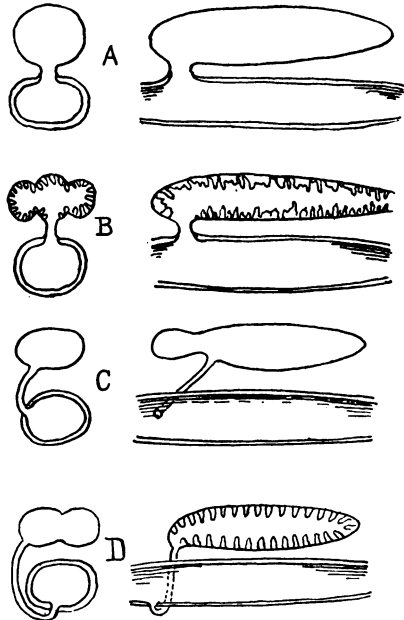


FIG. 290.—Diagrams of air bladder in fishes, after Dean. *A*, Physostomous fishes; *B*, *Lepidosteus* and *Amia*; *C*, *Erythrinus*; *D*, *Ceratodus*.

LUNGS AND AIR DUCTS

Lungs arise in all tetrapoda and in a few fishes (dipnoi) as a diverticulum from the ventral side of the pharynx, immediately behind the last gill pouch. The diverticulum divides almost as soon as outlined into right and left halves, each the anlage of the corresponding

lung (fig. 282). As development proceeds, the two grow in a caudal direction into the trunk, carrying the peritoneum with them as they protrude into the cœlom, so that they eventually have an entodermal lining, derived from the epithelium of the pharynx; an outer serous layer of peritoneum, with mesenchyme carrying blood- and lymph-vessels, nerve and smooth-muscle fibres between the two. In this development two parts are differentiated, the lungs, the actual seat of the exchange of gases, and the air ducts leading from the pharynx to them. The ducts may consist of an anterior unpaired portion, the **wind-pipe** or **trachea**, connecting with the pharynx, and usually dividing at its lower or posterior end into two tubes, the **bronchi**, leading to the two lungs. In most air-breathing vertebrates the anterior part of the trachea is specialized and forms a larynx. In addition to these parts, the mechanism by which air is drawn into and expelled from the lungs forms a part of the respiratory apparatus.

THE AIR DUCTS

The opening from the pharynx into the air ducts is known as the **glottis**, usually an elongate slit capable of being closed and opened by appropriate muscles. This is immediately succeeded by the ducts, which, except in the dipnoi, are more or less differentiated into regions and have skeletal supports in their walls.

In the dipnoi the glottis is either in the mid-ventral line (*Protopterus*) or a little to one side (*Lepidosiren*, *Ceratodus*) and the air duct passes up on the right side of the œsophagus to reach the lungs which are dorsal to the alimentary canal (fig. 290). The tube is without skeletal supports and connects directly with both lungs without any division into bronchi.

Larynx.—The beginnings of the larynx are seen in the amphibia, where in the lower types (*Necturus*) a pair of cartilages are developed on the sides of the glottis, in the position of a reduced visceral arch, each cartilage extending posteriorly a short distance along the air ducts. In other genera of urodeles the anterior end of each lateral cartilage separates from the rest as an **arytenoid**, the first of the laryngeal cartilages, imbedded in the walls of the glottis. The rest of the lateral cartilages may remain entire (fig. 291), or they may separate into a number of pieces, extending along the lateral walls of the trachea and bronchi. Usually the anterior pair of these pieces fuse in the mid-ventral line, thus forming the second (**cricoid**) element of the pharyngeal framework. These parts are removed by antagonistic muscles. One set of these, extending to the persistent

branchial arches, serves as dilators of the glottis; the others, connected with the laryngeal cartilages themselves, constrict the opening. In the anura the cricoid is converted into a ring, with the arytenoid hinged within and anterior to it, the whole larynx moving anteriorly to a position between the hinder processes of the hyoid plate (fig. 292). Inside of the short larynx thus framed by these cartilages are a pair of folds of the laryngeal lining, the **vocal cords**, extending parallel to the margins of the glottis. These may be tightened or relaxed, and by their vibration of their edges under influence of the breath the voice is produced.

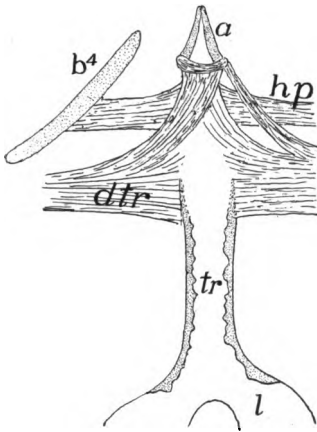


FIG. 291.—Trachea, etc., of *Amphiuma*, after Wilder. *a*, arytenoid cartilages; *b*⁴, fourth branchial arch; *dtr*, dilatator tracheæ muscle; *hp*, hyopharyngeus muscle; *l*, lung; *tr*, trachea with cartilages in its walls.

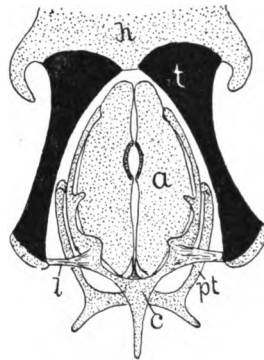


FIG. 292.—Laryngeal cartilages of frog, after Gaupp. *a*, arytenoid; *c*, cricoid; *h*, posterior part of body of hyoid; *l*, hyo-cricoid ligament; *pt*, tracheal process of cricoid; *t*, thyreoid; process of hyoid. Cartilages dotted one black.

The larynx is scarcely more developed in reptiles. The cricoid is usually an incomplete ring, to which the arytenoids are attached, and the whole is placed just ventral to the median part of the hyoid, with which it is closely associated (fig. 293). In several reptiles a fold of the mucous membrane just in front of the glottis is supposed to represent the beginnings of an epiglottis (*infra*), while in geckos and chameleons a pair of folds, running dorso-ventrally in the larynx, serve as vocal cords. The larynx is also rudimentary in the birds, its place as a vocal organ being taken by the syrinx to be described below, in connexion with the trachea. The arytenoids are frequently ossified in birds.

In the mammals the larynx reaches its highest development. Its framework is formed by the arytenoid and cricoid cartilages, homologous with those of the lower groups, and in addition, a **thyreoid cartilage** (or cartilages) on the dorsal side, anterior to the arytenoids

and cricoids. The origin of the thyreoid is best seen in the monotremes where the hyoid apparatus enters into close relations with the larynx (fig. 294), while the second and third branchial cartilages

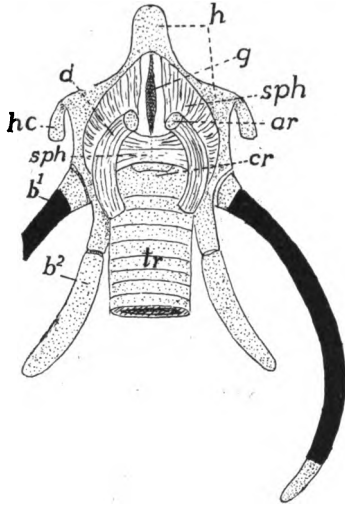


FIG. 293.

FIG. 293.—Laryngeal apparatus of *Chelone*, after Göppert. *ar*, arytenoid; *b*¹⁻², first and second branchial arches; *cr*, cricoid; *d*, dilator laryngis muscle; *g*, glottis; *h*, hyoid; *hc*, hyoid cornua; *sph*, sphincter laryngis; *tr*, trachea; cartilage dotted, bone black.

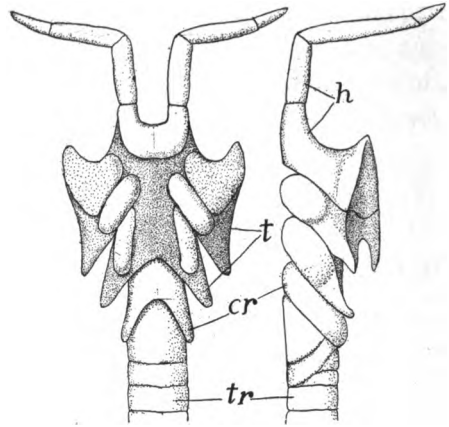


FIG. 294.

FIG. 294.—Ventral and side views of monotreme larynx, after Gegenbaur. *c*, cricoid; *h*, hyoid; *t*, thyreoid; *tr*, trachea.

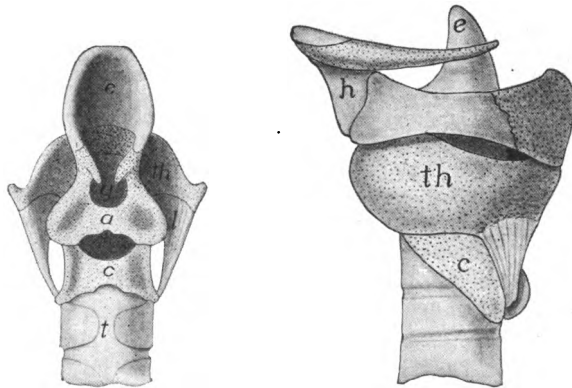


FIG. 295.—Dorsal and side views of larynx of opossum, *Didelphys virginianus* (Princeton, 1739), cartilages dotted. *a*, arytenoid; *c*, cricoid; *e*, epiglottis; *g*, glottis; *h*, hyoid; *t*, trachea; *th*, thyreoid.

form two plates, the lateral elements of the thyreoid on either side, the median element of the hyoid forming a copula. In the higher mammals the association of hyoid and larynx is not so intimate,

even in the embryo, but the thyreoid shows its double origin in its development.

In the higher mammals the thyreoid cartilage forms a half ring on the ventral side of the anterior end of the larynx, its anterior dorsal angles being produced into cornua connected by ligament with the hyoid (fig. 295). Dorsal to the thyreoid is the glottis with the arytenoids in its walls. Posterior to it is the ring-shaped cricoid, following which is the trachea. Anterior to the glottis is a fold of the mucous membrane of the pharynx, the epiglottis, supported by an internal cartilage (possibly the fourth branchial arch) which articulates with the anterior margin of the thyreoid. The epiglottis usually stands erect, leaving the glottis open for respiration, but during deglutition it is pulled back into the glottis, thus preventing the entrance of food into the trachea.

Internally the cavity of the larynx bears a **vocal cord** on either side. These are folds of the mucous membrane, extending from the thyreoid to the arytenoids, and by movements of these latter cartilages they can be tightened or relaxed, thus altering the pitch of the note caused by their vibration. Anterior to these cords is a pocket, the **laryngeal ventricle (sinus of Morgagni)** on either side, small in most mammals, but developed in the anthropoid apes to large vocal sacs (in the chimpanzee there is a median vocal sac in addition), which act as resonators, adding to the strength of the voice.

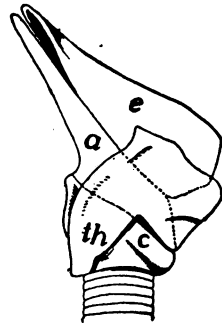


FIG. 296.—Larynx of *Xiphius cavirostris* (after Gegenbaur) from side showing the prolongation of epiglottis (*e*) and arytenoid (*a*) which project into the choana; *c*, cricoid; *th*, thyreoid.

In the whales and young marsupials the larynx is prolonged so that it projects into the choana behind the soft palate. In the whales (fig. 296) this is an adaptation to the manner of taking food from the water and breathing at the same time. In the young marsupials the milk is forced into the mouth by the muscles of the mammæ of the mother and this arrangement prevents strangulation.

Trachea.—In the tetrapoda the trachea is strengthened by the formation of cartilage in its walls, the beginnings of which are seen in the urodeles where the fifth branchial arch gives rise to these elements (p. 270). Their arrangement varies considerably in the urodeles and cæcilians, being sometimes scattered pieces, sometimes regularly arranged and even united in the lateral walls (fig. 291),

Corresponding to the posterior position of the lungs the trachea is long in these groups, but in the anura it can scarcely be said to exist, the lungs succeeding almost immediately to the larynx.

In the reptiles the trachea varies in length, being shortest in lizards (except amphisbænas), longer in snakes, tortoises and crocodiles, dividing into bronchi at varying distances from the lungs. It is frequently convoluted in turtles. In many reptiles the cartilage rings of the trachea are incomplete, but in *Sphenodon* (fig. 301), lizards and some snakes some cartilages (usually the more anterior) form complete rings, the others being completed dorsally by membrane. In snakes the successive rings are often united, especially on the sides.

The trachea is greatly elongate in birds in correlation with the length of the neck and the position of the lungs within the thorax. The rings, which are usually complete, are frequently ossified. The trachea is occasionally (male ducks, etc.) widened in the middle and in various groups becomes greatly convoluted so that its length from the glottis to the lungs exceeds that of the neck. In some these convolutions occur beneath the integument of the thorax; in some between the sternum and the muscles; and in the cranes and swans within the keel of the sternum.

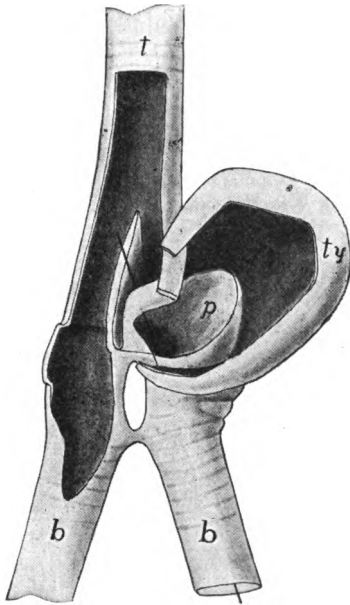


FIG. 297.—Syrinx of canvas-back duck, *Aythya*, laid open (Princeton 915). *b*, bronchi; *p*, pessulus; *t*, trachea; *ty*, tympaanum.

The larynx is never the organ of voice in the birds, its place being taken by a somewhat similar structure, the **syrinx**, at the division of the trachea into the bronchi. The sound-producing elements are membranes which vibrate by the passage of air, as do the vocal cords of mammals. Most common is the **broncho-tracheal syrinx**, in which the last rings of the trachea are united to form a resonating chamber, the **tympaanum**, while folds of membrane, internal and external **tympanic membranes** (not to be confused with the similarly named structure in the ear, p. 202), extend into the cavity from the median and lateral wall of each bronchus. In some cases there is also an

internal skeletal element (**pessulus**) which bears a semilunar membrane on its lower surface. In many birds this type of **syrix** is often asymmetrical (fig. 297) and is expanded into a (usually) bony resonating vesicle. In the **tracheal** type of **syrix** the lateral portions of the last tracheal rings disappear and the membrane which closes the gap forms the vibratile part. In the bronchial **syrix** the membranes occur between two successive rings of each bronchus, each ring being concave toward its fellow. By a shortening of the bronchial wall these membranes are forced as folds into the tube. In all types of **syrix** there are muscles attached to trachea and bronchi, which, by moving these parts, alter the tension of the folds, thus changing the note.

In the mammals the trachea is elongate (shortest in the whales and sirenians, dividing in the latter immediately behind the cricoid into the two bronchi), and the cartilage rings are usually incomplete dorsally, the gaps being closed by membrane. This structure allows the tube to remain open under ordinary conditions and yet allows it to give when food is passing down the oesophagus, just dorsal to it. In the cetacea and sirenia the tracheal cartilages are sometimes spirally arranged.

LUNGS

The morphology of the lungs may be understood by following their development in the mammals and then describing their modifications in the various classes of vertebrates. As stated above the lungs arise as a diverticulum (fig. 298, *A*) on the ventral side of the pharynx which quickly divides into two sacs, the anlagen of the two lungs. These are gradually pushed posteriorly toward the body cavity, still retaining their connexion with the pharynx by the air duct, and each consisting of an enlarged terminal vesicle connected by a slender portion (the beginning of the primary bronchus) with the undivided tracheal portion. With continued growth each terminal vesicle divides again and again, the result being a number of rounded vesicles connected with the primary bronchi by slender tubes, the secondary bronchi (fig. 298, *B*). By a continuation of this process tertiary and other bronchi are outlined, and also slender tubes, the bronchioles, to be described later, which connect the terminal vesicles with the ultimate bronchi. Next, the inner wall of each vesicle becomes divided into small chambers, the **alveoli**, the whole

vesicle now being known as an **infundibulum** (fig. 299). The result of these many divisions is an enormous amount of internal respiratory surface without great increase in the size of the whole organ. It is to be noticed that in this subdivision the entodermal lining takes the initiative, the outer (serous) surface showing but slight signs of the internal modifications.

Each infundibulum has its own duct which, when smooth internally, is called a **bronchiole**, when lined with alveoli, an **alveolar duct**. The alveoli of infundibulum and duct are lined with squamous epithelium, and in the walls is an extensive network of capillary blood-vessels. The lining cells of the bronchioles are cubical and

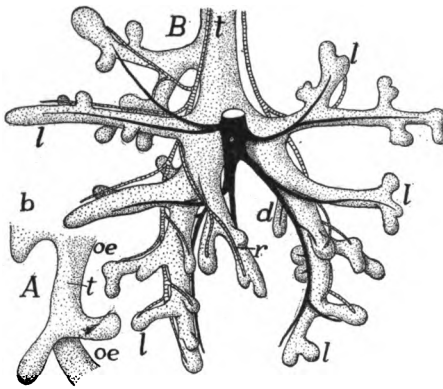


FIG. 298.

FIG. 298.—Two stages in the development of the lung of the pig, ventral views, after Flint. *A*, pig 5 mm. long; *B*, 18.5 mm. long. *b*, gill pouch; *d*, *l*, *v*, dorsal, lateral and ventral bronchi; *oe*, oesophagus; *t*, trachea.

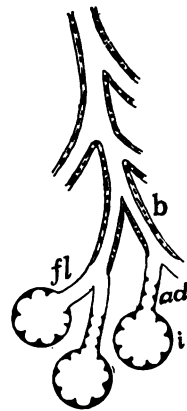


FIG. 299

FIG. 299.—Scheme of mammalian lung structure. *ad*, alveolar duct; *b*, bronchus; *fl*, bronchiole; *i*, infundibulum lined with alveoli.

those of the bronchi ciliated columnar. There are no skeletal elements in the bronchioles, but the bronchi have small cartilages in the walls, these exhibiting a tendency in the larger tubes to approximate the rings or semi-rings of the trachea.

In their backward growth into the coelomic region the lungs either insinuate themselves dorsal to the lining of the dorsal side of the body cavity (dipnoi and a few scattered forms) so that only their ventral surface has a serous coat; or they grow out as free structures, covered on all sides by the coelomic epithelium, and are bound to the dorsal wall by a mesenterial-like fold of varying extent. This outer coat of epithelium has received the name of pleura, the term being extended in the case of the mammals to include the whole lining of the

pleural cavity, separated from the rest of the cœlom by the diaphragm (p. 140).

DIPNOI.—In *Ceratodus* (fig. 290, *D*) there is a single lung sac; *Protopterus* and *Lepodosiren* have paired lungs, the two being united in front at the entrance of the air duct. In all three the inner surface is divided more or less regularly into groups of alveoli, separated by more prominent partitions. The pulmonary arteries arise from the last efferent branchial artery of either side, and hence the blood supply, under normal conditions, is arterial and the lungs cannot act as respiratory organs. In times of drought (*Protopterus*) or of foul water (*Ceratodus*) the gills no longer function and the pulmonary arteries bring venous blood to the lungs.

AMPHIBIA.—In the lower urodeles the two lungs are elongate (the left the longer) and are united at their bases, true bronchi being absent.

Internally they may be entirely smooth as in *Necturus*, or there may be alveoli in the basal portion (fig. 300), the whole representing a terminal vesicle either connected directly with the trachea (*A*) or by the intervention of an alveolar duct (*B*). In the cæcilians the left lung is very short, the other elongate, with alveoli developed throughout. In the frogs (fig. 300, *C*) the two lungs are distinct, and their walls are divided into a series of sacs or infundibula lined with alveoli. The infundibula open into

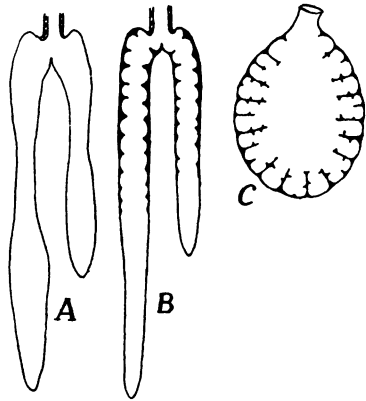


FIG. 300.—Different types of amphibian lungs. *A*, *Necturus*, without alveoli; *B*, alveoli in the proximal portion; *C*, frog, alveoli throughout.

a central chamber, which, since it is ciliated and has numerous glands in its walls, may be compared to a bronchiole. In the toads and aglossa the alveoli are more extensively developed in correlation with the more terrestrial habits

It has recently been shown that a number of terrestrial urodeles are lungless in all stages of development, and that no traces of larynx or trachea occur, even after the gills are absorbed. In these species there is a great development of capillaries in the skin and in the walls of the mouth and pharynx, the respiratory functions being transferred to these parts. In the frogs the skin is also respiratory and it is largely supplied by the cutaneous arteries which arise from the same arch as the pulmonary arteries.

In the amphibia the air ducts enter the anterior end of the lungs, but in the amniotes the lungs extend anteriorly to the entrance of the

bronchi which is on the medial side (fig. 302, *B*). This change is in part the result of the transfer of the heart into the thorax, the position of the pulmonary arteries forcing the bronchi toward the centre of the lungs. In the amniotes, also, the ducts are characterized by the presence of cartilage in their walls, so that they are true bronchi. These bronchi may also extend inside of the lungs, often dividing into secondary and tertiary bronchi inside them.

REPTILES.—In many reptiles (snakes, amphisbænans, many skinks) the lungs are asymmetrical (left usually larger in snakes, right in lizards) and exceptionally one may be absent in snakes. The

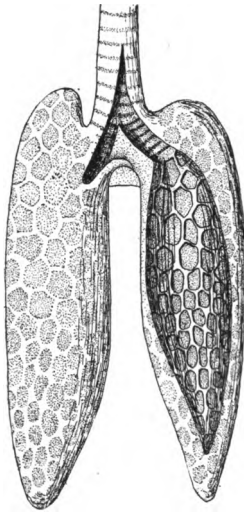


FIG. 301.

FIG. 301.—Lungs of *Sphenodon*, after Gegenbaur; the left lung opened to show the alveoli.

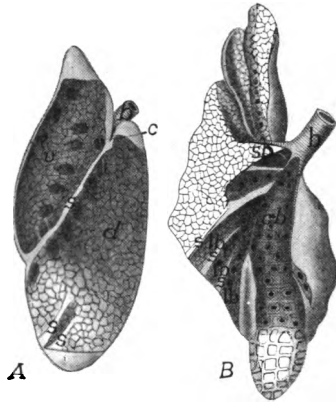


FIG. 302.

FIG. 302.—*A*, left lung of *Iguana*; *B*, right lung of *Varanus*, after Meckel. *b*, bronchus; *c*, connexion between dorsal and ventral chambers; *cb*, main bronchus; *d*, dorsal chamber; *lb*, lateral bronchi; *s*, septa; *sb*, secondary bronchus; *v*, ventral chamber.

internal structure shows considerable variation. The simplest conditions are found in the snakes and in *Sphenodon* (fig. 301), where the lungs consist of a single sac lined with infundibula in the basal portion (snakes) or throughout (*Sphenodon*). In the lizards (fig. 302) one or more vertical partitions or septa extend from the distal wall of the lung nearly to the entrance of the bronchus, thus dividing the lung into chambers lined with alveoli; while a part of the bronchus may extend (main bronchus, fig. 302, *B*) to the extremity of the lung. In the chameleons the septa do not reach the distal wall so that the chambers communicate here as well as at the proximal side, the result

being that the bronchus enters a cavity, the atrium, which connects with the chambers separated by the septa, and these in turn open into a terminal vesicle, a condition recalling the parabronchi of the birds, soon to be described. This resemblance is heightened by the development in these same lizards of long, thin-walled sacs from the posterior part of the lung which extend among the viscera, even into the pelvic region. These air sacs, which are used to inflate the body, foreshadow the similarly named structures in the birds. In the higher lizards (*Varanus*, fig. 302) and in the turtles and crocodiles there

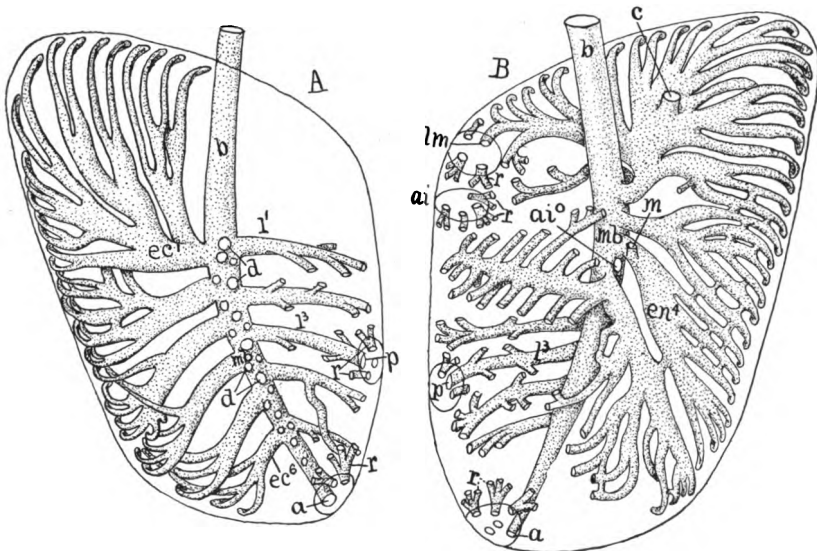


FIG. 303.—Diagrams of (A) dorsal and (B) ventral aspects of lung of hen, after Locy and Larsell. *a*, point of connexion of mesobronchus with abdominal air sac; *ai*, region of recurrent bronchi from anterior intermediate sac; *ai'*, connexion of anterior intermediate sac with bronchus; *b*, bronchus; *c*, attachment of cervical sac; *d*, roots of dorsibronchi; *ec*, ectobronchi; *en*, entobronchi; *l*, laterobronchi; *lm*, *m*, connexions of lateral and mesial moieties of interclavicular sac; *p*, connexion of posterior intermediate sac; *r*, retrobronchi from air sacs.

is no atrium, the bronchus, on entering the lung, breaking up into several tubes. As these connect with smaller tubes which lead to the infundibula, the whole lung has a spongy texture. Also, in the turtles the partitions are not vertical, but extend from medial to lateral side, and correlated with this, the entrance of the bronchus is on the ventral side of the lung, not as in lizards (fig. 302) on the medial side.

BIRDS.—The lungs in the birds are closely connected with the ribs and vertebral column and hence undergo less considerable changes

of shape than do the lungs in other groups. Their structure is peculiar. Each bronchus enters the medioventral side of the correspond-

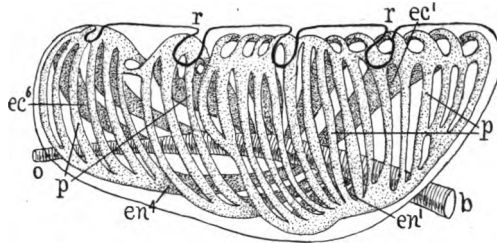


FIG. 304.—Diagrammatic side view of bird lung, showing the parabronchi connecting ecto- and entobronchi, after Locy and Larsell. *b*, bronchus; *ec*, ectobronchi; *en*, entobronchi; *o*, abdominal orifice, point of connexion with abdominal air sac; *p*, parabronchi; *r*, impressions of ribs.

ing lung and immediately enlarges into a vestibule or atrium (not shown in fig. 303), beyond which it continues as a main trunk, the **mesobronchus**, to the distal end of the lung. From this mesobronchus secondary bronchi arise, these being called **entobronchi**, **ectobronchi**, **laterobronchi** and **dorsibronchi**, according to their position. These secondary bronchi divide and give off

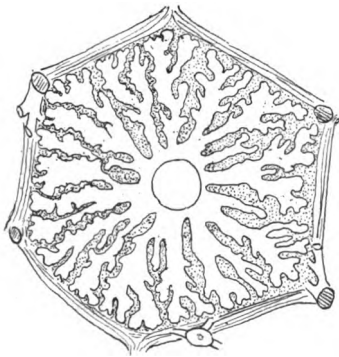


FIG. 305.

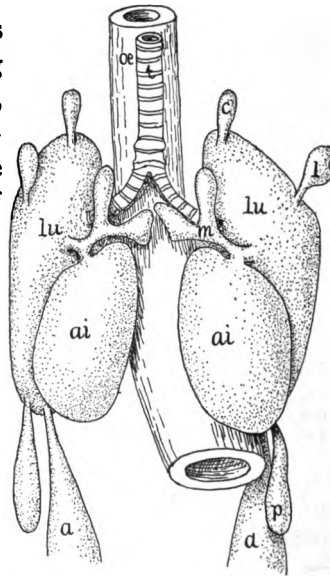


FIG. 306.

FIG. 305.—Section of lung pipe with radiating infundibula, after Schulze.

FIG. 306.—Ventral view of lungs and air sacs of twelve-day chick embryo, after Locy and Larsell. *ai*, anterior intermediate sac; *a*, abdominal sac; *c*, cervical sac; *l*, lateral moiety of interclavicular sac; *lu*, lung; *m*, mesial moiety of interclavicular sac; *oe*, oesophagus; *p*, posterior sac; *t*, trachea.

small tubes of uniform diameter—the air pipes or **parabronchi** (fig. 304)—which connect at the other end with others of the secondary

bronchi. The result of this is that there is no 'bronchial tree' like that of mammals, but a series of anastomosing tubules forming circuits within the lungs. No tubes end blindly. Each parabronchus bears numbers of elongate diverticula, radially arranged, with a narrower

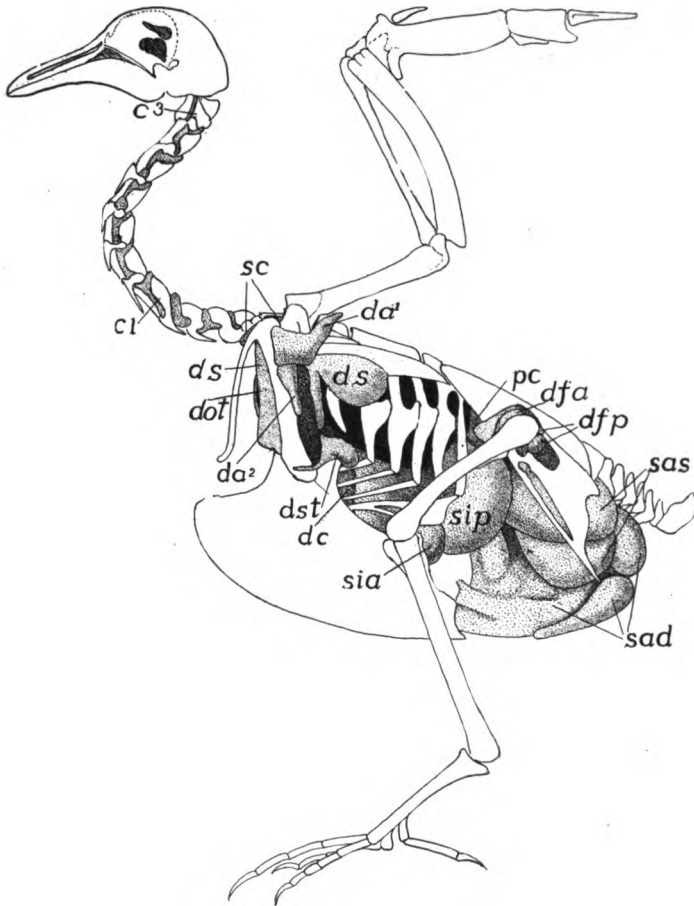


FIG. 307.—Air sacs and canals of pigeon, after Bruno Müller. c^{1-3} , intertransverse canals; da^{1-2} , axillary sac and its ventral diverticulum; dc , canal for ribs; dot , infraclavicular canal; ds , subscapular sac; dst , sternal canal; pc , preacetabular canals; sad , sas , right and left abdominal sacs; sc , cervical sac; sia , sip , anterior and posterior intermediate sacs.

basal portion and a larger, lobulated, and frequently branched distal part (fig. 305). Apparently the parabronchi are to be compared with the bronchioles, the diverticula with the infundibula of other vertebrates.

Another feature in the birds is the presence of air sacs. The

mesobronchus and usually four of the secondary bronchi do not stop at the lung wall, but are continued as thin-walled sacs which occur in all living species of birds. Each of these sacs has received several names; for details of these reference should be had to special works. The **interclavicular sac** lies anterior to the furcula. It arises from two parts on either side of the body (fig. 306), but these usually unite so that the result is an unpaired structure. The **cervical sac** of either side lies at the base of the neck and gives off a branch which extends to an **axillary sac** in the region of the axilla. The other sacs lie in the trunk, lateral to the viscera, and are called the **anterior intermediate, posterior intermediate, and abdominal**, the relations of which are shown in figures 306 and 307. These sacs receive their air from the ends or from branches of the bronchi. Recently it has been found that the air does not return by the same passages, but that there are **recurrent bronchi** leading from the air sacs back to the lungs (fig. 303). From the air sacs slender tubes extend among the viscera and into certain of the bones. The pelvis, humerus, sternum, coracoid, and ribs most frequently contain prolongations of the air sacs—are **pneumatic**—less frequently the femur, furcula and scapula.

Usually there are eight entobronchi (fig. 303), these arising from the medial side of the mesobronchus, but bending to the ventral side of the lung. The ectobronchi vary in number from six to ten. They arise on the dorso-medial side of the mesobronchus and pass to the dorsal side of the lung. The laterobronchi are comparatively few. They supply the lateral part of the lung. The dorsibronchi are smaller and more numerous than the others, some arising from the ectobronchus and some from the mesobronchus. In the chick there are about twenty-five of these.

The cervical air sac is connected with the second entobronchus (fig. 303). The duct leading to the anterior intermediate sac arises from the middle part of the mesobronchus, that for the posterior intermediate from one of the laterobronchi, while the abdominal sac is a direct continuation of the mesobronchus. Of the recent reptiles only the chameleons have anything like air sacs. The bones of the fossil bird *Archaeopteryx* were not pneumatic, but those of some of the extinct dinosaurian reptiles were.

There is considerable uncertainty as to the functions of the air sacs. The fact that the walls are supplied with arterial blood, together with the absence of any respiratory capillary network, negatives the idea that they are to any great extent respiratory. It has been suggested that they are concerned with the maintenance of equilibrium during flight and that they also lessen the specific gravity

of the body; that they play a part in the reduction of the bodily temperature in correlation with the absence of sweat glands, and that, where they extend between muscles, they reduce the friction. More plausible is the view that, by the motion of the parts by which they are surrounded, they aid in the inspiration and expiration of the air, especially during flight, thus allowing the thoracic framework to remain rigid as an attachment of the muscles, and at the same time permitting the air to pass twice over the respiratory surfaces of the lungs.

MAMMALS.—The general structure of the mammalian lung is outlined above (p. 275). Each lung is entirely enclosed by the pleural membrane, and the pleural cavity in which it lies is entirely cut off from the rest of the coelom by the diaphragm, which is usually transverse to the main axis of the body, but is oblique in the whales. The external shape of the lung is largely due to the position in the pleural cavity, where it has to fit on either side of the pericardium, while the presence of the diaphragm causes the posterior surface to be truncate. In some mammals the lungs are simple and without division into lobules (whales, elephant, odd-toed ungulates, *Hyrax*) and in the monotremes only the right is divided. Elsewhere both lungs are lobed, but the lobes (varying in number from two to six) are more numerous on the right side.

Internally there is a main bronchus from which dorsal and ventral secondary bronchi arise, the latter dividing in a dichotomous manner. In most mammals the bronchi are strengthened by cartilages which form rings in the larger, scattered pieces in the smaller trunks. Frequently one or both anterior (apical) bronchi lie in front of or above the pulmonary artery and these are called **eparterial** bronchi, the others being **hyparterial**, but the distinction is of little morphological importance.

In one of the whales (*Pontoporia*) the eparterial bronchus of one side leaves the main trunk close to the larynx and outside the lung, so that here there are apparently three main bronchi. It is estimated that there are over 400,000,000 alveoli in the human lung.

The phylogenetic history of the lungs is uncertain, one view being that they have developed from the air bladder of fishes, the other is that they are modified gill pouches, which, instead of growing laterally and opening to the exterior, have extended caudally and have encroached upon the coelom. Favoring the first of these views are the double condition of the bladder in some ganoids, and especially in

Polypterus, which is looked upon as representing the ancestors of the tetrapoda. Here the walls of the bladder have alveolar walls like the lungs of higher vertebrates, while the pneumatic duct and the blood supply are like the corresponding structures in the tetrapoda. On the other hand, the dorsal position of the pneumatic duct and the arterial blood supply in fishes are difficult to reconcile with conditions in the higher vertebrates. Favoring the other view are the following facts. The lungs are paired outgrowths from the pharynx immediately behind the last gill clefts and in serial order with them; the blood supply from the sixth arterial arch is in full accord with this view, while the skeletal supports of larynx and trachea have, in the early stages and more primitive forms, the relations and appearance of rudimentary gill arches, while the muscles of the region are modified from those of the visceral arches.

The mechanisms by which air is caused to enter the lungs (**in-spiration**) or is expelled from them (**expiration**) differ considerably in the various classes. In the amphibia air is drawn into the mouth via the nares by depressing the floor of the oral cavity. Then, the nares being closed by small muscles, the contraction of the mylohyoid muscle forces the air into the lungs. Expiration is affected in part by the elasticity of the lungs, in part by the muscles of the body wall. In most reptiles the position of the ribs is altered by the action of the intercostal muscles, thus altering the size of the pleuro-peritoneal cavity, to accommodate which air is drawn into and expelled from the lungs. It is difficult to understand how inspiration is effected in the chelonia, but transverse muscles run ventral to the lungs, and these by their contraction, expel the air. Inspiration in other reptiles is not understood, expiration is effected by the muscles in the walls of the lungs and by the transverse abdominal muscles. In the birds the lungs are attached to the ribs and vertebræ, so that any motion of the latter necessitates a change in shape and size of the lungs. In addition the air sacs, as noted above, may play a part in the movement of the air.

In the mammals the ribs are hinged at an oblique angle to the vertebral column, the angle being changed accordingly as the intercostal muscles are contracted or relaxed, and thus the size of the thoracic cavity is increased or diminished. Then the diaphragm (p. 140) also plays an important part in this alteration in size. This transverse muscle forms a complete partition between pleural and peritoneal cavities, projecting into the former like a dome when re-

laxed. When it contracts it flattens, thus increasing the size of the pleural cavity and drawing air in through the trachea. The abdominal muscles also have their effect. Expiration is caused in part by the action of the intercostal and abdominal muscles, in part by the elastic tissue and smooth muscles in the lungs themselves.

ACCESSORY RESPIRATORY STRUCTURES

Allusion has already been made to the pharyngeal and dermal respiration of the amphibia (p. 277). There are several fishes in which the hinder part of the alimentary tract is also respiratory. Thus in *Cobitis* water is drawn in and expelled from the anus, and the posterior half of the digestive canal is richly vascular and is the seat of considerable respiration.

Before hatching or birth the lungs of the amniotes are unable to function, while a certain amount of oxygen is necessary for the development and the carbon dioxide formed must be carried away. This respiratory function is assumed by the allantois. The **allantois** (fig. 308) is a ventral diverticulum from the hinder part of the alimentary canal, which during foetal or embryonic life, acquires a relatively enormous development. It extends beyond the body limits and in reptiles and birds comes into close relations with the porous egg shell, while in the mammals it plays an important part in the formation of the placenta. In all these the allantois is extremely vascular, developing a rich network of blood-vessels close to the shell (sauropsida and monotremes) or to the walls of the maternal uterus (mammals), which serves for the rather limited exchange of gases necessary for the young. After free life begins the allantois is either absorbed (sauropsida) or is lost with the rest of the placenta (mammals), only the basal part persisting as the urinary bladder, described in connexion with the urogenital system.

ORGANS OF CIRCULATION

The functions of the circulation are two-fold: to carry food and oxygen to the tissues and organs of the body and to remove the waste from them. In addition it has been made probable that every activity of the body results in the formation of peculiar substances—**activators**—which have fixed and definite effects upon the various organs. These activators pass into the blood and form the stimulus which may cause other organs or cells, remote from the place where

the activator is formed, to act. This subject is a new one and much may be expected from it in the future.

The structures concerned in the circulation are two fluids, the blood and the lymph; and the vessels (**vascular system**) in which the fluids circulate, certain parts of the vessels being specialized (hearts) for the propulsion of the blood and lymph. A blood heart occurs in all vertebrates in connexion with the blood circulation; most vertebrates have lymph hearts in connexion with the lymph-vessels, but in the higher groups the flow of the lymph is due to the blood pressure and also to the motion of the parts through which the lymph-vessels course.

BLOOD AND LYMPH

The two circulating fluids, blood and lymph, are much alike. Each consists of a fluid portion, the **plasma**, in which float numerous solid particles, the **corpuscles**. The plasma is colorless or slightly yellow and can be separated by clotting into a solid part, **fibrin**, and a fluid, the **serum**, which is, under ordinary circumstances, incapable of clotting again. The lymph plasma contains less of the fibrin-forming substances (**fibrinogen**) than does the blood plasma. The composition of the plasma is very complex. Besides water it contains proteids, extractives, salts, and a number of less-known substances, internal secretions, enzymes, etc. The plasma can also absorb a considerable amount of carbon dioxide. It serves to carry nourishment to the tissues and takes away from them the waste of metabolism.

The corpuscles are of three kinds, erythrocytes, leucocytes and blood plates. Only the leucocytes occur in the lymph while the blood contains all three.

The **erythrocytes**, or red corpuscles give the blood its color. They have fixed outlines and are flattened oval discs in the non-mammals (except cyclostomes) and the camels, circular biconcave discs in the other mammals, and in all except the mammals they are nucleated throughout their existence. They owe their color to an iron-containing proteid, hæmoglobin, which readily combines with oxygen and to a less extent with carbon dioxide and as readily gives up these gases in places where they are scanty. This renders the erythrocytes the respiratory elements of the blood.

It has recently been stated that the erythrocytes of the mammals are hat-shaped (hollow cones) while inside the blood-vessels, and that they assume the biconcave shape after leaving them. This account has been disputed.

The size of the erythrocytes varies in different vertebrates, being the largest in the amphibia (*Amphiuma*) and smallest in the vertebrates (musk deer). A few measurements are giving here in microns (0.001 mm.). Where two dimensions are given they are the length and breadth of the oval corpuscles. Musk deer, 2.5 μ ; man, 7.7 μ ; hen, 7x12 μ ; carp, 9x15 μ ; frog, 16x25 μ ; *Necturus*, 31x58.5 μ ; *Amphiuma*, 44.5x73 μ .

In the higher vertebrates the red corpuscles arise by division of giant cells (erythroblasts) in the red bone marrow, but in the young and at times of great depletion of the blood new red corpuscles may be formed in the spleen and the liver. At first all nucleated, but in the mammals the nucleus is soon lost.

The **leucocytes** or white corpuscles (divided accordingly as they occur in blood or lymph into leucocytes and lymphocytes) are very variable in shape (amoeboid) and may be uni- or polynucleate. By their amoeboid motions they are able to pass through the endothelial walls of the capillaries and to pass among the cells of the different tissues, hence they are often called wandering cells. They have the power of ingesting foreign bodies which renders them of value in combating pathogenic organisms; and they also aid in the absorption of fats and peptones.

The blood plates are very little known. Their size is less than that of the red corpuscles and they rapidly degenerate when drawn from the vessels. They are circular or elliptical in outline.

THE BLOOD-VASCULAR SYSTEM

The blood-vessels include the **arteries**, which carry the blood from the heart to all parts of the body; the **veins**, which bring it back, and the **capillaries**, minute tubes, which connect the ends of the arteries and veins, for the system is closed, and there is a complete circulation.

Since all transfer of gases and nourishment takes place through the capillaries, these vessels have extremely thin walls, consisting of a single layer of squamous epithelium, the so-called intima. Usually, as the name implies, the capillaries are very small in diameter, but attention has recently been called to the **sinusoids**, vessels with similar walls but larger in diameter, which are noticeable in some developing organs, especially the liver. Here also must be mentioned the **retia mirabilia**, places where an artery or vein suddenly breaks up into a network of small vessels (often capillary) which unite again, as in the chorioid plexuses of the brain, the red bodies of the swim bladder, the pseudobranchs and in the glomeruli of the kidney, to form a vessel as large as before. In the lymph nodes there are similar networks of the lymph-vessels.

Arteries and veins (fig. 309) are larger than the capillaries and they have their walls strengthened outside of the intima by layers of smooth muscle fibres (**muscle wall**) and connective tissue, mostly elastic (**adventitial wall**) (fig. 309). Since the arteries are subjected

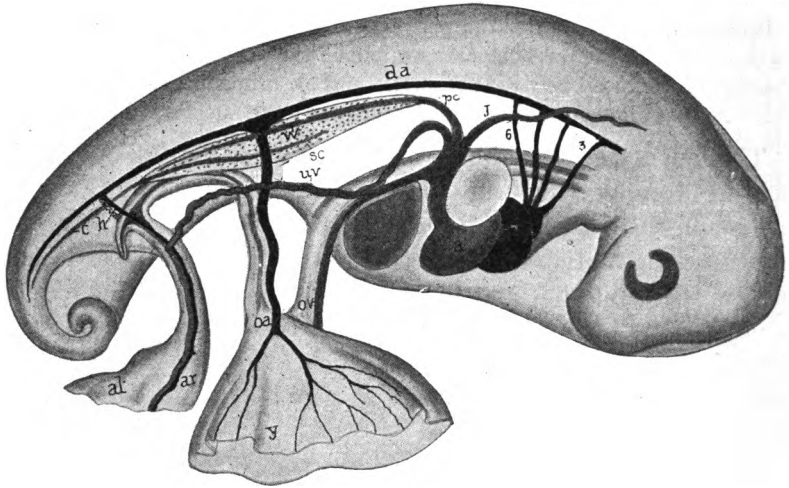


FIG. 308.—Embryonic circulation of snapping turtle, *Chelydra*, showing relations of allantois, after Agassiz and Clarke. *a*, right auricle; *al*, allantois; *av*, allantoic vessels; *c*, caudal vein; *da*, dorsal aorta; *h*, hypogastric artery; *j*, jugular; *l*, liver; *oa*, *ov*, omphalomesenteric artery and vein; *pc*, post-cardinal; *sc*, subcardinal vein; *uv*, umbilical vein; *w*, Wolffian body; *y*, yolk sac; 3-6 aortic arches.

to greater pressure than the veins their walls are relatively much thicker, but in other respects the two are much alike, except that valves to prevent the backflow of the blood, may occur in the veins,

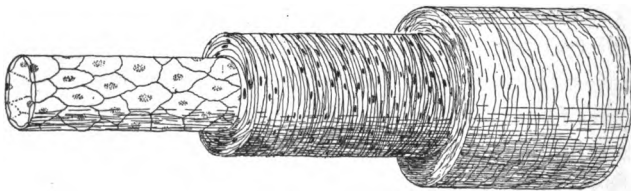


FIG. 309.—Diagram of artery or vein. At the left the intima alone; covered in the middle by the muscularis, and at the right with the adventitia added.

especially those which are vertical in the normal position of the animal (legs).

It has been suggested, with much plausibility, that the main blood-vessels are the remnants of the segmentation cavity, which elsewhere has been obliterated by the increase of the mesoderm. As will be recalled (p. 16) the mesothelium grows toward the middle line above and below the digestive tract, thus

tending to narrow the segmentation cavity in these regions into two longitudinal tubes. The epimeral part of the mesothelium divides into somites, and of course the segmentation cavity extends between these, and as these somites grow downward, these lateral extensions of the segmentation cavity are carried ventrally, so that at last they form a series of pairs of transverse vessels connecting the longitudinal trunks, thus forming the vessels of the somatic wall. Other tubes, connecting the dorsal and ventral trunks, would form between the two walls of the mesentery and between the splanchnic mesoderm and the entoderm, thus outlining the vessels of the alimentary tract.

Even more speculative is the suggestion that the original circulation was lymphoidal and that the blood circulation is a specialization of a part of this, the definitive lymph-vessels being the unmodified part of the primitive system of vessels.

An appreciation of this probable ancestral condition makes the actual structures more easily understood. In development much of this phylogenetic history has been lost, while other parts have been masked by the development of additional vessels. Many vessels,

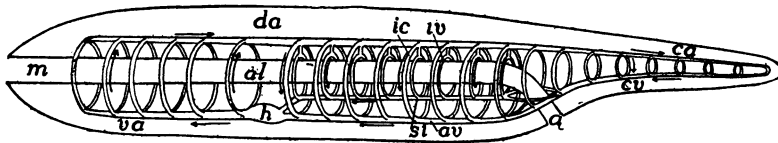


FIG. 310.—Diagram of the primitive vertebrate circulation. *a*, anus; *al*, alimentary canal; *av*, abdominal vein; *ca*, *cv*, caudal artery and vein; *da*, dorsal aorta; *h*, heart; *ic*, intercostal (somatic) transverse vessels; *iv*, intestinal vessels; *m*, mouth; *si*, subintestinal vein; *va*, ventral aorta. The arrows indicate the direction of the flow of the blood.

which theoretically should arise as spaces between other tissues, are actually formed as solid cords of cells, which are later canalized and converted into tubes. Again, separate vessels of the embryo may fuse during development into a single vessel of the adult.

The chief features of the theoretically primitive condition may be summarized here (fig. 310). A dorsal tube carries the blood toward the tail. From this transverse vessels—right and left, somatic and splanchnic—arise, which connect with two ventral longitudinal tubes, one in the wall of the alimentary tract and extending forward to its junction with the second which runs in the ventral body wall, a single tube coursing from the point of union to the anterior end of the body. In *Amphioxus* various parts of this system develop muscular walls and act as pumping organs. In the vertebrates, so far as the blood system is concerned, there is a single pumping organ, the heart (the portal heart of the myxinoids may be ignored in this general statement). The heart arises in the ventral tube beneath

the pharynx and anterior to the junction of the two tubes. It marks the line of division of the transverse tubes into ascending and descending, those in front of the heart carrying the blood upward while those behind return it to the ventral vessels which carry it forward. The transverse vessels are not continuous but capillaries intervene between their dorsal and ventral moieties.

With this introduction, an outline of the circulation in the lower vertebrates (ichthyopsida) and in the embryos of the amniotes may make the following clearer.

In all vertebrates the heart lies on the ventral side of the alimentary canal in a **pericardial sac** which is a part of the coelom (p. 18). In the heart as soon as it is functional, several parts are differentiated. At the posterior end is a thin-walled sac, the **sinus venosus**, which is followed, going forward, by a larger division, the **atrium**, with slightly thicker walls. The next division, the **ventricle**, is much thicker walled on account of the development of the muscles necessary to force the blood through the whole system. In front of the ventricle, but still inside of the pericardial cavity, is a tube, the **arterial trunk**, which is continued farther forward, in front of the pericardial cavity, by the **ventral aorta**.

The ventral aorta gives off a series of pairs of vessels, the **aortic arches** (fig. 311) which rise on the sides of the pharynx, in the gill septa, to the dorsal side of the alimentary canal where those of a side unite in a longitudinal canal, the **radix aortæ**, the radices of the two sides uniting farther back to form the **dorsal aorta**, which continues to the posterior end of the body. From the arches and from the dorsal aorta (all of these are arterial) numbers of arteries arise, some of which are mentioned here, others being considered later.

The most anterior aortic arch gives rise to two

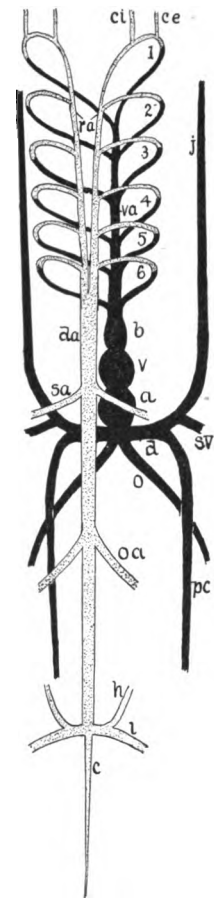


FIG. 311.—Diagram of early circulation of vertebrate. *a*, atrium; *b*, bulbus arteriosus; *c*, caudal artery; *ce*, *ci*, external and internal carotid arteries; *d*, Cuvierian duct; *da*, dorsal aorta; *h*, hypogastric artery; *i*, iliac artery; *j*, jugular vein; *o*, omphalomesenteric vein; *oa*, omphalomesenteric artery; *pc*, post-cardinal vein; *ra*, radices aortæ; *sa*, *sv*, subclavian artery and vein; *v*, ventricle; *va*, ventral aorta, 1-6, aortic arches.

arteries on either side, an **internal carotid artery** which goes to the brain, and an **external carotid** which supplies the more superficial parts of the head. As was indicated above, the arteries arising from the dorsal aorta are either somatic or visceral. Among the first category are the **intercostal** and the **renal arteries**, the intercostals coursing between the myotomes, the renals being distributed to the successive segments of the excretory organs. Among these somatic arteries an anterior and a posterior pair usually obtain especial prominence, the first (the **subclavian artery**) supplying the fore limb, while the **iliac artery** has similar relations to the hind limb. The splanchnic or visceral arteries show little trace of metamerism. They are distributed to the walls of the alimentary tract. Two pairs of these vessels, again, are of special importance, a pair of **omphalo-mesenteric arteries** in front, and a pair of **hypogastric arteries** near the origin of the iliac arteries.

The distal ends of these and other arteries are connected by capillaries with the veins, through which the blood is returned to the heart. The head is drained by a pair of (**superior**) **jugular veins** above the mouth, while (in fishes) the region of the lower jaw and the lower side of the gill arches have a pair of **inferior jugulars**. These run back to the level of the hinder part (venous sinus) of the heart, where they are joined on either side by a **postcardinal vein** coming from the excretory organ. Jugulars and postcardinal of a side unite to form a transverse trunk, the **Cuvierian duct**, which empties into the sinus venosus.

A pair of **omphalo-mesenteric veins** enter the posterior side of the venous sinus. These pass on either side of the liver, and are the continuations of a **subintestinal vein** which runs on the ventral side of the alimentary canal. Behind, the subintestinal forms a loop around the anus, beyond which it extends to the end of the tail as the **caudal vein**. **Subclavian veins** from the fore limbs empty either into the jugulars or the postcardinals near the Cuvierian duct, while the blood leaves the hind limb of either side by an **iliac vein**, which runs forward in the lateral body wall as the **lateral abdominal vein**, to enter the Cuvierian duct. Of these veins, the omphalo-mesenteric and subintestinal belong to the visceral group, the others are somatic.

Most of the vessels mentioned in the foregoing paragraphs are laid down very early in the embryo, and the later developments are largely concerned with modifications and additions to this frame-

work. For convenience these will be taken up under the heads of the heart, the arteries and the veins.

It is impossible here to follow in detail the development of all parts of the circulatory system, or even to mention all of the vessels in all of the groups. All that can be attempted is an account of the more important parts and their modifications, with here and there references to their history which will render their peculiarities more intelligible. Most of the major trunks are now known to appear at first as lines of vascular cells, similar to and arising in the same way as those described in connexion with the heart (below), and it seems possible that the intima of all of the blood-vessels is in genetic relations to such lines of cells. It should be remembered that the vascular system is extremely variable, even within the limits of the species.

THE HEART

The heart, the central organ for the propulsion of the blood, lies in the pericardial sac, the walls of which constitute the pericardium, the cavity being partially filled with a serous **pericardial fluid**. The walls of the heart are largely muscular, the muscles forming the **myocardial layer**, which is covered on its inner and outer surfaces by epithelium (endothelium). The epithelial layer turned toward the pericardial cavity is the **epicardium** (really pericardial in nature), while that on the side of the blood cavity of the heart is the **endocardium**.

The development of the heart is simplest in the vertebrates with relatively small yolk. It is more modified in the elasmobranchs, and is most complicated in the large yolked eggs of the sauropsida and in the mammals where the yolk sac is large, though the yolk is small. The following account is based upon the development in the amphibia:

From just behind the point where the first or spiracular gill cleft is to form, backward to the region just in front of the anlage of the liver the hypomeral portions (lateral plates) of the coelomic walls grow ventrally beneath the alimentary canal (figs. 312-314) in much the same way as farther back (p. 16). In these descending plates splanchnic, mesenterial and somatic walls, as well as the coelomic cavity are recognized. As they descend, cells which have received the name of **vascular cells** appear between the coelomic walls and the entoderm. The origin of these has been in dispute, but the present

evidence favors their origin from the mesothelium. Some of these vascular cells are more dorsal and aid in the formation of the dorsal blood-vessels, while the ventral (fig. 312, *A*) contribute to the heart and the ventral trunks.

The descent of the lateral plates continues until their lower edges meet just dorsal to the ventral ectoderm and the ventral parts of the mesenterial regions of the two sides fuse to a vertical plate, the **ventral mesocardium** (fig. 312, *B*), above which is a groove in which the ventral vascular cells lie. Next, the edges of the plates crowd in above the groove and meet to form a **dorsal mesocardium**, the result being that groove is converted into a tube. The mesocardia disappear early, the ventral usually being lost before the dorsal is formed (fig. 312, *C*). (A portion of the ventral mesocardium persists



FIG. 312.—Diagrammatic cross sections of developing heart. Compare with figures 313 and 314. In *A* the descending mesothelial plates have nearly met, a number of vascular cells between them. In *B* the plates have met ventrally, forming the ventral mesocardium; most of vascular cells utilized in forming the endocardium. In *C* the plates have met dorsally, with the resulting dorsal mesocardium; the ventral mesocardium has disappeared, placing the two coelomic cavities, now the pericardium, in communication. *c*, coelom; *ec*, ectoderm; *en*, entoderm; *end*, endocardium; *m*, edges of descending mesothelium; *p*, pericardium; *v*, vascular cells.

in turtles and crocodiles, connecting the apex of the heart to the pericardial wall). The walls of the tube, which are to form the muscular and epicardial walls of the heart, are called the **myoepicardial mantle**.¹ The vascular cells, which are enclosed in this mantle, gradually arrange themselves as a continuous sheet, the **endocardium**, which lines the future heart.

With the disappearance of the mesocardia the coelomic spaces on the two sides communicate with each other so that the myoepicardial mantle lies free on all sides in a coelomic sac, being bound to the walls only at the two ends. This cavity or sac is the **pericardial cavity**, the extent of which is decreased by the fusion laterally of the somatic and splanchnic walls (fig. 314).

In front of and behind this tube the descending lateral plates are kept from meeting in the middle line by the projections for the mouth

¹ The fact that the heart muscles arise from this layer—mesothelial and yet not myotomic—partly explains the differences between cardiac and other muscles.

and liver (fig. 314). Vascular cells, however, are formed in these regions and these furnish the lining of tubes on either side, arising in the edges of the lateral plates. These tubes consequently diverge from the myoepicardium in front and behind and form the first stages of the vessels connected with the heart, the anterior pair giving rise to the **mandibular arteries**, the posterior to the **omphalomesenteric** (omphalomesaraic) **veins** (fig. 314). At about the same time a transverse tube appears on either side, which connects with the heart tube, just in front of the division into omphalomesenterics (fig. 313). These transverse vessels continue laterally between the

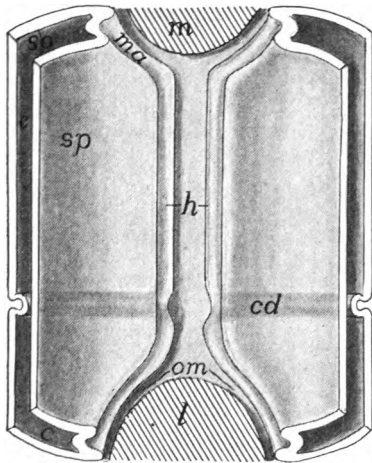


FIG. 313.

FIG. 313.—Diagram of the formation of the heart tube, showing the descending mesothelial plates from above. *c*, cœlom; *cd*, first appearance of the Cuvierian ducts; *h*, grooves to form heart and ventral aorta; *l*, liver; *m*, mouth; *ma*, mandibular artery; *om*, omphalomesenteric veins; *so*, *sp*, somatic and splanchnic walls of cœlom.

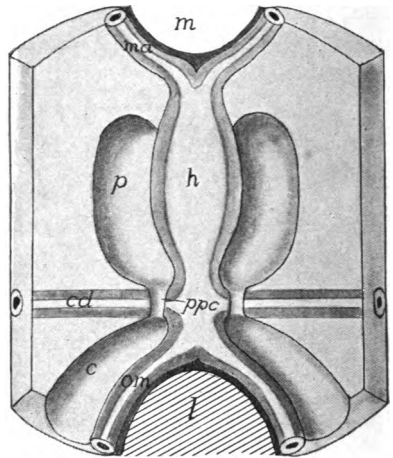


FIG. 314.

FIG. 314.—Early stage of the heart; the descending plates of fig. 313 have met, forming the heart and ventral aorta. *c*, peritoneal cœlom; *p*, pericardial cœlom; *ppc*, pericardio-peritoneal canals; other letters as in fig. 313.

lateral plate and the ectoderm, forming the venous trunks known as the **ducts of Cuvier** (**trunci transversi**), the other relations of which will be described later (p. 310). The cœlom on either side of the heart is restricted behind by the ridge formed by the Cuvierian ducts (fig. 314); with growth this interruption grows larger, the result being a transverse partition, the **septum transversum** (fig. 11), which bounds the pericardial cavity behind and separates it from the rest of the cœlom, the peritoneal cavity. At first this septum is incomplete, and in the myxinoids and elasmobranchs it never closes dorsally to the omphalomesenterics, but leaves two openings.

the **pericardio-peritoneal canals** (fig. 314). Elsewhere the pericardial and peritoneal cavities are entirely separate in the adult.

In teleosts and amniotes, where the early embryo is closely appressed to the very large yolk sac, the development of the heart is modified. At first the pharynx is not complete below but communicates ventrally with the yolk. Hence the two hypomeres are prevented, for a time, from meeting ventrally. Each, however, is accompanied by its vascular cells; its edge becomes grooved and the grooves are rolled into a pair of tubes, lined with endocardium, so that for a time the anlage of the heart consists of two vessels (fig. 315), each connected in front and behind with its own mandibular artery and omphalomesenteric vein, and is surrounded with its pericardial sac. Later the two tubes approach and fuse, with the formation of mesocardia as before: these latter soon disappearing, leaving the whole much as in the small yolked forms.

In the early stages the pericardium is relatively large, but it does not keep pace with the growth of the other parts, until finally in the adult it is only large enough to accommodate the changes in size and

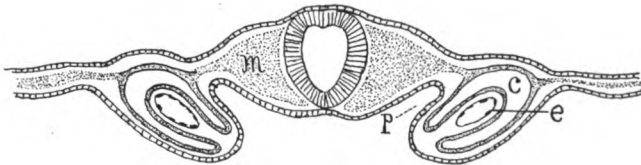


FIG. 315.—Section through the developing heart of a rabbit, after His. *c*, pericardial cœlom; *e*, endothelium of half of heart; *m*, mesoderm; *p*, pharyngeal region not yet cut off from yolk sac.

shape of the heart, due to its alternating enlargement (**diastole**) and contraction (**systole**).

As long as the mesocardia are present the cardiac tube is a straight canal, lying in the pericardial sac and connected with its walls in front and behind. With their disappearance the tube increases in length more rapidly than does the pericardium, the result being the flexure of the tube on itself, something like the letter S, the flexures being largely in the vertical plane. At the middle point of the flexure the tube remains small, forming the **atrio-ventricular canal**, but in front of and behind this the walls become thickened and the lumen enlarged. The posterior and dorsal of the chambers thus formed becomes the **atrium (auricle)**, the ventral and anterior the **ventricle** of the heart.

The atrium is bounded posteriorly by a constriction, behind which the tube expands into another chamber, the **sinus venosus**, which extends back to the posterior wall of the pericardium and re-

ceives the ducts of Cuvier and the omphalomesenteric veins. The ventricle, also, does not reach the anterior wall of the pericardium, but the anterior part of the heart tube forms a smaller trunk, the **truncus arteriosus**, while from the pericardium to the mandibular arteries is an arterial vessel, the **ventral aorta** (fig. 320).

Muscles, as stated above, are developed in the wall of the heart, but to an unequal extent in the different parts, being scanty in the sinus venosus, and most abundant in the ventricle where they form an internal framework of trabeculæ, giving the ventricle a somewhat spongy characteristic. Folds or **valves** of the endocardium appear in places at an early date and are so arranged that they permit the

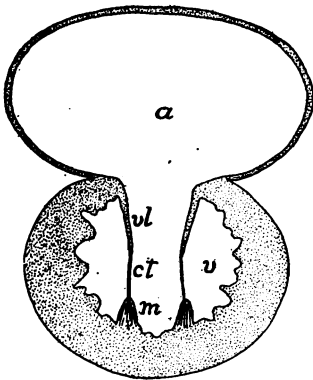


FIG. 316.—Diagrammatic cross section of heart showing atrio-ventricular valves; *a*, atrium; *ct*, chorda tendinea; *m*, musculla papillosa; *v*, ventricle; *ul*, atrio-ventricular valves.

blood to flow forward but prevent any backflow. In the base of the truncus these valves take the form of pockets on the walls, there being several (3–8) rows with several valves in a row in the elasmobranchs (fig. 317, *A*) and ganoids. This valvular part of the truncus is called the **conus arteriosus**. In other vertebrates the conus is reduced to a single row of valves.

Valves also occur in the atrio-ventricular canal (fig. 316) but here the pocket-like condition is impossible. The folds extend from the canal into the ventricle and are prevented from folding back into the atrium, under the heavy ventricular pressure, by ligaments—**chordæ tendineæ**—which extend from the edges of the valves to the opposite wall of the ventricle, and are kept taut during systole by short papillose muscles (**columnæ carnea**) at the base. Other valves, more simple in character, occur around the opening from the sinus into the atrium and, in some vertebrates, where the hepatic veins empty into the sinus.

In many fishes the conus arteriosus is followed by a strongly muscular region, the **bulbus arteriosus** (fig 317, *B*) which has muscles like those of the heart (p. 130), while the truncus in front of this has smooth muscles, like the rest of the blood-vessels. Hence conus and bulbus are to be regarded as a part of the heart, while the region in front is a part of ventral aorta to be described below.

The heart, as described above, is usually spoken of as a **branchial**

or **venous heart**, since it represents the extremes of development in the cyclostomes and fishes (the dipnoi excepted). In these animals all of the blood which enters the heart is venous blood and is all pumped directly to the gills to lose its carbon dioxide and to take up oxygen, before being distributed to the various parts of the body. In its course through the body it passes but once through the heart in order to make the complete circuit. The term is not strictly correct for the embryonic amniotes, for in these only oxygenated blood passes through the heart when it is in this stage.

When, however, lungs are formed (dipnoi and amphibia) to share in the respiratory processes, the heart begins to divide into arterial or systemic, and venous or respiratory halves. This division is brought

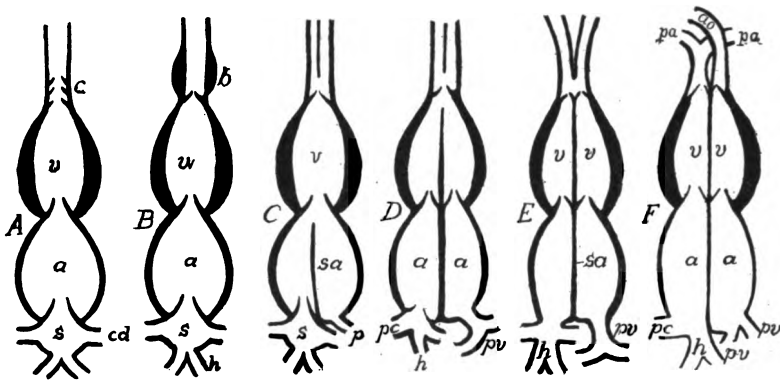


FIG. 317.—Different stages in the differentiation of the parts of the heart. *A*, elasmobranch; *B*, teleosts; *C*, amphibia; *D*, lower reptiles; *E*, alligator; *F*, birds and mammals. *a*, atrium; *ao*, aorta; *b*, bulbus arteriosus; *c*, conus; *cd*, Cuvierian duct; *h*, hepatic veins; *pa*, pulmonary artery; *pc*, pre- and postcaval veins; *pv*, pulmonary vein; *s*, sinus venosus; *sa*, septum atriorum; *v*, ventricles.

about by the formation of a septum or partition in the atrium, partially or completely dividing the chamber, the pulmonary vein (p. 315) opening into the left half, which thus becomes arterial, while the sinus, with its veins, is connected with the right alone (fig. 317, *C*).

Still higher in the scale the partition or septum extends through the atrio-ventricular canal, dividing its valves into two groups (**tricuspid** valves on the right side, **mitral** on the left) and partially dividing the ventricle (most reptiles fig. 317, *D*). In the crocodilia (fig. 317, *E*) the division of the ventricle is completed by the extension of the septum to the anterior end, but there is an opening (**foramen Pannizæ**) between the two sides of the aortic trunk, so that some

admixture of arterial and venous blood can occur. In the birds and mammals (fig. 317, *F*) there is complete internal separation of the two sides of the heart, though externally it usually shows but slight signs of the division. As a result of this division blood must pass twice through the heart (once through the venous, once through the arterial half) in order to make a complete circuit of the body. Venous blood enters the right atrium, passes to the right ventricle, by which it is forced to the lungs (**pulmonary or respiratory circulation**). Returning to the heart by the pulmonary veins, it passes

through the left atrium and ventricle and thence through the **systemic circulation**, by which all parts of the body are supplied.

When first formed, the heart lies close behind the mandibular artery (first aortic arch to be described below), but as other vessels are formed it is forced farther back into a position, in the lower vertebrates, ventral to and a little behind the pharynx, but in the adult tetrapoda it is carried back, as a result of unequal growth, even into the thorax, the extreme of migration being seen in the giraffe and the long-necked birds.

Although all of the blood of the body passes through the heart at short intervals, this is not sufficient for the nourishment of that organ. Therefore its muscles are usually supplied with blood through **coronary arteries** (fig. 318) which arise from the aortic arches

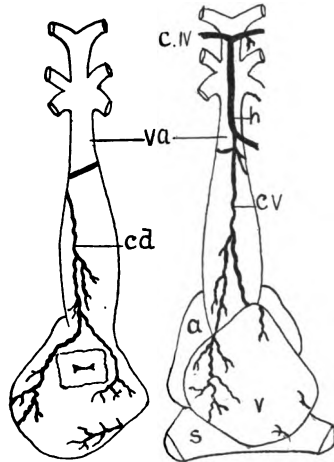


FIG. 318.—Dorsal and ventral views of the heart of *Amia*, after Parker and Davis. *a*, auricle; *cd*, dorsal coronary artery; *cv*, ventral coronary artery; *cIV*, commissure from fourth arch; *h*, hypobranchial artery; *s*, sinus venosus; *v*, ventricle; *va*, ventral aorta. The auricle has been removed from the dorsal view leaving the atrio-ventricular canal visible.

and run back along the truncus arteriosus to reach the atrium and ventricle.

THE ARTERIES

Aorta and Aortic Arches.—The **ventral aorta** is the trunk in front of the pericardium, extending from the truncus arteriosus to the mandibular artery (first aortic arch). It runs, not through a cavity, but between muscles and through connective tissue. The mandibular arteries pass upward on either side of the pharynx until they reach its dorsal surface. With development, the ventral aorta

elongates and at the same time other aortic arches arise between the mandibular arteries and the pericardium, these extending dorsally until they meet the backward prolongations of the first, thus forming a pair of longitudinal tubes, dorsal to the alimentary tract, the *radices aortæ* (fig. 311).

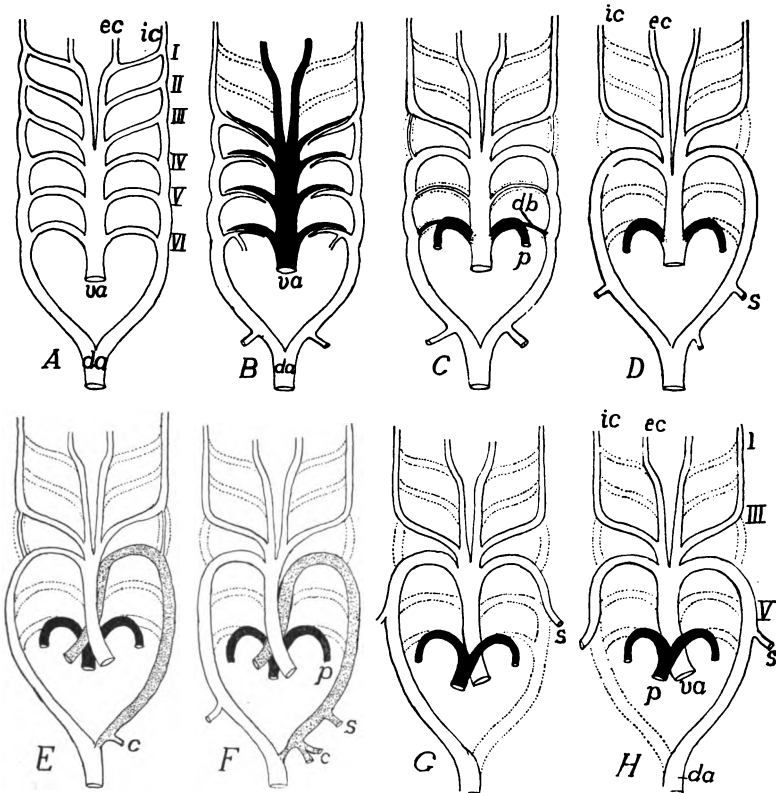


FIG. 319.—Modifications of the aortic arches in different vertebrates, after Boas; *A*, primitive scheme; *B*, dipnoan; *C*, urodele; *D*, frog; *E*, snake; *F*, lizard; *G*, bird; *H*, mammal. *c*, coeliac artery; *da*, dorsal aorta; *db*, ductus Botallii; *ec*, *ic*, external and internal carotids; *p*, pulmonary artery; *s*, subclavian; *ua*, ventral aorta. Vessels carrying venous blood black; those with mixed blood shaded; those which disappear, dotted outlines.

The number of pairs of aortic arches varies with the number of gill clefts, the vessels coursing in the septum between the clefts. The number of arches is greatest in the myxinoïds, where the number of clefts varies (p. 255); seven or eight in the notidanid sharks; and, as recent investigations tend to show, probably six in the embryos of all other vertebrates. The history of these arches differs greatly in the different classes (fig. 319), there usually being a reduction in

number by the more or less complete abortion of one or more pairs as well as a modification of those which persist, accompanying changes in the respiratory system.

With the development of gills (ichthyopsida) each aortic arch becomes divided into two portions, an **afferent branchial artery** conveying blood from the ventral aorta to the gills and an **efferent branchial artery** (sometimes called a **branchial vein**) carrying it from the gills to the radix aortæ (fig. 319, *B*; 320). These two vessels parallel each other for a part of their course and are connected with each other by numerous capillary loops which run through the gill filaments (fig. 278). In passing through the gills the blood loses its carbon dioxide and takes up oxygen, and thus becomes converted

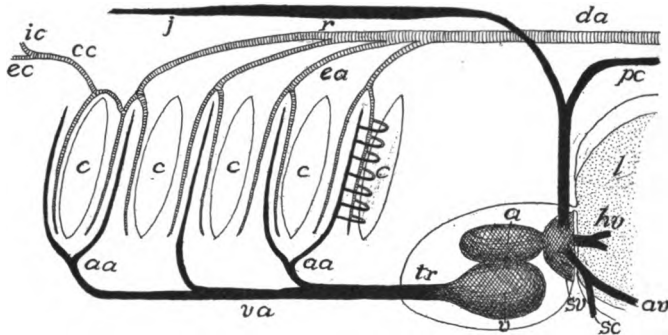


FIG. 320.—Scheme of branchial circulation in elasmobranchs. *a*, atrium; *aa*, afferent branchial arteries; *av*, abdominal vein; *c*, gill clefts; *cc*, common carotid; *da*, dorsal aorta; *ea*, efferent branchial arteries; *ec*, external carotid artery; *hv*, hepatic vein; *ic*, internal carotid; *j*, jugular vein; *l*, liver; *pc*, postcardinal vein; *sc*, subclavian vein; *sv*, sinus venosus; *tr*, truncus arteriosus; *v*, ventricle; *va*, ventral aorta.

from venous to arterial blood. In the amniotes afferent and efferent branchial arteries are never differentiated, the aortic arches being continuous from the ventral aorta to the radices aortæ.

The first of these arches (the mandibular arteries) never forms afferent and efferent portions since no gills are ever developed in their region. From each half of this arch an artery, the **external carotid**, extends forward to supply the lower and a part of an upper jaw, while an **internal carotid artery** forms an extension forward of each radix and supplies the brain and face (fig. 311). Later their relations are such that the carotids appear to arise from the first of the functional arches (fig. 319, *C* to *H*).

As was said above, the typical number of aortic arches is six pairs, this number being but rarely exceeded. In all groups except cyclos-

tomes and fishes they undergo considerable modification, and in the fishes they are frequently more or less reduced in correlation with the reduction of the gills (p. 254). The modifications may be outlined as they occur in the successive pairs of arches.

In many fishes and all tetrapoda the first arch on either side disappears beyond the point where the external carotid arises (fig. 319, *B* to *D*) while, correlated with the reduction of the spiracular gill, the second pair of arches is partially or completely lost in the adult. The third pair is always persistent and through them flows the blood for the internal carotids and, in the fishes, gymnophiona and a few urodeles (fig. 319, *C*) and reptiles (*E*), blood for the radices aortæ as well. In all other tetrapoda the radix disappears between the third and fourth arches (fig. 319, *D*) and consequently here the third arch is purely carotid in character. When this occurs the por-

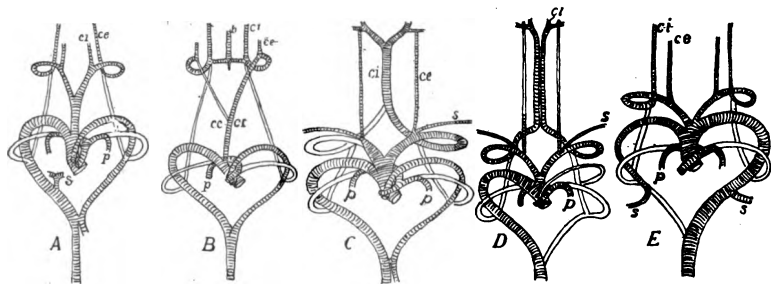


FIG. 321.—Aortic arches of amniotes, after Hochstetter. *A*, *Varanus*; *B*, snake; *C*, alligator; *D*, bird; *E*, mammal. *b*, basilar artery; *cc*, common carotid; *ei*, *ce*, internal and external carotids; *da*, dorsal aorta; *p*, pulmonary; *s*, subclavian.

tion of the ventral aorta between the third and fourth arches carries blood for the carotids alone and hence forms a **common carotid** trunk, usually divided into right and left common carotid arteries.

The fourth pair of arches are the systemic trunks in all tetrapoda, carrying blood from the ventral to the dorsal aortæ, while the fifth, reduced in size, perform a similar function in a few lizards and urodeles (fig. 319, *C*), but elsewhere they entirely disappear. The fourth arches show a differentiation between the two sides in many reptiles. That on the left side becomes separated from the rest of the ventral aorta (fig. 319, *E*, *F*) and has its own trunk connecting with the right side of the partially divided ventricle, and, as will be understood from the relations of the heart (p. 297), it may carry a mixture of arterial and venous blood. From the dorsal side, this blood of the left fourth arch is largely distributed to the digestive

tract, the cœliac axis arising from its radix (fig. 319, *E, F*) while the part connecting it with the dorsal aorta is reduced in size. The right arch and the carotids are connected with the left side of the heart and hence are purely arterial, the arch forming the main trunk connecting the heart with the dorsal aorta. In the birds (fig. 319, *G*) the radix of the left side of the adult disappears distal to the origin of the subclavian artery, so that this arch supplies only the fore limb of that side, while the right arch is purely aortic in character. In the mammals (fig. 319, *H*) these relations are exactly reversed, the right arch being subclavian, the left supplying the dorsal aorta and the subclavian of that side.

With the development of lungs (dipnoi, tetrapoda) a pair of pulmonary arteries are developed from the sixth pair of arches on the ventral side of the pharynx. These grow back into the lungs, while the rest of the arch, dorsal to their origin, becomes reduced to a small vessel, the **ductus arteriosus** (**d. Botallii**, fig. 319, *C*) in some urodeles, and persists occasionally vestigially in higher vertebrates. Elsewhere it entirely disappears.

The ductus Botalli is important in the embryonic circulation of amniotes, as the larger part of the blood goes through it to reach the dorsal aorta, as long as the allantois is the organ of respiration, while only enough blood goes through the pulmonary artery to nourish the lung. With the first inspiration of air, the duct closes and all blood passing into the last arch goes to the lung.

In the dipnoi and amphibia, where the ventricle remains undivided, the pulmonary arteries are connected with the same trunk (ventral aorta) as are the other aortic arches (fig. 319, *C, D*). In the amniotes (*E, F, G, H*) with partial or complete division of the ventricle (fig. 319, *D to F*), the truncus and the ventral aorta are divided in such a manner that derivatives of the sixth arch are connected with the right side of the heart, while the rest of the ventral aorta, save for the exception noted in the reptiles above, receives its blood from the left side of the heart.

In connexion with the almost complete obliteration of the fifth arch, and, in most pulmonate vertebrates, the separation of the sixth from the rest, it is interesting to note that in the lower vertebrates (elasmobranchs) there is already a differentiation of these two arches from the others of the series (fig. 320).

The dorsal aorta arises by the fusion of two primitive trunks which run posteriorly, just dorsal to the mesentery and approximately parallel to the notochord, to the end of the body. This fusion may extend only as far forward as the last aortic arch, the parts of the trunks in front of this point being the

radices aortæ (fig. 311), or, again, it may involve the whole of the radices, the aorta in this case extending to the most anterior arch.

In human anatomy the different parts of the aortic vessels have names different from those adopted here. The persistent portion of the ventral aorta is called the **ascending aorta**, the persistent fourth arch is the **arch of the aorta**, and the adjacent part of the dorsal aorta is the **descending aorta**. The rest of the dorsal aorta is divided into the **thoracic** and **abdominal aortæ**, accordingly as they lie in the regions of the corresponding cavities. These terms are inapplicable in comparative anatomy.

The arteries arising from the dorsal aorta may be grouped under the two categories, visceral and somatic (p. 289). To the former belong the vessels running through the mesenteries to supply the digestive tract. In the primitive condition these are numerous, but they do not show a metameric character. In the majority of verte-

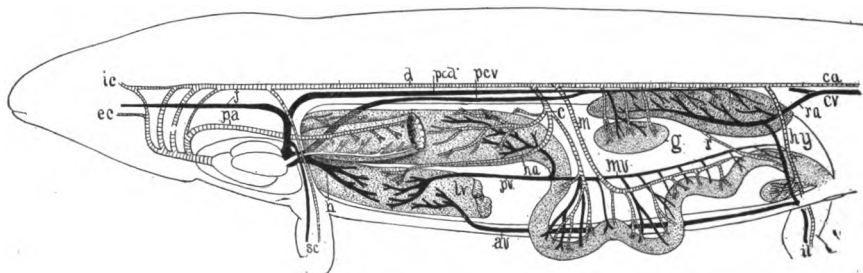


FIG. 322.—Diagram of vertebrate circulation based on a urodele. Arteries cross-lined; veins black except the pulmonary vein, white. *av*, abdominal vein; *c*, cœliac artery; *ca*, *cv*, caudal artery and vein; *d*, dorsal aorta; *ec*, external carotid; *g*, gonad; *h*, hepatic vein; *ha*, hepatic artery; *hy*, hypogastric artery; *ic*, internal carotid; *il*, iliac artery and vein; *j*, jugular; *lv*, liver; *m*, *mv*, mesenteric artery and vein; *pa*, pulmonary artery; *pcd*, post-cardinal; *pcv*, postcava; *pb*, hepatic portal vein; *r*, renal adhevent vein; *sc*, subclavian artery and vein.

brates they become united into a smaller number of main trunks from which branches go to the various regions of the canal. The principal of these trunks are the following: There is usually present a **cœliac artery**, arising from one radix or from the dorsal aorta near it, and dividing in the mesogaster into **gastric**, **splenic** and **hepatic arteries**, distributed to stomach, spleen and liver. The **superior mesenteric artery** is connected in development with the omphalomesenteric arteries (p. 291) and goes to the anterior part of the intestine; while frequently an **inferior mesenteric artery** is distributed to the posterior part of the digestive tract. The superior mesenteric may fuse with the cœliac to form a **cœliac axis**, while not infrequently other mesenteric arteries may be developed.

The **hypogastric arteries**, already mentioned, primitively connect

the dorsal aorta with the subintestinal vein in the neighborhood of the anus, and later give off vessels to the region of the rectum. When, as in all classes, from the amphibia upward, a urinary bladder is developed from the rectal (cloacal) region, the hypogastrics form its blood supply, these vessels being the vesical arteries. In the amniotes the distal end of the anlage of the bladder forms a foetal

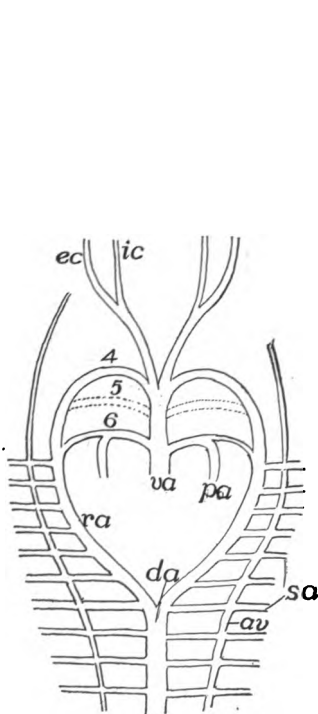


FIG. 323.

FIG. 323.—Diagram of early relations of vertebral arteries in an amniote. *av*, vertebral artery; *da*, dorsal aorta; *ec*, *ic*, external and internal carotids; *pa*, pulmonary artery; *ra*, radix aortæ; *sa*, subclavian; *va*, ventral aorta; 4-6, aortic arches.

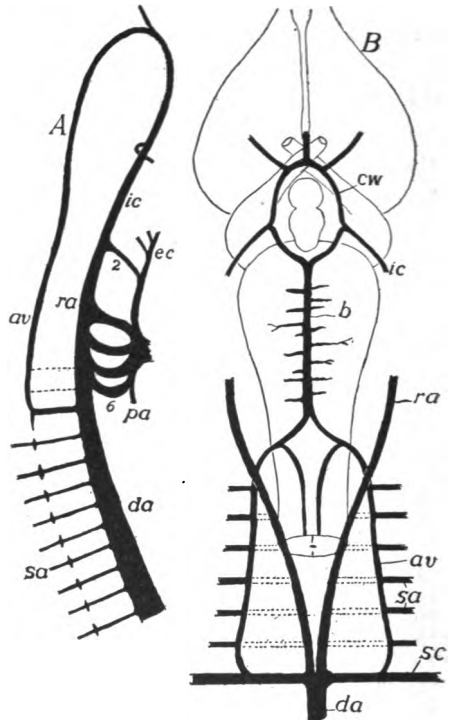


FIG. 324.

FIG. 324.—*A*, side view of developing anterior arteries of *Lacerta*, after van Bemmel; the vertebral artery not developed behind; *B*, ventral view of the relations of the arteries at the base of the vertebrate brain. *av*, vertebral artery; *b*, basilar artery; *cw*, circle of Willis; *da*, dorsal aorta; *ec*, *ic*, external and internal carotids; *pa*, pulmonary artery; *ra*, radix aortæ; *sa*, segmental arteries; *sc*, subclavian; 2-6, aortic arches.

structure known as the allantois, described in another section (p. 382), and parts of the vesical arteries are carried out as **allantoic arteries** (figs. 327, 329), into the new formation. Since these pass through the umbilicus, they are also known as the **umbilical arteries**. Later, when the umbilicus disappears, the allantoic arteries are lost and only the rectal and vesical arteries remain of the hypogastric trunks.

Behind the hypogastric arteries the caudal aorta is called the **caudal artery** (figs. 322, 327). The somatic arteries are more numerous and are metamericly arranged. They are distributed to the body wall and to the parts arising from it by development, and may be subdivided into two groups. The first of these in the early stages are given off in pairs from the radices and the dorsal aorta, an artery on either side extending laterally between each two successive myotomes (fig. 310). These are the upper halves of the transverse somatic vessels alluded to on p. 289. Many of these remain in a slightly modified condition and are called **intercostal arteries** (including **lumbar** and **sacral arteries**, etc., according to position). These usually become connected on either side (fig. 323), near their origin, by a longitudinal vessel, the **vertebral artery**, which, in the higher vertebrates, runs through the vertebrarterial canal (p. 61) of the vertebræ.

In the region of the aortic roots, after the formation of the vertebral artery, all of the segmental arteries except the last of the series lose their connexion with the radix and henceforth are supplied by way of the posterior segmental and the vertebral (fig. 324). Anteriorly the vertebral arteries pass to the ventral side of the spinal cord (or medulla oblongata) dividing there into two branches, one

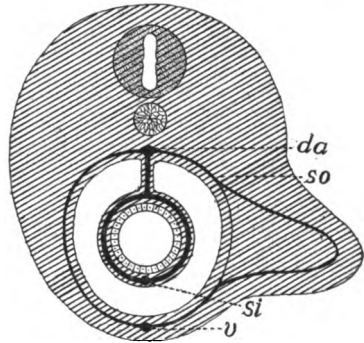


FIG. 325.—Diagram of origin of blood supply of vertebrate appendage. *v*, abdominal vein; *da*, dorsal aorta; *si*, subintestinal vein; *so*, somatic (segmental) vascular arch.

of which, joining its fellow of the opposite side, runs back beneath the spinal cord as a **spinal artery**, while the anterior branches unite in the same way to form a **basilar artery**, running forward beneath the medulla (fig. 324, *B*). At the point just behind the hypophysis the basilar divides, one-half passing on either side of that structure and receiving the internal carotid of that side. The trunks thus formed unite in front in the region of the optic chiasma. There is thus formed an **arterial ring**, the **circle of Willis** (fig. 324, *B*), around the hypophysis.

As the limbs grow out, segmental arteries, corresponding in number to the somites concerned in the appendages, extend into the member. Distally these arteries become connected with each other and with the veins of the limb by a network of small vessels. By enlarge-

ment of parts of these main trunks and of the connecting network (fig. 326), and the partial or complete atrophy of other portions, the definitive circulation of the limb is established. This explains the numerous variations in the blood supply of the limbs, both in the distal parts and in the origin of the main trunks, which may arise from the dorsal aorta or from the radices as far forward as the third aortic arch. This will explain the shiftings of the subclavian artery shown in fig. 319.

The main trunk of the fore limb may have different names in different parts of its course. It is the **subclavian artery** as it leaves the dorsal aorta, the **axillary** as it enters the limb, and the **brachial** in the upper arm. It divides near the elbow into **radial** and **ulnar arteries**, which run near the corresponding bones into the podium.

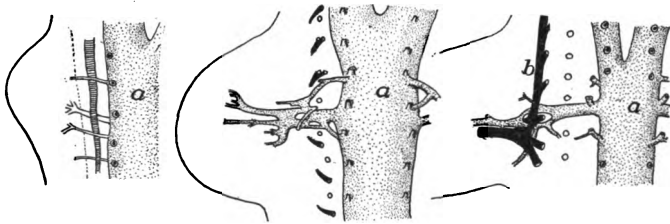


FIG. 326.—Three stages in the development of the arteries of the fore limb of the white mouse, after Göppert. *A*, 8 days; *B*, 9 days; *C*, 10 days; *a*, aorta; *b*, brachial plexus. (The vessels are extremely variable, not agreeing even on the two sides of a single individual.)

There are some additional elements of complexity in the development of the arteries of the hind leg. As in front, several somatic vessels are concerned and there is the same formation of a capillary network. Two of the arteries attain special prominence. In front is the **epigastric artery**, which descends from the aorta to the ventral side of the body and runs forward to supply the lower portion of the myotomes, becoming connected at first with the epigastric veins, although later they may anastomose with the hinder ends of the cutaneous arteries (*infra*). When the hind limb grows out, the epigastric sends a branch, the **external iliac** or **femoral artery**, into its anterior side. As the leg increases in size this may surpass the parent epigastric in size, the latter now appearing as a side branch.

The second pair of somatic arteries are the **sciatic (ischiodic) arteries**. These descend into the posterior side of the leg, the name changing at the angle of the knee to **popliteal artery**, and farther down it divides into **peroneal** and **anterior and posterior tibial** arteries,

the peroneal supplying the calf of the leg, the others continuing into the foot.

The arrangement of vessels thus outlined is characteristic of the lower tetrapoda where the femoral artery is small. It is also characteristic of the embryos of the mammals, but in the latter, before birth, the femoral artery grows down, joins the popliteal, and thus becomes the chief supply of the limb. These trunks and the hypogastric do not always remain distinct, but may fuse in different ways at the base. Epigastric and hypogastric arteries are distinct in many reptiles and in birds, but elsewhere they fuse to form the common **iliac artery**, so called since the proximal portion of the femoral is often called the **external**, the hypogastric the **internal iliac artery**. The sciatic, too, may remain distinct or it may fuse with the others at the base, and then its independent portion appears as a branch of the common iliac artery.

A **cutaneous artery**, arising from either the subclavian or the pulmonary artery of either side (both conditions occur in the amphibia), runs backward in the skin of the trunk, and may extend back and unite with the epigastric artery. When, as in the amphibia, these arise from the pulmonary they contain venous blood and the skin acts as a subsidiary respiratory organ (p. 277).

The arteries going to the excretory and reproductive organs are paired and, in the more primitive vertebrates show a marked metamerism. They are best described in details along with the urogenital structures in a subsequent section. It may be mentioned here that the metamerism is well shown in the **nephridial** or **renal arteries** going to the pro- and mesonephroi, while there is usually but a single pair of renal arteries to supply the metanephroi (true kidneys) of the amniotes. The arteries to the gonads may be included under the single head of **genital arteries**, though they are usually subdivided into the **spermatic** and **ovarian arteries** according to the sex. Like the nephridial, the genital arteries are more numerous in the lower and are reduced in number in the higher forms.

THE VEINS

Continuing from the description of the development of the heart (p. 294), the ventral margins of the lateral plates, posterior to the pericardium are kept from meeting in the middle line by the anlage of the liver (figs. 327, 328). The edges of the plates become grooved in the same way as in front and each groove becomes rolled into a tube, lined with vascular cells, so that two vessels, the **omphalomesenteric veins**, extend back from the heart, around the liver, to meet the extensions of the omphalomesenteric arteries already described. Behind the connexion of these vessels another pair of

tubes, the **subintestinal veins** (fig. 327, *si*) continue back on the ventral side of the alimentary canal, until, just behind the anus, they fuse to a median tube, the **caudal vein**, which extends the length of the tail.

The two subintestinal veins soon fuse to a single median vessel (fig. 331, *B*), save for a loop around the anus connecting it with

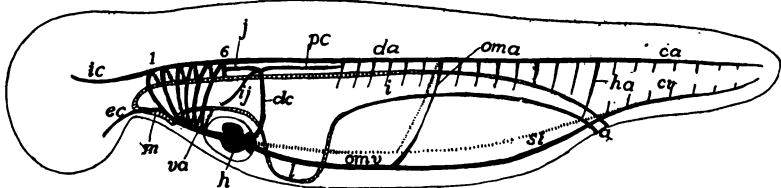


FIG. 327.—Diagram of the circulation in an early stage of a small yolked vertebrate (amphibian). *c*, anus; *ca*, *cv*, caudal artery and vein; *da*, dorsal aorta; *dc*, Cuvierian duct; *ec*, external carotid; *h*, heart; *ha*, hypogastric artery; *i*, intestine; *ic*, internal carotid; *ij*, inferior jugular; *j*, superior jugular; *l*, liver; *m*, mouth; *oma*, *omv*, omphalomesenteric artery and vein; *pc*, postcardinal vein; *si*, subintestinal vein; 1-6, aortic arches.

the caudal vein. This connexion persists in the cyclostomes, but disappears elsewhere. Of the two omphalomesenteric veins, the right soon disappears with the exception of a short distance between the sinus venosus and the liver (fig. 328), leaving the left as the

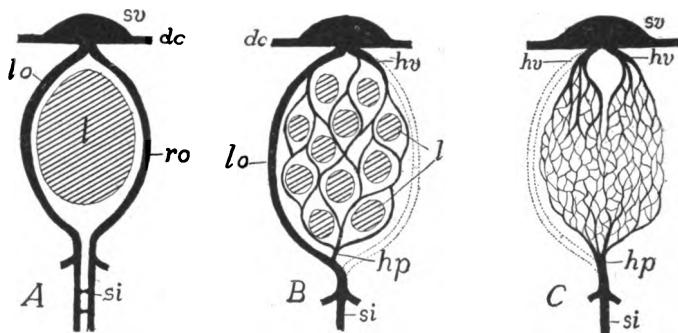


FIG. 328.—Three stages in the development of the hepatic portal system. *A*; primitive; *B*, liver tubules beginning to develop, right omphalomesenteric interrupted; *C*, definitive condition, liver not indicated. *dc*, Cuvierian ducts, *hp*, hepatic portal vein; *hv*, hepatic vein; *l*, liver; *lo*, *ro*, left and right omphalomesenteric veins; *si*, subintestinal vein; *sv*, sinus venosus.

trunk connecting the posterior parts with the heart, this passing along the left side of the liver (fig. 328, *B*).

Portal Circulation.—As the liver develops from the simple sac it is at first, into the compound tubular condition (p. 248), the left omphalomesenteric breaks up into a sort of rete mirabile of sinusoids,

which ramify among the liver tubules, finally connecting with both omphalomesenterics on the anterior side of the liver (fig. 328, *B*). As the liver increases in size the network of sinusoids increases in complexity, supplying all of the tubules. For a time the left omphalomesenteric retains its primitive importance on the side of the liver and is known as the **ductus venosus (Arantii)**, but soon this preeminence is lost and all blood coming from behind passes through the network of capillaries in the liver before it enters the heart (fig. 328, *C*). Such a capillary circulation occurring in the course of a vein is known as a **portal system**, and this one occurring in the liver is the **hepatic portal circulation**. It consists of the vessels bringing the blood to the liver (**portal vein**)—a part of the original omphalo-

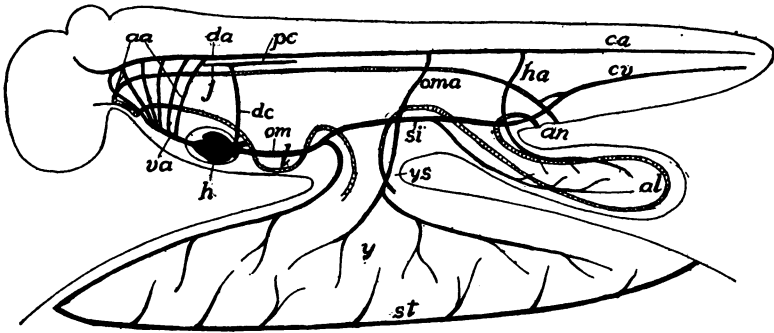


FIG. 329.—Diagram of embryonic circulation in a large-yolked vertebrate; compare with fig. 319. *aa*, aortic arches; *al*, allantois; *an*, anus; *ca*, *cv*, caudal artery and vein; *da*, dorsal aorta; *dc*, Cuvierian duct; *h*, heart; *ha*, hypogastric (allantoic) artery; *j*, jugular vein; *l*, liver; *oma*, *om*, omphalomesenteric artery and vein; *pc*, postcardinal vein; *si*, subintestinal vein; *st*, sinus terminalis; *va*, ventral aorta; *y*, yolk; *ys*, yolk stalk.

mesenteric—the capillary vessels, and the bases of both omphalomesenterics, now known as the **hepatic veins**, which convey the blood from the liver to the heart.

In eggs with a large yolk (elasmobranchs, sauropsida) the presence of this large food supply exercises a modifying influence on these ventral veins (fig. 329). From the junction of the omphalomesenteric and the subintestinal veins a pair of large **vitelline veins** run out into the yolk sac, over the yolk, and play a large part in the transfer of material to the growing embryo. The distal parts of these veins follow the margin of the yolk sac, forming a tube (**sinus terminalis**) into which smaller veins empty. Blood is brought to the yolk by the omphalomesenteric arteries, which are also distributed to the yolk sac, dividing up distally into a network of capillaries connecting distally with the vitelline veins. By these latter the blood is carried to the liver and through the portal circulation to the heart. In the mammals a similar vitelline circula-

tion is developed, but as the yolk sac contains no yolk, it is of minor importance and is soon lost.

In the amniotes an outgrowth, the allantois (p. 285), arises as a diverticulum from the hinder end of the alimentary canal, increases in extent, growing downward and carrying the ventral body wall before it. Branches of the hypogastric arteries, known as the **allantoic arteries**, extend into it (fig. 329) and are connected by capillaries with **umbilical veins** which arise from the sub-intestinal vein behind the vitelline veins. There thus is formed an **allantoic circulation** which is both respiratory and nutritive in character. In the reptiles both of the umbilical veins persist through the foetal life (only one shown in fig. 308), but in birds and mammals one aborts, leaving the other as the efferent vessel of the allantois. With the end of foetal life (at hatching or at birth) both the vitelline and the allantoic circulations disappear, leaving only inconspicuous rudiments.

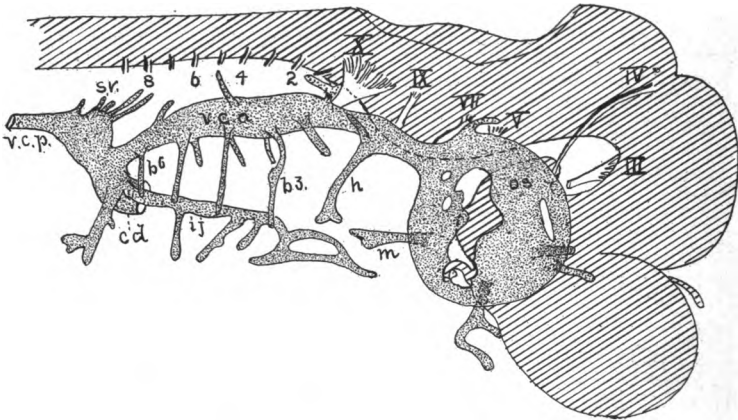


FIG. 330.—Developing anterior veins of *Scyllium* embryo, 26 mm. long; after Grosser. b^3 - 6 veins of the visceral arches; *cd*, Cuvierian duct; *h*, vein of hyoid arch; *ij*, inferior jugular; *m*, vein of mandibular arch; *os*, orbital sinus; *sv*, segmental veins; *vca*, superior jugular; *vcp*, postcardinal; III-X, cranial nerves; 2-8, spinal nerves.

The entrance of the **Cuvierian ducts** into the heart was mentioned on page 294. These ducts are a pair of transverse vessels which enter the sinus venosus, one from either side, and, together with the hepatic veins, mark the posterior limit of the heart. Each develops outside of the somatic wall of the hypomere and extends dorsally until it reaches the level of the top of the cœlom (fig. 327). In this course, in the fishes, each receives an **inferior jugular vein** which comes from the head, bringing back blood from the muscles of the lateral and ventral branchial regions. At its dorsal end each Cuvierian duct divides into the two cardinal veins, a **superior jugular (anterior cardinal)** and a **postcardinal vein** (fig. 330), which belong to the dorsal half of the body. The **superior jugular** comes from the head,

dorsal to the gill clefts and brings blood from the more dorsal regions. Since the inferior jugulars are found only in fishes and salamanders, the anterior cardinal is usually called simply the **jugular** and that usage will be followed here.

The postcardinals are closely related in development to the excretory system, and keep pace with its development backward, so

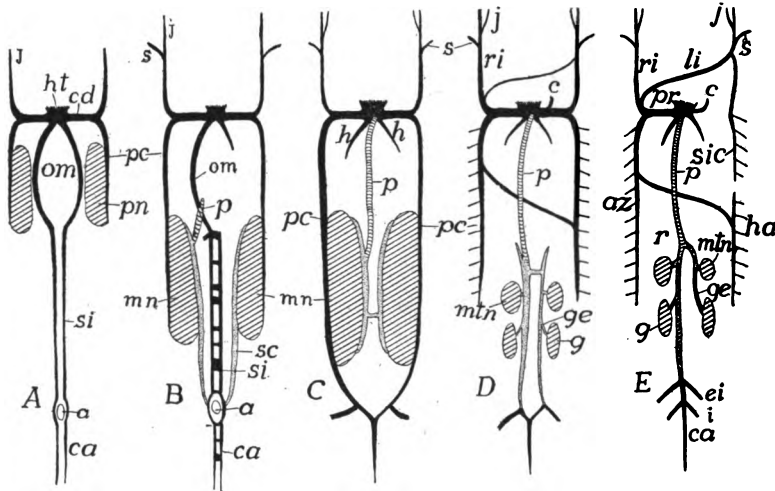


FIG. 331.—Scheme of development of the principal veins. *a*, anus; *az*, azygos major; *c*, coronary vein; *ca*, caudal vein; *cd*, Cuvierian duct; *ei*, external iliac; *g*, gonads; *ge*, genital (spermatic, ovarian) vein; *h*, hepatic veins; *ha*, hemiazygos; *ht*, heart; *i*, ischiadic; *j*, jugular; *li*, left innominate; *mn*, *min*, meso- and metanephroi; *om*, omphalomesenterics; *p*, postcava; *pc*, postcardinal; *pn*, pronephros; *pr*, precava; *r*, renal; *ri*, right innominate; *s*, subclavian; *sc*, subcardinal; *si*, subintestinal; *sic*, superior intercostal.

In *A* the early condition with paired omphalomesenterics and subintestinals, the postcardinals extending back as far as the pronephroi. *B*, mesonephroi developed and with them the subcardinals and the beginning of the postcava; one omphalomesenteric lost and subintestinals and caudals beginning to fuse; the intestinal vessels omitted in the later figures. *C*, postcava has joined sinus and postcardinals have reached caudals; *D*, amniote, appearance of metanephroi (true kidneys) with obsolescence of mesonephroi; the postcardinals lose connexion with caudal, their place being taken by the backward extension of the subcardinals; formation of cross connexions between jugulars and between postcardinals of the two sides. *E*, breaking up of postcardinals and disappearance of left Cuvierian duct, the other being called the precava.

Postcaval elements crosslined; subcardinal, dotted; other veins black.

that they eventually reach the loop which the caudal and subintestinal vein makes in passing around the anus. They run just above the dorsal side of the cœlom and dorsal to the nephridial arteries (p. 307). They are preeminently the blood-drainage system of the early excretory organs and they retain that function throughout life in the lower vertebrates.

Closely associated with the postcardinals are the **subcardinals**.

As the mesonephroi (see Excretory Organs) reach the hinder end of the coelom, the caudal vein loses its primitive connexion with the subintestinal vein and becomes connected with a pair of vessels, the subcardinal veins, which develop between the two mesonephroi and ventral to the nephridial arteries (fig. 331, *B*). The blood from the tail now goes through the subcardinals and from them into the excretory organs, passing through a system of capillaries, to be

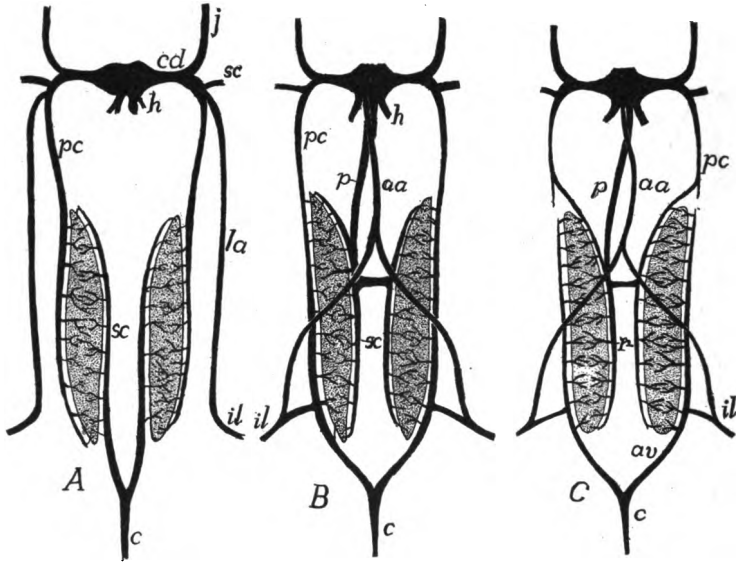


FIG. 332.—Relations and modifications of the post- and subcardinal, abdominal and postcaval veins in different stages of the amphibia. In *A* the veins (*il*) from the hind limb return directly to the heart by the lateral abdominal veins (*la*), while the blood from the tail (*c*) passes by way of the subcardinals (*sc*) through the mesonephroi to the postcardinals (*pc*). In *B* the lateral abdominals have united in front to form the anterior abdominal vein (*aa*); the iliacs have sent a branch to the postcardinals, which have grown back to join the caudals, while the subcardinals have lost their connexion with the caudal and have acquired one with the postcava (*p*), a backward growth from the sinus venosus. In *C* the postcardinals have been interrupted, the posterior half of each now forming an adhevent vein (*av*) while the subcardinals, as in *B*; form the revehent veins (*r*).

gathered again in the postcardinals and by them to be returned to the heart. Here, then, there is another portal system (p. 309), the first **renal-portal** system, which may be modified later, as will be described below.

With the development of the limbs corresponding veins arise (fig. 332), a **subclavian vein** for each fore limb, a **common iliac** for the hind leg, these bringing the blood from the appendage to the trunk. In the young each subclavian empties into the postcardinal

of the same side, but in the adult the opening may shift to the Cuvierian duct or to the jugular. The common iliac vein likewise empties into a vein, the **epigastric** or **lateral abdominal**, which runs forward in the body wall to connect with either the postcardinal or the duct of Cuvier (fig. 332, *A*). This condition obtains throughout life in some elasmobranchs, but higher in the scale the iliac vein, while retaining its connexion with the epigastric, grows toward the middle line and joins the postcardinal of the same side, a condition which

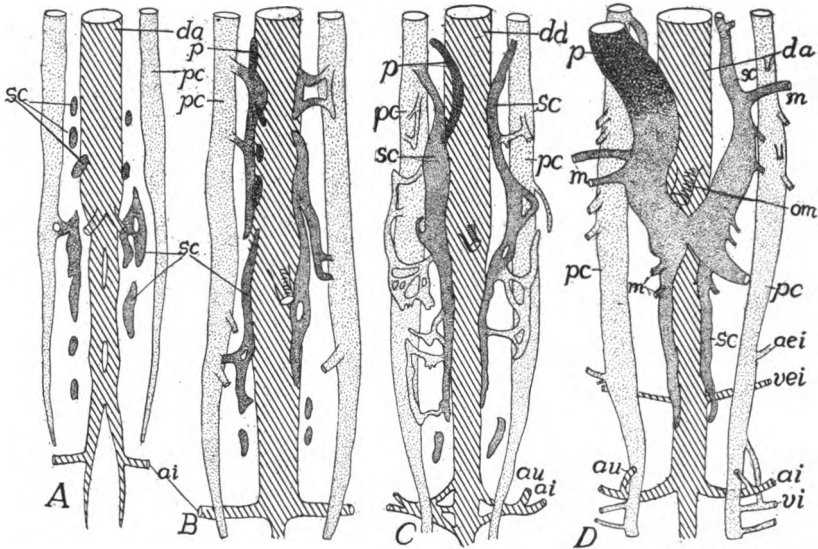


FIG. 333.—Development of postcaval system in birds (*A, B*, sparrow; *C, D*, chick), schematized after A. M. Miller. In *A* the postcardinals have extended nearly to the pelvic region and the subcardinals are appearing as isolated spaces. In *B* the subcardinal spaces are uniting and the capillary system connecting with the postcardinals is developing, while the postcava is arising. In *C* the postcava has united with the subcardinal of the right side. *ai*, ischiadic artery; *aie*, external iliac artery; *au*, umbilical (hypogastric) artery; *da*, dorsal aorta; *m*, mesonephric veins; *om*, omphalomesenteric artery; *p*, postcava and its anlagen; *sc*, subcardinal and its elements; *vei*, external iliac vein; *vi*, ischiadic vein.

is permanent in amphibia and reptiles (fig. 332, *B, C*), where blood coming from the hind limb has two routes to the heart.

The epigastric veins of the two sides may fuse in the median line in front (amphibia, some reptiles, birds), forming an **anterior abdominal vein** (fig. 332, *C*) which reaches the heart by passing through the remains of the ventral mesentery (**ligamentum teres**) to the liver and thence forward. A similar anterior abdominal vein has been described in *Echidna* but is unknown elsewhere in the mammals.

In the fishes the vessels of the appendages are but slightly de-

veloped, there being a subclavian vein entering the Cuvierian duct, and occasionally a **brachial vein** which may empty into the sinus venosus. In the amphibia a **cutaneous magnus vein** (fig. 343), coming from the skin of the trunk, may enter the subclavian, while in all tetrapoda the subclavian, after leaving the limb, receives a superficial **cephalic** and an **axillary vein**, the latter changing its name in the appendage to the **brachial vein**. In the hind limb the com-

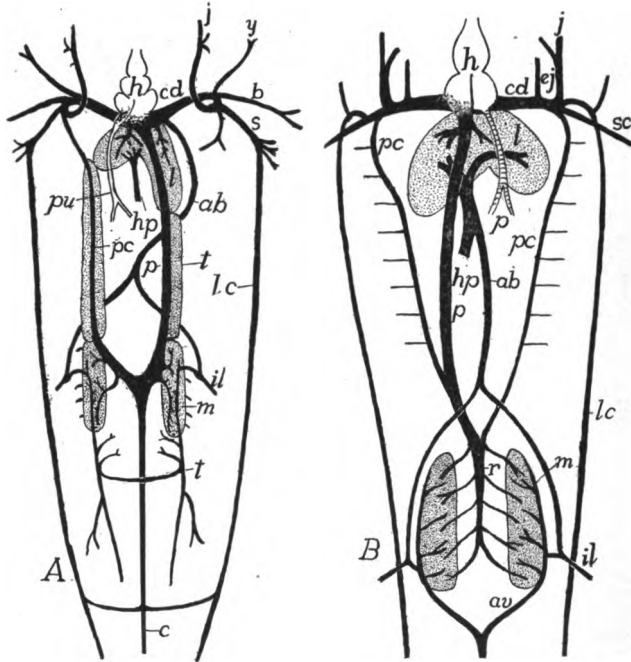


FIG. 334.—*A*, venous system of *Ceratodus*, dorsal view, after Spencer; *B*, of a urodele, ventral view. *ab*, abdominal vein; *av*, venæ advehentes; *b*, brachial; *c*, caudal; *cd*, Cuvierian duct; *ej*, external jugular; *h*, heart; *hp*, hepatic portal; *ij*, inferior jugular; *j*, jugular; *il*, iliac; *l*, liver; *lc*, lateral cutaneous; *m*, mesonephros; *p*, postcava; *pc*, post-cardinal; *r*, venæ revehentes; *s*, subclavian; *t*, testes.

mon iliac vein is formed by the union of the **femoral** and **sciatic (ischiodic) veins**, as well as the hypogastric (**internal iliac**) vein already referred to.

In the classes above fishes (dipnoi, amphibia and amniotes) a new vein, the **postcava (vena cava inferior)** appears. This arises in part from scattered spaces, in part as a diverticulum of the sinus venosus and the hepatic veins, and grows backward, dorsal to the liver, until it meets and fuses with the right subcardinal vein (figs. 332,

333), a portion of which now forms a new trunk, carrying blood from the posterior part of the body to the heart.

With the appearance of the postcava changes are introduced in the embryonic renal portal circulation (p. 312) which may be summarized as follows: The subcardinals lose their connexion with the caudal vein and become connected with each other by transverse vessels (**interrenal veins**), while parts of the postcardinals adjacent to the nephridial organs separate from the parts in front, and grow backward and connect with the caudal vein (fig. 333). These posterior parts of the postcardinals now become the **advehent veins** (fig. 332, C) of a second renal portal system, bringing blood from the tail and hind limbs to the excretory organs (mesonephroi). The subcardinals of the two sides usually fuse in the middle line, a process initiated by the appearance of the interrenal veins, and now act as a **revehent vessel**, carrying blood from the excretory organs to the postcava and the anterior portion of the postcardinals which have joined the anterior ends of the subcardinals (fig. 332, C). The changes in the postcardinals and the renal portal system of mammals will be described below.

In *Ceratodus* (dipnoi, fig. 334, A) there are some differences from the above account. Thus the anterior portion of the right postcardinal (not shown in the figure) loses its connexion with the vessels behind and acts as a **vertebral vein**, taking the blood from the intercostal veins of that side back to the heart. The caudal and the subcardinals form a continuous trunk, the revehent vessels forming side branches. The posterior portions of the postcardinals grow back into the tail as paired vessels, forming no connexion with the caudal vein. In *Protopterus* the vertebral vein is lacking, the subcardinals are not fused behind, while the advehent veins are connected with the caudal.

The development of lungs brings about the appearance of one or more pairs of **pulmonary veins** which carry the (arterial) blood from these organs to the heart. These arise as an outgrowth from the left atrial portion of the heart, dividing farther back to reach the two lungs. At no time do the pulmonary veins connect with the sinus venosus, but they always empty into the left atrium (figs. 322, 334).

The Fœtal Circulation

Some features of the foetal circulation of the amniotes have already been alluded to, but the whole may be summarized here. In the amniotes, with the development of a large yolk sac and of the allantois, the vessels on the ventral side of the body become corre-

spondingly modified. The processes involved may be readily understood from a comparison of figures 327 and 329. The yolk sac is to be regarded as a diverticulum of the intestine while the allantois is a similar outgrowth from the urinary bladder, itself a process of the alimentary canal. These outgrowths naturally carry with them the blood-vessels distributed to the parts from which they arise. Hence the omphalomesenteric artery and the vitelline veins (derivatives of the omphalomesenteric veins) extend out over the yolk, increasing in number as well as in extent of their branches as the yolk sac spreads over the yolk.

In the same way the hypogastric arteries are carried out with the allantois, these portions being called the **allantoic** or **umbilical arteries**, the blood being carried back to the trunk by a single **allantoic vein**. These two kinds of vessels—arteries and veins—are connected in the distal part of the allantois by a rich network of capillary vessels. It is by these that the allantois is able (p. 285) to act in the sauropsida as an organ of respiration. In the mammals, by means of osmosis through the placenta, it is not only respiratory, exchanging gases with the uterine walls (there is no exchange of blood with the mother), but it serves as a recipient of nourishment by the passage of plasma from the maternal tissues.

From the foregoing statements it will be seen that in the sauropsida five vessels—three arteries and two veins—pass out through the umbilicus to the foetal adnexa, but in the mammals, where the yolk is wanting and the yolk sac reduced and transitory in character, the omphalomesenteric artery and the vitelline vein disappear early, leaving but three vessels in the umbilical cord. In the elasmobranchs, where there is a large yolk sac but no allantois, only the yolk sac (omphalomesenteric) circulation is found.

Circulation in the Separate Classes

CYCLOSTOMES present marked differences in the circulation of the two groups, the petromyzons being nearly normal, the myxinoids decidedly aberrant. The aortic arches vary in number with the number of gill pouches (p. 255). In the myxinoids the common carotid is connected with all of the efferent branchials by a trunk running parallel to the body axis, just dorsal to the gill pouches. The intersegmental arteries of the dorsal region are irregular, sometimes alternating, sometimes appearing in pairs on the two sides of the median line. In the lampreys (fig. 335) the subcardinals are united behind, the postcardinals in front, these latter uniting with the single inferior jugular of the left side to form the unpaired Cuvierian duct, the presence of which renders the sinus venosus

asymmetrical and forces the hepatic veins to empty into the right side of the heart (fig. 336). The heart in all cyclostomes has a rudimentary conus. The hepatic portal receives a vein from the head, and then passes back to a contractile portal heart, just before it enters the liver.

FISHES.—In the fishes, the dipnoi excepted, the circulation corresponds rather closely in its main features with the primitive condition or embryonic described above. The purely venous heart is situated in the floor of the pharyn-

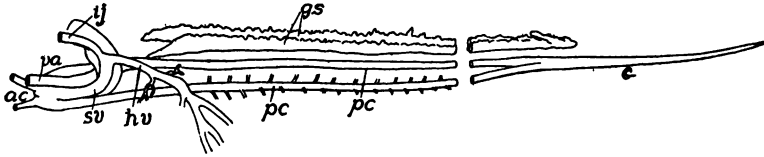


FIG. 335.—Oblique ventral view of venous system of *Petromyzon*, drawn from a corrosion preparation (Princeton, 669); *ac*, precardinal; *c*, caudal; *gs*, genital sinus; *hv*, hepatic vein; *ij*, inferior jugular; *pc*, postcardinal; *sv*, sinus venosus; *va*, ventral aorta.

geal region, between and behind the last pair of branchial arches. The atrium is dorsal to the ventricle. In the elasmobranchs and ganoids the valves of the conu are arranged in several transverse rows (3–8), but in the teleosts (*Butyrinus* and *Osteoglossum* excepted) they are reduced to a single row, apparently corresponding to the first of the lower forms. The aortic arches correspond in number to the functional gill clefts—six or seven in the notidanid sharks, five in other elasmobranchs, and at most four in ganoids and teleosts. The carotids of the two sides are usually connected by a transverse vessel. Paired inferior jugulars are usually present, but they are lacking in *Polypierus*, while in *Lepidosteus* and in many teleosts they are united at the base into a single trunk which empties directly into the sinus venosus. Epigastric veins are usually present, but are lacking in many bony fishes. The elasmobranchs are characterized by the presence of very large sinuses in the postcardinal and hepatic veins. Valves in the veins are common in the elasmobranchs.

DIPNOI.—In this group the atrium, in correlation with the development of lungs, becomes partially divided, as described above (p. 297). No true atrioventricular valves occur, their place being taken by a strong ridge on the inner side of the atrial cavities. This, at the time of systole, closes the canal and at the same time partially divides the ventricle into arterial and venous halves. The spirally twisted conus has eight rows of valves and in *Ceratodus* the short truncus shows the beginning of a division (completed in *Protopterus*) separating the arterial from the venous arches. This separation is effected by a longitudinal fold which may be the result of the fusion of a row of conal valves. In all there are four aortic arches, the anterior two in *Protopterus* receiving arterial blood. The principal veins are shown in fig. 334, the most important features

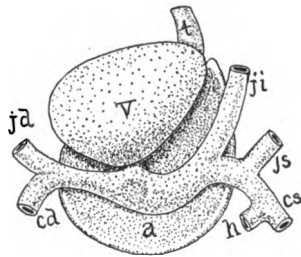


FIG. 336.—Heart of lamprey, after Röse. *a*, atrium; *cd*, *cs*, left and right postcardinals; *h*, hepatic vein; *jd*, right jugular; *ji*, *js*, inferior and superior left jugulars; *t*, truncus arteriosus; *v*, ventricle.

being the development of the postcava, the rudimentary right postcardinal, and the fact that the hepatic veins empty into the sinus venosus and not into the postcava as in the amphibia (fig. 339).

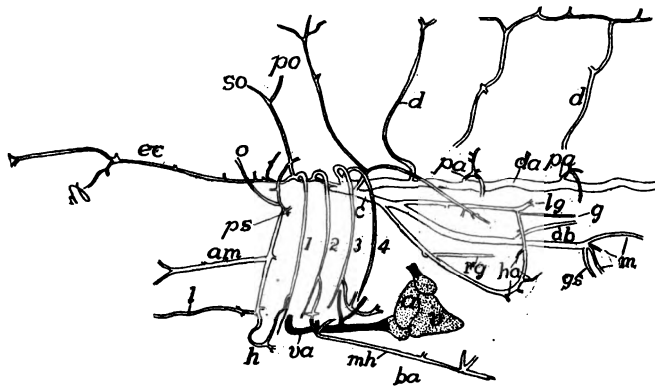


FIG. 337.—Anterior arterial vessels of the tile fish (*Lopholatilus*), after Silvester. *a*, atrium; *ab*, to air bladder; *am*, to angle of mouth; *c*, celiac axis; *d*, dorsal arteries; *da*, dorsal aorta; *ec*, external carotid; *g*, genital artery; *gs*, gastrosplenic; *h*, hyoid artery; *ha*, hepatic; *l*, lingual; *lg*, left gastric; *m*, mesenteric; *mh*, middle hypobranchial; *o*, ophthalmic; *pa*, parietal; *po*, postorbital; *ps*, pseudobranch; *rg*, right genital; *so*, supraorbital; *v*, ventricle; *va*, ventral aorta.

AMPHIBIA.—In the amphibia the heart is carried back into the trunk, to an extent not found in any of the fishes, and it shows another advance in development in having the atria in front of the ventricle, a condition which reappears

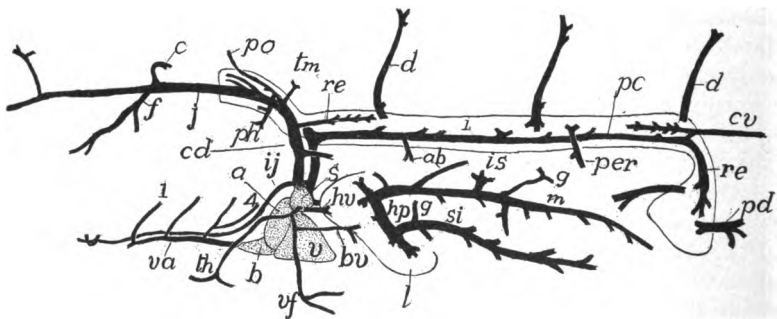


FIG. 338.—Anterior venous system and heart of *Lopholatilus*, after Silvester. *a*, auricle; *ab*, veins from air bladder; *b*, bulbus; *bv*, brachial vein; *c*, cerebral vein; *cd*, Cuvierian duct; *cv*, caudal vein; *d*, dorsal branches of parietal veins; *f*, facial vein; *g*, gastric veins; *hp*, hepatic portal; *hv*, hepatic veins; *i*, outline of mesonephros; *ij*, inferior jugular; *in*, *is*, veins from intestine and spleen; *j*, jugular; *l*, liver; *m*, mesenteric vein; *pe*, postcardinal; *pd*, postcloacal; *per*, peritoneal; *ph*, pharyngeal; *po*, postorbital; *re*, anterior revehentes; *s*, sinus venosus; *si*, veins from stomach and intestine; *th*, thyreoid; *tm*, thymus; *v*, ventricle; *va*, ventral aorta; *vf*, vein from ventral fin.

in all of the higher vertebrates. The division of the primitive atrium by a septum atriorum is carried farther than in the dipnoi. This septum is fenestrated in the urodeles and gymnophiona, entire in the anura, but in none does it extend

clear to the ventricular wall. In systole the edge of the septum is forced forward, completely separating the two atria. No corresponding septum is developed in the ventricle, but numerous muscular trabeculæ extend through the ventricular cavity which tend to prevent the mingling of arterial and venous blood. Conditions differ in the lungless urodeles (p. 277), there being no atrial septum, the whole heart being venous as in fishes. In *Proteus*, *Cryptobranchus*, and cæcilians the arterial bulb and trunk are simple, but in many other urodeles and in anura they are spirally twisted and the bulb contains a spiral fold or septum (fig. 340) which possibly is the result of fusion of valves. This fold separates the trunk into two tubes. This division is continued in

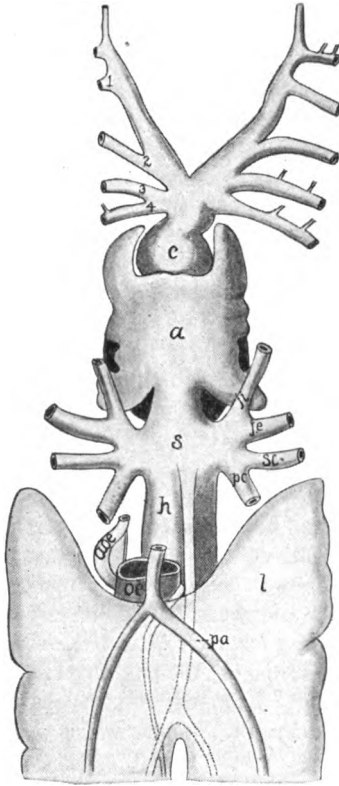


FIG. 339.

FIG. 339.—Heart and adjacent parts of *Proteopterus*, after Röse. *a*, atrium; *aoe*, oesophageal artery; *l*, air bladder (lung); *c*, conus; *h*, hepatic vein; *ji*, *is*, superior and inferior jugular veins; *oe*, cesophagus; *pa*, pulmonary artery; *pc*, postcardinal vein; *ph*, pharyngeal artery; *s*, sinus venosus; *sc*, subclavian vein; 1-4, afferent branchial (aortic) arteries.

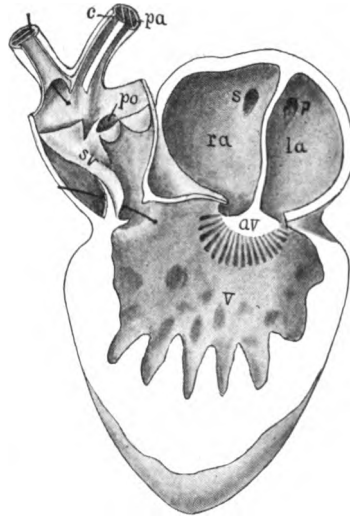


FIG. 340.

FIG. 340.—Heart of frog laid open, based on figures by Bourne. *av*, atrioventricular valve; *c*, carotid; *la*, left atrium; *p*, opening of pulmonary vein into atrium; *pa*, pulmonary arch, connected with bulb at *po*; *ra*, right atrium; *s*, opening of systemic veins into atrium; *sv*, spiral valve in bulb; *v*, ventricle.

the anterior part of the truncus by a horizontal septum (short in urodeles, longer in anura) separating aortic and pulmonary trunks, the former subdivided in a similar way a little farther forward into carotid and aortic portions.

In the early amphibian larvæ each fully developed aortic arch except the last (morphological sixth) extends into the gills, but as the branchiæ begin to be absorbed, a small vessel connecting the bases of the afferent and efferent arteries

enlarges and becomes the path of the main blood stream and a part of the arch of the adult (fig. 341). Of the four arches (3, 4, 5, and 6 of the primitive scheme) the fifth is lost in the adults of all except a few urodeles and cæcilians. The fourth connects with the dorsal aorta and the sixth with the pulmonary arteries. These last, which have a Botall's duct on one or both sides in some urodeles, are noticeable for the large cutaneous arteries—anterior and posterior—which arise from them in the anura, and which play an important part in respiration. Connected with the carotid arteries are the carotid glands (p. 264). In the larval stage each consists of a network of blood-vessels—a rete mirabile—between the afferent branchial and the carotid arteries, but in the adult this degenerates into a small muscular organ containing sympathetic cells at the junction of external and internal carotids. The caudal artery and vein entirely disappear in the adult anura.

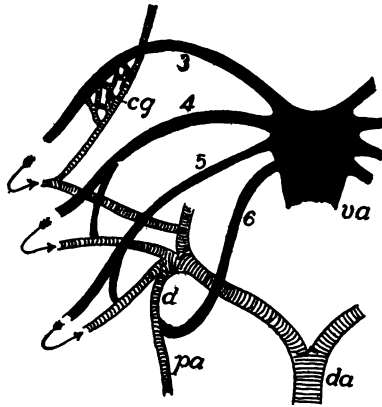


FIG. 341.—Diagram of the aortic arches in amphibia. Arterial blood cross lined, venous black. The gill circulation omitted, its course indicated by arrows; the permanent circulation after the absorption of gills shown. *cg*, carotid gland; *da*, dorsal aorta; *d*, ductus Botalli; *pa*, pulmonary artery; *va*, ventral aorta; 3-6, aortic arches.

The postcava is always well developed and the epigastric (lateral abdominal) veins unite to form an anterior abdominal vein (fig. 332) so that the blood from the hind limbs may return to the heart through either the anterior abdominal and the hepatic portal system or the renal portal system and the postcava.

In the lungless salamanders the heart and blood-vessels show correlated modifications. Those of the heart were mentioned above. The pulmonary arteries and veins fail to develop, but the cutaneous arteries and the smaller vessels supplying the pharyngeal region are greatly enlarged, respiration being effected by the skin and the mucous membrane of the throat.

The action of the anuran heart may be outlined here. The two atria, filled with blood, contract at the same time, forcing arterial and venous blood into the ventricle, but these are kept from mixing by the muscular trabeculæ already mentioned. At the systole of the ventricle, the venous blood, which lies nearest the bulbus, is first forced forward. This takes the most direct course through the wide and shorter pulmonary arteries which are practically empty at the time. The next portion of the blood—mixed arterial and venous, follows the next easiest course through the aortic arches, while the last to leave the ventricle, consisting of pure arterial blood, can only go to the carotids, where the resistance is greater on account of the small size of the vessels and the obstacles presented by the carotid glands.

REPTILES.—The circulation in the reptiles shows several advances over that in the amphibia. The division of the heart is carried into the ventricle and the sinus venosus is not visible from the exterior, though valves at the en-

trance of the veins into the atrium show that it has not entirely disappeared. The atrial septum is complete and is continued forward into the ventricle, partially (*Sphenodon*, turtles, squamata) or completely (crocodiles, fig. 342, *B*) separating it into arterial and venous halves. The arterial trunk often shows a spiral twist (fig. 346).

The eculiar relations of the aortic arches have already been mentioned (p. 301; fig. 319, *E*, *F*), but it should be mentioned that there is often a connexion between the right and left fourth aortic arches—the foramen of Panniza (fig. 342, *B*), so that blood can pass from one side to the other. It is stated that with quiet breathing blood goes from the right arch into the left; with rapid respiration the flow is in the other direction. But under ordinary conditions the blood in the right arch is predominantly arterial, that in the left largely venous. As

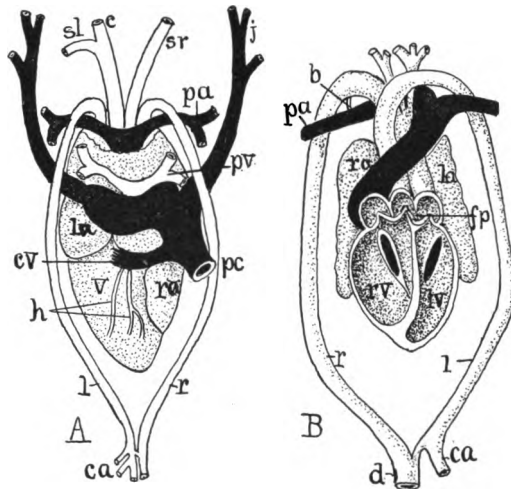


FIG. 342.—*A*, dorsal view of heart of crocodile, after Röse; *B*, ventral scheme of heart laid open, after Greil. *b*, remnants of Botall's duct; *c*, carotid trunk; *cv*, cardinal vein; *ca*, coeliac artery; *d*, dorsal aorta; *fp*, foramen Panizzæ; *h*, coronary arteries; *j*, jugular vein; *l*, left aortic arch; *la*, left atrium; *lv*, left ventricle; *pa*, pulmonary artery; *pc*, postcava; *pv*, pulmonary vein; *r*, right aortic (fourth) arch; *ra*, right atrium; *rv*, right ventricle; *sl*, *sr*, left and right subclavian arteries; *v*, ventricle.

the latter is the chief supply of the alimentary canal (fig. 342, *ca*) this is not physiologically as anomalous as it would at first sight appear. Correlated with these differences of the fourth arch on the two sides is the fact that both of the subclavian arteries arise from the left arch, while usually these are united with the carotids, so that subclavians and carotids form for a distance a common trunk, the brachiocephalic artery. In the snakes the subclavians are lost, while in the same group and in the snake-like lizards one of the pulmonary arteries disappears along with the degeneration of the corresponding lung.

In many reptiles the anterior parts of the postcardinal veins are replaced by the vertebral veins and the blood from the excretory organs is wholly returned to the heart by the postcava. That from the posterior parts of the body can return either by the renal portal system (fig. 347) or by the paired abdominal

veins and the hepatic portal system. The vertebral, or unpaired, veins, just alluded to, unite with the subclavian and the jugular of the same side to form a common trunk (really the Cuvierian duct) which is here called the precava (vena cava anterior) the postcava being the vena cava posterior.

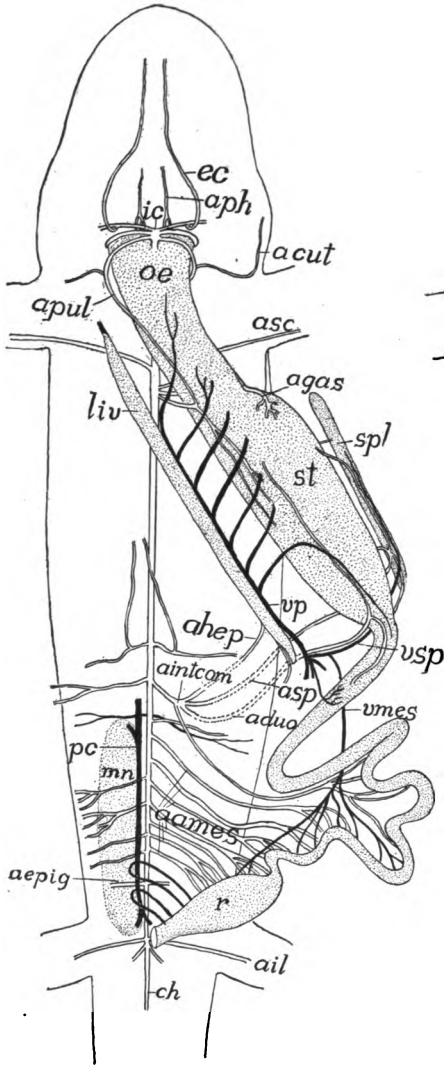


FIG. 343.

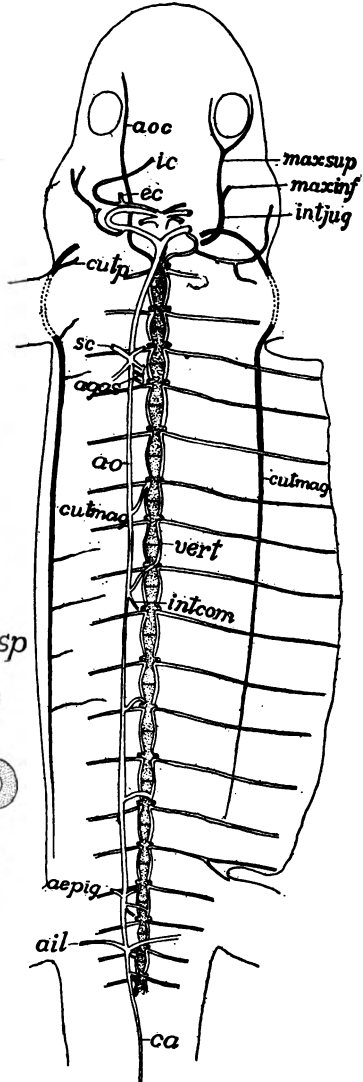


FIG. 344.

BIRDS.—There is a complete division of the heart and arches in the birds, and the right arch alone of the fourth primitive pair connects in the adult with the dorsal aorta. There is the same formation of brachiocephalic arteries as was

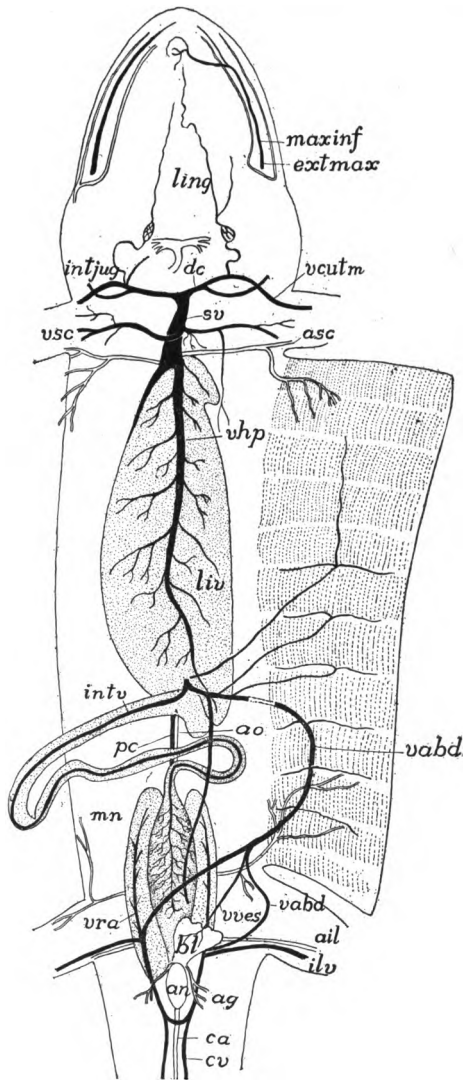


FIG. 345.

FIGS. 343, 344, 345.—Circulatory system of *Desmognathus fuscus*, after Miss Seelye; fig. 343, superficial vessels; fig. 344, deeper vessels; fig. 345, vessels of the dorsal body wall; all from the ventral surface. *ames*, mesenteric arteries; *acut*, cutaneous artery; *aduo*, duodenal artery; *aepig*, epigastric artery; *ag*, artery to anal gland; *agas*, gastric arteries; *ahep*, hepatic artery; *ail*, iliac artery; *aintcom*, common intestinal artery; *ao*, aorta; *aoc*, ocular artery; *aph*, pharyngeal artery; *an*, anus; *apul*, pulmonary artery; *asc*, subclavian artery; *asp*, splenic artery; *bl*, urinary bladder; *ca*, caudal artery; *cutmag*, cutaneous major vein; *cutp*, cutaneous parva vein; *cv*, caudal vein; *ec*, external carotid; *extmax*, external maxillary; *ic*, internal carotid; *ilv*, iliac vein; *intcom*, common intestinal; *intjug*, internal jugular; *intv*, intestinal vein; *ling*, lingual; *liv*, liver; *maxinf*, maxillary, inferior and superior maxillaries; *mn*, mesonephros; *æ*, oesophagus; *pc*, postcava; *r*, rectum; *spl*, spleen; *st*, stomach; *sv*, sinus venosus; *vabd*, abdominal vein; *vcut*, cutaneous vein; *vhp*, hepatic vein; *veri*, vertebral artery; *vmes*, mesenteric vein; *vsp*, portal vein; *vra*, vena renalis advehentis; *vsp*, splenic vein; *vves*, vein from bladder.

noted in the reptiles. In the heart the right ventricle is crescent-shaped in horizontal section, and it tends to embrace the other. In both there is but slight development of the muscular trabeculæ. The conus and the sinus are lost. The truncus is completely divided (fig. 348, *A*), the arch coming from the left ventricle connecting with the right fourth arch, which alone reaches the dorsal aorta in the adult, the left of the pair continuing only as far as the origin of the subclavian of that side. There is the same disappearance of the post-cardinals as in reptiles, while the iliac veins extend to the postcava (fig. 348, *B*).

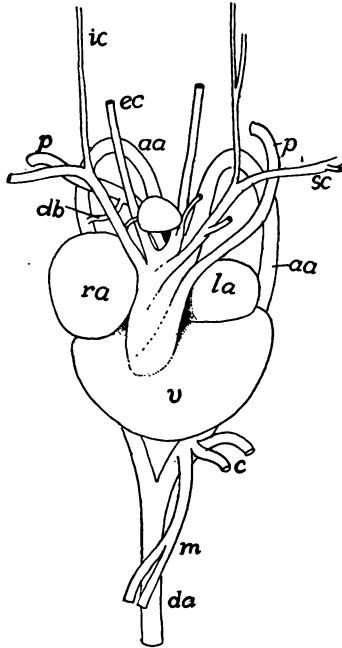


FIG. 346.

FIG. 346.—Heart of snapping turtle, *Chelydra serpentina* (Princeton, 479). *aa*, aortic arch; *c*, coeliac artery; *da*, dorsal aorta; *db*, Botall's duct; *ec*, *ic*, external and internal carotids; *la*, left auricle; *p*, pulmonary artery; *ra*, right auricle; *sc*, subclavian artery; *v*, ventricle; *m*, mesenteric artery.

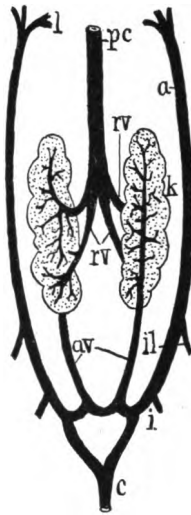


FIG. 347.

FIG. 347.—Posterior veins of alligator, after Gegenbaur. *a*, lateral abdominal; *av*, advehent veins; *c*, caudal; *i*, ischiadic; *i'*, iliac; *i''*, iliac; *k*, kidney; *l*, entrance of lateral abdominal into liver; *pc*, postcava; *rv*, revehent veins.

The right jugular vein is larger than the left, which is sometimes completely closed.

MAMMALS.—In the mammals the two sides of the heart are completely separated, and the sinus is merged in the right atrium, the sinuatrial valves being rudimentary (*valvulæ Eustachii* and *Thebesi* in the base of the postcava and the coronary vein respectively). In the monotremes both atrioventricular valves consist of three cusps, but elsewhere the right is tricuspid, the left bicuspid. The persistent left aortic arch forms the only connexion between the heart and the dorsal aorta, and from its arch the subclavian and carotid arteries

arise. In their arrangement almost every conceivable condition may occur (fig. 349), brachiocephalic arteries on one or both sides being common.

The renal portal system (best developed in the monotremes) has but a transitory existence, disappearing early with the degeneration of the mesonephroi

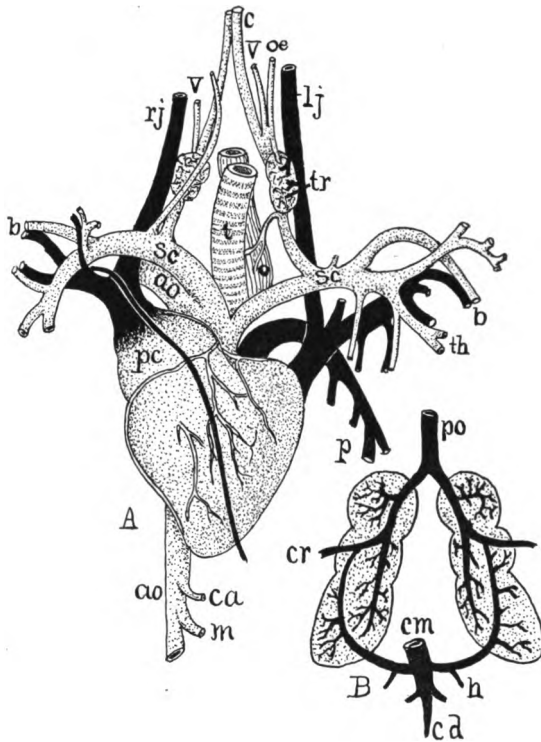


FIG. 348.—*A*, Heart and adjacent vessels of swan, after Gadow; *B*, renal circulation of bird, after Gegenbaur. *ao*, aorta; *c*, carotid; *ca*, coeliac artery; *cd*, caudal vein; *cm*, coccygeo-mesenteric vein; *cr*, crural vein; *h*, hypogastric vein; *lj*, left jugular; *o*, oesophagus; *oe*, oesophageal artery; *p*, pulmonary artery; *pc*, precava; *po*, postcava; *rj*, right jugular; *sc*, subclavian artery; *t*, trachea; *th*, thoracic artery; *tr*, thyroid; *v*, vertebral artery.

(Wolffian bodies). As these organs disappear a part of the capillary system of the Wolffian bodies enlarges and forms a main trunk connecting the postcava

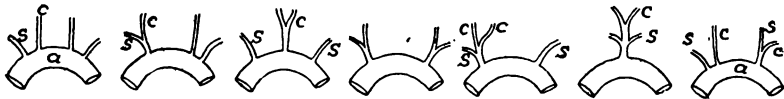

FIG. 349.—Modifications of the origin of the carotid and subclavian arteries in mammals.

with the posterior parts of the postcardinal veins (fig. 350, *C*) which bring the blood from the tail, the iliacs and the permanent kidneys. With farther development (*D*, *E*) the left postcardinal is largely lost (except the part connecting with

the suprarenal and gonad of that side), and all the blood from the posterior part of the body is returned by the right postcardinal and the postcava, which appear

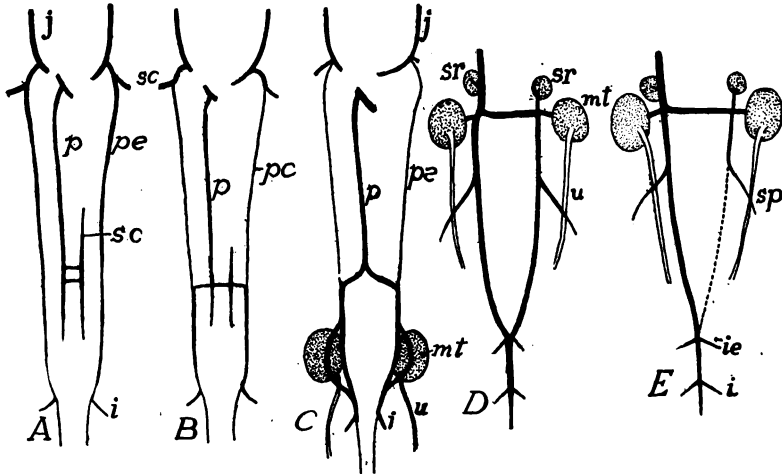


FIG. 350.—Development of posterior veins of rabbit, after Hochstetter. *C* and *D* represent only the hinder part of the whole shown in *A* to *C*. In *B* the veins for the postcaval-subcardinal system have tapped the postcardinal veins, which in *C* have lost their connexion with the anterior part and empty now through the postcava exclusively. In *E* the left posterior postcardinal is entirely lost. *i*, ischiadic vein; *ie*, external iliac; *j*, jugular; *mt*, metanephros (kidney); *p*, postcava; *pc*, postcardinal; *s*, subclavian; *sc*, subcardinal; *sr*, suprarenal; *u*, ureter.

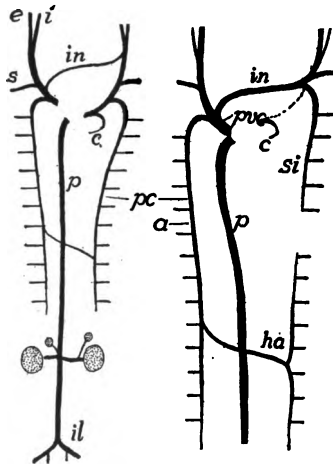


FIG. 351.—Development of the anterior veins of a mammal. *A*, earlier stage, to be compared with fig. 350 *C*; *B*, definitive condition of adult. *a*, azygos; *c*, coronary; *e*, *i*, external and internal jugular; *ha*, hemiazygos; *il*, iliac; *in*, innominate; *p*, postcava; *pc*, postcardinal; *prec*, precava (superior vena cava); *si*, superior intercostal veins.

(fig. 351, *A*) as if they arose from a union of the iliac veins. Correlated with these changes in the venous system and the impossibility of venous blood enter-

ing the excretory organs, there is developed a renal artery from the aorta for each of the permanent kidneys.

The anterior parts of both subcardinals separate from the portions formerly connected with the excretory organs and are henceforth known as the azygos vein on the right side, the hemiazygos on the left. Farther, either the azygos or the hemiazygos may disappear, or, as in man, the hemiazygos may be interrupted and the blood from the hinder part be returned to the heart by way of a cross connexion (fig. 351) and the azygos of the right side. In such a case the anterior part of the hemiazygos is called the superior intercostal vein. The abdominal veins are important in foetal life, bringing blood from the placenta to the embryo.

In the lower vertebrates (monotremes, marsupials, ungulates, insectivores and bats) the Cuvierian ducts of both sides persist as in the non-mammalian classes. In whales, edentates, carnivores and primates an innominate vein extends across from the carotid-subclavian trunk of one side to the other (fig. 351, B) so that all of the blood is returned to the heart by means of the base of the right trunk, now known as the precava (vena cava anterior). All that persists of the left Cuvierian duct is the coronary vein, returning blood from the wall of the heart to the right atrium.

THE LYMPHATIC SYSTEM

The lymphatic system consists of (1) a series of lymph-vessels which penetrate all parts of the body; (2) of pulsating portions of these vessels, the **lymph hearts**; and (3) peculiar aggregates of connective tissue, leucocytes and lymph-vessels which are grouped under the general head of **lymph glands**.

There are different views as to the morphology of the blood and lymph systems. According to one (Marcus) the lymph-vessels were primitively connected with the coelom and have only secondarily come into relations with the blood-vascular system. Others think that both blood- and lymph-vessels have arisen from extracœlomic spaces, from which, by modification and specialization, the two systems have been differentiated. The fact that in many invertebrates there is but a single system, best compared with the lymph system of the vertebrates, and that, even in the crustacea, lymphatic and blood systems are but partially differentiated, is of interest in this connexion.

The lymph-vessels are, in part, capillary in character, with walls of endothelium. The larger ducts and still larger sinuses are strengthened by the same layers of smooth muscle fibres and elastic and fibrous tissue as occur in the blood-vessels (p. 288). The capillaries have numerous anastomoses, but the larger vessels are said to terminate blindly, while, at least in the higher vertebrates, some may connect with the coelom by minute openings (**stomata**) in the peritoneal wall. In the mammals and, to a less extent in the birds, the

larger vessels have valves at intervals to prevent the backflow of the lymph, these valves often giving the vessels a nodulated appearance. Proximally the lymph-vessels empty at two or more points into the veins. The fluid portion of the lymph is derived in part by osmosis from the walls of the blood capillaries, in part from the alimentary canal.

The development of the lymph-vessels has been traced mainly in birds and mammals (chiefly in the latter), with fewer observations on amphibia and other classes. Many points remain to be worked out, there being considerable differences in the various accounts. Apparently the process in its main features is as follows:

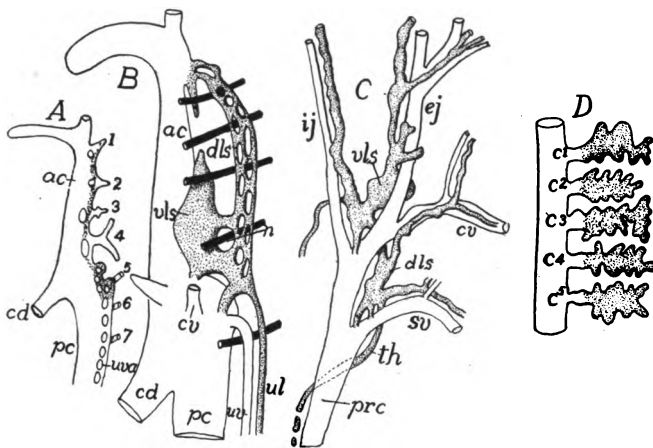


FIG. 352.—Early development of the lymph-vessels in the cat, after McClure and Huntington. *A*, in 6.5 mm. embryo; *B*, in 10.5 mm. embryo; *C*, definitive stage; *D* diagram of developing diverticula of chick which are to form lymph heart, based on Sala. *ac*, anterior cardinal vein; *c*¹⁻⁷, coccygeal veins; *cd*, Cuvierian duct; *cv*, cephalic vein; *dls*, dorsal veno-lymphatic sinus; *ej*, *ij*, external and internal jugulars; *prc*, precava; *th*, thoracic duct; *ul*, primitive ulnar lymphatic; *uva*, anlage of ulnar vein; *vls*, ventral veno-lymphatic sinus; 1-7, segmental vessels; lymphatic-forming tissue stippled.

Near the junction of pre- and postcardinals on either side numerous small diverticula are given off from the lateral side of these veins (fig. 352, *A*). These diverticula unite with each other, forming small tubes parallel to the parent vessels and united to them for a time at numerous points where the budding took place. Later these connexions are lost and the tubes are separated from the veins (fig. 352, *B*) forming an **anterior cephalic duct**, extending forward, parallel to the jugular vein; an **ulnar lymphatic duct** destined to grow into the fore limb; and, a little later, a **thoracic duct** grows back, parallel to the postcardinal vein. All of these vessels are united near their

point of origin by a large sinus, the **jugular lymph sac** (fig. 352, C). Later the lymph sac reestablishes communication at one or two points in the subclavian-jugular region with the vein.

The conditions at the posterior part of the body are less certainly known (fig. 352, D). A **cistern of chyle** (a mesenterial lymph sac) and a **posterior lymph sac** develop in close connexion with the post-cava in the region of the nephridial organs, and it is possible that a portion of the thoracic duct grows forward from the cistern of chyle, while other vessels grow into other regions. Later the primitive

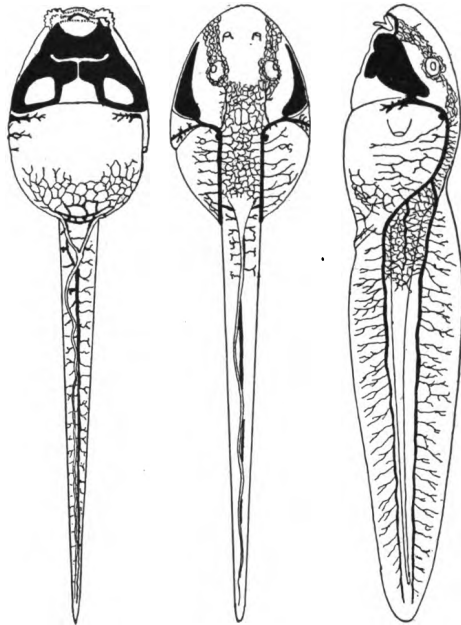


FIG. 353.—Superficial lymph-vessels of a tadpole of a frog, after Hoyer.

trunks thus outlined give off branches which gradually extend into all parts of the body, but of their development little is known. Anastomoses occur between the vessels of the two sides of the body and not infrequently the thoracic duct of one side shows more or less degeneration, resulting in a lack of symmetry in the adult.

Not enough is known of the distribution and development of the chief lymphatic vessels in other animals to render broad generalizations possible, but it can be said that in all groups the system is most extensively developed in the subcutaneous tissue (fig. 353), in the meninges of the central nervous system, in the intermuscular con-

nective tissue, in the mesenteries and the walls of the alimentary canal, and as a network in close relation to the blood-vessels in all parts of the body.

The **lymph hearts** are enlarged portions of the lymph-vessels which have contractile walls, are provided with valves to prevent backflow of the fluid and which force the lymph into the veins. Usually they are near the entrance of the lymph-vessels into the veins. In most cases these hearts contract by means of the intrinsic muscles of the walls, but in some urodeles (*Amblystoma*, *Salamandra*, fig. 354, *A*) there is an unpaired lymph heart beneath the truncus arte-

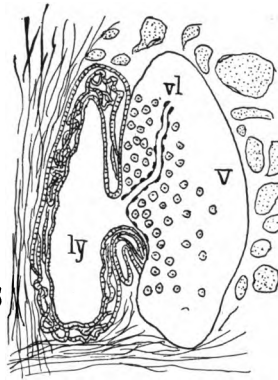
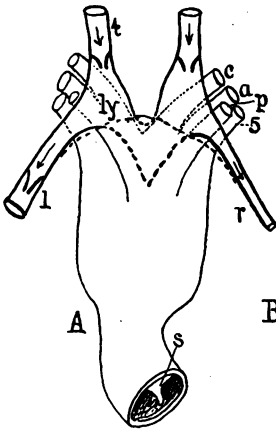


FIG. 354.

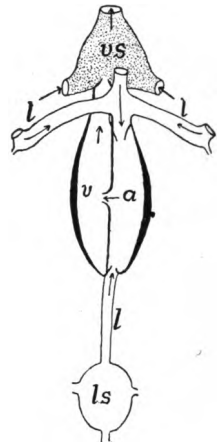


FIG. 355.

FIG. 354.—*A*, truncus and cardiac lymph heart of *Salamandra*, after Greil; *B*, entrance of lymph-vessel into a vein, after Weliky. *a*, aortic arch; *c*, carotid; *l*, left revehent lymph-vessel; containing valves; *ly*, lymph heart; *p*, pulmonary arch; *r*, right revehent lymph-vessel; *s*, spiral valve of truncus; *l*, advehent lymph-vessel; *v*, vein; *vl*, valve at entrance of lymph into vein; *5*, fifth aortic arch. In *A* the heavy dotted line indicates the anterior extent of pericardium.

FIG. 355.—Scheme of caudal lymph heart of teleost, after Favaro. *a*, atrium; *l*, lymph vessels; *ls*, lymph sinus; *v*, ventricle; *vs*, venous sinus of caudal vein.

rius in such relations that it enlarges and contracts with the systole and diastole of the blood-vessels.

As was intimated above there is a constant osmosis of fluid from the blood capillaries into the surrounding tissues. This finally passes into the distal capillaries of the lymph system, while in the walls of the alimentary canal there are, in addition, the results of the digestive processes added to the fluid in the lymph-vessels. As this latter portion has a milky appearance, due to the contained fat, it is called **chyle** and the lymphatics which contain it are called **lacteals** and **chyle ducts**. All of these additions to the contents of the lymph-

vessels make a current in the larger lymph trunks, and finally the whole of the lymph is returned to the veins by the several connexions already mentioned. In addition to the propelling force of the lymph hearts and the pressure due to absorption and osmosis, the lymph is also carried along by the motions of the parts in which the vessels ramify, their pressure being supplemented by the action of the valves.

In all fishes which have been accurately studied the lymph system is well developed (fig. 356), consisting of numerous trunks running through the body

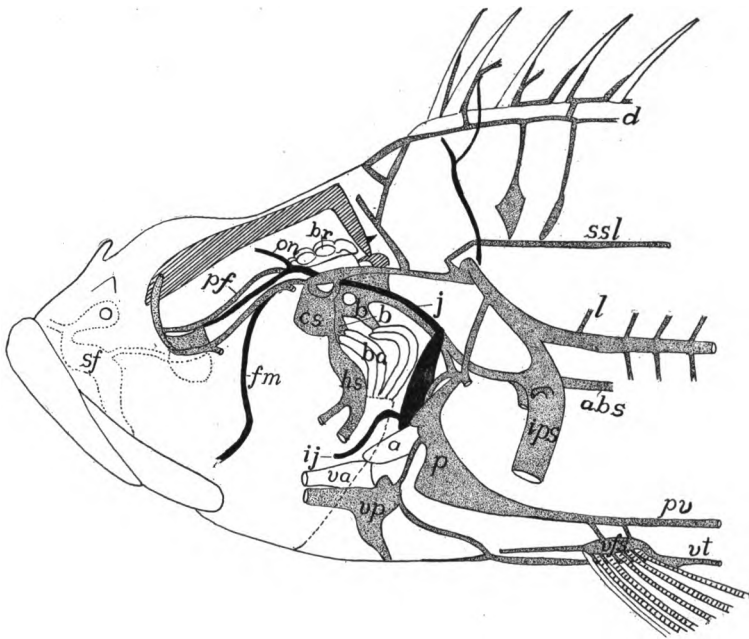


FIG. 356.—Deeper anterior lymphatics (stippled) of *Scorpenichthys*, after Allen. *a*, auricle; *abs*, abdominal sinus; *b*, brachial sinus; *br*, brain; *cs*, cephalic sinus; *d*, dorsal trunk; *fm*, facialis-mandibularis vein; *hs*, hyoid sinus; *ij*, inferior jugular vein; *ips*, inner pectoral fin sinus; *j*, jugular vein; *l*, lateral trunk; *on*, orbito-nasal vein; *p*, peri cardiacal sinus; *pf*, profundus facialis lateral trunk; *pv*, profundus ventral trunk; *sf*, superficial lateral trunk; *ssl*, superior spinal longitudinal trunk; *v*, ventricle; *va*, ventra aorta; *vps*, ventral fin sinus; *vp*, ventral pericardial sinus; *vt*, ventral abdominal trunk.

and head, these connecting with unpaired sinuses in connexion with the dorsal and anal fins and between the pectorals. The system opens into the veins in both the cardiac and the caudal and cardiac regions. In the caudal region (teleosts, myxinoids) are larger cavities which are usually regarded as lymph hearts, but this interpretation has been doubted in the case of the teleosts. The mechanism of the caudal heart may be understood from figure 355.

In the urodeles there are two subvertebral trunks, united behind, but separate in front, which empty into the corresponding subclavian veins. Into these

trunks a cephalic trunk on either side empties. More superficial is a trunk on either side which follows the lateral line, and connected with this are a series of lymph hearts, from fourteen to twenty in number. In the anura (frog) is the replacement of the ordinary tubes by large spaces, some superficial, some deep in the body, into which the lymph capillaries empty. These are connected with each other, while they are connected with the veins by openings into the vertebral branch of the internal jugular and into the iliac, there being lymph hearts connected with each of these openings. The anterior lymph hearts lie between the transverse processes of the third and fourth vertebræ, the caudal lateral to the end of the urostyle. In the anuran tadpole there are additional hearts in the trunk which follows the lateral line. The cæcilians are stated to have a pair of lymph hearts for each segment of the trunk.

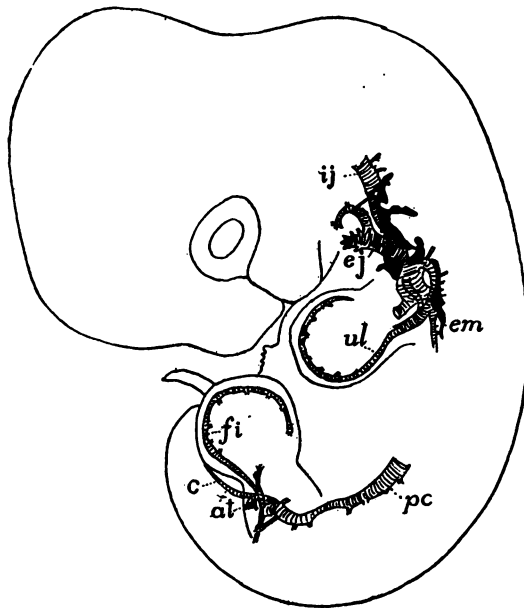


FIG. 357.—Early lymph system (black) of 10 mm. rabbit embryo, after F. T. Lewis. *at*, anterior tibial; *c*, caudal; *fi*, primitive fibular; *ej*, *ij*, external and internal jugular; *em*, external mammary; *pc*, postcardinal; *ul*, primitive ulnar veins.

In the reptiles there is a well-developed subvertebral lymph trunk, which is said in some cases to envelope the adjacent blood-vessels, dividing in front to empty into both brachiocephalic veins. Behind there is a connexion with the ischiadic and renal veins. Near this point, usually just posterior to the dorsal end of the ilium, there is a lymph heart on either side. The vessels are numerous and very large in snakes, and a pair of lymph hearts occur in the same relative position as in other orders. In the birds there are paired main vessels (thoracic ducts) united behind, and there are two pelvic hearts, which, however, are not contractile in the adult ratites and disappear from the adults of other groups.

In the mammals the primitively paired thoracic ducts are sometimes re-

tained throughout life, but usually only one persists. This begins at the cistern of chyle in the lumbar region and empties into the left brachiocephalic vein near the entrance of the single cephalic lymph duct. The thoracic duct receives the lymph-vessels from the limbs and others (lacteals) from the alimentary canal. In those cases where there is but a single thoracic duct in front, its representative on the right side is a much smaller vessel connected with the right side of the venous system. No lymph hearts are known in the mammals. The jugular lymph sacs of the embryo have been regarded as such, but the absence of valves and muscles in the walls renders such an interpretation doubtful.

As a part of the lymphatic system are to be enumerated **lymph follicles**, lymph glands (or knots) and blood lymph (hæmolymph) glands. The follicles (often called **Peyer's patches**) appear in the intestinal wall from reptiles upward. They consist of reticular connective tissue crowded with leucocytes (lymphocytes). In birds and mammals (their existence in sturgeon and crocodiles is doubted) the **lymph glands** are found. These are aggregates of lymph follicles, enclosed in a common capsule, and in close relation to lymph-vessels which send afferent and efferent branches into them, these breaking up into a network of sinusoids on the interior. They occur in the neck region of birds, and in the mesenteries of mammals.

The **spleen** is in some respects intermediate between the lymph glands and the blood-lymph glands. It lacks the afferent and efferent lymph-vessels and has a rich blood supply. It arises in the wall of the alimentary canal as an aggregation of mesenchyme cells, and the statement that there are entodermal contributions to it has been contradicted. The differences in its position in the different groups leads to the view that it originally belonged to a greater length of the digestive tract, and that different portions have developed in the separate classes of vertebrates. In the cyclostomes there is no distinct spleen, but cavernous tissue in the intestinal wall has been interpreted as splenic. In many fishes it is a compact organ, while in others it is composed of separate segments distributed along a considerable length of the canal. In turtles and frogs it lies along the intestine, while in urodeles, reptiles, birds and most mammals it is a compact body near the stomach. In monotremes it is three-lobed, the posterior lobe extending back along the intestine. The spleen serves, apparently, as a place for the disintegration of the red blood corpuscles as well as functioning as a leucocyte-forming organ.

The **tonsils** (p. 266) belong to the category of lymphoid struc-

tures. Under this name are included two kinds of structures, the pharyngeal and the palatine tonsils. The first of these lie in the roof of the gullet, the palatine being situated between the inner ends of the Eustachian tubes of amniotes, in mammals on either side of the pillars of the fauces. Besides these there are lingual tonsils at the sides of the roots of the tongue, and other similar structures at various points of the floor and roof of the tetrapoda, concerning which our knowledge is scanty.

The **hæmolymph glands** differ from the true lymph glands in the presence of red blood corpuscles. Their function is supposed to be somewhat the same as that of the spleen—the destruction of the red blood corpuscles, and possibly the formation of both leucocytes and erythrocytes. This latter type is rather uncommon, being largely confined to the neighborhood of the aorta and its chief branches, and to that of the postcava.

Mention should be made of other possibly lymph structures. Among these are the **fat bodies (corpora adiposa)**—band-like (urodele) or lobulated, richly vascularized masses of fat (anura) connected with the gonads of the amphibia. Of their origin and function little is accurately known. They are usually stated to arise from a modification of the wall of the postcava, but lately they have been said to come from the same general mass as the gonads themselves. It is suggested that they prepare some substance for the gonads, a view in accord with the fact that they are greatly reduced in the spring of the year. Even less is known of the **hibernating glands** of rodents and insectivores, masses of fat with (for fat) a very rich blood supply.

THE UROGENITAL SYSTEM

In several phyla of the animal kingdom there is an intimate relation between the reproductive and excretory organs, the ducts of the latter serving either to carry the products of the gonads directly to the exterior or acting as brood organs where a portion of the development of the egg takes place. This association of the two systems is especially intimate in most vertebrates and hence this section is headed Urogenital System, because of the difficulty of treating the two components separately.

The urinary or excretory organs have for their purpose the elimination of the nitrogenous waste (and occasionally other products) from the system. They are paired organs which consist of glandular

portions, the **nephridia** (kidneys), and their ducts. The reproductive organs include the **gonads** or sexual 'glands,' which (**ovaries**) produce the eggs or (**testes**) the spermatozoa, and the passages by which these products are carried to the external world. To these are frequently added accessory reproductive structures by which, in certain cases, the sperm is transferred to the female.

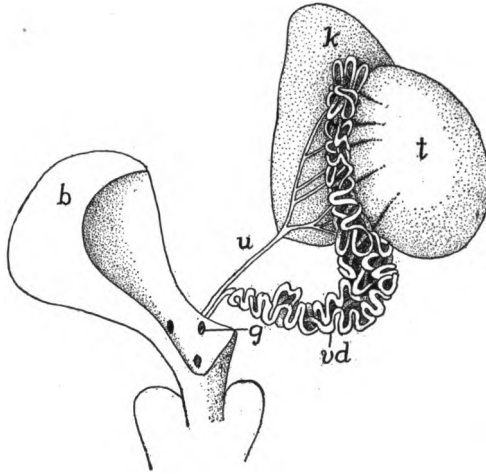


FIG. 358.—Urogenital organs of *Emys europea*, after Bojanus. *b*, urinary bladder; *g*, opening of vas deferens into the urogenital sinus; *k*, kidney; *t*, testis; *u*, ureter; *vd*, vas deferens.

THE EXCRETORY ORGANS

The nephridia consist of a series of excretory tubules, specialized in different ways, and of the ducts into which the tubules empty. As the function of the nephridia is the elimination of the nitrogenous waste (uric acid, urea, etc.) which accumulates in the blood, they have an abundant blood supply, entirely derived, in the younger stages of all vertebrates and in the adults of the higher groups from the dorsal aorta, while in the later developmental stages and in the adults of most anamniotes the aortic blood is supplemented by blood coming from the tail and hind limbs by way of the caudal and iliac veins (fig. 344).

In its extreme development one of the excretory tubules may consist of the following parts (fig. 359): At the proximal end the tubule opens into the coelom (metacoel) by a ciliated funnel, the **nephrostome**; the cilia, which may continue for some distance along the inside of the tubule, serving to create a current which carries the

cœlomic fluid into the tubule and thence outward. Farther along the tubule expands into a **Malpighian** or **renal corpuscle** (fig. 360). This consists of a vesicle (**Bowman's capsule**), one side of which projects into the other, nearly filling the cavity. This inturned portion is the **glomerulus**. It consists of a network of capillary blood-vessels—a *rete mirabile*—supplied by an artery and drained by a




FIG. 359.—Diagram of conventionalized excretory tubule. *a*, ascending limb of Henle's loop; *b*, Bowman's capsule of Malpighian body; *c*¹—*c*², first and second convoluted tubules; *ct*, collecting tubule; *d*, descending limb of Henle's loop; *g*, glomerulus of Malpighian body; with artery and vein; *h*, Henle's loop; *n*, nephrostome opening into cœlom; *x*, entrance of other tubules into collecting duct.

vein. Beyond the connexion with the Malpighian body the tubule becomes contorted or convoluted and its cells are strongly glandular in character. This **first convoluted tubule** is succeeded by a nearly straight tract, folded once on itself into the descending and ascending limbs of **Henle's loop**. Next follows the **second convoluted tubule**,

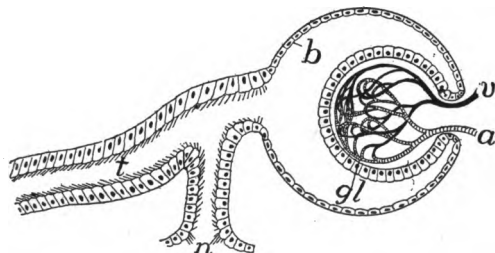


FIG. 360.—Diagram of renal (Malpighian) corpuscle. *a*, artery; *b*, Bowman's capsule; *gl*, glomerulus; *n*, nephrostome; *t*, nephridial tubule; *v*, vein.

which passes by means of a short connecting tubule into a non-glandular **collecting tubule** into which several other systems of excretory tubules enter, and which leads more or less directly into the urinary duct which conveys the waste from the excretory organ to the exterior.

One or another of these typical parts may be lacking in certain groups. Thus in the amniotes the nephrostomes are never formed,

though they occur in most ichthyopsida. In the pronephros the Malpighian corpuscle is rudimentary or lacking at all stages, while there is no differentiation of convoluted tubules and Henle's loop.

The function of the various parts of the nephridial tubule is in outline as follows: Theoretically it would appear that in the primitive condition the nitrogenous waste, which is elaborated in the liver, collected in the coelom and, together with the coelomic fluid, was passed outward through the nephrostomes and the tubules, which acted merely as ducts. Higher in the scale the parts become more differentiated and specialized. The renal corpuscles form a filtering apparatus by which water is passed from the blood-vessels of the glomerulus into the tubules near their beginning, and this serves to carry out the urea, uric acid, etc., secreted by the glandular portions of the walls of the tubules (convoluted tubules, ascending limb of Henle's loop).

In development there may be two or three successive series of nephridial structures, the higher number occurring only in the amniotes. These are known as the **pronephros** (head kidney), **mesonephros** (Wolffian body), and the **metanephros** (permanent kidney of the amniotes). All three are closely related in development and structure, but are distinguished by differences in origin and in the final details.

Three views are held as to their relations one to another. According to one they are parts of an originally continuous excretory organ (**holonephros**) which extended the length of the body cavity. This has become broken up into the separate parts which differ merely in time of development and function, with minor modifications in details. A second view is that they are three separate organs, while a third regards them as superimposed structures which occasionally overlap (birds, gymnophiona) and thus are not, strictly speaking, homologous but rather homodynamous. The first view has the most in its support, but for convenience the three structures are kept distinct here.

All three nephridia arise from the mesomeric somites (p. 16) or from the Wolffian ridge which appears on either side of the median line where the mesomeres separate from the rest of the wall of the body cavity, the mesomeric cells furnishing the nephrogenous tissue from which the definitive organs develop.

Pronephros.—The pronephros is the first to appear in development. As will be recalled (p. 15) the mesomere, like the epimere, becomes segmented; and later, when the epimere separates to form the myotome, the dorsal end of each mesomere becomes closed, the

whole then forming a sac, opening below into the ventral, undivided coelom (metacele). A varying number of these **nephrotomes** (as they are called) lying a little behind the head are concerned in the formation of the pronephros (some teleosts, one; two in most urodeles and amniotes; three in lampreys, anura, some sharks and some amniotes; four or five in some sharks and *Lepidosteus*; seven

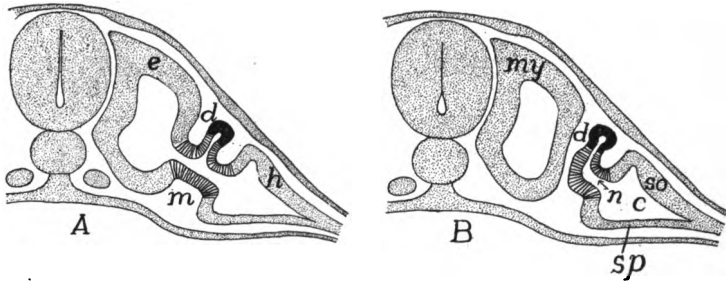


FIG. 361.—Scheme of origin of pronephric tubules after Felix. *A*, earlier, *B*, later stage. *c*, coelom; *d*, pronephric tubule and duct; *e*, epimere; *h*, hypomere; *m*, mesomere (lined); *my*, myotome; *n*, nephrostome; *so, sp*, somato- and splanchnopleure.

or eight in skates; eight to eleven in *Amia*; and a dozen in some cæcilians; while it is claimed that the whole series of nephridial tubules of *Bdellostoma* is pronephric). The somatic walls of these nephrotomes (fig. 361) grow out toward the ectoderm, thus forming slender pronephric tubules (amphibia), or solid cords which later become canalized (elasmobranchs, amniotes), but in all cases they eventually




FIG. 362.—Reconstruction from longitudinal sections of pronephros of *Hypogeophis* (caecilian), after Brauer. Pronephric duct (*pd*) and primary pronephric tubules light; the rest of the somites (nephrotomes) black; glomeruli between tubules 2-8. The three trunk somites in front of 1 develop no tubules.

form tubes, the proximal end of each communicating freely with the metacele by way of the cavity of the nephrotome, the opening of the latter into the metacele being the **nephrostome**. As will be understood, these tubules, like the nephrotomes, are metameric in character, equalling the somites in number. The distal ends grow outward until they are just beneath the ectoderm; when they bend

toward the posterior end of the body, the anterior tubules fusing with those behind. From the junction a tube, the **pronephric** or **archinephric duct**, gradually grows backward just beneath the ectoderm (figs. 362, 364) until it reaches the posterior end of the metacoel, when it fuses with the hinder end of the digestive tract (cloaca) or with the ectoderm in the vicinity of the anus. An opening now breaks through into the cloaca, thus putting the coelom indirectly in communication with the outer world.

At first the pronephric duct lies closely below the ectoderm and is almost equally near the lining of the metacoel. As the myotomes grow downward they come to lie between the ducts and the ectoderm so that eventually the ducts are just beneath the lining of the definitive body cavity.

There has been considerable dispute as to the origin of the cells which form the pronephric duct. They were long believed to be solely of mesothelial character, arising by proliferation from the tube itself. Then it was noticed that the backward-growing tube fused at its tip with the ectoderm and it was thought that there was an actual contribution of ectodermal cells at this point. This view received considerable support from its agreement with certain theoretical views. The matter is not yet decided. The writer is convinced, from the study of perfectly preserved material in which cell boundaries are clearly shown, that in the sharks (*Acanthias*) which were thought most strongly to support the view of ectodermal contribution, that the whole duct is of mesothelial origin.

In the teleosts the dorsal end of the nephrotome grows out to form the pronephric tubule, to which both somatic and splanchnic walls thus contribute. In the amphibia the nephrotome is not distinctly separated from the lateral plates (hypomere) and the pronephric tubules are formed from the common area.

The pronephros is functional for a time in the embryos of some lower vertebrates; in other groups it is a rudimentary and transitory structure, save for its participation in the oviducts and the ostium tubæ abdominale (see below). When functional, it takes the nitrogenous waste from the body cavity, while its filtering apparatus consists either of separate glomeruli (one for each tubule) or the glomeruli of the separate somites may run together, forming a **glomus** (fig. 363). These glomeruli or the glomus of the pronephros do not project into a Bowman's capsule, but lie immediately above the dorsal wall of the coelom, between the mesentery and the nephrostomes (fig. 364), pushing the epithelium before them. Later, as in the cæcilians, they and the nephrostomes may be enclosed in a cavity

cut off from the coelom, so that the whole resembles a renal corpuscle, but is different in origin. In either case the exuding fluid passes into the metacoel, from which it is drawn by the cilia of the nephrostomes and passed into the tubules.

The blood is brought to the glomus or glomeruli by short segmental arteries arising from the dorsal aorta (fig. 364) and, after passing through the capillaries, it is carried away by the postcardinal veins of the corresponding side to the heart, these veins keeping pace in their backward development with the development of the nephridial tubules.

There is much that goes to show that the pronephros formerly had a much greater extension than at present, including a larger number of somites.

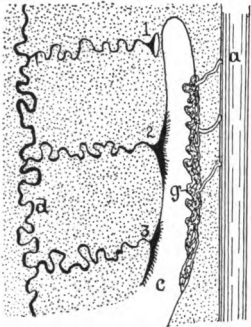


FIG. 363.—Reconstruction of the pronephros of *Salamandra*, after Semon. *a*, aorta; *c*, connexion of nephrostomal with the main coelom; *d*, pronephric duct; *g*, glomus; 1, 2, 3, nephrostomes of pronephric tubules.

It has, however, been replaced in the adults of all vertebrates (with the possible exception of *Bdellostoma*) by the mesonephros, and later, in the amniotes, by the metanephros as described below. It persists, however, with slight modification in the cyclostomes and a few teleosts.

Mesonephros.—The mesonephros or Wolffian body is the second excretory organ to arise. It arises after the pronephros and its ducts are formed, by the development of a series of mesonephric tubules which grow out from the nephrotomes behind those concerned in the formation of the pronephros. These tubules extend laterally until they meet and fuse with the pronephric duct, which now acts as the excretory canal of the new gland. In some cases the point of origin

of the mesonephric tubules is clearly dorsal to that of the pronephric tubules (fig. 364), and in some cases (birds, cæcilians) pro- and mesonephric tubules have been described as arising from the same nephrotome, one above the other. In most ichthyopsida the opening of the nephrotome into the metacoel forms the nephrostome, but in the amniotes this opening is closed before the tubules are formed and consequently nephrostomes are lacking in the latter group in all stages of development, and the tubules have no connexion with the peritoneal cavity.

Usually several metameres intervene between the last pronephric and the first mesonephric tubule, there being seventeen such metameres in *Amia*. On

the other hand, in crossopterygian ganoids, turtles and crocodiles the last pronephric and the first mesonephric tubules arise from the same somite.

Segmental arteries grow out from the aorta to the splanchnic wall of each nephrotome, forming there a network of capillaries at a higher level than the pronephric glomeruli (fig. 365). The glomerulus thus formed presses the wall before it, while the rest of the nephrotome closes around it as a Bowman's capsule, the whole forming a Malpighian body (in some rodents the glomeruli are rudimentary or absent). In most ichthyopsida the Malpighian body is connected on one side with the metacoele by the nephrostome, and on the other with the mesonephric tubule.

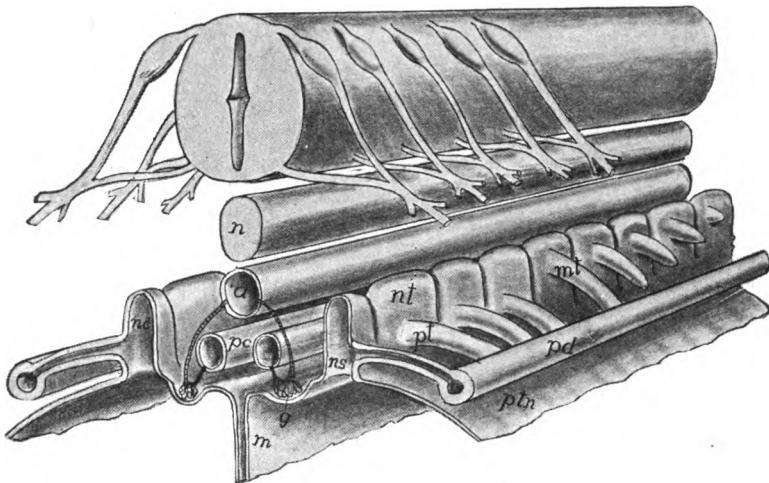


FIG. 364.—Stereogram of developing pro- and mesonephros. *a*, aorta; *g*, glomerus or glomerulus; *m*, mesentery; *nt*, mesonephric tubule; *n*, notochord; *nc*, cavity of (*nt*) nephrotome; *ns*, nephrostome; *pc*, postcardinal vein; *pd*, pronephric duct; *pt*, pronephric tubule; *ptm*, peritoneal membrane.

Thus at first the mesonephros is a metameric structure, extending over a much larger number of somites than does the pronephros and reaching nearly to the posterior limits of the metacoele. As the development of the embryo proceeds, the number of tubules, in all vertebrates except the myxinoids, increases by budding in a manner not readily described (fig. 367). These tubules unite with those first formed, so that the distal part of these become collecting tubules. Each of these secondary tubules forms its own Malpighian body and all of the tubules elongate, become convoluted (fig. 366) and the mesonephros loses its primitive metameric character.

At the same time changes are introduced into the mesonephric

circulation. The veins emerging from the renal corpuscles extend out into the region of the tubules, each breaking up there into a sec-

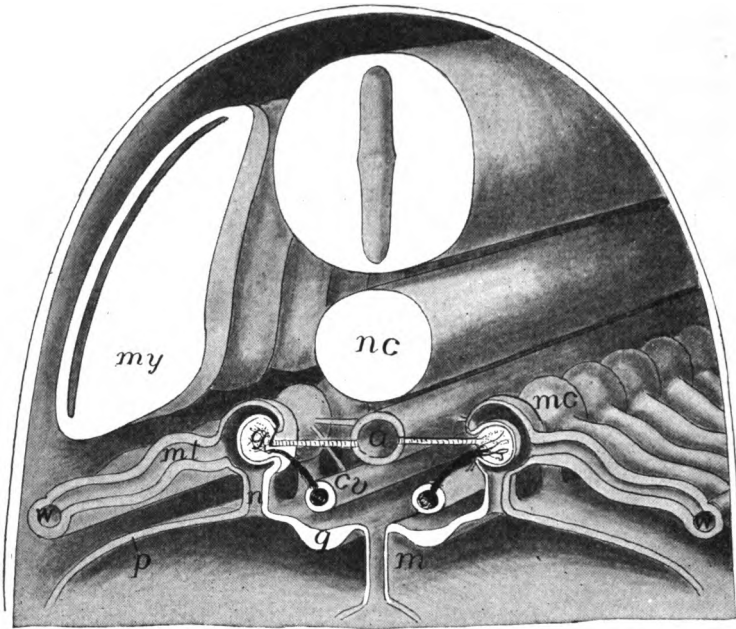


FIG. 365.—Stereogram of mesonephros. *a*, aorta; *cv*, postcardinal vein; *g*, genital ridge; *gl*, glomerulus; *m*, mesentery; *mc*, Malpighian corpuscle; *mt*, mesonephric tubules; *my*, myotome; *n*, nephrostome; *nc*, notochord; *p*, peritoneal lining; *w*, Wolffian duct.

ond system of capillaries which envelop the tubules before returning the blood to the postcardinal vein. The subcardinal vein (p. 311) brings the blood from the caudal region (and usually from the hind limbs) to the Wolffian body and this is also returned *via* the postcardinals to the heart. (For details of the modifications of the mesonephric circulation see pp. 311-327.)

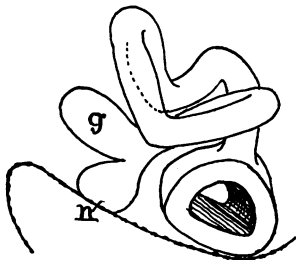


FIG. 366.—Reconstruction of a mesonephric tubule of *Amblystoma*, after Hall. *g*, glomerulus; *n*, nephrostome.

The Mesonephric Ducts.—The conditions in the elasmobranchs have been regarded as very primitive. In them (and to some extent in some of the amphibia), when the mesonephros develops, the pronephric duct divides longitudinally from its hinder end as far forward as the anterior end of the Wolffian body. Of the two ducts thus formed (fig. 368, A),

one, the **Wolffian (Leydig's) duct**, remains connected with the tubules of the mesonephros and forms its excretory canal. The

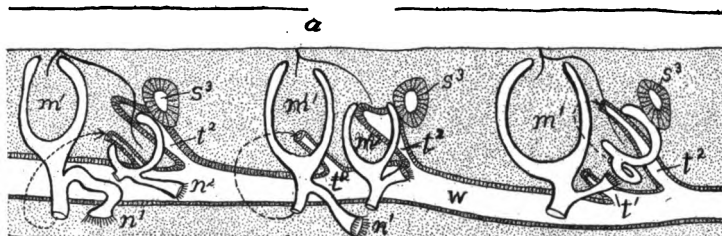


FIG. 367.—Reconstruction of three somites of the Wolffian body (mesonephros) of *Hypogeophis*, after Brauer. *a*, aorta; m^1 - m^2 , primary and secondary Malpighian bodies; n^1 - n^2 , corresponding nephrostomes; s^3 , tertiary segments of mesonephros; t^1 - t^2 , primary and secondary mesonephric tubules; *w*, Wolffian duct.

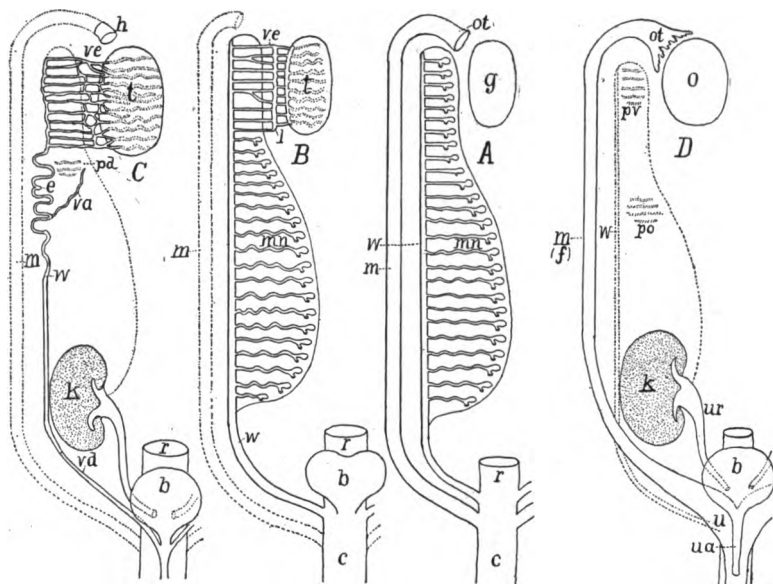


FIG. 368.—Diagrams of urogenital structures in (A) indifferent and in female elasmobranchs and amphibians; (B) male elasmobranchs and amphibians; (C) male amniote (mammal); (D) female amniote (mammal). *b*, urinary bladder; *c*, cloaca; *e*, epididymis; *k*, kidney (metanephros); *f*, Fallopian tube; *g*, gonad; *h*, 'stalked hydatid'; *l*, longitudinal tubule; *m*, Müllerian duct (oviduct), rudimentary in B and C; *mn*, mesonephros; *o*, ovary; *ot*, ostium tubæ abdominale; *pd*, paradidymis; *po*, paroöphoron; *pv*, parovarium; *r*, rectum; *t*, testis; *u*, uterus; *ua*, urethra; *ur*, ureter; *va*, vas aberrans; *vd*, vas deferens; *ve*, vasa efferentia; *w*, Wolffian duct, urinary in A, urogenital in B, genital in C and rudimentary in D.

other, the **Müllerian duct**, is similarly related to the pronephros and its derivatives and in the female forms the tube (oviduct) by which the eggs are carried to the exterior. In other amphibia and

in the amniotes the pronephric duct does not divide, but remains solely in the service of the mesonephros and forms the Wolffian duct, while the oviduct arises in another matter, to be described in connexion with the reproductive organs (p. 351). In the teleosts also there is no division of the pronephric duct.

Metanephros.—The mesonephros is functional in the embryos of all vertebrates and throughout life in the ichthyopsida. It also functions for a short time after birth in certain reptiles (lizards) and in the lowest mammals (*Echidna*, opossum). It becomes replaced in the adults of all amniotes by the metanephroi, the only structures to

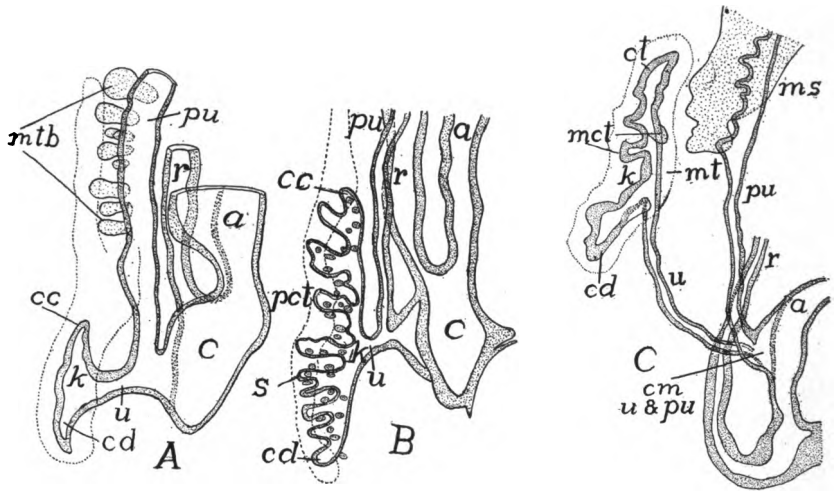


FIG. 369.—Profile reconstructions of lizard (*Lacerta agilis*) (A) 16 mm. long; (B) 20 mm. long; and (C) human embryo 115 mm. long, after Schreiner. *a*, allantois stalk; *c*, cloaca; *cc*, cranial collecting tubule; *cd*, caudal collecting tubule; *k*, permanent kidney (metanephros); *mct*, median collecting tubule; *ms*, mesonephros; *mt*, metanephric (nephrogenous) tissue; *mtb*, mesonephric tubules; *pct*, primary collecting tubule; *pu*, Wolffian duct (primitive ureter); *r*, rectum; *s*, secondary collecting tubule; *u*, ureter; *cm*, *u* and *pu*, common portion of primitive and permanent ureters.

which the name kidneys is strictly applicable. Each metanephros arises behind the mesonephros of the same side. From the dorsal hinder end of the Wolffian duct, near its entrance into the cloaca, a tube, the ureter (fig. 369, A, *k*) grows forward, parallel to the parent duct, into the tissue posterior and dorsal to the mesonephros. This nephrogenous tissue is apparently serially homologous with that from which the mesonephric tubules have arisen, but all traces of metamerism have disappeared from it and the metanephros is not gesmented in any stage of development. In this nephrogenous tissue the anterior end of the ureter gives off a varying number of branches

(fig. 369, *B*), each of which expands at its tip, thus forming a primary renal vesicle, and a little later the place where the branches and the ureter unite expands, the enlargement forming the pelvis of the definitive kidney. The cells of the nephrogenous tissue form a number of aggregates around each primary vesicle; each aggregate soon becomes hollow, and develops into an S-shaped tubule (fig. 370, left), one end of which joins the primary renal vesicle, while a glomerulus arises at the other end, but no nephrostomes are formed. Later there is a great multiplication of these tubules and an extension of the capillary system of the glomeruli around them, much as in the

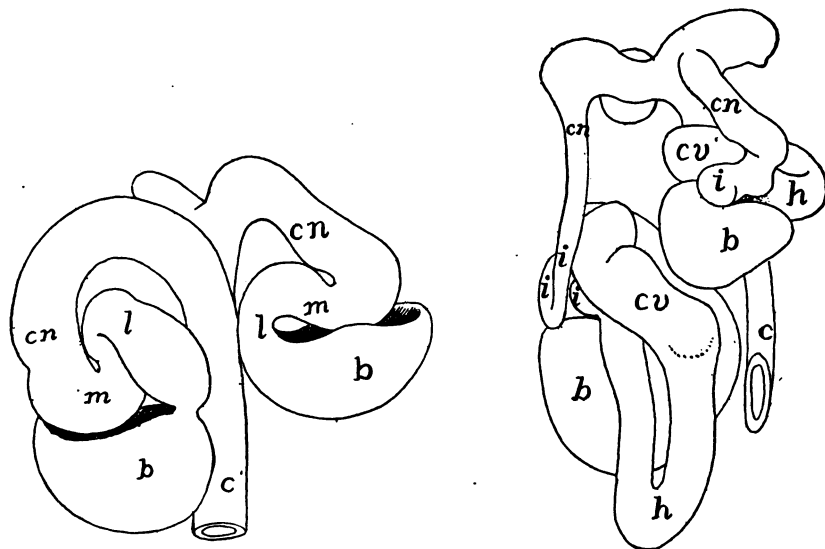


FIG. 370.—Models of two stages in the development of tubules of kidney (metanephros) of man, after Stoerk. *b*, Bowman's capsule; *c*, collecting tubule; *cn*, connecting tubule; *cv*, convoluted tubule; *h*, Henle's loop; *i*, intercalary tubule; *l*, lower arch; *m*, middle piece.

mesonephros. The differentiation of each tubule into convoluted, collecting and, in birds and mammals, Henle's loop regions occurs early (fig. 370, right).

Urinary Bladder.—At or near the hinder ends of the excretory ducts there is frequently a reservoir for the urine, the urinary bladder or **urocyst**. Of these there may be three kinds. In most fishes (fig. 383) the bladder arises by a fusion of the hinder ends of the Wolffian ducts plus a part derived from the hinder end of the digestive tract (cloaca), the Wolffian ducts emptying into it and the whole opening to the exterior, usually dorsal and posterior to the anus

In the dipnoi there is a diverticulum from the dorsal wall of the cloaca, anterior to the openings of the Wolffian ducts. This is usually called the urinary bladder (fig. 373 *D*), but it may be homologous with the rectal gland of the elasmobranchs.

The third type, the **allantoic bladder**, occurs in all tetrapoda. This arises as a ventral diverticulum from the cloaca. In the amphibia the whole of the outgrowth forms the bladder and its walls are supplied by the hypogastric arteries. In the amniotes the proximal portion alone is converted into the urinary bladder, while the more distal portion, becomes in the embryo the respiratory organ of the growing young, the allantois. This part extends far beyond the body wall, carrying with it branches of the hypogastric arteries (allantoic arteries), and in the mammals forms a part of the placenta. The allantois becomes reduced in the later stages and at the beginning of free life is entirely absorbed or is lost with the placenta. In the amphibia the urine finds its way into the urinary bladder *via* the cloaca, as the urinary ducts (Wolffian ducts) do not open directly into it. In those amniotes in which a bladder is present the ureters open into it, and the urine is conveyed to the exterior by a single tube, the **urethra**. In many sauropsida there is no urinary bladder, though the allantois is formed in development.

There is great difficulty in comparing the excretory system of the vertebrates with anything known in the invertebrates. In general the nephridial tubules may be compared with those of the annelids. Both have nephrostomes opening into the coelom, and convoluted tubules enveloped in a network of capillary blood-vessels, but in the annelid each tubule opens separately to the exterior in the somite behind that in which the nephrostome lies, while in the vertebrate the series of tubules empty into a common duct. When it was thought (p. 339) that the ectoderm contributed to the pronephric duct, the homologies appeared easy. The duct was originally a groove on the outer surface into which the separate tubules opened. Then the groove was rolled into a tube which continued backward to the vicinity of the anus. By the downgrowth of the myotomes the duct became cut off from its primitive position and came to lie just outside the peritoneal lining. When, however, it is considered that in all probability the pronephric duct is formed solely from the mesoderm the homology falls to the ground and an explanation is still a desideratum.

THE REPRODUCTIVE ORGANS

The tissue which is to form the ovaries and testes early forms a pair of genital ridges, one on either side of the mesentery and between it and the Wolffian ridge (fig. 365). At one time it was thought that

the anlage of the gonad was segmental in character and 'gonotomes,' comparable to nephrotomes and myotomes, were described. It has since been shown that no metamerism exists and that the primary germ cells, which alone characterize the gonads, arise in several groups of vertebrates (probably in all) from the entoderm, which is never metameric. At about the time of the differentiation of the somites they migrate through the developing mesoderm to their definitive position in the epithelium of the genital ridges, the **primitive** or **primordial ova** (whether to form eggs or sperm) being recognizable from their size and their reaction to microscopic stains (figs. 371, *o*; 374). In the adults of many vertebrates the gonads at maturity project far into the coelom and are often suspended by a fold of

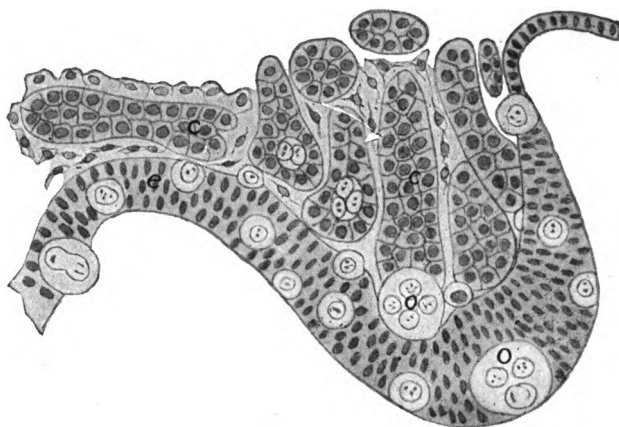


FIG. 371.—Section of genital ridge of chick of five days' incubation, after Semon. epithelium of ridge (coelomic wall); *c*, medullary cords; *o*, primordial ova.

peritoneum which is called a **mesorchium** in the male, a **mesoarium** in the female.

The gonads are primitively paired; the unpaired condition which occurs in cyclostomes, many fishes and birds, is either the result of fusion or of one-sided degeneration. Thus in the Ammocete stage of the lampreys the mesentery is lost and the gonads of the two sides fuse. In the myxinoids, on the other hand, only the left gonad normally reaches a functional stage.

Ovaries.—In the ovarian epithelium the primitive ova multiply, and the products, accompanied by some of the epithelial cells, sink into the deeper stroma of connective tissue, thus forming **ovarial** or **medullary cords** (fig. 371, *c*), each containing a number of ova. Then the cords break up and each egg becomes surrounded with a

layer of epithelial cells, the whole forming a **Graafian follicle**, the follicle cells supplying nourishment to the contained ovum. In the higher vertebrates there is a great increase in the number of follicle cells, which become arranged in several layers. Then in mammals (fig. 372) a split arises in the follicle, the cavity becoming filled with a **follicular liquor**, while the ovum, surrounded by several layers of cells, adheres to one side of the cavity, this part being called the **discus proligerus**.

When the eggs have attained their full size and the proper time has arrived, some of the follicles migrate to the surface of the ovary, then the follicles rupture and the contained ova escape into the coelom. Their history from this point will be outlined in connexion with the genital ducts. Each ruptured follicle (at least in elasmobranchs, amphibians, and amniotes leaves a scar on the surface of the ovary—the **corpus luteum**—characterized by the presence of peculiar ('lutein') cells.

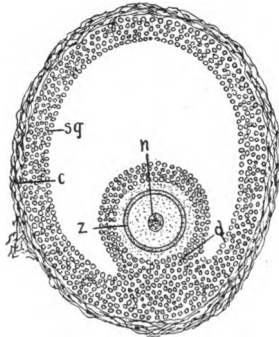


FIG. 372.—Graafian follicle of cat. *c*, connective-tissue capsule; *d*, discus proligerus; *n*, nucleus of ovum; *sg*, stratum granulosum (follicle cells); *z*, zona pellucida.

Testes.—In the gonads of the male (testes) there is a somewhat similar insinking of the primordial ova and epithelial cells into the stroma of the genital ridge, but, instead of breaking up into separate follicles, each sexual cord develops a lumen and becomes converted into a **seminiferous tubule**, in the walls of which both the epithelial cells and the primordial ova are recognizable, as well as a third kind of cell, called **Sertoli's cell**, concerning which accounts are somewhat at variance, some regarding them as derivatives of the epithelial cells, others as coming from the primitive germ cells. They play no part in the actual formation of the spermatozoa, but act rather as nutritive or 'nurse cells' for the developing spermatozoa. For the differentiation of the germ cells into spermatozoa reference must be made to the text-books of embryology and histology. In most vertebrates the testes continue in the position where they first appear, but in most mammals they eventually descend to a position outside of the body cavity and are enclosed in a special pouch, the scrotum. This descent of the testes is described in connexion with the reproductive organs of the mammals, below.

THE REPRODUCTIVE DUCTS

The reproductive products formed in the gonads have to be carried to the exterior, either as spermatozoa, or as eggs or young in different stages of development, the ducts in the male being called **vasa deferentia**, those of the female being **oviducts**. The former are usually the Wolffian ducts, the latter may be either the Müllerian ducts or tubes developed for the special purpose, or lastly, the abdominal pores.

Male Ducts.—In the elasmobranchs, amphibia and amniotes the Wolffian ducts (fig. 368) serve as the outlet for the sperm. While the seminiferous tubules are developing, there occurs a proliferation of cells from the wall of the Bowman's capsules in the anterior end of the mesonephros. These **medullary cords** extend through the adjacent connective tissue and into the genital ridge where they come into close connexion with the developing seminiferous tubules (fig. 371). When the latter acquire their lumen the medullary cords also become canalized, so that both form a continuous transverse tubule (*vas efferens*) leading from the genital cells to the Malpighian corpuscles, and thence by the mesonephric tubules to the Wolffian duct (fig. 373, *A*). These **vasa efferentia** become connected by a longitudinal canal before entering the Wolffian body, while usually there is another longitudinal testicular canal connecting them in the body of the testis (fig. 373, *B*). Usually this connexion of testis and Wolffian body takes place at the anterior end of the mesonephros, but in some dipnoi the posterior end of the mesonephros alone is involved. This is frequently accompanied by a degeneration of the glomeruli of the tubules concerned, so that this part of the mesonephros loses its excretory character and becomes subsidiary to reproduction (fig. 368, *B, C*). With this formation of *vasa efferentia* the sperm never enters the *cœlom* except as this is represented in the cavities of the mesonephric tubules.

As a farther result the anterior end of the Wolffian duct becomes purely reproductive in the male and is usually greatly coiled, this portion being called the **epididymis**. In the amniotes, where the hinder portion of the mesonephros is supplanted by the true kidney (*metanephros*), the whole Wolffian duct is a sperm duct (*vas deferens*) in the male, while in the female it largely or completely degenerates. In the amphibia and elasmobranchs the hinder end of the duct is both reproductive and excretory in the male; in the female it is purely excretory.

In the ichthyopsida, other than elasmobranchs and amphibia, the sperm is carried to the exterior in other ways, and there is no connexion of the testes with the excretory organs. In the cyclostomes the sperm escapes from the testes into the cœlom and then is passed to the exterior by way of the abdominal pores (p. 19) which in the lampreys open into a cavity (**sinus urogenitalis**) which also receives the hinder ends of the Wolffian ducts. In the myxinoids the pores

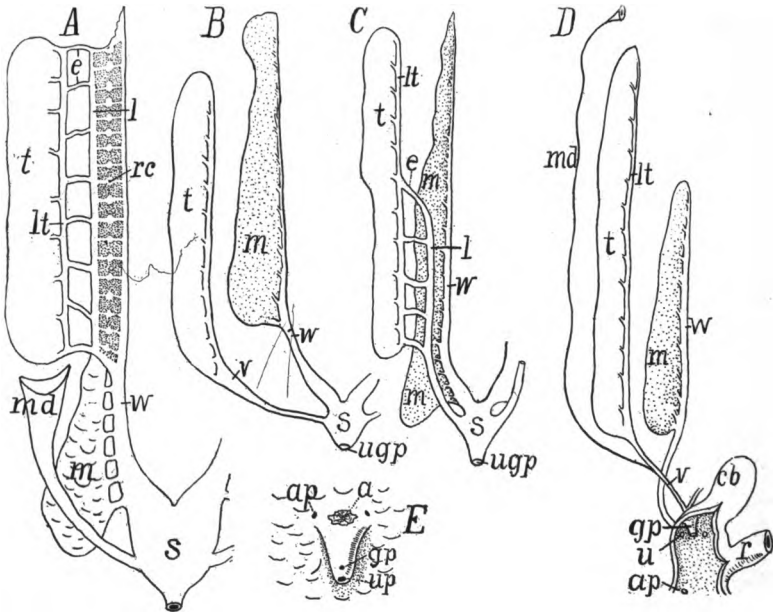


FIG. 373.—Diagrams of urogenital organs of male fishes, after Goodrich. *A*, *Acipenser* (*Lepidosteus* and *Amia* similar, but lack the oviduct); *B*, teleosts; *C*, *Polypterus*; *D*, *Protopterus*; *E*, urogenital openings of female salmon. *a*, anus; *ap*, abdominal pore; *cb*, cloacal ('urinary') bladder; *e*, vasa efferentia; *gp*, genital pore (papilla); *l*, longitudinal duct; *lt*, longitudinal testis duct; *m*, mesonephros; *md*, Müllerian(?) duct; *r*, rectum; *rc*, renal corpuscle; *s*, urogenital sinus; *t*, testis; *u*, *up*, urinary pore; *ug*, *up*, urogenital pore; *v*, vas deferens; *w*, Wolffian duct.

are united, and they open to the exterior behind the anus and between it and the urinary openings.

The conditions found in the sturgeons (fig. 373, *A*) and in *Polypterus* give a possible explanation to the aberrant structures of the teleosts. In the first group can be made out the vasa efferentia and the two longitudinal canals connecting them, these extending the whole length of the testis. In *Polypterus* (fig. 373, *C*) the connexion between the testis and mesonephros is confined to the hinder portion of organs, the anterior vasa efferentia and the longitudinal canal disappearing in front, the longitudinal testicular canal taking

the sperm from the anterior end of the testis and carrying it farther back for passage through the mesonephros. Here the anterior end of the Wolffian duct is purely excretory. A farther concentration of the efferent functions to the last vas efferens would give, with a few other modifications, the conditions of the teleosts (fig. 373, *B*). In all of this group there is no connexion of testes with mesonephroi. The seminiferous tubules are connected by a longitudinal canal (apparently the longitudinal testicular canal of other vertebrates) which runs in the membrane (mesorchium) supporting the testis, back to the external opening, which is either directly to the exterior between the urinary opening and the anus (fig. 383) or into a urogenital sinus (fig. 373, *B*).

This view is farther supported by the relation in the dipnoi. In *Ceratodus* there are numerous vasa efferentia which extend from the testis into the mesonephros. In *Lepidosiren* the efferent ductules are fewer in number and they arise from a posterior degenerate portion of the testis, while in *Protopterus* (fig. 373, *D*) there is but a single vas efferens on either side and this passes through the posterior end of the Wolffian body.

Oviducts.—In the elasmobranchs the Müllerian duct, which, as described above, arises by a splitting of the pronephric duct, serves as the oviduct. After separation from the Wolffian duct this opens in front into the coelom by means of the pronephric tubules and their nephrostomes. Then these flow together, forming a large opening, the **ostium tubæ abdominale**, on either side (in elasmobranchs the ostia of the two sides are usually united ventral to the liver) through which the eggs, which pass from the ovary into the coelom are carried into the oviduct.

In some amphibia (*Salamandra*) the pronephric tubules and nephrostomes take a part in the formation of the ostium tubæ and the beginning of the oviduct, while in *Amblystoma* the ostium develops in close connexion with the pronephric nephrostomes. Here, as in all other tetrapoda, the rest of the oviduct arises by the formation of a groove of the peritoneal membrane close beside the Wolffian duct. This becomes rolled into a tube, the Müllerian duct (fig. 374). In the amniotes the anterior end of the groove does not close, but remains open as the ostium tubæ (fig. 368, *A*).

Usually the condition in the elasmobranchs has been regarded as the primitive one, a supposition which renders it difficult to homolo-

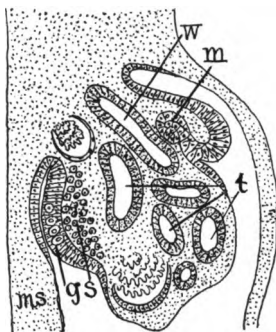


FIG. 374.—Section through the urogenital region of a four-day chick embryo, after Waldeyer. *g*, analage of gonad with primordial ova; *m*, involution of peritoneum to form the Müllerian duct; *ms*, mesentery; *s*, cells to form stroma of gonad; *t*, tubules of mesonephros; *w*, Wolffian duct.

gize the Müllerian ducts (oviducts) of elasmobranchs with those of other forms. Still, when the adult conditions are considered—similar ostia, similarity of position and of external openings—it is hardly possible to believe them as merely analogous, as examples of convergence. The facts in the amphibia, referred to in the preceding paragraph are additional evidence of homology. If, however, it be

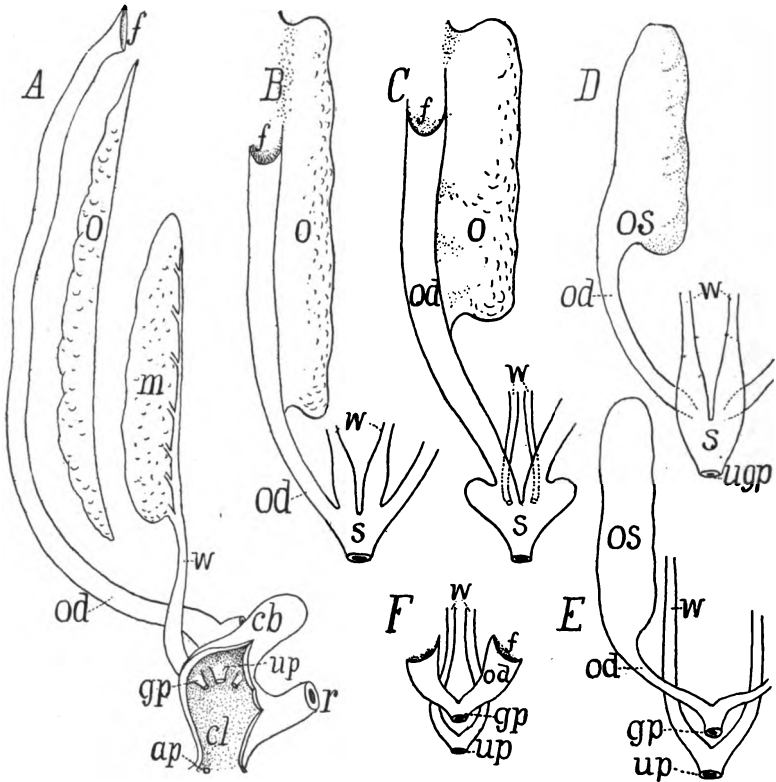


FIG. 375.—Diagrams of urogenital organs of female fishes, after Goodrich. *A* *Protopterus*; *B*, *Polypterus*; *C*, *Amia*; *D*, *Lepidosteus*; *E*, most teleosts; *F*, salmonid. *ap*, abdominal pore; *cb*, cloacal bladder; *cl*, cloaca; *f*, funnel of oviduct; *gp*, genital pore or papilla; *m*, mesonephros; *o*, ovary; *od*, oviduct; *r*, rectum; *s*, urogenital sinus; *up*, urinary pore, (papilla); *ugp*, urogenital pore (papilla); *w*, Wolffian ducts.

assumed that the more common type of development, by the infolding of cœlomic epithelium, be the primitive condition, the difficulties are less, though not entirely solved. Then, if it be that the homologous tissue in the elasmobranchs was at first included in the tissue of the pronephric duct and that the splitting is a secondary operation to separate parts which elsewhere are always distinct, the similarities are more apparent.

In the females, as in the males, of cyclostomes and teleosts the reproductive ducts are not easily brought into harmony with those of other vertebrates, and an answer to all questions cannot be had until the development of the parts has been studied in more forms, and especially the ganoids and dipnoi. In the cyclostomes the eggs are shed from the ovaries into the cœlom and are thence passed outward through the abdominal pores.

In the teleosts there are several conditions. The ovaries may be simple and solid bands or saccular in character with an internal lumen (fig. 375, *E*). In the first the eggs pass into the cœlom and thence to the exterior by abdominal pores or by oviducts of varying lengths (fig. 375, *F*). Concerning the nature of these ducts there is uncertainty. They may be true Müllerian ducts or new formations within the group. The fact that similar tubes occur, with permanently open ostia in both sexes of the sturgeons (fig. 373, *A*), and that these open behind into the Wolffian ducts, lends probability to the view that the ducts of the ordinary teleosts are Müllerian in character, but greatly modified.

The saccular condition of the ovaries appears to arise in two ways. In the one the primitively free edge of the ovary bends laterally and fuses with the cœlomic wall, thus enclosing a cavity, the **parovarial canal**, closed in front. In the other type a groove of the covering epithelium forms on the surface of the ovary. This closes over and sinks inward, forming what is termed as an **entovarial canal**. Either canal may extend backward to the hinder end of the body cavity, thus forming an oviduct, or the oviduct may be formed from both kinds of canals, one in front, the other behind. From this it would appear that the ovary originally extended back to the hinder end of the cœlom (as it does in *Cyclopterus*) or that the par- or entovarial canal had united with a Müllerian duct which has otherwise been entirely lost. The oviducts thus formed usually unite before opening to the exterior, either directly or *via* a urogenital sinus. The oviducts in the dipnoi (fig. 375, *A*) are much like those of the selachians, emptying independently into the cloaca. They persist, though of small size, in the males (fig. 373, *D*).

COPULATORY ORGANS

In many vertebrates the eggs are fertilized after passing from the oviducts to the exterior. This is the case with the cyclostomes, most fishes, with the exception of the elasmobranchs, and with many amphibians. In other groups (including some teleosts) fertilization is internal. In some cases the transfer of the sperm from the male to the female is effected by the apposition of the cloacæ of the two sexes, but in others copulatory organs of an intromittent character

occur. These are formed in several ways and are not homologous throughout. Hence they will be considered here under the separate groups.

HERMAPHRODITISM

Individuals of either sex which have assumed some of the external or secondary sexual characters of the other sex are sometimes spoken of as hermaphrodites, especially in the case of mammals if the copulatory organs be concerned. This is not true hermaphroditism, which consists in having both ovarian and testicular organs or tissues in the same individual and as a consequence the ability to produce both eggs and spermatozoa. There may be both kinds of tissue in the different parts of the same gonad, or the two may be intermingled (*ovotestis*) or the gonads of the two sides of the body may be of different sexes. Both ovaries and testes may be functional at the same time, or one may be functional at one time and the other at another (*proterandric hermaphroditism*).

Among the cyclostomes there are occasional specimens of lampreys which have been regarded as hermaphroditic, but in the myxinoids this is the regular occurrence, the anterior end of the gonad is female and the posterior male. One or the other of these is functional, the animal being predominantly either male or female, and some individuals are regarded as sterile. Nansen regards this as a case of proterandric hermaphroditism. In the teleosts several species of *Serranus* are regularly hermaphroditic as is *Chrysophrys aurata*, while in several other species it is an occasional occurrence. *Triton taeniatus* is the only urodele in which it is reported, but in the anura it is most common. Thus it is frequent in the frogs and occasional in other genera. In the toads (*Bufo*) there is frequently a 'Bidder's organ' in front of the gonads which contains immature ova in the male. Among the birds the phenomenon has been reported in the chaffinch. (The assumption of male plumage by female birds at the close of sexual life is not a case of hermaphroditism.) Among the mammals the cases are extremely rare, but cases, apparently well authenticated, have been reported in the goat, pig and man.

ADRENAL ORGANS

Under this heading are included two sets of structures, *interrenals* and *suprarenals*, of uncertain morphology and function. The names are given in allusion to the fact that they are usually closely associated

in position with the nephridial structures, though they have no other relation to them. The two differ in structure and probably in function and are very distinct in the lower vertebrates but in amphibia and amniotes they are united in a common structure, the interrenals forming the cortex, the suprarenals the medulla of the mammalian adrenals.

The interrenals arise from the cœlomic epithelium, but it is as yet uncertain as to the details, some thinking that they are connected with the pronephros, others with the mesonephric structures, while still others regard them as distinct in origin. They are at first either isolated clusters of cells or longer bands of cells near the dorsal margin of the mesentery, sometimes bilaterally symmetrical and in the lower vertebrates in the early stages extending through the length of the cœlom.

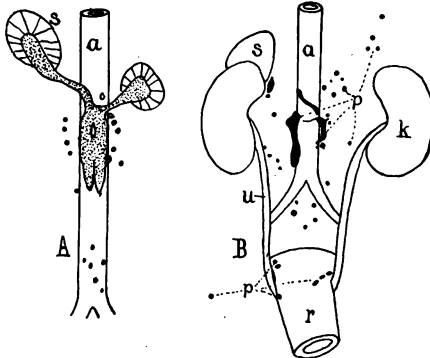


FIG. 376.

FIG. 376.—*A*, Diagram of the phæochrome system of a just-born rabbit; *B*, of a forty-five day girl, after Kohn. *a*, aorta; *k*, kidney; *p*, phæochrome bodies; *r*, rectum; *s*, suprarenal; *u*, ureter. In *A* the connexion of the bodies with the medulla of the suprarenal is indicated.

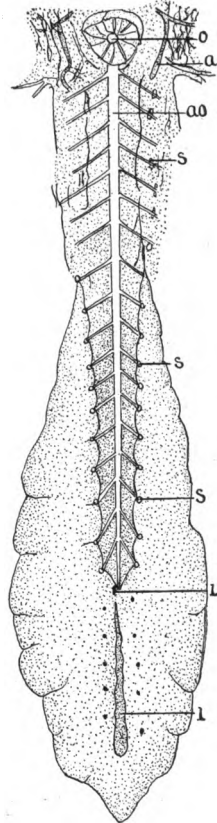


FIG. 377.

FIG. 377.—Adrenal system of *Scyllium*, after Swale Vincent. *a*, axillary heart; *ao*, aorta; *i*, interrenals; *s*, suprarenals.

The anlage of the suprarenal bodies is in the sympathetic ganglia, certain cells of which separate from the rest. Some of these retain their ganglionic character through life, while others are the **chromophile** or **phæochrome cells**, so-called because they stain brown or yellow with chromic salts. These are usually closely related to

the blood-vessels in their early stages (fig. 376) and this relation persists through life.

In the fishes interrenals and suprarenals are separate (fig. 377), the suprarenals often being more or less metameric and in close relations to the blood-vessels supplying the mesonephros and those farther in front. The interrenals are more compact and in the fishes they lie between the excretory organs of the two sides of the body.

In the tetrapoda the two organs are more closely associated, the tissues of the two being mixed in the adults of amphibia and reptiles, while in the mammals the interrenal tissue is on the outside, forming the cortex of the **adrenal** (frequently called the **suprarenal**) body which lies at the anterior end of the kidney. The suprarenal tissue is the medulla of the adrenals. It consists of numerous phæochrome cells with small aggregates of nerve cells, and forms a series of tubules through which blood supplied by the suprarenal artery circulates before being carried away by the vein. In the amphibia the adrenals are closely associated with the Wolffian bodies, either being attached to the inner margins (urodeles), or forming yellow stripes (anura) on the ventral surface. In the reptiles they are lobulated bodies near the gonads.

Both are organs of internal secretion, their product being passed directly into the blood. The medullary portion in mammals forms **adrenalin**, an **activator** or **hormone**, which by its action on the muscles causes an increase in the blood pressure. Less is known concerning the function of the interrenal organ, but it seems that in part it destroys certain toxins, the products of metabolism, which otherwise would be injurious to the organism.

UROGENITAL ORGANS IN THE SEPARATE CLASSES

CYCLOSTOMES.—In this class the nephrostomes are lost with the exception of the most anterior, while the pronephric duct becomes degenerate between the anterior end and the functional part of the excretory organs.

In the lampreys the pronephros extends over thirteen somites, but only the anterior five form complete tubules, the remainder, however, join the pronephric duct. The pronephros is best developed in the *Ammocete*, 10 mm. long, and in this stage the mesonephros is also developed and both are functional. With increase in size there is a degeneration of the mesonephric tubules in front and a formation of new ones behind, the definitive organ extending over about two-fifths of the body length. Each pronephros projects into the cœlom as a band supported by a fold of the peritoneal membrane. The two pronephric ducts unite a little in front of the hinder end, forming a urogenital sinus into

which the abdominal pores empty, and which, in turn, opens at the tip of a urogenital papilla just behind the anus.

In the myxinoids the nephridial tubules develop as a continuous series, the organ in the earliest stage known extending over somites 11-80. Later the organ becomes divided into two parts by the degeneration of the intermediate tubules. The anterior part projects into the body cavity and is provided with nephrostomes, while the posterior part, reaching through some twenty or thirty somites, has its tubules strictly segmental, each with a Malpighian body. This is the functional excretory organ.

The gonads, which are usually unpaired (p. 347) are band-like structures, supported by a fold of the peritoneal membrane (mesorchium or mesoarium, p. 347). The eggs and sperm, when ripe, fall into the cœlom and are carried to the exterior by the urogenital pore. The myxinoids have hermaphroditic gonads, the anterior part being ovarian, the posterior testicular. One sex, however, predominates in each individual, except a few which are completely sterile. One view (Nansen) is that the sexes alternate in function (proterandric hermaphroditism). Another is that (Schreiner) there is a rudimentary hermaphroditism, the gonad of one sex or the other being degenerate. The eggs of the lampreys are small, those of myxinoids much larger, the latter being enclosed in a horny shell with anchoring hooks at either end. The eggs of the lamprey closely resemble those of the amphibia in their early development.

ELASMOBRANCHS.—The pronephros is never functional as an excretory organ, but its nephrostomes fuse and form the ostium tubæ in the female, by which the eggs are carried from the ovary to the exterior. In these animals there is the typical splitting of the pronephric duct into Wolffian and Müllerian ducts (p. 342). The functional excretory organs are the mesonephroi and the urinary ducts from the functional part of these may separate from the rest (fig. 378, *u*) which degenerate with the degeneration or modification of the anterior end of the Wolffian body. The general form of the mesonephroi is modified by the other viscera, and these organs are frequently asymmetrical. Usually the nephrostomes are closed in the adult, but in some (*e.g.*, *Acanthias*) they persist. The anterior end of each mesonephros is always narrowed, and in the male it and the anterior end of the Wolffian duct form the connexion with the testis, the coiled anterior end of the duct forming the epididymis (fig. 378, *e*) while the mesonephric tissue is frequently called Leydig's gland (fig. 379). The urinary ducts fuse behind into a urinary bladder. In the female the bladder opens at the tip of a urinary papilla, but in the male it connects with a urogenital sinus, into which a pair of sperm reservoirs empty, and from this a duct empties at the tip of a urogenital papilla (fig. 378, *B*).

As in all other vertebrates the gonads are at first paired and symmetrical, but in some (*Trygon*, *Myliobatis* and their relatives) only the left ovary comes to full development, possibly the result of pressure of the spiral valve on the right gonad. With these exceptions the gonads are paired and lie far forward in the body cavity as lobes connected with the body wall by mesorchia or mesovaria, the testes being more variable in position than are the ovaries.

The Müllerian ducts serve as oviducts, those of the two sides connecting with the cœlom by a common opening (fig. 378, *o*) the ostium tubæ abdominale,

the result of the fusion of the pronephric nephrostomes. The eggs, escaping from the ovaries, are received by the ostium and are carried backward by the oviducts to a **shell or nidamental gland**, where the shell (slight in the viviparous species, stronger in the others) is secreted. The rest of the tube is enlarged and serves, especially in the viviparous species, as a uterus, the inner surface bearing vascular villi by which nourishment and oxygen are brought to the embryo. The eggs are very large, those of some species exceeding those of the ostrich in

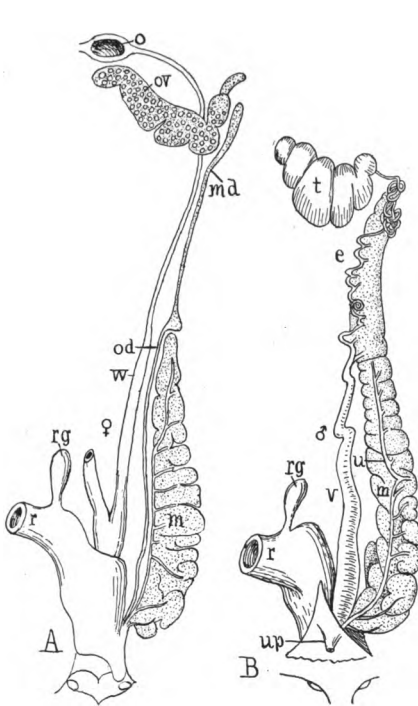


FIG. 378.—Urogenital organs of (A) immature female and (B) male *Torpedo marmorata*, after Borcea. *e*, epididymis; *m*, mesonephros; *md*, degenerate anterior end of mesonephros of female; *o*, ostium tubæ; *od*, oviduct (Müllerian); *ov*, ovary; *r*, rectum; *rg*, rectal gland; *u*, definitive ureter; *up*, urogenital papilla; *v*, vas deferens; *w*, Wolffian duct.

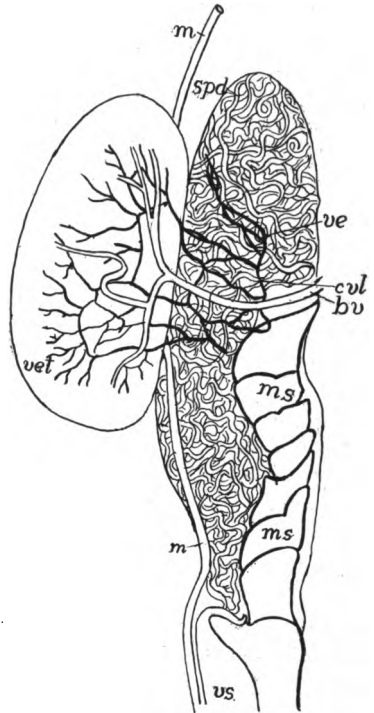


FIG. 379.—Testis and anterior end of mesonephros of *Chimæra*, after Parker and Burland. *bv*, blood-vessel; *cul*, longitudinal tubule; *m*, Müllerian duct; *m.s*, anterior end of mesonephros (Leydig's gland); *spd*, sperm duct; *ve*, *vet*, vasa efferentia; *vs*, seminal vesicle.

size. The usual form of the egg shell is quadrangular with tendril-like prolongations at each corner, but this is varied, some (*Acanthias*) being simple sacs; others, like *Heterodontus*, having complicated cases. Some species of both sharks and skates are viviparous.

The relations of the male ducts to the testes are typical (p. 349), the anterior end of the mesonephros forming an epididymis. The vasa deferentia of the two sides unite just before the entrance to the cloaca to form a urogenital sinus,

with which an oval sperm sac is connected on either side. In the holocephali (fig. 379) the epididymal region is separated by a considerable interval from the rest of the mesonephros and forms a large Leydig's gland which secretes the spermatophores. The Müllerian duct is reduced in the male, and frequently is without a lumen; its anterior end may retain a reduced funnel.

As fertilization is internal in the elasmobranchs, the posterior or inner side of the pelvic fin is specialized for a copulatory organ, by which, even in the late embryo, the sexes can be distinguished. The metapterygium (p. 124) and the basalia connected with it are more or less completely separated from the rest and form the so-called **clasper (mixipterygium)**, a slender part of the fin. Each clasper is grooved along its medial surface and when the two are inserted in the cloaca of the female the grooves form a tube for the passage of the spermatozoa. The clasper contains a large gland, but its relations to copulation and fertilization are unknown.

The interrenals are paired in skates, elsewhere unpaired; they may form a continuous mass (fig. 377) or may be separate bodies between the kidneys, recognizable from their yellow color. The suprarenals are metameric in the sharks, irregularly distributed in the skates, but always in close relations to the sympathetic system, and in their posterior range they may be imbedded in the mesonephroi.

GANOIDS.—The number of pronephric tubules varies from two (second and fifth postotic somites) in *Polypterus*, to five or six in *Lepidosteus* and sturgeons and eight to eleven in *Amia*. The pronephros degenerates in the adult. The mesonephros has nephrostomes in *Amia* and the sturgeons. This organ is markedly segmental, and in the sturgeons the anterior part is separated from the rest, while the organs of the two sides are united behind. The urinary ducts are the Wolffian ducts, and the Müllerian ducts of the females enter the urinary bladder.

In most species the ovaries are band-like and there are oviducts which have broad internal funnels and, as said above, they open to the exterior together with the urinary ducts, a relation which favors the view that they are Müllerian ducts like those of elasmobranchs, but reduced in extent in correlation with the backward extension of the gonads. In *Lepidosteus*, however, the ovary is saccular as in the teleosts, the eggs passing into the central cavity and then to the exterior by a duct which is apparently but a sterile backward extension of the ovary. The males are more normal, the testes being frequently lobulated and with the regular ductules leading from the testes to the anterior end of the mesonephros (fig. 373) and thence separately or by a common duct into the Wolffian duct. The males of all but *Lepidosteus* have short funnels like the females, an additional evidence that these are reduced Mullerian ducts.

TELEOSTS.—In development the pronephros extends over from one to six somites, these having a tendency to form a common chamber and a **glomus**. Usually the pronephros degenerates, but it persists through life in a few species (*Zoarces*, *Lepadogaster*, *Fierasfer*) and functions in the larval stages in many more. The mesonephros varies in shape. Frequently the organs of the two sides are united behind, less frequently in front, while occasionally there is a cross connexion in the middle; lobes may extend forward from the main

mass or into the tail. In many the anterior portion differs from the rest and is called a head kidney, although it is not a pronephros. It is rather a peculiar tissue, rich in lymph cells, developed from the walls of the cardinal veins. The nephridial ducts (Wolffian) are usually imbedded in the substance of the mesonephros (fig. 38o, *d*), but sometimes they run on the ventral surface of the organ.

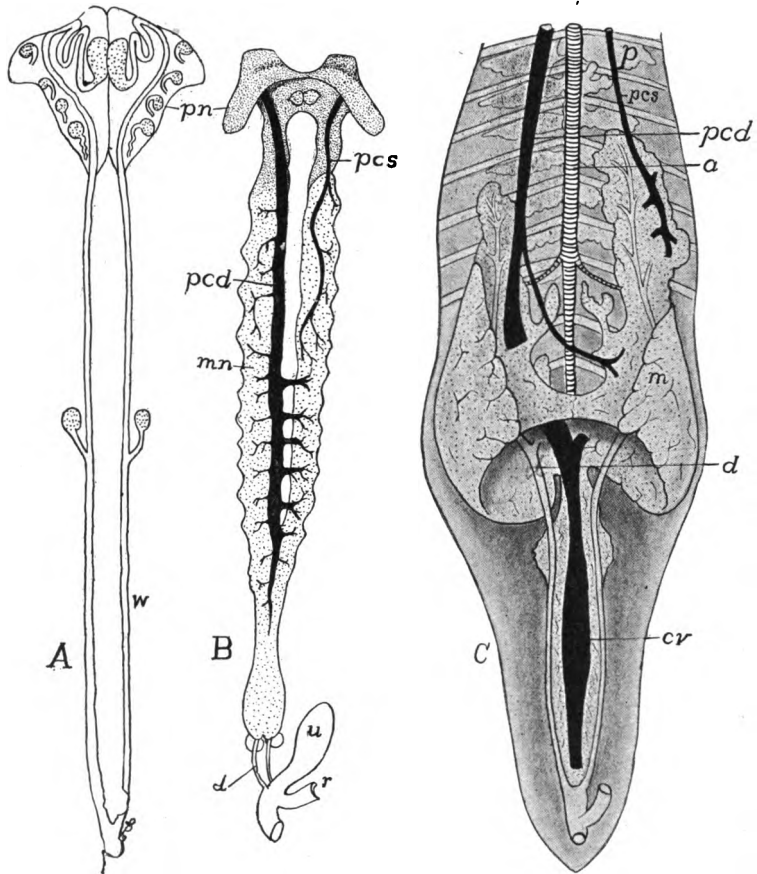


FIG. 380.—Urinary organs of teleosts, after Haller. *A*, pronephros and ducts of young *Salmo fario*; *B*, excretory organs of adult perch, *Perca fluviatilis*; *C*, of carp, *Cyprinus carpio*; *a*, aorta; *cv*, caudal vein; *d*, urinary duct; *m*, *mn*, mesonephros; *pcd*, *pcs*, right and left postcardinal veins; *p*, *pn*, pronephros; *r*, rectum; *u*, urinary bladder; *w*, *wd*, Wolffian duct.

The ducts of the two sides unite behind and from this union and in some cases from the wall of the cloaca, a urinary bladder is formed. The external urinary opening is behind the anus, sometimes united with the genital opening.

The ovaries may be flattened, plaited lobes, bound to the peritoneal wall by mesovaria. From this condition, which occurs in many salmonids, many modifications may be traced. Thus in the same family (fig. 381) there is frequently

a groove on the edge of each ovary, while in other groups the edges of the groove unite so that a hollow gonad is formed. The eggs ripen and escape into this cavity when it is present; in the others they escape into the cœlom.

The ovarian ducts are not homologous. In most salmonids and scattered species from other groups the eggs pass from the cœlom to the exterior through

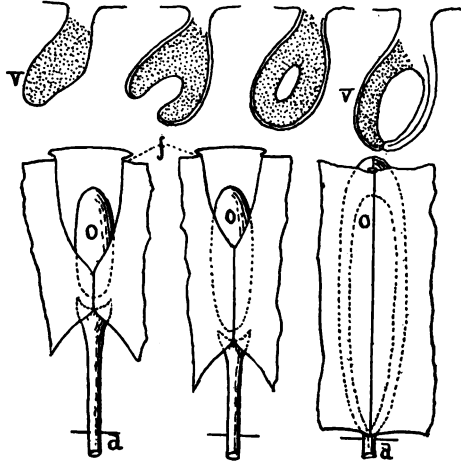


FIG. 381.—Schematic representation of the enclosure of the teleost ovary by the cœlom, in surface view and sections, after Haller. *f*, peritoneal fold; *o*, ovary; *d*, terminal duct; *V*, ventral side of sections.

sex openings which may be modified abdominal pores (p. 19) behind the anus. These are sometimes extended inside the cœlom by a short funnel (fig. 382). In all other cases there is a direct extension of the saccular ovary into a short oviduct like that of *Lepidosteus*, with an opening on either side behind the anus.

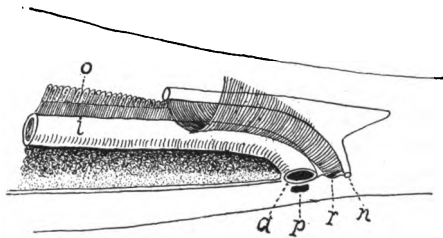


FIG. 382.—Relations of oviducts and pori abdominales in *Coregonus*, after Weber. *a*, anus; *i*, intestine; *n*, nephridial opening; *o*, ovary; *p*, pore of right side; *r*, opening of oviduct.

In most teleosts the number of eggs produced in a season is very large, sometimes numbering millions. Usually, after passing from the oviducts they are left to the mercy of the water, but a number of species (*Embiotocids*, several *Cyprinodonts*, *Gambusia*) are viviparous, the eggs developing in the hollow ovary or its ducts, which in some cases provide nourishment for the growing young. In these fish there must be internal fertilization, but copulatory organs are

known in but few species, formed in one species from the ventral fin, in another by the hæmal spine of a caudal vertebra, and in a third by an outgrowth behind the anus.

In the male the testes are simple or lobulated. Internally each testis consists of radial chambers of varying shape which are connected with a complicated system of tubules leading to the vas deferens, which runs back to open into the hinder end of the Wolffian duct or to open independently to the exterior (fig. 383, *go*).

Hermaphroditism is rare among teleosts. It occurs commonly among the species of *Serranus* and *Chrysophrys*, and has been observed with specimens of cod, mackerel and herring.

Interrenal organs are known in the bony fishes, scattered in or on the ventral surface of the mesonephros (Stannius's corpuscles). Suprarenals have been described in the wall of the cardinal vein, but this is uncertain.

DIPNOI.—In *Ceratodus* there are two pronephric tubules, that of the third somite being complete, that of the fourth rudimentary. The glomerulus lies

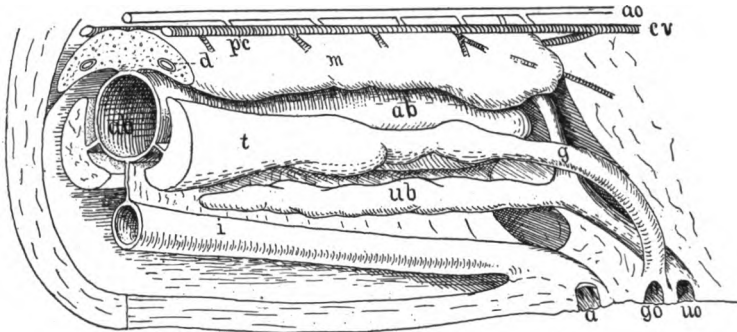


FIG. 383.—Hinder part of urogenital organs of male pike, *Esox lucius*, after Goodrich. *a*, anus; *ab*, air bladder; *ao*, aorta; *cv*, cardinal vein; *d*, Wolffian duct; *g*, genital duct; *go*, genital opening; *i*, intestine; *pc*, postcardinal vein; *t*, testis; *ub*, urinary bladder; *uo*, urinary opening; *m*, mesonephros; *cv*, caudal vein.

beside the open nephrostome. The mesonephros is at first strongly metameric. There are no nephrostomes in the adult and none appear at any time in *Lepidosiren*. The adult mesonephros is widest behind, but the relations of the efferent ductules of the male are differently arranged in the separate genera, as mentioned above (p. 350).

The reproductive organs are apparently more like those of elasmobranchs. The oviducts resemble, at least in structure, Müllerian ducts, and have their ostia far forward near the heart. These tubes, like those of the amphibia, secrete a gelatinous substance around the eggs. The ducts of the two sides unite before emptying at the tip of the genital papilla into the cloaca. The same ducts are retained in the male *Ceratodus* and to a less extent in the other genera.

The gonads are elongate. The testes are enveloped, together with the mesonephroi, in a lymphoidal tissue rich in fat. The sperm passes into a longitudinal tubule (fig. 373) and from this by one (*Protopterus*) or several efferent

ductules to the posterior end of the mesonephros, the epididymis thus being posterior in position. Less is known of the structures in *Ceratodus*, but the ductules are more numerous and the epididymis is anterior.

AMPHIBIA.—The pronephros (developing from two somites in urodeles, three in anura and from ten to thirteen in cæcilians) retains its functions in urodeles and anura until the metamorphosis, when its tubules degenerate. The

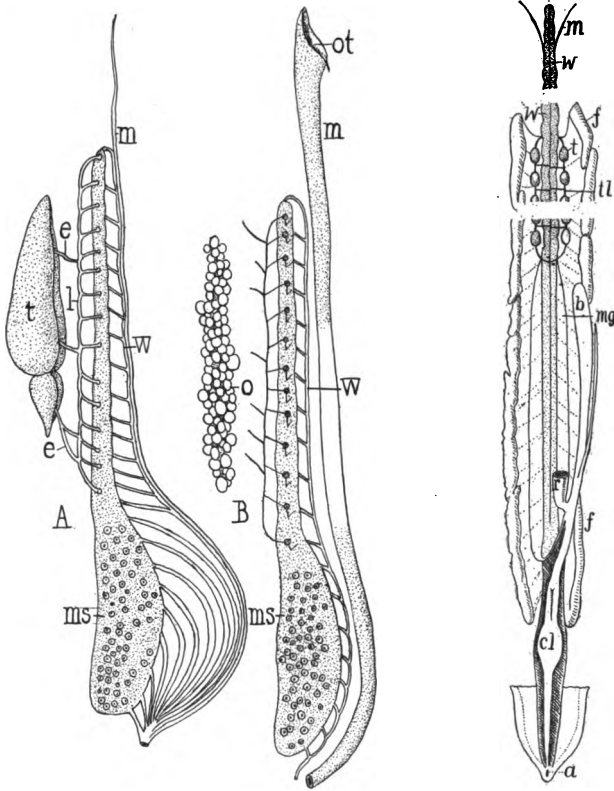


FIG. 384.

FIG. 385.

FIG. 384.—Diagram of (A) male and (B) female organs of urodele, after Spengel. *e*, vasa efferentia; *l*, longitudinal duct; *m*, Müllerian duct; *ms*, mesonephros with nephrostomes indicated; *o*, ovary; *ot*, ostium tubæ; *t*, testis; *w*, Wolffian duct.

FIG. 385.—Male urogenital organs of *Epicrion*, after Spengel. *a*, anus; *b*, urinary bladder; *cl*, cloaca; *f*, fat bodies; *m*, Müllerian ducts; *mg*, glandular part of same; *r*, rectum; *t*, testes; *ll*, longitudinal testicular canal; *w*, Wolffian body.

part of the coelom into which the pronephric nephrostomes open, tends to be cut off as a separate chamber, while the blood supply may form a glomus. The early mesonephros consists of a tubule with its nephrostome, tubule and glomerulus to each somite, but in the adult this metamerism is lost (except anteriorly) by the development of secondary tubules, each like the original, the nephrostomes sometimes numbering over a thousand on the ventral surface of each Wolffian body. These nephrostomes persist with their normal connexions in cæcilians

and urodeles, but in the adult anura the nephrostomes separate from the nephridial tubules and join branches of the renal blood-vessels, thus placing the coelom in connexion with the circulatory system.

In the urodeles (fig. 384) the mesonephroi form a pair of ridges or projecting folds on the dorsal wall of the coelom. Their length is somewhat proportional to the body length, and the anterior end of each loses its excretory character, and in the male becomes subservient to reproduction, as described above (p. 351). The caecilians (fig. 385) resemble the urodeles except that the mesonephroi are more lobulated, the result of aggregates of secondary tubules around the collecting tubules.

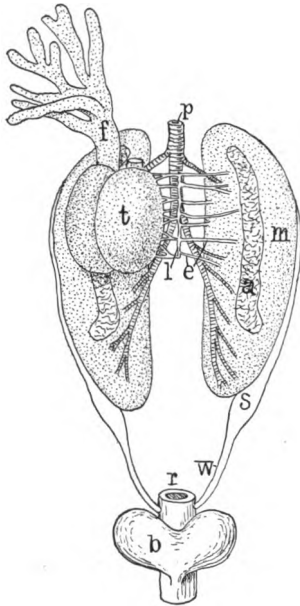


FIG. 386.—Urogenital organs of male frog, ventral view. The left testis (*t*) has been turned to the right to show the efferent ductules (*e*). *b*, urinary bladder; *a*, adrenal organ; *f*, fat body (that of the left side removed); *l*, longitudinal duct; *m*, mesonephros; *p*, postcava; *r*, rectum; *s*, seminal receptacle; *w*, Wolffian duct.

The sexual organs of the amphibia fit well into the general scheme. The gonads are roughly correlated in form to the shape of the body, being compact in the anura, longer in the urodeles, and longest in the caecilians. The testes have both the longitudinal and the testicular canals connecting the efferent ductules, these latter passing through the anterior part of the mesonephros, sometimes utilizing the nephridial tubules, sometimes pursuing their own course, the two conditions being found in different species of frog (*Rana*) in Europe. The relations in the American species are not known. In the caecilians (fig. 385) the testes resemble two strings of beads, each bead consisting of a number of seminiferous tubules, the string of either side being connected by the testicular canal. In urodeles the testes are shorter and in the anura they are rounded.

The ovaries are saccular, with an internal cavity lined with pavement epithelium. The eggs do not escape into this as in the teleosts, but into the body

of aggregates of secondary tubules around the collecting tubules. In the anura the organs are more compact and the differentiated anterior end is lacking, although the efferent ductules of the testes pass through the mesonephros. The nephridial waste, in all cases, is carried away by the Wolffian duct, while, in the males, the same duct acts as a vas deferens as in the elasmobranchs. The ducts of the two sides open separately into the cloaca, and in the males each usually has an enlargement, the seminal vesicle, which in the breeding season, is a reservoir for the spermatozoa. The urinary bladder differs from that of the ichthyopsida in being ventral to the cloaca. It is of the allantoic type. It is very long in the caecilians and in *Amphiuma*, saccular in most urodeles, and bifid at the tip in the majority of anura, being even divided into two sacs, connected only at the opening into the cloaca in some species.

The sexual organs of the amphibia fit well into the general scheme. The gonads are roughly correlated in form to the shape of the body, being compact in the anura, longer in the urodeles, and longest in the caecilians.

The testes have both the longitudinal and the testicular canals connecting the efferent ductules, these latter passing through the

cavity, from which they pass into the ostium tubæ. The ovarian cavity is lymphatic in character. The oviducts are very long, the ostia far forward, and in the adults they are greatly coiled and have glandular walls which secrete the gelatinous substance which envelops the eggs. The oviducts of the two sides open separately to the cloaca in most species, but in the toad the two unite a little in front of the cloacal opening.

Fertilization is external in the anura, internal in cæcilians and urodeles, though there is no intromittent organ aside from the somewhat protrusible cloacal region, well developed in cæcilians. In the urodeles the cloaca has a glandular lining, and in the females it contains tubules which act as reservoirs of sperm. In the male the glands secrete a substance which binds the spermatozoa into bundles (spermatophores).

There are many interesting accessory reproductive relations among the amphibia. Thus the cæcilians and *Amphiuma* lay their eggs in long strings in the soil and the female incubates them. The male often takes charge of the eggs. In *Pipa* each egg undergoes development in a pit in the skin of the back of the female, and in *Nototrema* and *Opisihodelphys* (South American tree-toads) there is a large pocket in the skin of the back, opening near the coccyx, where the eggs are carried until partially (*Nototrema*) or entirely developed. *Salamandra maculosa* and *S. atra* bring forth living young, the former being born with gills, the latter in the perfect condition. Oviposition usually occurs in the spring in colder climates (in the autumn with *Cryptobranchus* of America) and as the drain on the system is very considerable immediately after hibernation, the substance of the fat body, which always is closely connected with the gonads, is utilized at this time.

SAUROPSIDA.—Reptiles and birds agree, in the general features of the urogenital apparatus with the amniote conditions as outlined in the general account above. The pronephros is rudimentary at all stages and at no time functions as an excretory organ. The mesonephros (which always lacks nephrostomes) takes its place in foetal life, and in some reptiles it continues to function for some time after hatching, but in all it is eventually replaced by the metanephros, though its degenerate remains persist in the reptiles (better preserved in the female) as the so-called 'yellow body.' Another portion persists in the male, forming, much as in mammals, the connexion between the testis and the vas deferens. As long as the mesonephros remains functional, the Wolffian duct is the urinary passage, but after the metanephros comes into function, the duct degenerates in the female, though persisting as the vas deferens in the male. It opens either into the urinary bladder or into the cloaca.

The metanephros never extends as far forward as does the mesonephros of the ichthyopsida, but is usually restricted to the posterior part of the body cavity and frequently to the pelvic region. It is usually small and compact or lobulated, but in the snakes it is long, and the lobulation is sometimes so extensive that the lobules are connected only by the ureter. In the lizards and some song birds, the kidneys of the two sides are often connected by a cross band behind. The mesonephroi of birds are usually three-lobed, the lobules lying in cavities in the pelvis between the sacral vertebræ and the transverse processes. The waste is carried from the kidneys by the ureters which open sepa-

rately into the cloaca (fig. 387). Only in lizards and turtles is there a well-developed urinary bladder of the allantoic type (fig. 358) although an allantois is present in the development of all, and urinary bladders, sometimes dorsal, sometimes ventral to the cloaca, are common in the embryonic stages. The urine in other sauropsids is semisolid and consists largely of uric acid.

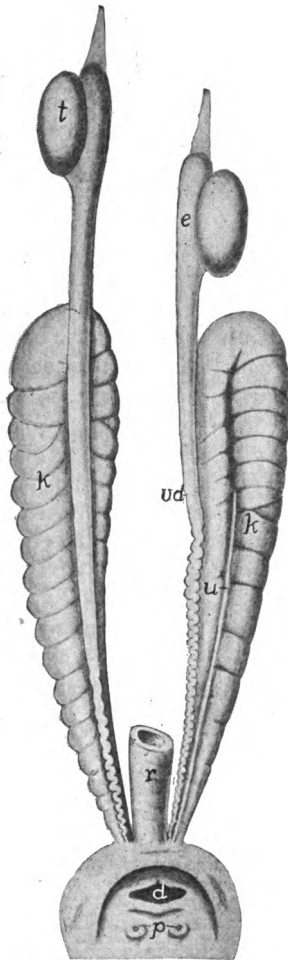
The gonads are roughly correlated in shape with that of the body and often there is a lack of symmetry between the two sides of the animal. Thus in reptiles and birds there is a marked tendency for the gonad of one side to be farther forward than is the other, and in birds this goes so far that in the female the ovary of the right side may be degenerate or even may be entirely lost.

The Wolffian duct is the vas deferens in the male and the anterior end of the mesonephros forms the connexion of the testis with the duct, the two constituting an epididymis, which usually is small in birds, but larger than the testis in many reptiles. In most reptiles the ureter and vas deferens of a side have a common opening to the cloaca, but in birds they are distinct (fig. 388, *B*). Müller's duct often persists in the male, sometimes with a lumen, and an ostium, and in *Lacerta viridis*, the common green lizard of Europe, it is as well developed as in the female.

The ovaries are saccular with an internal lymphoid cavity, and the walls are rich in blood-vessels, in correlation with the relatively enormous eggs. In some lizards the right ovary is farther forward and larger than the left, a contrast to the conditions in birds mentioned above. Corresponding to the reduction of the right ovary of birds, the oviduct of that side is reduced or may be practically absent. In all sauropsida each oviduct opens to the coelom by a large, slit-like ostium (fig. 388) and the tube, usually longitudinally plaited, is differentiated into regions with different functions.

FIG. 387.—Urogenital organs of *Monitor*, after Gegenbaur. *d*, opening of digestive tract into cloaca; *e*, epididymis; *k*, kidney; *p*, papillæ of urogenital system; *r*, rectum; *t*, testes; *u*, ureter; *vd*, vas deferens.

In *Sphenodon*, crocodiles, turtles and birds the first part of the oviduct secretes the albumen (white) of the egg, which is lacking from the eggs of snakes and lizards. Farther down is an enlargement, called the uterus or shell gland, which secretes the shell with its organic base and, in birds and some reptiles, its large amount of lime. The eggs are forced along the oviducts by the action of the muscles in their walls.



Sphenodon lacks copulatory organs, but they occur in all other sauropsida, though formed on two entirely different plans, one restricted to the squamata, the other, occurring in the crocodiles, turtles and some birds, being homologous with those of the mammalia.

In the young squamata (snakes and lizards) a couple of sacs are developed from the posterior wall of the transverse anus, and in the embryonic stages they resemble appendages. These form the copulatory organs which are called hemipenes. (These are present in both sexes,

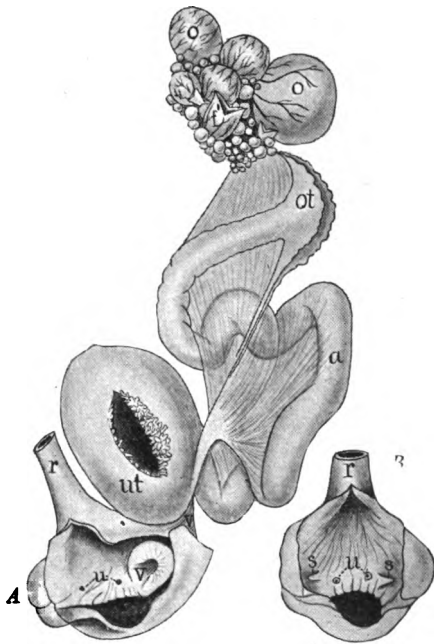


FIG. 388.

FIG. 388.—A, genitalia of hen; B, cloacal region of cock, after Tichomiroff. *a*, albumen secreting region of oviduct; *f*, discharged follicle of ovary; *o*, advanced ova in follicles; *ot*, ostium tubæ abdominale; *r*, rectum; *s*, openings of vasa deferentia; *u*, urinary openings; *ut*, uterus or shell gland with the villi showing in the opening.

FIG. 389.—Hemipenes of *Crotalus horridus*, after J. Müller. One hemipenis is exerted, the other retracted but laid open. *cl*, cloaca; *g*, seminal groove; *p*, hemipenis; *r*, rectum, *rp*, retractor muscle of hemipenis; *u*, ureter; *vd*, vas deferens (Wolffian duct).

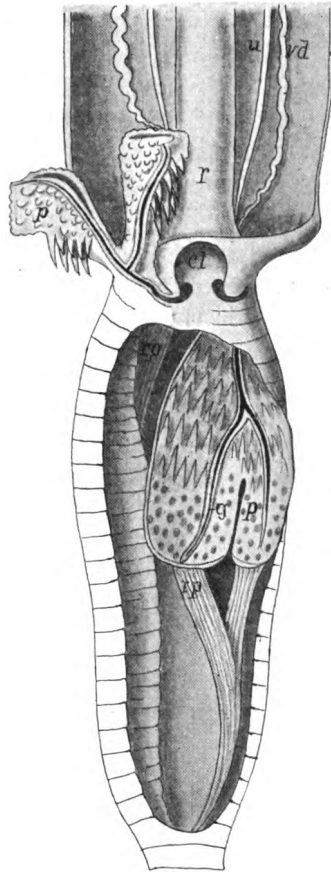


FIG. 389.

though much smaller in the female.) With further growth these develop retractor muscles and are drawn back into pockets (fig. 389). Each hemipenis, which may be notched or bifid at the tip, has a somewhat spiral groove on the medial surface for the passage of the spermatozoa. These hemipenes are everted for copulation and are retracted at other times.

In the other sauropsida there is a single penis, developed from the same

anlagen as in the mammals. In its simplest form this penis is a thickening of the ventral wall of the cloaca (figs. 390, 391), the upper surface of which bears a longitudinal groove for the passage of the sperm. Below this is a longi-

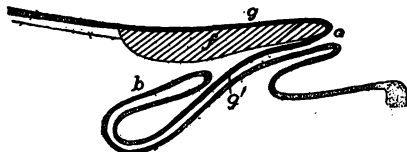


FIG. 390.—Ventral cloacal wall and penis of *Rhea* (schematized), after Boas. *b* blind sac; *f*, corpus fibrosum; *g*, seminal groove; *g'*, its continuation along blind sac; *o* opening of blind sac. Mucous membrane dotted, seminal groove black.

tudinal band of fibrous tissue (corpus fibrosum), sometimes in places divided into right and left halves. Between this and the surface is cavernous tissue with large spaces which, when filled with blood, render the whole firm and enlarged

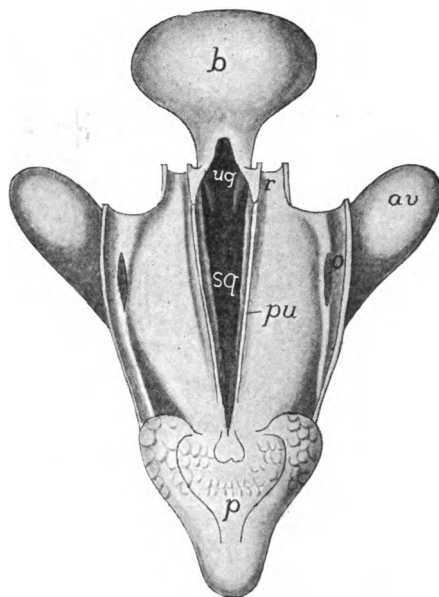


FIG. 391.—Cloacal region of adult turtle (*Emys lutaria*), after von Moller. The rectum and cloaca have been laid open from the dorsal surface and the urogenital sinus exposed. From the opening of the sinus into the cloaca a seminal groove extends along the ventral cloacal surface and can be cut off by a pair of folds (plicae urorectales) from the cloacal cavity. *av*, anal vesicle; *b*, urinary bladder; *o*, opening of anal vesicle into cloaca; *p*, penis, exserted; *pu*, plicae urorectales; *r*, rectum; *sg*, seminal groove; *ug*, urogenital groove.

(erectile tissue). The tip of the structure is produced as a genital prominence which can be traced in mammals as the glans penis. A homologous structure, the clitoris, is developed in the female, where all other parts are lacking. Only a few birds (ostriches, ducks, geese, swans, etc.) have penial structures.

Several reptiles have cloacal glands (a single dorsal pair in snakes, a lateral pair added in lizards) of uncertain function. The crocodiles have a pair of 'musk-glands' in the same region, the distal end of their ducts being protrusible. The adrenal glands of the sauropsida are intimately associated with each other, the trabeculæ of suprarenals and interrenals being commingled except in lizards and turtles where the suprarenal tissue is on the dorsal side of the interrenal.

MAMMALS.—In the mammals but two pronephric tubules are outlined in development and these are never functional excretory organs. The pronephric duct is first a solid cord on the surface of the nephrotomic segments and later it becomes canalized. Of the fate

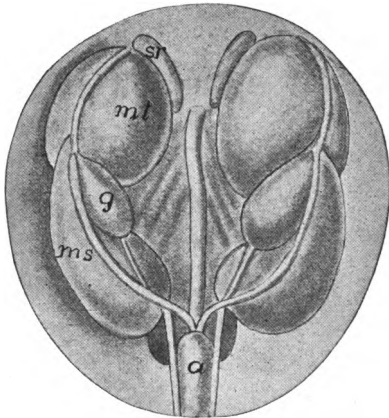


FIG. 392.—Urogenital organs in pig embryo 67 mm. long, after Klaatsch. *a*, allantois, *g*, gonad; *ms*, *mt*, meso- and metanephroi; *sr*, adrenal.

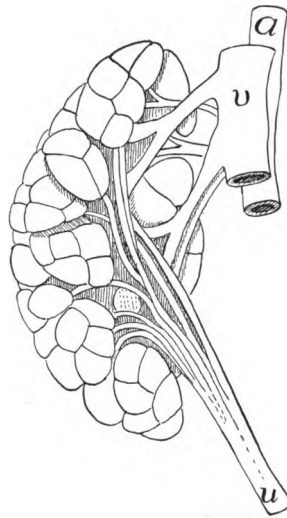


FIG. 393.—Lobulated kidney (metanephros) of otter, *Lutra canadensis* (Princeton, 2234). *a*, aorta; *u*, ureter; *v*, postcava.

of the pronephros little is known. The mesonephros, on the other hand, is an important structure in foetal life (fig. 392), and in marsupials and monotremes it continues to function for some time after birth. Later it disappears in all, with the exception of the parts concerned in the formation of the efferent ductules of the testes, and some other inconsiderable remnants in both sexes (fig. 368, *C*, *D*). Nephrostomes are formed only in *Echidna*, and in some rodents no glomeruli occur.

The permanent kidney (metanephros) is, in the young stages, lobulated, a result of the peculiar development (p. 344), the lobules

corresponding to the diverticula given off from the apex of the ureter, each lobule having its own duct. This condition is retained in adult elephants, some ungulates, carnivores (fig. 393) and primates, and especially in the aquatic species (whales, seals), the lobules being most numerous (200+) in some whales. In all other species the ducts fuse and the lobules unite later into a compact mass lying in the lumbar region near the last rib.

Each kidney has a peculiar shape (giving rise to the adjective reniform), convex on the lateral, concave on the medial side, the con-

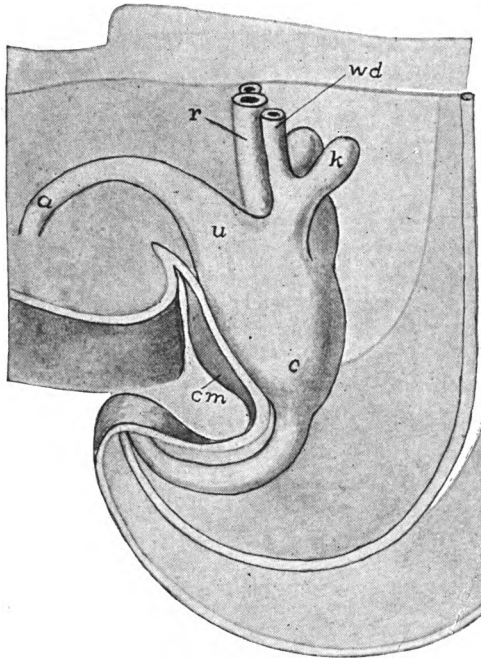


FIG. 394.—Model of cloacal region of human embryo, 6.5 mm. long, after Keibel; *a*, allantois; *c*, cloaca; *cm*, cloacal membrane; *k*, outgrowth to form kidney and ureter; *r*, rectum; *u*, where bladder will develop; *wd*, Wolffian duct.

cavity being the **hilum**, from which the ureter arises and where the renal artery and vein connect with the kidney. Except in *Echidna*, there is a cavity, the **pelvis of the kidney** just inside the hilum, into which one or several papillæ project from the opposite wall, each bearing the openings of numerous collecting tubules (p. 345). In section the kidney shows two different textures, even to the naked eye. The outer **cortex** appears granular, because there are collected the Malpighian bodies and the convoluted tubules, while the inner

medulla is radially lined, since here are the straight portions of Henle's loops and the collecting tubules. Cortex and medulla form two series of interlocking pyramids, the result of the primitive lobulation of the metanephros.

The ureters, the history of which is given on p. 344, are free for most of their course. In the early stages they open at the base of the allantoic outgrowth (p. 346) into the same part of the cloaca as do the reproductive ducts (fig. 394), this region being somewhat separated from the rest as a **urogenital sinus**, the individuality of which becomes

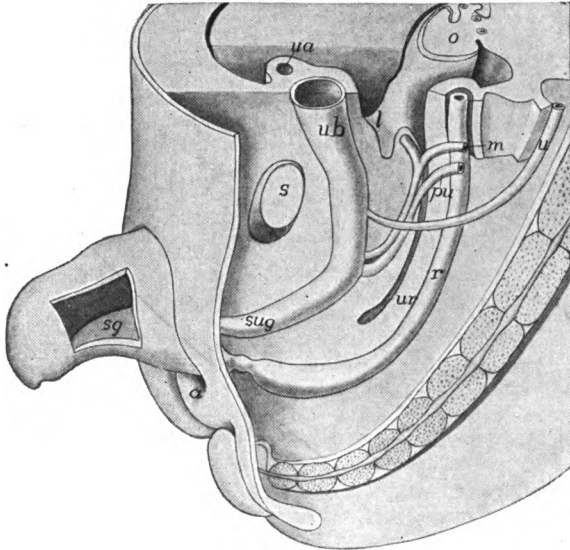


FIG. 395.—Model of pelvic region of human embryo 25 mm. long, after Keibel. (Compare with fig. 394.) *a*, anal opening; *l*, lateral ligament of uterus; *m*, Müllerian duct; *o*, ovary; *pu*, primitive ureter (Wolfian duct); *r*, rectum; *s*, symphysis pubis; *sg*, septum of genital protuberance; *sug*, urogenital sinus; *u*, ureter; *ub*, urinary bladder; *ur*, recto-uterine excavation.

more marked with increasing age (fig. 395, *sug*). In the monotremes this condition is permanent, the ureters opening on papillæ opposite the base of the allantois, the proximal portion of which expands to form the **urinary bladder**. In all other mammals the openings of the ureters is included in the bladder and in these the urine only reaches the urogenital sinus by the allantoic stalk, now called the **urethra**, a name which is applied in the male to the whole tube leading to the exterior, which can be described only after a consideration of the reproductive organs.

In the history of the reproductive organs the following parts are

concerned; the embryonic excretory organs (mesonephroi), and their (Wolffian) ducts; the gonads; the Müllerian ducts; the cloaca, and the anlagen of the external genitalia which arise in the anterior or ventral wall of the urogenital sinus.

In the early stages the gonads are situated anteriorly to the kidneys. The ovaries are spherical or oval and are equally developed

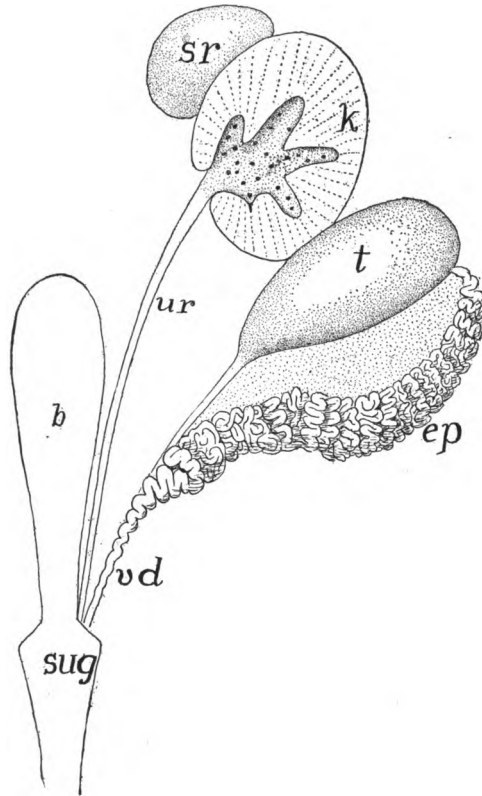


FIG. 396.—Urogenital organs of male *Ornithorhynchus*, after Gegenbaur. *b*, bladder; *ep*, epididymis; *k*, kidney opened, showing ends of collecting tubules; *sr*, adrenal; *sug*, urogenital sinus; *t*, testis; *ur*, ureter; *vd*, vas deferens.

except in the monotremes where the left is the larger (*cf.* birds) and it is of interest that eggs—one in *Echidna*, two in *Ornithorhynchus*—have been found only in the left oviduct. The ovaries remain near their early position in the monotremes, while in all other mammals they pass farther back, but never outside of the pelvis. They are supported by the mesovaria which are attached to the median side of the double fold of the peritoneum which supports the mesonephros.

When the Wolffian body degenerates the fold becomes the **broad ligament** while another fold continues down the Müllerian duct as the **ligament of the ovary**. In some mammals the ovaries have, in addition, a special fold of the peritoneum, which in the rats and mice encloses the ovary, the ostium tubæ connected with its opening.

The testes are relatively small and are shaped much like the ovaries and at first they are at about the same level. The outer surface is smooth, a fibrous envelope, the tunica albuginea, having developed around them, which sends trabeculæ inward, dividing the seminiferous tubules into lobules. Except in the monotremes (fig. 396) the testes descend farther into the pelvic cavity, remaining permanently in the pelvis in many insectivores, some edentates, elephants, whales and *Hyrax*. In other groups they pass outside the pelvic cavity to be enclosed in a special sac, the **scrotum**. The testes

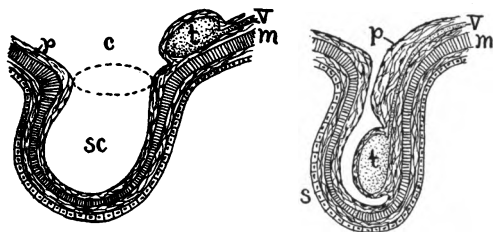


FIG. 397.—Schematic representation of the descent of the testis, after O. Hertwig. *c*, abdominal coelom; *m*, transverse abdominal muscle, *p*, peritoneum; *s*, scrotum; *sc*, coelom of scrotum; *t*, testis; *v*, vas deferens.

are supported by a cord, the **gubernaculum**, the homologue of both ligaments of the ovary.

The change in position of ovary and testis is accomplished in part by the unequal growth of body wall and the supporting ligaments. In the case of the male this **descent of the testis** is complicated. In outline it is as follows: By the unequal growth of gubernaculum and body wall the testes are drawn down into the scrotum which is a protruding part of the body wall into which a part of the coelom extends (fig. 397). This wall is formed in part from the genital folds (see copulatory organs, below) which surround the genital eminence. It lies in front of the penis in the marsupials, behind it in all placental mammals. When the canal connecting the cavity of the scrotum (**bursa inguinalis**) remains open (fig. 397, *B*) as it does in marsupials, bats, rodents, insectivores, etc., the descent is temporary, the testes being withdrawn into the peritoneal cavity at the close of the breeding season by the **cremaster muscle**, developed from the transverse abdominal muscle. In other mammals the descent is permanent, though sometimes it does not occur until the time of sexual maturity.

Two regions are differentiated in the Müllerian ducts of the female

monotremes (figs. 398, 399, *A*, 400, *I*), an anterior **Fallopian tube** and a more posterior **uterus**, the lines between the two not being sharply drawn. The Fallopian tube connects with the cœlom by a broad and fringed ostium, while the tube itself secretes the albumen which surrounds the eggs. The uterus is more muscular and its walls form the horny shell (with calcareous deposits in the duckbill) around the

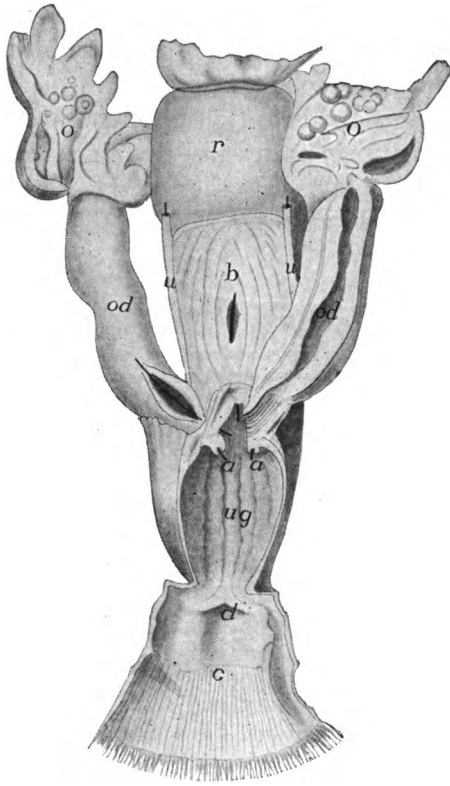


FIG. 398.—Female genitalia of *Echidna*, after Owen. *a*, openings of ureters into, *ug*, urogenital sinus; *b*, bladder, a bristle passing into urogenital sinus; *c*, cloaca; *d*, opening of rectum into cloaca; *o*, ovary; *od*, oviduct, the lower part uterine, *r*, rectum; *u*, ureters.

egg. Distally each uterus opens directly into the urogenital sinus which connects with the cloaca and so with the exterior (fig. 398).

In all other mammals the lower end of the Müllerian duct, between the uterus and the urogenital sinus, is differentiated as a **vagina** to receive the copulatory organ of the male. In the marsupial there are two vaginae, and in some the vaginae of the two sides fuse near the uterus so that a cæcal pocket results (fig. 399, *B*), and in a few this

pocket also connects with the urogenital sinus so that a third vagina occurs.

In all placental mammals there is a fusion of the posterior ends of the Müllerian ducts, which in the more primitive forms only includes the vaginal region, the result being a single vagina, with two uteri connected, each with its own opening (os uteri) into the vagina

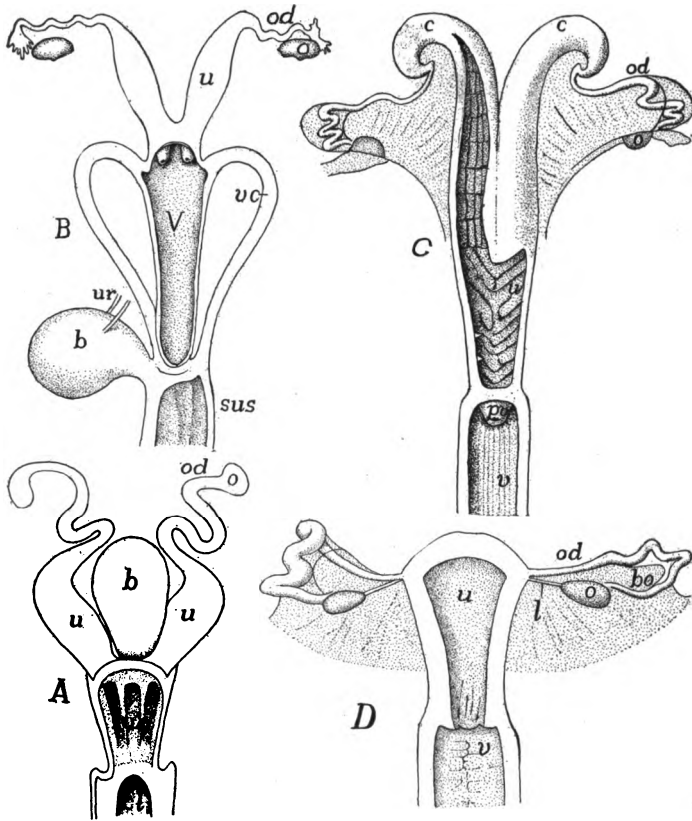


FIG. 399.—Uteri of (A) *Ornithorhynchus*; (B) *Halmaturus*; (C) sheep and (D) *Inuus*, after Gegenbaur. *b*, bladder; *bo*, bursa ovarica; *c*, cornua uteri; *cl*, cloaca; *l*, ligament of ovary; *o*, ovary; *od*, oviduct (Fallopian tube); *pv*, processus vaginalis; *sus*, *sug*, urogenital sinus; *u*, uterus; *ur*, ureter; *v*, vagina; *vc*, vaginal canals.

(uterus duplex, fig. 400, II). This occurs in most rodents. Still higher in the scale (carnivores, ruminants, horse and pig) the fusion is carried farther, so that there is a single os uteri and the uteri are fused only at the lower ends (uterus bipartitus, fig. 400, III). Again the fusion may be carried farther (uterus bicornis, fig. 399 C) in which the double origin is still shown in the two horns at the proximal end.

Lastly, as in primates (figs. 399, *D*; 400, *V*, *VI*) the fusion is complete and a **uterus simplex** occurs, the double nature being shown only by the two Fallopian tubes.

The reproductive duct of the male is the Wolffian duct which is connected with the testis by the epididymis already described. There are numerous small tubules, the homologues of the efferent ductules of the lower vertebrates, and like them connected by vessels which correspond to the longitudinal canals. The upper end of the Wolffian duct (now called the **vas deferens**) is greatly coiled, and the

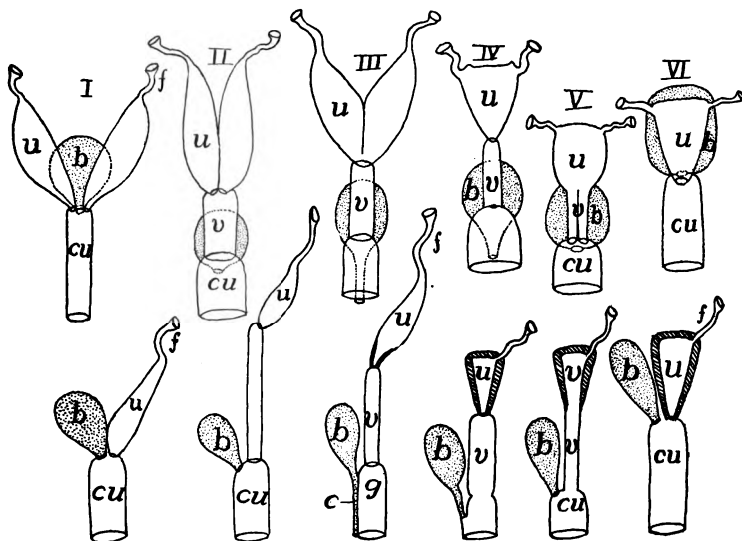


FIG. 400.—Dorsal and side views of female genital structures in *I*, monotreme; *II*, *Orycteropus* (uterus duplex); *III*, many monodelphs (*Uterus bipartitus*); *IV*, most monodelphs; *V*, *Bradypus*; *VI*, *Dasypus*; *b*, bladder; *cu*, urogenital sinus; *f*, Fallopian tube; *g*, genital sinus; *u*, uterus; *v*, vagina.

lower portion opens into the urogenital sinus, or urethra, the walls of which are muscular, forming an **ejaculatory duct**.

In the female the Wolffian duct and the mesonephros are largely lost in the adult, the mesonephros forming a small collection of tubules near the anterior end of the ovary which are known as the **parovarium**. In the male the Müllerian duct is also largely lost, the lower portion sometimes persisting as a small blind tubule imbedded in the prostate gland and known as the **uterus masculinus**.

In the testes, between the tubules, are small aggregates of cells known as **interstitial cells**, which have recently been shown to be glands with internal secretion. In man their products, which pass into the blood, apparently cause the assumption of the secondary male characters—growth of hair on the face, change of voice, etc.—at the time of puberty. There would also seem to be

some analogous structure in the ovary governing the development of female characteristics and controlling some of the features of menstruation.

There are a number of accessory glands connected with the genital ducts, these being usually better developed in the male than in the female. Only the more prominent are mentioned here. The **seminal vesicles** (present in some rodents, bats, insectivores and in ungulates and primates) are a pair of tubular or saccular glands opening into the vasa deferentia just before their entrance into the urogenital canal. The **prostate glands**, which occur in all placental mammals with the exceptions of edentates and whales, are connected with the urogenital canal. Farther along the canal are **Cowper's glands** which occur in almost all mammals as scattered bodies or aggregated into larger masses, and surrounded by smooth muscle.

Concerning the functions of these glands considerable uncertainty exists. From the fact that removal of the prostate and the seminal vesicle in rats prevents fertilization, and the further fact that the secretion of the seminal vesicles increases the activity of the spermatozoa, it seems probable that they

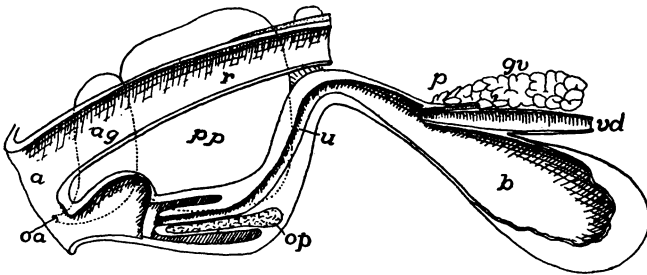


FIG. 401.—Diagram of male genitalia of beaver, *Castor canadensis*, after Weber. *a*, anus; *ag*, anal gland; *b*, urinary bladder; *gv*, gland of vas deferens; *oa*, opening of anal gland; *op*, os penis; *p*, prostate; *pp*, preputial gland; *r*, rectum; *u*, ureter; *vd*, vas deferens.

are of great importance in connexion with fertilization. Then it has been shown that in some instances the coagulation of the secretion of these glands closes the vagina after copulation has occurred, thus preventing the exit of the sperm.

In the monotremes the urogenital sinus empties into the cloaca, from which waste from the digestive canal as well as urinary and reproductive products pass to the exterior through a single opening (whence the name monotreme). In all other mammals there is a more or less complete separation of fæcal and urogenital matter. This is accomplished by a horizontal partition which divides the cloaca into a dorsal rectum and a ventral urogenital portion, the wall between them being the **perineum**. This is but slightly developed and not appearing from the exterior in marsupials, where there is an inpushing of the external skin so that only one opening is visible. The same is true in a less degree in rodents (fig. 401) and insectivores.

This pit is not a cloaca, since it is ectodermal in origin, while the cloaca is derived from the entodermal part of the digestive tract.

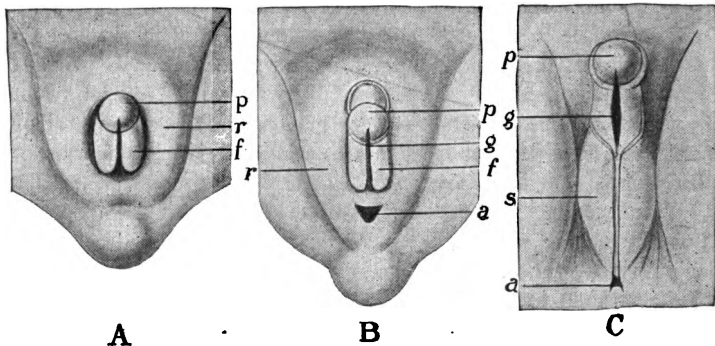


FIG. 402.—Development of the male external genitalia of man, after O. Hertwig. *A*, indifferent stage from which either sex may develop; *B*, early, and *C*, later stages; *a*, anus; *f*, genital folds; *g*, urogenital groove; *p*, genital prominence; *r*, genital ridge; *s*, scrotum.

In the monotremes the penis (fig. 403, *I*) is still cloacal in position, but there is an advance over the sauropsida in that the groove on

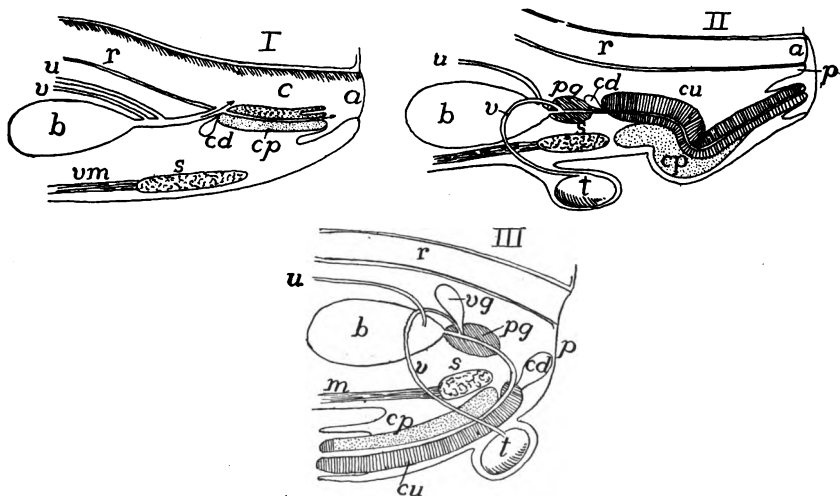


FIG. 403.—Diagrams of male urogenitalia in *I*, monotreme; *II*, marsupials; and *III*; monodelphs, after Weber. *a*, anus; *b*, bladder; *c*, cloaca; *cu*, corpus cavernosus urethra, *cp*, corp. cav. penis; *cd*, Cowper's gland; *p*, perinaeum; *pg*, prostrate gland; *r*, rectum; *s*, symphysis pubis; *t*, testis; *u*, ureter; *v*, vas deferens; *vg*, vesicular gland; *vm*, ventral muscles.

the dorsal surface has been converted into a canal which carries both urine and sperm. The whole structure can be protruded and retracted into a sheath formed from the loose mucous membrane of the

cloaca. As stated above, in all other mammals the connexion of the urogenital sinus with the cloaca is lost in the early stages, though in the lower groups the capacity of protrusion and retraction of the penis is retained.

In both sexes of the other mammals the same anlagen of the external genitalia are found. These consist of the genital prominence already mentioned, which is formed from the ventral or anterior wall of the cloaca. This soon protrudes from the opening and, when the perineum is formed, two thickenings appear on either side, a more medial **genital fold** and a larger and lateral **genital ridge**, these extending back nearly to the level of the anus (fig. 402). In the female the genital prominence never develops much farther, while the folds and ridges become the **labia minora** and **majora**. In the male a groove is formed on the primitively dorsal surface of the prominence, this continuing into the cloaca. Then the folds grow together behind the prominence, closing the groove to a tube, the urethra, while the prominence becomes the **glans penis**. A similar growth of the genital ridges toward the median line results in the formation of the outer wall of the scrotum.

In the lower mammals there is the same retractile condition of the penis as in the monotremes (figs. 401, 403, *II*), but in the higher groups it is permanently exerted (fig. 403, *III*). In the marsupials the tip of the penis is frequently bifurcate, corresponding to the two vaginæ of the female. In many rodents, bats, many carnivores, whales and a few primates a **penis bone** is developed in the middle line of the intromittent organ (fig. 401). In all there are the same corpora fibrosa and cavernosa as in the sauropsida.

NUTRITION AND RESPIRATION OF THE EMBRYO—FETAL ENVELOPES

In all vertebrates except the mammals there is enough nourishment stored in the egg to carry the young through its development up to the point where it hatches and shifts for itself. In the cyclostomes, dipnoi and amphibia this nourishment (**food-yolk** or **deutoplasm**) is soon enclosed by the body wall. In ganoids and teleosts, where it is relatively larger in amount, it forms for a time a projecting mass enclosed in a **yolk sac**, and this condition reaches its extreme in the elasmobranchs and sauropsida. The yolk sac, in the fishes, is an extension of the intestine and the body wall, and is richly supplied by vitelline arteries and veins which are derivatives of the omphalomesenteric vessels (p. 309). In the sauropsida, owing to the development of the amnion and the consequent separation of the non-embryonic somatopleure from the yolk, the yolk sac is composed of

the splanchnopleure alone, but it has homologous blood-vessels. In the mammals (monotremes excepted) the yolk is greatly reduced and the yolk sac (here often called the **umbilical vesicle**) is vestigial in character.

The vitelline vessels take the yolk and carry it into the body where it is utilized in building the embryo, all of it being eventually metabolized and used by the cells. The rich supply of capillary vessels in the sac also forms an efficient respiratory apparatus. In the viviparous sharks villi are developed on the oviducal lining and these afford a means of exchange of gases with the embryo, and for getting rid of the nitrogenous waste. It is a question how far there is a transfer of food by the same means. In some species of *Mustelus* and *Carcharias* the villi fit into depressions in the yolk sac, thus forming an analogue to the placenta of the mammals—a **vitelline placenta**—though formed in a greatly different manner.

The viviparous teleosts have saccular ovaries, and the development of the egg takes place in the cavity, the walls of which at the breeding season become villous. In the viviparous *Salamandra atra* only one egg develops and this leaves the mother in the adult shape. The other eggs degenerate and are used as food by the one. There is also a modification of the lining of the oviduct in this species which allows some blood to escape and this gives additional nourishment.

In the amniotes the yolk sac reappears and there are, in addition, two other foetal structures which are peculiarly characteristic, the allantois and the amnion, to which reference has been made in the preceding pages.

The amnion usually arises as a fold of the somatic wall of the coelom in front and on either side of the embryo (fig. 404), later followed by a similar tail fold. These folds extend upward and then inward, until they finally meet above the embryo, thus enclosing it in an amniotic cavity, filled with an amniotic fluid. These folds fuse in the middle line, the two sides of the fusion breaking through so that above the wall of the amniotic cavity—the **true amnion**—there is a second cavity, a part of the extraembryonic coelom, directly continuous with the coelom of the body. This cavity is bounded externally by the dorsal part of the amniotic fold, which is called the **serosa, false amnion** or **chorion**. The serosa lies immediately below the vitelline membrane of the egg.

In a number of mammals the amniotic cavity arises by a splitting of the embryonic area in such a way that the results are practically similar to those

described above. Little is known of the phylogeny of the amniotic structures, which are without parallel in the animal kingdom, except in the scorpions where

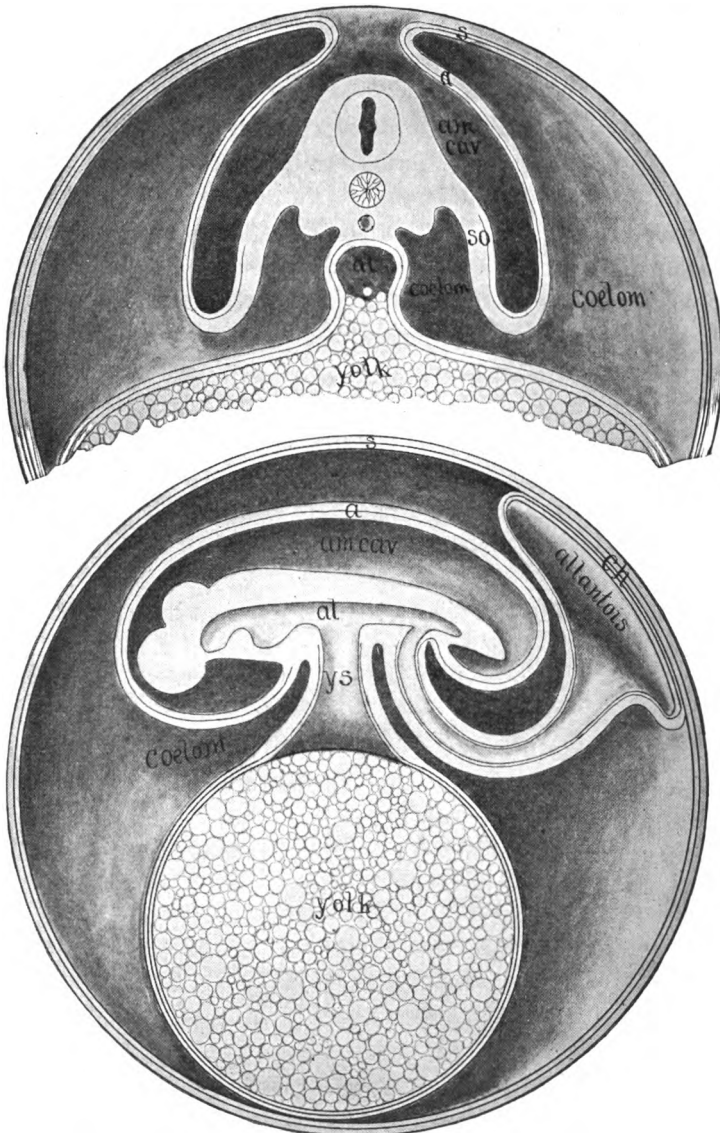


FIG. 404.—Diagrams of the development of amnion and allantois. Upper figure earlier, transverse section; lower later, longitudinal. *a*, amnion; *al*, alimentary canal; *am. cav.*, amniotic cavity; *ch*, beginning of placental area; *s*, serosa; *so*, somatopleure; *ys*, yolk stalk.

similar structures arise in the same way. Of course there is no phylogenetic connexion between the two. It has been suggested that there may be a tendency

for the embryo to sink into the yolk and that the amnion is to prevent its being completely covered by this substance. It should be noted that the amnion only occurs in the terrestrial forms, and that it results in the complete envelopment of the embryo by a fluid medium which acts like a water cushion, tending to prevent injuries which might accompany the deposition of the egg on the land.

The homologue of the **allantois** is found in the urinary bladder of the amphibia. It is an outgrowth from the ventral side of the hinder end of the digestive tract and consists of a lining of entoderm, covered externally with the splanchnic layer of the mesoderm—is developed solely from the splanchnopleure—and projects into the coelom (fig. 404, lower). In its outgrowth it carries with it branches of the hypogastric blood-vessels, the allantoic arteries and veins (fig. 329, usually there is but a single vein). As it develops, it extends into the exocoelom, its distal end swelling into a large sac, connected with the digestive tract by a slender stalk. Usually it extends to the chorion and fuses with it, and the sac, flattening out, may gradually extend until the embryo and the amnion are nearly enclosed by it. In some cases the amnion expands and fuses with one side of the allantois.

In the sauropsida the allantois (and its covering chorion) comes eventually to lie just beneath the shell, and, as the latter is very porous and the allantois richly vascular, the latter is in position to function in respiration. As the embryo increases in size, the side walls of the body gradually close in, ventral to the embryo, until they reach the stalks of the yolk sac and the allantois. In this way these structures come to be connected with the body by a narrow band (the **navel** or **umbilical cord** of mammals) in which the allantoic and vitelline blood-vessels run.

The mammals vary from this account of the allantois, but the differences can be reconciled with the conditions in the sauropsida. In the majority of the mammals there is the same union of allantois and chorion, and from the union the peculiarly mammalian structure, the placenta, is formed.

The **placenta** is a more or less intimate union of the allantoic region of the embryo with the wall of the uterus of the mother. It serves for the nutrition and respiration of the growing young. For a comprehension of its structure a few details of the composition of the uterus are necessary. The wall of the uterus has an outer coat, a part of the peritoneum, inside of which is a thick muscular layer, this being followed by a mucous layer (**mucosa**) which consists largely

of connective tissue ramified by numerous blood-vessels and by branched glands which are merely diverticula of the epithelium lining the cavity of the uterus (fig. 405).

Except in the monotremes, the eggs, fertilized in the Fallopian tube, descend into the uterus and there become implanted, either in the cavity or actually enveloped in the mucosal wall. In the marsupials and in some other forms the yolk sac is large and nearly encloses the whole embryo and its amnion, and so leaves but a small space where the allantois could possibly reach the chorion. The yolk

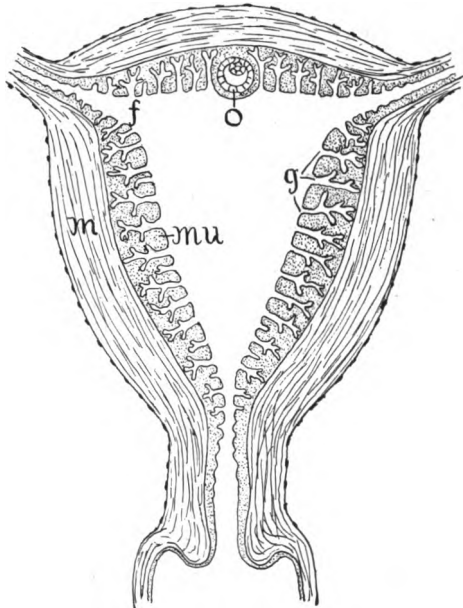


FIG. 405.—Diagram of uterus simplex. *f*, opening of Fallopian tube; *g*, uterine glands; *m*, muscular layer (no attempt to indicate direction of fibres); *mu*, mucosa; *o*, early implanted ovum.

sac is highly vascular and it becomes thrown into a number of folds which become inserted into corresponding folds of the uterus, the epithelial walls of which degenerate into a syncytial layer. By this **vitelline placenta**, some nourishment is transferred to the young. Among the marsupials, only in *Perameles* and *Dasyurus* does the allantois reach the chorion, this part now resting against the uterine syncytium, these two species having a true or allantoic placenta. All other mammals have the **allantoic placenta**, the details of its structure differing greatly in the separate orders and even within the same order. There is also much intergrading, but the following general

account will give the major heads under which the different types may be arranged.

In many mammals there is no very intimate connexion between the allantoic and the maternal tissues, and when birth occurs there is merely a separation between maternal and foetal parts. This division was formerly called **non-deciduata**, for which, for reasons not necessary to discuss here, the term **semiplacenta** has recently been introduced. In two marsupials (*Dasyurus* and *Peromeles*) this type occurs and in them the outer surface of the chorion remains smooth, the only union between maternal and foetal structures being merely the apposition of the two surfaces. A placenta of this sort is the **semiplacenta avillosa**.

In all other mammals the surface of the chorion becomes covered with projections (**villi**) into which loops of the allantoic blood-vessels extend, thus increasing the amount of absorptive surface. These villi are arranged in different ways. Thus in the whales, lemurs, and many ungulates they are uniformly distributed over the surface, and extend into the glands of the uterus, a layer of modified uterine epithelium intervening between villi and maternal blood-vessels (**semiplacenta diffusa**). In other ungulates (most ruminants) the villi are arranged in groups or **cotyledons**, the chorionic surfaces between the cotyledons being smooth (**semiplacenta diffusa**, the old **cotyledonary placenta**). In the dugong the villi form a ring or zone around the chorion, either end being free from them (**semiplacenta zonaria**).

In the remaining mammals the union of uterine and foetal structures is far more intimate. The uterine epithelium disappears early, and the villi extend into the remains of the glands, so that foetal and maternal tissues are inextricably intertwined. In these cases, when birth occurs, not only is the allantoic portion of the placenta cast off, but the mucosa splits and is lost with the other. The forms having this type were formerly classed as **deciduata**, now they are said to have a true placenta (**placenta vera**) composed of foetal and maternal portions. Of these there are two types with an intermediate condition, these being based as before on the distribution of the villi. In the **zonary placenta** (most carnivores) the villi form a ring around the chorion, and in the elephant and the Hyracoids cotyledons also occur. The second type, represented by bats, insectivores, rodents (fig. 406) and the higher primates (including man) the placenta is disc-like, occurring on only one side of the chorion (**discoidal pla-**

centa). In a few carnivores the conditions are intermediate between the discoidal and the zonary types, the zone being incomplete, with a gap of some extent.

It should be noted that in several forms with an allantoic placenta (horse, carnivores, rodents, and insectivores) there is also present a more or less well-developed vitelline placenta. In the case of the placenta vera there may be merely an invasion of the connective tissue by the chorionic villi, or the walls of the uterine blood-vessels may break down, so that the villi extend into the blood stream of the mother. In the primates the chorion at first has villi all over the surface, but later they are restricted as described above, so that there

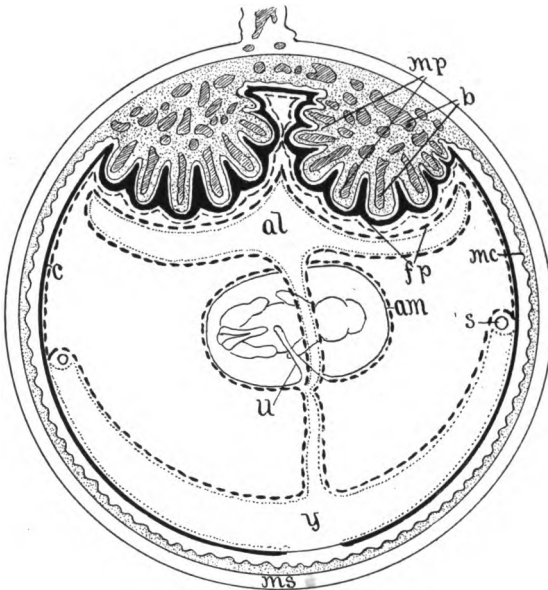


FIG. 406.—Schematic representation of the placenta and embryo of the rabbit, after Bonnet. *am*, amnion; *al*, allantois; *b*, blood sinuses; *c*, chorion; *fp*, foetal placenta; *mp*, maternal placenta; *ms*, muscular wall of uterus; *mc*, mucosa of uterus; *s*, sinus terminalis; *u*, umbilical cord; *y*, yolk sac.

are recognized two regions, the chorion frondosum, with villi, and the chorion læve, where they are absent.

That portion of the uterine wall which, in animals with a placenta vera, is cast off at birth is called the decidua. In man and the higher apes the embryo and its envelopes become enclosed (fig. 405, *o*) in the uterine wall, and in this case the portion which bounds the embryo toward the free surface is called the decidua capsularis (or reflexa), that opposite, the decidua serotina, while the rest of the mucosa is the decidua vera. In animals with a true placenta there would be extensive hemorrhage at the time of parturition, were it not that the contraction of the uterine muscles closed the blood-vessels. After birth, the lining epithelium of the uterus is restored by outgrowths from the bottoms of the uterine glands which are not cast off with the decidua.

BIBLIOGRAPHY

In the list of books and articles dealing with vertebrate morphology there have been included only such titles as are likely to be accessible in the majority of the laboratories of the country. Hence citations are largely from the periodicals and society publications of America and England and from the leading journals of the Continent. The student who wishes to go farther into any subject will find additional references in the papers quoted here and also in the works of Wiedersheim, Gegenbaur, Hertwig and others, while the current papers are listed in the *Anatomischer* and *Zoologischer Anzeiger*. For economy of space the titles have been abbreviated, but in such a way as to indicate something of the character and contents of the work.

JOURNALS AND TRANSACTIONS

Academy of Natural Sciences, Philadelphia, Proceedings.
American Naturalist.
American Journal of Anatomy.
American Academy of Arts and Sciences, Proceedings.
Anatomical Record.
Anatomischer Anzeiger.
Anatomische Hefte.
Archiv für Anatomie und Physiologie, Anatomische Abtheilung.
Archiv für mikroskopische Anatomie.
Biological Bulletin.
Boston Society of Natural History, Memoirs and Proceedings.
Ergebnisse der Anatomie und Entwicklungsgeschichte.
Jenaische Zeitschrift für Naturwissenschaften.
Journal of Anatomy and Physiology.
Journal of Comparative Neurology.
Journal of Morphology.
Mittheilungen aus der zoologischen Station zu Neapel.
Morphologische Arbeiten.
Morphologisches Jahrbuch.
Museum of Comparative Zoology. Bulletin.
Quarterly Journal of Microscopical Science.
Royal Society of London, Philosophical Transactions.
Zeitschrift für wissenschaftliche Zoologie.
Zoologischer Anzeiger.
Zoologischer Jahrbücher, Abteilung für Anatomie und Entwicklungsgeschichte.
Zoological Society of London, Proceedings and Transactions.

TEXT-BOOKS, MANUALS AND GENERAL WORKS

BALFOUR: Treatise on comparative embryology. 2 vols. London, 1880-82.
BARKER: Anatomical Terminology. Philadelphia, 1907. (Contains nomenclature of Basel Commission—'BNA.')

BARRELL: Rise of air-breathing vertebrates. Bull. Geol. Socy. America, 27, 1916.
BÖHM and DAVIDOFF: Histology, trans. by Huber, Philadelphia.
BRONN'S Klassen und Ordnungen des Thierreichs.
Works of JOHN SAMUEL BUDGETT. Cambridge, 1907. (Mostly teleosts, dipnoi and amphibia.)

- Cambridge Natural History. 10 vols. London, 1895-1909.
- CHORONSHITZKY: Entstehung der Milz, Leber, Gallenblase, Pankreas, und Pfortader-system bei verschiedenen Wirbelthiere. Anat. Hefte, 13, 1910.
- DAHLGREN and KEPNER: Principles of animal histology. N. Y., 1908.
- DOHRN: Studien zur Urgeschichte des Wirbelthierkörpers. Mitth. zool. Sta. Neapel, 3-17, 1881-1904.
- Festschrift zu 70sten Geburtstage Rudolf Leuckarts. Leipzig, 1892.
- GEGENBAUR: Vergleichende Anatomie der Wirbelthiere. 2 vols. Leipzig, 1898-1901. Handbuch der vergleichend. und experim. Entwicklungslehre (edited by O. HERTWIG). 3 vols. Jena, 1901-1906.
- HERTWIG: Lehrbuch der Entwicklungsgeschichte des Menschen und der Wirbelthiere, 9th edition, Jena, 1910. (An earlier edition, trans. by Mark. London, 1892).
- HILL: Primary segments of vertebrate head. Zool. Jahrb., 13, 1899.
- HUBRECHT: Die Säugetiereontogenese. Jena, 1909.
- HUXLEY: Manual of the anatomy of vertebrated animals. N. Y., 1872.
- HUXLEY: Scientific memoirs. 5 vols. London, 1898-1903.
- KEIBEL and others: Normentafeln zur Entwicklungsgeschichte: Pig (Keibel); hen (Keibel and Abraham); Ceratodus (Semon); rabbit (Taylor); Lacerta (Peter); deer (Keibel); Tarsius (Hubrecht); man (Keibel and Elze); Acanthias (Scammon).
- KINGSLEY: Text-book of vertebrate zoology. N. Y., 1899.
- LANKESTER: A treatise on zoology. London, 1900-(9 vols. published).
- MINOT: Human embryology. N. Y., 1892.
- MINOT: Bibliography of vertebrate embryology. Memoirs Boston Socy. Nat. Hist., 4, 1892.
- MCMURRICH: Development of the human body. Philadelphia, 1904.
- OPPEL: Lehrbuch der vergleichenden mikroskopischen Anatomie der Wirbelthiere. Jena, 1896-Incomplete, 8 pts. published.
- OWEN: Anatomy of vertebrates. 3 vols. London, 1866-68.
- PARKER: Course of instruction in zootomy. London, 1895.
- PARKER and HASWELL: Text-book of Zoology. 2 vols. London, 1897.
- SCHIMPKEWITZ: Lehrbuch d. vergl. Anatomie d. Wirbelthiere. Stuttgart, 1912.
- SCHNEIDER: Lehrbuch der vergleichenden Histologie. Jena, 1902.
- STANNIUS: Handbuch der Zootomie, zweiter Theil, Wirbelthiere. (Only fishes, amphibia and reptiles published) Berlin, 1856. (Invaluable as summary of older work.)
- STÖHR: Text-book of histology, trans. by Lewis. Philadelphia, 1910.
- VIALLETON: Elements de morphologie des vertebres. Paris, 1911.
- WIEDERSHEIM: Vergleichende Anatomie der Wirbeltiere; 7th ed., Jena, 1909. (Abridgment trans. by Parker, London, 1908.)
- WILDER: History of the human body. N. Y., 1909.
- WOODWARD: Outlines of vertebrate paleontology. Cambridge, 1898.
- ZIEGLER: Lehrbuch der Entwicklungsgeschichte der niederen Wirbeltiere. Jena, 1902.
- ZITTELL: Handbuch der Paläontologie. 5 vols. München, 1880-93. (A translation and adaptation by Eastman. 2 vols. London.)

MONOGRAPHS ON SINGLE SPECIES AND GROUPS

Cyclostomes

- AYERS and JACKSON: Morphology of Myxinoïds. Bull. Cincinnati Univ., 1, 1900. Skeleton and muscles. Jour. Morph., 17, 1901.
- COLE: Papers on anatomy of Myxine: Trans. Roy. Socy. Edinburg, 1905-12.

- DEAN: Development of *Bdellostoma*. *Quar. Jour. Micr. Sci.*, 40, 1897.
 HOWES: Affinities, interrelationships and systematic position of marsipobranchs, *Trans. Biol. Socy. Liverpool*, 6, 1892.
 SCOTT, W. B.: Entwicklungsgeschichte der Petromyzonten. *Morphol. Jahrb.*, 7, 1882.
 SCOTT, W. B.: Development of Petromyzon. *Jour. Morph.*, 1, 1887.
 SHIPLEY, A.: Development of Petromyzon. *Quar. Jour. Micr. Sci.*, 27, 1887.
 WOODLAND: Supposed gnathostome ancestry of Marsipobranchs and anatomy of *Geotria* and *Mordacia*. *Anat. Anz.*, 45, 1913.

Fishes

- ALLIS: Cranial muscles and nerves of *Amia*. *Jour. Morph.*, 12, 1897; of *Scomber*. same 18, 1903.
 AYERS: Anatomie und Physiologie der Dipnoer. *Jena. Zeitschr.*, 18, 1884.
 BALFOUR: Monograph on the development of Elasmobranch fishes. London, 1878. (Ext. *Jour. Anat. and Physiol.*, 1876-78.)
 BALFOUR and PARKER: Structure and development of *Lepidosteus*. *Phil. Trans.*, 1882.
 DEAN: Fishes, living and fossil. N. Y., 1895.
 DEAN: Development of garpike and sturgeon. *Jour. Morph.*, 11, 1895.
 DEAN: Chimæroid fishes and their development. *Carnegie Inst.*, 1906.
 GARMAN, S.: *Chlamydoselachus*, a living cladodont shark. *Bull. Mus. Comp. Zool.*, 12.
 GÜNTHER, A.: *Ceratodus*. *Philos. Trans. Royal Socy.*, 1871.
 GÜNTHER: Introduction to the study of fishes. Edinburgh, 1880.
 KELLICOTT: Development of vascular and respiratory systems of *Ceratodus*. *Mem. N. Y. Acad. Sci.*, 2, 1905.
 KERR: Development of *Lepidosiren*. *Quar. Jour. Micros. Sci.*, 45 and 46.
 LOCY: Contribution to structure and development of vertebrate head (*Acanthias*). *Jour. Morphol.*, 9, 1891.
 MÜLLER: Muskeln und Nerven der Brustflossen und Körperwände bei *Acanthias*. *Anat. Hefte*, 43, 1911.
 PARKER: Anatomy and physiology of Protopterus. *Trans. R. Irish Acad.*, 30, 1892.
 PFÜLLER: Kopfanatomie der Macruriden. *Jena. Zeitschr.*, 52, 1914.
 POLLARD: Anatomy and position of *Polypterus*. *Zool. Jahrbuch, Abth. Anat.*, 5, 1892.
 RAUTHER: Panzerwelse. *Zool. Jahrb. Abt. Anat.*, 31, 1911.
 WIEDERSHEIM: Skelet und Nervensystem von *Lepidosiren*. *Jena. Zeitschr.*, 14, 1892.
 WILSON: Embryology of sea bass (*Serranus*). *Bull. U. S. Fish Comm.*, 9, 1891.
 WRIGHT et al.: Anatomy of *Amiurus*. *Proceed. Canad. Inst.*, 2, 1884.

Amphibia

- BRAUER: Entwicklungsgeschichte und Anatomie der Gymnophionen. *Zool. Jahrbuch, Abth. Anat.*, 10, 12, 16, 1897-1902.
 COPE: Batrachia of North America. *Bull. U. S. National Museum*, 34, 1889.
 EMERSON: Anatomy of *Typhlomolge*. *Proc. Boston Socy. Nat. Hist.*, 32, 1905.
 FISCHER, J. G.: Anatomische Abhandlung über Perennibranchiaten und Derotremen. Hamburg, 1864.
 GAUFF: Anatomie des Frosches. 3 vols. Braunschweig, 1896-1904. Contains extensive bibliography.
 GOODRICH: Median and Paired Fins of Fishes. *Quar. Jour. Micr. Sci.*, 50, 1906.
 GÖTTE: Entwicklungsgeschichte der Unke. Leipzig, 1875.
 HOLMES: Biology of frog. N. Y., 1906.
 HOFFMANN: Amphibien, in *Bronn's Klassen und Ordnung des Thierreiches*.

- HUXLEY: Article Amphibia in *Encyclop. Brit.*, 9th edit., vol. 1.
 KINGSLEY: Systematic position of Cæcilians. *Tufts Coll. Studies*, 1, 1902.
 KLINKOWSTROM: Anatomie der Pipa. *Zool. Jahrbuch, Abth. Anat.*, 7, 1894.
 MILLER and others: Papers on anat. of *Necturus* (lung, circulation, brain). *Bull. Univ. Wisc.*, 33, 1900.
 PLATT: Development of cartilaginous skull and branchial and hypoglossal musculature of *Necturus*. *Morph. Jahrbuch*, 25, 1902.
 REESE: Anat. of *Cryptobranchus*. *Am. Nat.*, 40, 1906.
 SARASIN, P. and F.: *Entwicklungsgeschichte und Anatomie der ceylonischen Blindwühle Ichthyophis*. Wiesbaden, 1887-1890.
 SEELYE: Circulatory and respiratory systems of *Desmognathus*. *Proc. Boston Socy. Nat. Hist.*, 32, 1906.
 SMITH: Development of *Cryptobranchus*. *Jour. Morph.*, 23, 1912.
 WIEDERSHEIM: Anatomie der Gymnophionen. Jena, 1879.
 WILDER: Anatomy of *Siren lacertina*. *Zool. Jahrbuch, Abth. Anat.*, 4, 1891.

Reptiles

- ATWOOD: Visceral anatomy of blacksnake. *Washington Univ. Studies*, 4, 1916.
 BEDDARD: Visceral anat. of Lacertilia. *Proc. Zool. Socy. London*, 1888.
 CLARK: Embryology of turtle, in Agassiz, *Contrib. to Nat. Hist. of U. S.*, 2, 1857.
 CLARKE: Embryology of alligator. *Jour. Morph.*, 5, 1891.
 COE and KUNKEL: Anatomy of Aniella. *Trans. Conn. Acad. Arts and Sci.*, 12, 1906.
 COPE: Crocodilians, lizards, and snakes of North America. *Rept. U. S. Nat. Mus. for 1889, 1900*.
 HAY: Fossil turtles of North America. *Carnegie Inst.*, 1908.
 GÜNTHER: Anatomy of Hatteria [*Sphenodon*]. *Philos. Trans.*, 1867.
 HOFFMANN: Reptilia, in Bronn's *Klassen u. Ordnungen*, 3 vols., 1890.
 MARTIN and MOALE: How to dissect a chelonian. *N. Y.*, 1895.
 ORR: Embryology of lizard. *Jour. Morph.*, 1, 1887.
 REESE: Embryology of alligator. *Smithsonian Misc. Coll.*, 51, 56, 1908-10.
 REESE: *The Alligator and its allies*. *N. Y.*, 1915.
 SCHAUNSLAND: *Entwicklungsgeschichte der Hatteria [Sphenodon]*. *Arch. f. mikr. Anat.*, 57, 1900.

Birds

- BEDDARD: Structure and classification of birds. London, 1898.
 COUES: Osteology and myology of *Colymbus torquatus*. *Mem. Bost. Socy., Nat. Hist.*, 1, 1866.
 COUES: Key to North American birds. Boston, 1887.
 DUVAL: *Atlas d'embryologie*. Paris, 1888.
 FOSTER and BALFOUR: *Elements of embryology*. London, 1896.
 GADOW: Aves, in Bronn's *Klassen und Ordnungen d. Thierreichs*.
 LILLIE: Development of the chick. *N. Y.*, 1908. (Contains large bibliography.)
 MARSHALL: Anatomy of *Phænoptilus*. *Proc. Am. Philos. Socy.*, 44, 1905.
 PARKER: Morphology of duck and auk tribes. *Cunningham Mem. R. Irish Acad.*, 6, 1890.

Mammals

- CALDWELL: Embryology of Monotremata and Marsupialia. Part I. *Phil. Trans.*, 178, 1887.
 CARLSSON: Anatomie von *Notoryctes*. *Zool. Jahrb., Abth. Anat.*, 20, 1904.

- CUNNINGHAM: Text-book of Anatomy. 4th edit., N. Y., 1916.
- ELLENBERGER und BAUM: Vergleich. Anatomie der Haustiere. Berlin, 1900.
- GEGENBAUR: Lehrbuch d. Anatomie der Menschen, Leipzig, 1898. (New edition by Fürbringer in course of publication.)
- FLOWER and LYDDEKER: Mammals, living and extinct. London, 1891.
- GRAY: Anatomy, descriptive and surgical. Philadelphia.
- HERTWIG: Entwicklungsgeschichte des Menschen. Jena, 8th edit., 1906. (3rd edit. translated by Mark. N. Y., 1892).
- HIS: Anatomie menschlicher Embryonen. Leipzig, 1880-84.
- HUBRECHT: Descent of the primates. N. Y., 1897.
- KINGSLEY: Origin of the mammals. Science, 14, 1901.
- LEWIS: Gross anatomy of a 12-mm. pig. Am. Jour. Anat., 2, 1903.
- LEISERING und MÜLLER: Vergleich. Anatomie der Haussaugetiere. 1885.
- McMURRICH: Development of the human body. Philadelphia, 1904.
- MINOT: Laboratory text-book of embryology. Philadelphia, 1911.
- MIVART: The cat. London, 1881.
- MORRIS: Text-book of anatomy. Philadelphia.
- NEWMAN and PATTERSON: Development of the nine-banded armadillo (*Tatusia*). Jour. Morph., 21, 1910.
- OSBORN: Origin of mammals. Amer. Nat., 32, 1898.
- OSBORN: Age of mammals. N. Y., 1910.
- PIERSOL: Human Anatomy, Philadelphia, 1907.
- REIGHARD and JENNINGS: Anatomy of the cat. N. Y., 1901.
- SISSON: Anatomy of domestic animals, 2nd edit. Philadelphia, 1914.
- THYNG: Anatomy of a 7.8-mm. pig embryo. Anat. Record, 5, 1911.
- WEBER: Anatomisches über Cetaceen. Morph. Jahrbuch, 13, 1888.
- WEBER: Die Säugethiere. Jena, 1904.
- WIEDERSHEIM: Der Bau des Menschen als Zeugniß für seine Vergangenheit. Tübingen 1908.
- WILDER and GAGE: Animal Technology as applied to the cat. N. Y., 1892.
- WILSON, J. T., and HILL, J. P.: Development of *Ornithorhynchus*. Philos. Trans., B, 199, 1907.

COELOM, ABDOMINAL PORES

- AYERS: Pori abdominales. Morph. Jahrb., 10, 1885.
- BLES: On the openings in the wall of the body cavity of vertebrates. Proc. Roy. Soc. London, 62, 1897.
- BROMAN: Entwicklung und Bedeutung der Mesenterien und Körperhöhlen bei Wirbeltieren. Ergebnisse, 15, 1905.
- BROMAN: Entwicklung d. Pericardium und Zwergfells. Ergebnisse, 20, 1911.
- GEGENBAUR: Pori abdominales. Morph. Jahrb., 10, 1885.
- KLAATSCH: Morphologie der Mesenterialbildungen am Darmcanal der Wirbeltieren. Morph. Jahrb., 18, 1892.
- MALL: Development of the human coelom. Jour. Morph., 12, 1897.
- MATHES: Morphologie der Mesenterialbildungen bei Amphibien. Morph. Jahrb., 23, 1895.
- WEBER: Abdominalporen der Salmoniden nebst Bemerkungen über Geschlechtsorgane. Morph. Jahrb., 12, 1887.

INTEGUMENT

- BATELLI: Bau der Reptilienhaut. Arch. mikr. Anat., 17, 1879.
- BOAS: V. Wirbelthierekrallen. Morph. Jahrbuch, 23, 1895.

- BOAS:** Morphologie der Nägel, Krallen, Hufe und Klauen. *Morph. Jahrb.*, 11, 1884.
See also 21, 1894.
- BONNET:** Die Mammarorgane (Summary). *Ergebnisse*, 2, 1892; 7, 1898.
- BONNET:** Haarspiral und Haarspindel. *Morph. Jahrb.*, 11, 1886.
- BOWEN:** Epitrichium of human epidermis. *Anat. Anz.*, 4, 1889.
- BRAUER:** Leuchtorgane der Knochenfische. *Verhandl. zool. Gesellsch.*, 13, 1904.
- BURCKHARDT:** Luminous organs of selachians. *Ann. and Mag. Nat. Hist.*, VII, 6, 1900.
- DAVIES:** Entwicklung der Feder, u. s. w. *Morph. Jahrb.*, 15, 1889.
- DRASCH:** Giftdrüsen des Salamanders. *Verhandl. anat. Gessellsch.*, 6, 1892.
- V. EGGELING:** Phylogenie d. sog. Schenkelporen. *Jena. Zeitsch.*, 51, 1914.
- ESTERLY:** Poison glands of Plethodon. *Publ. Univ. Cal., Zool.*, 1, 1904.
- GOODRICH:** Dermal fin rays of fishes. *Quar. Jour. Micr. Sci.*, 47, 1904.
- GÖPPERT:** Phylogenie der Wirbelthierkralle. *Morph. Jahrb.*, 25, 1898.
- GREEN:** Phosphorescent organs in Porichthys. *Jour. Morphol.*, 15, 1900.
- HENNEBERG:** Entwicklung der Mammarorgane der Ratte. *Anat. Hefte*, 13, 1899.
- JAPHA:** Haare der Waltiere. *Zool. Jahrb., Abt. Anat.*, 32, 1911.
- JEFFRIES:** Epidermal system of birds. *Proc. Boston Socy. Nat. Hist.*, 22, 1883.
- JONES:** Development of the nestling feather. *Oberlin Lab. Bulletin*, 13, 1907.
- KERBERT:** Haut der Reptilien. *Archiv mikr. Anat.*, 13, 1876.
- KEIBEL:** Ontogenie und Phylogenie von Haare und Feder. *Ergebnisse*, 5, 1895.
- KERR:** Development of skin and derivatives in Lepidosiren. *Quar. Jour. Micros., Sci.*, 46, 1902.
- KRAUSE:** Entwicklung der Epidermis und ihrer Nebenorgane. *Handbuch der Entwicklungslehre*, 2, Th. 1, 1902.
- VON LENDENFELD:** Phosphorescent organs of fishes. *Challenger reports*, 22, 1887.
Summary in *Biol. Centralblatt*, 7, 1887.
- LEVIG:** Vascularisiertes Epithel. *Archiv mikr. Anat.*, 52, 1898.
- MAURER:** Vascularisierung der Epidermis bei Anuren. *Morph. Jahrb.*, 26, 1898.
- MAURER:** Haut-Sinnesorgane, Feder, und Haaranlagen, *Morph. Jahrb.*, 18, 1892; 29, 1893. See also 26, 1898.
- DE MEJERE:** Die Haare der Säugetiere und ihre Anordnung. *Morph. Jahrb.*, 21, 1894.
Feathers, 23, 1895.
- MUÏSE:** Cutaneous glands of toad. *Am. Jour. Anat.*, 9, 1909.
- NICOGLU:** Hautdrüsen der Amphibien. *Zeitschr. wiss. Zool.*, 56, 1893.
- O'DONOGHUE:** Growth changes of mammary apparatus of *Dasyurus*. *Quar. Jour. Micr. Sci.*, 57, 1911.
- PARKER:** Movement of melanophore pigment, especially in lizards. *Jour. Exp. Zool.*, 3, 1906.
- PARKER and STARRALL:** Color changes in skin of Anolis. *Proc. Am. Acad. A. and S.*, 40, 1906.
- POULTON:** Bill and hair of Ornithorhynchus. *Quarterly Jour. Micro. Sci.*, 36, 1894.
- PROFÉ:** Ontogenie und Phylogenie der Mammarorgane. *Anat. Hefte*, 11, 1898.
- PYCRAFT:** Interlocking of feathers. *Nat. Science*, 3, 1893.
- REED:** Poison glands of catfishes. *Amer. Nat.*, 41, 1907.
- REH:** Schuppen der Säugetiere. *Jena. Zeitsch.*, 29, 1895.
- ROMER:** Schuppen und Haare am Schwanz von Mus. *Jena. Zeit.*, 30, 1896. See also 31, 1898.
- SAWADSKY:** Larval Haftapparates bei Acipenser. *Anat. Anz.*, 40, 1911.
- SCHMIDT:** Integument von Voeltzkowia (lizard). *Zeit. wiss. Zool.*, 94, 1910.
- SCHLUDT:** Entwicklung von Schuppe und Feder. *Arch. mikr. Anat.*, 83, 1913.
- SCHULZ:** Giftdrüsen der Kröte und Salamander. *Archiv mikr. Anat.*, 34, 1889.
- SCHWALBE:** Farbenwechsel winterweisser Thiere. *Morph. Arbeiten*, 2, 1893.

- SEMON: Mammarorgane der Monotremen. *Morph. Jahrb.*, 28, 1899.
 SPENCER and SWEET: Hairs of Monotremes. *Quar. Jour. Mic. Sci.*, 41, 1899.
 STÖHR: Entwicklung des menschlichen Wollhaares. *Anat. Hefte*, 23, 1903.
 STRONG: Development of the primitive feather. *Bull. Mus. Comp. Zool.*, 40, 1902.
 WALLACE: Axillary gland of *Batrachus*. *Jour. Morphol.*, 8, 1893.
 WHIFFLE: Naso-labial groove of lungless salamanders. *Biol. Bull.*, 11, 1906.
 WILDER: Palms and soles. *Amer. Jour. Anat.*, 1, 1902.
 ZEITSCHMANN: (Odoriferous glands of Cervidæ). *Zeits. wiss. Zool.*, 74, 1903.

DERMAL SKELETON

- BOLDT: Ruckenschild der *Ceratophrys*. *Zool. Jahrb. Abt. Anat.*, 32, 1911.
 DANIEL: Anatomy of *Heterodontus*. I. Exoskeleton. *Univ. Calif. Pub., Zool.*, 13, 1914.
 GOETSCH: Hautknochenbildung bei Fischen und *Amia*. *Arch. mikr. Anat.*, 86, 1915.
 HASE: Schuppenkleid der Teleostier. *Jena. Zeitsch.*, 42, 1907.
 HASE: Morphol. Entwicklung der Ktenoidschuppen. *Anat. Anz.*, 40, 1911.
 HERTWIG: Placoidschuppen und Zähne der Selachier. *Jena. Zeitsch.*, 8, 1874.
 HERTWIG: Hautskelett der Fische. *Morph. Jahrb.*, 2, 1876; 5, 1879; 7, 1881.
 KLAATSCH: Morphologie der Fischenschuppen. *Morph. Jahrb.*, 16, 1890.
 NICKERSON: Development of scales of *Lepidosteus*. *Bull. Mus. Comp. Zool.*, 24, 1893.
 PARKER: Correlated abnormalities in scutes and plates of tortoise. *Amer. Nat.*, 35, 1901.
 RÖMER: Panzer der Gürteltiere. *Jena. Zeitsch.*, 27, 1892.
 TMS: Development and morphology of scales of some teleosts. *Quar. Jour. Micros. Sci.*, 49, 1905.
 WIEDERSHEIM: Histologie der Dipnoerschuppen. *Arch. mikr. Anat.*, 18, 1880.

SKELETON—GENERAL

- BAUR: Morphology of ribs. *Amer. Naturalist*, 21, 1887. *Jour. Morph.*, 3, 1889.
 (See *Anat. Anz.*, 9, 1883.)
 BAUR: Carpus and Tarsus der Wirbelthiere. *Zool. Anz.*, 8, 1885.
 BRAUS: Gliedmassenpropfung und Grundfragen der Skelettbildung. *Morph. Jahrb.*, 39, 1909.
 COPE: Vertebrates of the tertiary formations of the West. *Report U. S. (Hayden's) Geol. Survey*, 3, 1884.
 DEAN: Origin of paired limbs. *Amer. Nat.*, 36, 1902.
 GADOW: First and second visceral arches with reference to the homologies of the auditory ossicles. *Phil. Trans.*, 179, 1888.
 GAUPP: Schalleitenden Apparates bei den Wirbeltiere. *Ergebnisse*, 8, 1899.
 GAUPP: Schlafendgegend am Wirbelthiereschädel. *Morph. Arbeit.*, 4, 1894.
 GAUPP: Alte Probleme und neuere Arbeiten über Wirbelthiereschädel. *Ergebnisse*, 10, 1900.
 GAUPP: Fragen an d. Lehre vom Kopfskelett. *Anat. Anz., Ergänzungshefte*, 29, 1896.
 GAUPP: Unterkiefer der Wirbeltiere. *Anat. Anz.*, 39, 1911.
 GAUPP: Säugerpterygoid und Echidnapterygoid, u. s. w. *Anat. Hefte.*, 42, 1910.
 GEGENBAUR: Skelett der Gliedmassen der Wirbelthiere und der Hintergliedmassen der Selachier. *Jena. Zeitsch.*, 5, 1870.
 GEGENBAUR: Über das Archipterygium. *Jena. Zeitsch.*, 7, 1872.
 GEGENBAUR: Primäre und secundäre Knochenbildung. *Jena. Zeitsch.*, 3, 1867.
 GEGENBAUR: Untersuchungen zur vergl. Anatomie der Wirbelthiere. 3 parts, Leipzig, 1872.

- GÖTTE: Morphologie des Skelettsystems der Wirbelthiere. (Girdle and breastbone.) Arch. f. mikr. Anat., 15, 1878.
- HERTWIG: Zahnsystem der Amphibien und seine Bedeutung für die Genese des Skeletts der Mundhöhle. Arch. mikr. Anat., 11, 1874.
- HÖWES: Morphology of the sternum. Nature, 43, 1891.
- KINGSLEY: The ossicula auditus. Tufts Coll. Studies, 1, 1900.
- PARKER: Structure and development of the shoulder girdle and sternum. Ray Society, 1867.
- PARKER and BETTANY: Morphology of the skull. London, 1877.
- REYNOLDS: Vertebrate skeleton. Cambridge (England), 1897.
- THACHER: Median and paired fins. Trans. Conn. Acad., 3, 1877.
- THYNG: Squamosal bone in Tetrapoda. Tufts Coll. Studies, 2, 1906.
- WOODWARD: Vertebrate paleontology. Cambridge, 1898.
- WIEDERSHEIM: Gliedmassenskelett der Wirbelthiere. Jena, 1892.
- WINSLOW: Chondrocranium in the ichthyopsida. Tufts Coll. Studies, 1, 1898.
- ZITTELL: Handbuch der Palaontologie. München, 1884-93. (A translation of an abridgment, by Eastman, London, 1900.)

Fishes

- ADAMS: Skull of Anarrhichthys. Kansas Univ. Sci. Bull., 4, 1908.
- ALLIS: Cranium of Amia. Jour. Morph., 2, 1889; 14, 1898.
- ALLIS: Jaw bones and breathing valves of Polypterus. Anat. Anz., 18, 1900.
- ALLIS: Skull of Scomber. Jour. Morph., 18, 1903.
- ALLIS: Homologies of palatoquadrate of Selachians. Anat. Anz., 45, 1914.
- BALFOUR: Development of skeleton of paired fins of elasmobranchs. Proc. Zool. Socy. London, 1881.
- BOYER: Mesoderm in teleosts and its share in pectoral fin. Bull. Mus. Comp. Zool., 23, 1892.
- BRIDGE: Ribs in Polyodon. Proc. Zool. Socy. London, 1897.
- BROEMER: Kopf eines embryos von Chlamydoselachus u. d. Segmentirung des Selachierschädels. Jena. Zeitsch., 44, 1908.
- CARTIER: Entwicklungsgeschichte der Wirbelsäule. Zeitsch. wiss. Zool., 25, 1875.
- CORNING: Urwirbelknospen in der Brustflossen der Teleostier. Morph. Jahrb., 22, 1894.
- CRAMER: Skull of Sebastodes. Stanford Univ. Pub., 2, 1895.
- DANIEL: Anatomy of Heterodontus, II. Endoskeleton., Jour. Morphol., 26, 1915.
- DEAN: Cladoselache. Jour. Morph., 9, 1894.
- DEAN: Fin-fold origin of paired fins. Anat. Anz., 11, 1896.
- DERJUGIN: Entwicklung des Schultergürtels und Brustflosse bei den Teleostiern. Zeit. wiss. Zool., 96, 1910.
- DOHRN: Paarigen und unpaarigen Flossen der Selachier. Naples Mittheilungen, 5, 1886.
- FOOTE: Extrabranchials in elasmobranchs. Anat. Anz., 13, 1897.
- FÜRBRINGER: Visceralskelett der Selachier. Morph. Jahrb., 31, 1903.
- GADOW and ABBOTT: Evolution of vertebral column of fishes. Phil. Trans., 186B, 1895.
- GAUPP: Entwicklung der Schädelknochen b. d. Teleostiern. Anat. Anz., Ergänzungshefte zu 23, 1903.
- GEGENBAUR: Entwicklungsgeschichte der Wirbelsäule des Lepidosteus. Jena. Zeitschr., 3, 1867.
- GEGENBAUR: Untersuchungen zu vergleichenden Anatomie der Wirbelthiere. Leipzig, 1872. (Skull of elasmobranchs, girdles of fishes.)
- GEGENBAUR: Kopfskelett von Alepocephalus. Morph. Jahrb., 4, Suppl., 1878.

- GEIGENBAUR: Clavicula und Cleithrum. *Morph. Jahrb.*, 23, 1895.
- GEIGENBAUR: Flossenskelett der Crossopterygier und das Archipterygium der Fische. *Morph. Jahrb.*, 22, 1894.
- GEIGENBAUR: Über das Archipterygium. *Jena. Zeitsch.*, 7, 1872.
- GIBIAN: Hypobranchialskeletes der Haie. *Morph. Jahrb.*, 45, 1912.
- GOODRICH: Pelvic girdle and fin of Eusthenopteron. *Quar. Jour. Micr. Sci.*, 45, 1901.
- GOODRICH: Dermal finrays of fishes. *Quar. Jour. Micr. Sci.*, 47, 1904.
- GOODRICH: Development, structure and origin of fins of fishes. *Quar. Jour. Micr. Sci.*, 50, 1906.
- GÖPPERT: Morphologie der Fischrippen. *Morph. Jahrb.*, 23, 1896.
- GRASSI: Entwicklung der Wirbelsäule der Teleostier. *Morph. Jahrb.*, 8, 1882.
- HARRISON: Entwicklung der unpaaren und paarigen Flossen der Teleostier. *Arch. mikr. Anat.*, 46, 1895. See also 42, 1893.
- HASSE: Entwicklung der Wirbelsäule der Elasmobranchier. *Zeitsch. wiss. Zool.*, 55, 1892; Ganoiden, 57, 1893; Cyclostomen, 57, 1893.
- HAY: Vertebral column of *Amia*. *Field Columbian Museum, Zool. Publications*, 1, 1895.
- KLAATSCH: Vergleich. *Anat. der Wirbelsäule*. *Morph. Jahrb.*, 19-22, 1893-95.
- MAYER: Unpaaren Flossen der Selachier. *Naples Mittheilungen*, 6, 1885.
- PARKER: Structure and development of the skull in sharks and skates. *Trans. Zool. Socy. London*, 10, 1878.
- PARKER: Skeleton of Marsipobranchs. *Phil. Trans.*, 1883.
- PARKER: Structure and development of skull in Lepidosteus. *Phil. Trans.*, 1882; of sturgeons, same volume.
- POLLARD: Suspension of jaws in fishes. *Anat. Anz.*, 10, 1894.
- POLLARD: Oral cirri of siluroids and origin of head. *Zool. Jahrb., Anat. Abth.*, 8, 1895.
- SAGEMEHL: (several papers on skulls of fishes). *Morph. Jahrb.*, 9, 10, 17, 1884-1891.
- SEWERTZOFF: Visceralskelet der Cyclostomen. *Anat. Anz.*, 45, 1913.
- SCHALK: Entwicklung des Cranial und Visceralskeletts vom Petromyzon. *Arch. mikr. Anat.*, 83, 1913.
- SHUFELDT: Osteology of *Amia* (based on Francque). *Rept. U. S. Fish Commis. for* 1883, 1884.
- STARKS: Several papers. *Proc. U. S. Nat. Mus.*, 21-27, 1898-1904.
- SWINNERTON: Pectoral skeleton of teleosts. *Quar. Jour. Micr. Sci.*, 49, 1905.
- THACHER: Median and paired fins. *Trans. Conn. Acad.*, 3, 1878.
- THACHER: Ventral fins of ganoids. *Trans. Conn. Acad.*, 4, 1878.
- VEIT: Entwicklung des Primordialcranium von Lepidosteus. *Anat. Hefte.*, 44, 1911.
- WALTHER: Entwicklung der Deckknochen am Kopfskelett des Hechtes. *Jena. Zeitsch.*, 16, 1883.
- WELLS: Skull of *Acanthias*. *Jour. Morph.*, 28, 1917.
- WRIGHT: Skull and auditory organ of Hypophthalmus. *Trans. Roy. Soc. Canada*, 4, 1885.
- ZIEGLER: Hornfaden der Selachier und die Flossenstrahlen der Knochenfische. *Zool. Anz.*, 33, 1908.

Amphibia

- BROOM: Structure of mandible in Stegocephala. *Anat. Anz.*, 45, 1913.
- COPE: Hyoid and otic elements in batrachia. *Jour. Morph.*, 2, 1888.
- CREDNER: Stegocephalen und Saurier. *Zeitschr. deutsch. geolog. Gesellsch.*, 1881-1893.
- EGGELING: Aufbau der Skeletteile in Gliedmassen. *Jena*, 1911.
- FIELD: Entwicklung der Wirbelsäule der Amphibien. *Morph. Jahrb.*, 22, 1895.

- GADOW:** Evolution of vertebral column of amphibia and amniotes. *Phil. Trans.* 187 B, 1896.
- GAUPP:** Primordial-cranium von Rana. *Morph. Arbeiten*, 2, 1893.
- GÖPPERT:** Amphibienrippen. *Morph. Jahrb.*, 22, 1895.
- KINGSBURY and REED:** Columella auris in amphibia. *Jour. Morph.*, 20, 1909.
- MURRAY:** Vertebral column of certain urodeles. *Anat. Anz.*, 13, 1897.
- PARKER:** Structure and development of skull in urodeles. *Phil. Trans.*, 1877.
- PARKER:** Morphology of skull in Amphibia urodela. *Trans. Linn. Socy.*, Zool., 2, 1879.
- PARKER:** Structure and develop. of skull of common frog. *Phil. Trans.*, 1871.
- PARKER:** Struct. and dev. skull in Batrachia, Pt. II and III. *Phil. Trans.*, 1881.
- PARKER:** Struct. and dev. skull in urodeles. *Trans. Zool. Socy. London*, 11, 1882.
- PETER:** Schädel von Ichthyophis. *Morph. Jahrb.*, 25, 1898.
- PLATT:** Development of cartilaginous skull of Necturus. *Morph. Jahrb.*, 25, 1897.
- SHIMADA:** Wirbelsäule und Hüllen des Rückenmark von *Cryptobranchus japonicus*. *Anat. Hefte*, 44, 1911.
- TERRY:** Nasal skeleton of *Amblystoma*. *Trans. St. Louis Acad. Sci.*, 16, 1906.
- WHIPPLE:** Ypsiloid apparatus of urodeles. *Biol. Bull.*, 10, 1906.
- WIEDERSHEIM:** Kopfskelett der Urodelen. *Morph. Jahrb.*, 3, 1877.
- WILDER:** Skeletal system of *Necturus*. *Memoirs Boston Socy. Nat. Hist.*, 5, 1903.

Reptilia

- BAUR:** Osteologische Notizen über Reptilien. *Zool. Anz.*, 9 and 10, 1886-87.
- BAUR:** Pelvis of the Testudinata. *Jour. Morph.*, 4, 1891.
- BAUR:** Morphologie des Carpus und Tarsus der Reptilien. *Zool. Anz.*, 8, 1885.
- COPE:** Osteology of Lacertilia. *Proc. Am. Phil. Socy.*, 30, 1892.
- CORNING:** Neugliederung der Wirbelsäule bei Reptilien. *Morph. Jahrb.*, 17, 1891.
- COPE:** Degenerate scapular and pelvic arches in Lacertilia. *Jour. Morph.*, 7, 1892.
- FÜRBINGER:** Knochen und Muskeln der Extremitäten bei schlangenähnlichen Saurien Leipzig, 1870.
- GAUPP:** Chondrocranium von *Lacerta*. *Anat. Hefte*, 15, 1900.
- GÖTTE:** Wirbelbau bei Reptilien. *Zeitsch. wiss. Zool.*, 50, 1892.
- GÖTTE:** Entwicklung des Carapax der Schildkröten. *Zeit. wiss. Zool.*, 66, 1899.
- HAY:** Fossil turtles of North America. *Carnegie Inst.*, 1908.
- HOWES and SWINNERTON:** Development of skeleton of *Sphenodon*. *Trans. Zool. Socy. London*, 16, 1901.
- KINGSLEY:** Reptilian lower jaw. *Amer. Nat.*, 39, 1905.
- KUNKEL:** Development of skull of *Emys*. *Jour. Morph.*, 23, 1913.
- MARSH:** Numerous papers on fossil reptiles. *Am. Jour. Sci.*, 16-50.
- MOODIE:** Reptilian epiphyses. *Am. Jour. Anat.*, 7, 1908.
- NEIT:** Schädel d. *Dermochelys*. *Zool. Jahrb., Abt. Anat.*, 33, 1912.
- OGUSHI:** Skelett der japanischen *Trionyx*. *Morph. Jahrb.*, 43, 1911.
- PARKER:** Skull in the common snake. *Phil. Trans.*, 1878.
- PARKER:** Skull in the Lacertilia. *Phil. Trans.*, 1879.
- PARKER:** Skull in the crocodile. *Trans. Zool. Socy.*, 19.
- VERSLUYS:** Mittlere und äussere Ohrsphäre der Lacertilia. *Zool. Jahrb., Abth. Anat.* 12, 1898.
- VERSLUYS:** Columella auris bei Lacertilien. *Zool. Jahrb., Abth. Anat.*, 19, 1903.
- ZIMMERMANN:** Chondrocranium von *Anguis*. *Anat. Anz.*, 44, 1913.

Birds

- DU TOIT:** Synsacrum und Schwanz von *Gallus*. *Jena. Zeitsch.*, 49, 1913.
- GEGENBAUR:** Becken der Vögel. *Jena. Zeitsch.*, 6, 1871.

- LEBEDINSKY: Morphologie und Entwicklungsgeschichte des Vogelbeckens. Jena. Zeitsch., 50, 1913.
- LEIGHTON: Development of wing of Sterna. Tufts Coll. Studies, 1, 1894.
- LINDSAY: The avian sternum. Proc. Zool. Socy. London, 1885.
- MARSH: Odontornithes. U. S. Geol. Survey, 1880.
- MEHNERT: Entwicklung des Os pelvis der Vögel. Morph. Jahrb., 13, 1888.
- MORSE: Carpus and tarsus of birds. Ann. N. Y. Lyceum Nat. Hist., 10, 1872.
- OSBORN: Evidence for a dinosaur-avian stem in the Permian., Am. Nat., 34.
- PARKER: Skull of the common fowl. Phil. Trans., 1869.
- PARKER: Morphology of duck and auk tribes. Royal Irish Acad., Cunningham memoir, 6, 1890.
- PARKER: Structure and development of wing in common fowl. Phil. Trans., 179, 1888.
- PYCRAFT: Osteology of birds. Proc. Zool. Socy. London, 1898.
- SHUFELDT: Osteology of birds. Bulletin N. Y. State Museum, 130, 1909. (Gives full list of the author's numerous papers on avian anatomy.)
- SIEGELBAUER: Entwicklung der Vögelextremität. Zeit. wiss. Zool., 97, 1911.

Mammals

- ALLEN: Ethmoid bone in mammals. Bull. Mus. Comp. Zool., 10, 1883.
- BARDEEN: Development of human skeleton. Am. Jour. Anat., 4, 1905.
- BARDEEN: Development of thoracic vertebræ in man. Jour. Anat., 4, 1905.
- BAUR: Morphologie des Carpus der Säuger. Anat. Anz., 4, 1889.
- BRUSH: Cervical ribs. J. Hopkins Hosp. Bull., 12, 1901.
- BOAS: Metatarsus der Wiederkäuer. Morph. Jahrb., 16, 1890.
- COLLINGS: Skull of dog. London, 1896.
- DILG: Morphologie des Schädels bei Manatus. Morph. Jahrb., 39, 1909.
- EGGELING: Clavicula, Præclavicula, Halsrippen und Manubrium sterni. Anat. Anz., 29, 1906.
- FISCHER: Primordialcranium von Talpa. Anat. Hefte, 17, 1901.
- FLOWER: Osteology of the mammalia. London, 1885.
- FRTS: Entwicklung der Wirbelsäule von Echidna. Morph. Jahrb., 39, 1909.
- FROIÉP: Entwicklung der Wirbelsäule. Arch. Anat. und Phys., 1886.
- GAUPP: Neue Deutungen a. d. Gebiet der Lehre des Säugetierschädels. Anat. Anz., 27, 1905.
- GEGENBAUR: Episternal Skeletteile. Jena. Zeitsch., 1, 1864.
- HOLDER: Osteology of right whale. Bull. Am. Mus. Nat. Hist., 1, 1883.
- HOWES: Mammalian hyoid. Jour. Anat. and Phys., 30, 1897.
- KERNAN: Chondrocranium of a 20-mm. human embryo. Jour. Morph., 27, 1916.
- KÜKENTHAL: Hand der Cetaceen. Anat. Anz., 3, 1888; Morph. Jahrb., 19, 1892.
- MEAD: Chondrocranium of pig. Am. Jour. Anat., 9, 1909.
- OLMSTEAD: Primordialcranium eines Hundeembryo. Anat. Hefte, 43, 1911.
- PARKER: Skull of pig. Phil. Trans., 1874.
- PARKER: Structure and devel. skull in mammalia, Pt. 2, Insectivora. Pt. 3, Edentates. Phil. Trans., 1885.
- STROMER: Foramen entepicondyloideum und Trochanter tertius. Morph. Jahrb., 29, 1902.
- TERRY: Development of skull of cat. Jour. Morph., 29, 1917.
- VAN KAMPEN: Tympanalgegend des Säugetierschädels. Morph. Jahrb., 34, 1905.
- VOIT: Primordialcranium des Kaninchens. Anat. Hefte, 38, 1909.
- WEISS: Entwicklung der Wirbelsäule der weissen Ratte. Zeitsch. wiss. Zool., 69, 1901.
- WHITEHEAD and WADDELL: Development of human sternum. Am. Jour. Anat., 12, 1911.

MUSCULAR SYSTEM

- ALLIS: Cranial muscles of *Amia*. *Jour. Morph.*, 12, 1897.
- AYERS AND JACKSON: Myology of myxinoids. *Jour. Morph.*, 17, 1901.
- BLUM: Schwanzmuskulatur des Menschen. *Anat. Hefte*, 4, 1894.
- BRAUS: Entwicklung der Muskulatur und periph. Nervensystem der *Selachier*. *Morph. Jahrb.*, 26, 27, 1898-9.
- BRUNER: Smooth facial muscles of Amphibia. *Morph. Jahrb.*, 29, 1901.
- BYRNES: Develop. limb muscles in Amphibia. *Jour. Morph.*, 14, 1897.
- CHARNOCK: Muscles of mastication and movements of skull in *Lacertilia*. *Zool. Jahrb., Anat. Abth.*, 18, 1903.
- CORNING: Entwicklung Kopf- und Extremitäten-Muskulatur bei Reptilien. *Morph. Jahrb.*, 28, 1899.
- CORNING: *Vergl. Anat. der Augenmuskulatur*. *Morph. Jahrb.*, 29, 1900.
- DAVIDOFF: *Vergl. Anat. der hinteren Gliedmassen der Fische*. *Morph. Jahrb.*, 5-6, 1879-80.
- DRÜNER: Zungenbein-, Kiemenbogen- und Kehlkofmuskeln der Urodelen. *Zool. Jahrb. Abth. Anat.*, 15, 1901; 19, 1904.
- EDGEWORTH: Development of head muscles in *Gallus*. *Quar. Jour. Micr. Sci.*, 51, 1907.
- EDGEWORTH: Morphology of the cranial muscles of some vertebrates. *Quar. Jour. Micr. Sci.*, 56, 1911.
- EDGEWORTH: Development and morphology of mandibular and hyoid muscles of mammals. *Quar. Jour. Micr. Sci.*, 59, 1914.
- FEWKES: Myology of *Echidna*. *Bull. Essex Inst.*, 9, 1877.
- FÜRBRINGER: Muskeln der schlangenähnlichen Saurien. *Leipzig*, 1870.
- FÜRBRINGER: *Vergl. Anat. der Schultermuskeln*. *Urodeles, Jena. Zeitsch.*, 7, 1873; *Anura, l. c.*, 8, 1874; *Birds, l. c.*, 36, 1902; *Reptiles. Morph. Jahrb.*, 1, 1876.
- FÜRBRINGER: Muskulatur des Kopf der *Cyclostomen*. *Jena. Zeitsch.*, 9, 1875.
- FÜRBRINGER: Muskulatur des Vögelflügels. *Morph. Jahrb.*, 6, 1885.
- GADOW: Bauchmuskeln der Reptilien. *Morph. Jahrb.*, 7, 1881.
- GADOW: Myologie der Extremitäten der Reptilien. *Morph. Jahrb.*, 7, 1881.
- HUMPHREY: Several papers on muscles of sharks, dipnoi and urodeles. *Jour. Anat. and Phys.*, 1873.
- HUMPHREY: Muscles of *Lepidosiren* (Protopterus). *Jour. Anat. and Phys.*, 6, 1872. Muscles of *Ceratodus*, same vol.
- LAMB: Eye-muscles in *Acanthias*. *Am. Jour. Anat.*, 1, 1902.
- MACDOWELL: Myology of *Anthropithecus*. *Am. Jour. Anat.*, 10, 1910.
- MCMURRICH: Phylogeny of forearm flexors. *Am. Jour. Anat.*, 2, 1903; of palmar musculature, same vol.
- MALL: Development of human diaphragm. *Jour. Morph.*, 12, 1897. *Johns Hopkins Hosp. Bull.*, 12, 1901.
- MARION: Mandibular and branchial muscles of elasmobranchs. *Am. Nat.*, 39, 1905; *Tufts College Studies*, 2, 1905.
- MAURER: Ventral Rumpmuskulatur der Urodelen. *Morph. Jahrb.*, 17, 1892.
- MIVART: Myology of *Menopoma*, *Menobranchus*, *Chameleon*. *Proc. Zool. Socy. London*, 1869-70.
- NEAL: Development of hypoglossal musculature in *Petromyzon* and *Squalus*. *Anat. Anz.*, 13, 1897.
- RIBBING: Armmuskulatur der Amphibien, Reptilien und Säugetiere. *Zool. Jahrb., Abth. Anat.*, 11, 1907.
- RÜGE: Geschichtsmuskeln der Halbaffen. *Morph. Jahrb.*, 11, 1885.

- SCHUFELDT: Myology of the raven. London, 1890.
 SHUFELDT: Anatomy (mostly muscles) of *Geococcyx*. Proc. Zool. Socy. London, 1886.
 USKOW: Entwicklung des Zwergfells, u. s. w. Arch. mikr. Anat., 32, 1883.
 WILDER: Appendicular muscles of *Necturus*. Zool. Jahrb., Suppl. 15, 2 Bd., 1912.

ELECTRICAL ORGANS

- BALLOWITZ: Anatomie des Zittertaales. Arch. mikr. Anat., 50, 1897.
 BALLOWITZ: Elektrischen Organe von *Torpedo*. Arch. mikr. Anat., 42, 1893. (Large bibliography.)
 DAHLGREN and SILVESTER: Electric organ of *Astroscopus*. Anat. Anz., 29, 1906.
 EWART: Development of electric organ in skate. Phil. Trans., 179B, 1889.

NERVOUS SYSTEM

- BARKER: The nervous system and its constituent neurones. N. Y., 1899.
 EDINGER: Vorlesungen über den Bau der nervösen Centralorgane des Menschen und der Tiere. 7th edit., 2 vols., 1904-8.
 HERRICK: Introduction to Neurology. Philadelphia, 1915.
 JOHNSTON: Nervous system of vertebrates. Philadelphia, 1906.
 JOHNSTON: Morphology of vertebrate head from viewpoint of functional divisions of nervous system. Jour. Comp. Neurol., 15, 1905.
 JOHNSTON: Central nervous system of Vertebrates. Ergebnisse und Fortschritte der Zoologie, 2, 1910.
 RADL: Neue Lehre von zentralen Nervensystem. Leipzig, 1912.

BRAIN AND SPINAL CORD

General

- BARNES: Development of posterior fissure of spinal cord. Proc. Am. Acad. A. and Sci., 1883-4.
 DEJERINE: Anatomie des centres nerveux. Paris, 1895.
 GRÄPER: Rhombomeren und ihre Nervenbeziehungen. Arch. mikr. Anat., 83, 1913.
 HERRICK: Morphology of forebrain in amphibia and reptiles. Jour. Comp. Neurol., 20, 1910.
 HILL: Primary segments of vertebrate head. Zool. Jahrb., 13, 1899.
 HIS: Allgemeine Morphologie des Gehirn. Arch. Anat. und Phys., Abth. Anat., 1892.
 HOCHSTETTER: Entwicklung der Plexus chorioidei der Seitenkammern des Gehirns. Anat. Anz., 45, 1913.
 JOHNSTON: Morphology of forebrain vesicle in vertebrates. Jour. Comp. Neurol., 19, 1909.
 JOHNSTON: Morphology of vert. head from point of division of nervous system. Jour. Comp. Neurol., 15, 1905.
 JOHNSTON: Gehirn und Cranialnerven der Anamnier. Ergebnisse, 11, 1901.
 McCLURE: Segmentation of primitive brain. Jour. Morph., 4, 1890.
 NAKAGAWA: Origin of cerebral cortex and homology of optic lobe layers. Jour. Morph., 4, 1890.
 OSBORN: Origin of corpus callosum. Morph. Jahrb., 12, 1886.
 SMITH: Origin of corpus callosum. Trans. Linn. Socy., 7, 1897.
 STENDELL: Phylogenese der hypophysis. Anat. Anz., 45, 1914.
 TILNEY: Hypophysis cerebri. Memoirs Wistar Inst., 2, 1911.

WOERDEMANN: Vergleichende Ontogenie der Hypophysis. Arch. mikr. Anat., 86, 1914.

Cyclostomes and Fishes

- AYERS and WORTHINGTON: Finer anatomy of brain of Bdellostoma. Am. Jour. Anat., 8, 1908.
- BAUMGÄRTNER: Hypophysis of Squalus. Jour. Morph., 26, 1915.
- BING und BURCKHARDT: Zentralnervensystem von Ceratodus. Anat. Anz., 25, 1904.
- BURCKHARDT: Centralnervensystem von Protopterus. Berlin, 1892.
- CHANDLER: Lymphoid structure above myelencephalon of Lepidosteus. Univ. Calif. Pub. Zool., 9, 1911.
- COLE: Cranial nerves of Chimæra. Trans. Roy. Socy. Edinb., 38, 1896.
- DAMMERMAN: Der Saccus vasculosus der Fische ein Tieforgane. Zeit. wiss. Zool., 96, 1910.
- FRANZ: Das Mormyriden (brain). Zool. Jahrb., Abt. Anat., 32, 1911.
- FRANZ: Kleinhirn der Knochenfische. Zool. Jahrb., Abt. Anat., 32, 1911.
- GORONOWITSCH: Gehirn und Cranialnerven von Acipenser. Morph. Jahrb., 13, 1888.
- HALLER: Bau der Wirbeltiergehirns. I, Salmo und Scyllium. Morph. Jahrb., 26, 1898.
- HERRICK: Brains of some American fresh water fishes. Jour. Comp. Neurol., 1, 1891.
- HERRICK: Brain of certain ganoids. Jour. Comp. Neurol., 1, 1891.
- HERRICK and OBENCHAIN: Anatomy of cyclostome brain. Jour. Comp. Neurol., 23, 1913.
- JOHNSTON: Brain of Acipenser. Zool. Jahrb., 15, 1901.
- JOHNSTON: Brain of Petromyzon. Jour. Comp. Neurol., 12, 1902.
- JOHNSTON: Telencephalon of selachians. Jour. Comp. Neurol., 21, 1911.
- JOHNSTON: Olfactory lobes, forebrain and habenular tracts of Acipenser. Zool. Bull., 1, 1898.
- JOHNSTON: Telencephalon of ganoids and teleosts. Jour. Comp. Neurol., 21, 1911.
- KAPPERS: Teleost and selachian brain. Jour. Comp. Neurol., 16, 1906.
- KINGSBURY: Oblongata in fishes. Jour. Comp. Neurol., 7, 1897.
- LOCY: Contribution to structure and development of vertebrate head. Jour. Morph., 11, 1895.
- MAYER: Gehirn der Knochenfische. Arch. Anat. und Phys., 1882.
- MAYSER: Gehirn der Knochenfische (Cyprinoids). Zeit. wiss. Zool., 36, 1881.
- NEAL: Segmentation of nervous system in Acanthias. Bull. Mus. Comp. Zool., 31, 1898.
- NICHOLLS: Reissner's fibre. Anat. Anz., 40, 1912.
- NICHOLS: Reissner's fibre and sub-commissural organ. Quar. Jour. micr. Sci., 58, 1912.
- NICHOLS: Experiments on Reissner's fibre. Jour. Comp. Neurol., 27, 1917.
- SARGENT: Reissner's fibre. Bull. Mus. Comp. Zool., 45, 1904.
- SARGENT: Torus longitudinalis of teleost brain. Mark Anniv. Vol., 1904.
- STERZI: Il sistema nervoso centrale dei vertebrati. Padova, 1907. (Only first vol. cyclostomes and selachians, published).
- TRETIKOFF: Zentral Sinnesorgane bei Petromyzon. Arch. mik. Anat., 83, 1913.
- WALDSCHMIDT: Centralnervensystem und Geruchsorgane von Polypterus. Anat. Anz., 2, 1887.
- WORTHINGTON: Brain and cranial nerves of Bdellostoma. Quar. Jour. Micr. Sci., 49, 1905.

Amphibia

- BINDEWALD: Vorderhirn von Amblystoma. Arch. mikr. Anat., 84, 1914.
- BURCKHARDT: Hirn und Geruchsorgan von Triton und Ichthyophis. Zeitsch. wiss. Zool., 52, 1891.

- FISH: Central nervous system of *Desmognathus*. *Jour. Morph.*, 5, 1895.
 FISCHER: Amphibiorum nudorum neurologiæ specimen primus. Berlin, 1843.
 GAGE: Brain of *Diemyctylus* compared with *Amia* and *Petromyzon*. Wilder quarter-century book, 1893.
 GRIGGS: Early development of central nervous system in *Amblystoma*. *Jour. Morph.*, 21, 1910.
 HERRICK: Cerebellum of *Necturus*. *Jour. Comp. Neurol.*, 24, 1914.
 HERRICK: Medulla of *Amblystoma*. *Jour. Comp. Neurol.*, 25, 1915.
 KINGSBURY: Brain of *Necturus*. *Jour. Comp. Neurol.*, 5, 1895.
 KINGSLEY and THYNG: Hypophysis in *Amblystoma*. *Tufts Coll. Studies*, 1, 1904.
 OSBORN: Brain of *Amphiuma*. *Proc. Acad. Nat. Sci., Philadelphia*, 1883.
 OSBORN: Internal structure of amphibian brain. *Jour. Morph.*, 2, 1888.
 WALDSCHMIDT: Nervensystem der Gymnophionen. *Jena. Zeitsch.*, 20, 1886.

Reptilia

- BAUMGARTNER: Hypophysis in reptiles. *Jour. Morphol.*, 28, 1916.
 GISI: Gehirn von *Hatteria* [*Sphenodon*]. *Zool. Jahrb., Abth. Anat.*, 25, 1907.
 HALLER: Bau des Wirbeltiergehirns. II, *Emys*. *Morph. Jahrb.*, 28, 1900.
 HERRICK: Brain of certain reptiles. *Jour. Comp. Neurol.*, 1, 1891; see also vol. 3.
 HERRICK: Brain of alligator. *Jour. Cincinnati Socy. Nat. Hist.*, 12, 1890.
 HUMPHREY: Brain of *Chelydra*. *Jour. Comp. Neurol.*, 4, 1894.
 KÖPPEN: Anatomie des Eidechsengehirn. *Morph. Arbeiten*, 1, 1891.
 RABL-RÜCKHARD: Centralnervensystem des Alligator. *Zeitsch. wiss. Zool.*, 30, 1878.
 RABL-RÜCKHARD: Gehirn des Riesenschlange. *Zeitsch. wiss. Zool.*, 58, 1894.

Birds

- BUMM: Grosshirn der Vögel. *Zeitsch. wiss. Zool.*, 38, 1893.
 KAMON: Entwicklung des Gehirns des Hühnchens. *Anat. Hefte*, 30, 1906.
 SCHIMAZONO: Kleinhirn der Vögel. *Arch. mikr. Anat.*, 80, 1912.
 STREETER: Spinal cord of ostrich. *Am. Jour. Anat.*, 3, 1903.
 TURNER: Avian brain. *Jour. Comp. Neurol.*, 1, 1891.

Mammals

- BECHTEREW: Leitungsbahnen im Gehirn und Rückenmark. Leipzig, 1898.
 GRÖNBERG: Untersuchungen an Gehirn von *Erinaceus*. *Zool. Jahrb.*, 15, 1891.
 HALLER: Bau des Gehirn von *Mus* und *Echidna*. *Morph. Jahrb.*, 28, 1900.
 HERRICK: Brain of rodents. *Bull. Denison Univ.*, 6, 1891.
 LANDAU: Das Katzenhirn. *Morph. Jahrb.*, 38, 1908.
 SABIN: Atlas of medulla and mid-brain. Baltimore, 1910.
 SMITH: Brain of foetal *Ornithorhynchus*. *Quar. Jour. Micr. Sci.*, 39, 1896.
 SMITH: Morphology of brain in mammals. *Trans. Linn. Socy. London, Zool.*, 8, 1903.
 SYMINGTON: Commissures in marsupialia and monotremes. *Jour. Anat. and Phys.*, 27, 1892.

EPIPHYSIAL STRUCTURES

- BEARD: Parietal eye of cyclostomes. *Quar. Jour. Micr. Sci.*, 29, 1888.
 DENDY: Devel. parietal eye, etc., in *Sphenodon*. *Quar. Jour. Micr. Sci.*, 42, 1899.
 DEXTER: Development of paraphysis in fowl. *Am. Jour. Anat.*, 2, 1902.
 EYELESHYMER: Paraphysis and epiphysis in *Amblystoma*. *Anat. Anz.*, 7, 1892.

- GAUPP: Zirbel, Parietalorgan und Paraphysis. *Ergebnisse*, 7, 1897.
 HILL: Develop. of epiphysis in *Coregonus*. *Jour. Morph.*, 5, 1891; of teleosts and *Amia*, idem, 9, 1894.
 KINGSBURY: Encephalic evaginations in ganoids. *Jour. Comp. Neurol.*, 7, 1897.
 MINOT: Morphology of pineal region based on *Acanthias*. *Am. Jour. Anat.*, 1, 1901.
 NOWIKOFF: Parietalaue von Saurien. *Zeit. wiss. Zool.*, 96, 1910.
 REESE: Develop. of paraphysis and epiphysis in alligator. *Smithson. Misc. Coll.* 54, 1910.
 RITTER: Parietal eye in some lizards. *Bull. Mus. Comp. Zool.*, 20, 1891.
 SPENCER: Pineal eye in *Lacertilia*. *Quar. Micr. Sci.*, 27, 1886.
 WARREN: Pineal region in *Necturus*. *Am. Jour. Anat.*, 5, 1905.
 WARREN: Pineal region in reptiles. *Am. Jour. Anat.*, 11, 1911.

PERIPHERAL NERVES

- ALLIS: Cranial muscles and nerves of *Amia*. *Jour. Morph.*, 12, 1897.
 ALLIS: Cranial nerves in *Scomber*. *Jour. Morph.*, 18, 1903.
 BEARD: Branchial sense organs and associated ganglia in *Ichthyopsida*. *Quar. Jour. Micr. Sci.*, 25, 1885.
 BOWERS: Cranial nerves of *Spelerpes*. *Proc. Amer. Acad.*, 36, 1901.
 BRAUS: Innervation der paarigen Extremitäten bei *Selachiern* und *Dipnoer*. *Jena. Zeitsch.*, 31, 1898.
 BROEK: Bau des sympathet. Nervensystems der Säugetiere. *Morph. Jahrb.*, 37, 1907; 38, 1908.
 BROOKOVER: Olfactory nerve, terminalis nerve and preoptic sympathetic in *Amia*. *Jour. Comp. Neurol.*, 20, 1910; olfact. and terminalis in *Amiurus*. Idem, 21, 1911.
 CARPENTER: Develop. oculomotor and abducens nerves and ciliary ganglion in chick. *Bull. Mus. Comp. Zool.*, 48, 1906.
 CAMUS: Entwicklung des sympathischen Nervensystem beim Frosch. *Arch. mikr. Anat.*, 82, 1912.
 CHASE and RANSON: Vagus of dog. *Jour. Comp. Neurol.*, 24, 1914.
 COGHILL: Cranial nerves of *Amblystoma*. *Jour. Comp. Neurol.*, 12, 1902.
 COLE: Cranial nerves of *Chimæra*. *Trans. Roy. Socy.*, Edinburg, 38, 1896.
 COLE: Cranial nerves of *Gadus*. *Trans. Linn. Socy. London, Zool.*, 7, 1898.
 FISCHER: *Anat. Abhandl. über Perrenibranchiaten und Derotremen*. Hamburg, 1854.
 See also *Amphib. Nudorum*, etc., under Brain.
 GEGENBAUR: Kopfnerven von *Hexanchus*. *Jena. Zeitsch.*, 6, 1871.
 GOETTE: Entwicklung der Kopfnerven bei Fischen und Amphibien. *Arch. mikr. Anat.*, 85, 1914.
 HAMMERSTEN: Innervation der Bauchflossen bei *Teleostiern*. *Morph. Jahrb.*, 42, 1911.
 HERRICK: Cranial nerves of *Menidia*. *Jour. Comp. Neurol.*, 9, 1899.
 HERRICK: Cranial nerves of siluroids. *Jour. Comp. Neurol.*, 11, 1901.
 HERRICK: Criteria of homology in peripheral nervous system. *Jour. Comp. Neurol.*, 19, 1909.
 HERRICK: Peripheral nervous system of bony fishes. *Bull. U. S. Fish Commiss. for* 1898.
 HERRICK: *Nervus terminalis* in frog. *Jour. Comp. Neurol.*, 19, 1909.
 HUBER: Sympathetic nervous system. *Jour. Comp. Neurol.*, 7, 1897.
 HUBER: Minute anat. of sympathetic ganglia. *Jour. Morph.*, 16, 1899.
 JOHNSTON: Cranial nerves of *Petromyzonts*. *Jour. Comp. Neurol.*, 18, 1908.
 JOHNSTON: Cranial nerve components of *Petromyzon*. *Morph. Jahrb.*, 34, 1905.
 KUNZ: Development of sympathetic in turtles. *Am. Jour. Anat.*, 11, 1911; mammals

- and birds, *Jour. Comp. Neurol.*, 20, 1910; of amphibia, idem, 21, 1911; Evolution symp. syst. in vertebrates, idem, 21, 1911.
- KUPFFER: Entwicklungsgeschichte des Kopfes. *Ergebnisse*, 1895.
- KUPFFER: Development of cranial nerves. *Jour. Comp. Neurol.*, 1, 1891.
- LANDACRE: Cranial ganglia in *Amiurus*. *Jour. Comp. Neurol.*, 20, 1910.
- LANDACRE: Epibranchial placodes of *Lepidosteus* and their relation to the cerebral ganglia. *Jour. Comp. Neurol.*, 22, 1912.
- LANDACRE: Cerebral ganglia and early nerves of *Acanthias*. *Jour. Comp. Neurology*, 27, 1916.
- LENHOSSEK: Ciliarganglion der Reptilien. *Arch. mikr. Anat.*, 80, 1912.
- LOCY: New cranial nerve in selachians. *Mark Anniv. Vol.*, 1903. See also *Anat. Anz.*, 26, 1905.
- LUBOSCH: Nervus accessorius Willisii. *Arch. mikr. Anat.*, 54, 1899.
- MAYHOFF: 'Monomorphe' Chiasma opticum der Pleuronectiden. *Zool. Anz.*, 39, 1912.
- MCKIBBEN: Nervus terminalis in Amphibia. *Jour. Comp. Neurol.*, 21, 1911.
- MCKIBBEN: Eye-muscle nerves of *Necturus*. *Jour. Comp. Neurol.*, 23, 1913.
- MÜLLER: Anatomie und Entwicklung des peripherischen Nervensystem bei den Selachiern. *Arch. mikr. Anat.* 81, 1913.
- NEAL: Morphology of eye-muscle nerves. *Jour. Morph.*, 25, 1914.
- NEAL: Development of ventral nerves in selachii. *Mark Anniv. Vol.*, 1903.
- NORRIS: Cranial nerves of *Amphiuma*. *Jour. Comp. Neurol.*, 18, 1908.
- OGUSHI: Hirnnerven und Kopfsympathicus von *Trionyx*. *Morph. Jahrb.*, 45, 1913.
- PARKER: Optic chiasma in teleosts. *Bull. Mus. Comp. Zool.*, 40, 1903.
- PINKUS: Hirnnerven des Protopterus. *Morph. Arbeiten*, 4, 1894.
- PRENTISS: Development of hypoglossal ganglion in pig. *Jour. Comp. Neurol.*, 20, 1910.
- PUNNETT: Pelvic plexus and nervus collector in *Mustelus*. *Phil. Trans.* 192 B, 1900.
- SHELDON: Nervus terminalis in carp. *Jour. Comp. Neurol.*, 19, 1909.
- STANNIUS: Peripherische Nervensystem der Fische. *Rostock*, 1849.
- STREETER: Development of cranial and spinal nerves in occipital region of man. *Am. Jour. Anat.*, 4, 1904.
- STRONG: Cranial nerves of amphibia. *Jour. Morph.*, 10, 1895.
- WILKINSON: Cranial nerves of *Varanus*. *Morph. Jahrb.*, 35, 1901.

SENSE ORGANS

- OKAJIMA: Sinnesorgane von *Onychodactylus*. *Zeit. wiss. Zool.*, 94, 1909.
- OSAWA: Sinnesorgane der Hatteria [*Sphenodon*]. *Arch. mikr. Anat.*, 52, 1898.
- SCHWALBE: Lehrbuch der Anatomie der Sinnesorgane. *Erlangen*, 1883.

Dermal and Lateral Line Organs

- ALLIS: Lateral line system in *Amia*. *Jour. Morph.*, 2, 1889.
- ALLIS: Lateral sensory canals of *Mustelus*. *Quar. Jour. Micr. Sci.*, 45, 1902.
- ALLIS: Lateral canals of *Polyodon*. *Zool. Jahrb., Abth. Anat.*, 17, 1903.
- AYERS and WORTHINGTON: Skin end organs of trigeminal and lateralis nerves of *Bdellostoma*. *Am. Jour. Anat.*, 7, 1907.
- BEARD: Segmental sense organs and associated ganglia in ichthyopsida. *Quar. Jour. Micr. Sci.*, 25, 1885.
- BOLL: Savi'schen Bläschen von *Torpedo*. *Arch. Anat. und Phys.*, 1875.
- CLAPP: Lateral line system of *Batrachus*. *Jour. Morph.*, 15, 1899.
- COLLINGS: Sensory canal system of ganoids. *Quar. Jour. Micr. Sci.*, 36, 1894.

- EWART and MITCHELL: Lateral sense organs of Elasmobranchs. *Trans. Roy. Soc. Edinburg*, 38, 1892. (See Garman, *Bull. Mus. Comp. Zool.*, 17, 1888.)
- EWART: Sensory canal of Læmargus. *Trans. R. Socy., Edinb.*, 37, 1893.
- HARRISON: Entwicklung der Sinnesorgane der Seitenlinie der Amphibien. *Arch. mikr. Anat.*, 63, 1903.
- KINGSBURY: Lateral line system of American amphibia and comparisons with dipnoi. *Proc. Amer. Micros. Socy.*, 17, 1895.
- LANDACRE and CONGER: Origin of lateral line primordia in *Lepidosteus*. *Jour. Comp. Neurol.*, 23, 1913.
- MAURER: Die Epidermis und ihre Abkömmlinge. Leipzig, 1895.
- METCALF: Ampullæ of Lorenzini. *Trans. Am. Micr. Socy.*, 1915.
- MOODIE: Lateral line system in extinct amphibia. *Jour. Morph.*, 19, 1908.
- MORRILL: Pectoral appendages of *Prionotus*. *Jour. Morph.*, 11, 1895.
- MUNKERT: Lorenzini'schen Ampullen. *Anat. Anz.*, 19, 1901.
- PARKER: Function of lateral line system in fishes. *Bull. Bureau of Fisheries*, 24, 1905.
- PFÜLLER: Seitensinnesorgane der Macruriden, *Jena. Zeitsch.*, 52, 1914.
- POLLARD: Lateral line system in siluroids. *Zool. Jahrb.*, 5, 1893.
- RITTER: Eyes, integumental sense papillæ and skin of *Typhlogobius*. *Bull. Mus. Comp. Zool.*, 24, 1893.

Taste

- HERRICK: Phylogeny and morphol. position of terminal buds of fishes. *Jour. Comp. Neurol.*, 13, 1903.
- HERRICK: Organs and sense of taste in fishes. *Bull. U. S. Fish Comm.*, 22, 1903.
- HERRICK: Terminal buds of fishes. *Jour. Comp. Neurol.*, 13, 1903.
- SCHWALBE: Geschmacksorgane der Säugetiere. *Arch. mikr. Anat.*, 4, 1868.
- TUCKERMAN: Gustatory organs of mammals. *Jour. Morph.*, 2, 1888; 4, 1890; 7, 1892.

Smell

- ANTON: Jacobson'schen Organ und Nasenhöhle der Cryptobranchiaten. *Morph. Jahrb.*, 38, 1908.
- BAWDEN: Nose and Jacobson's organ with reference to amphibia. *Jour. Comp. Neurol.*, 4, 1894.
- BERLINER: Entwicklung des Geruchsorgane der Selachier. *Arch. mikr. Anat.*, 60, 1902.
- BLAUE: Nasenschleimhaut bei Fischen und Amphibien. *Arch. Anat. und Phys., Anat. Abth.*, 1884.
- BORN: Nasenhöhle und Thränennasengang der Amphibien. *Morph. Jahrb.*, 2, 1876; der Amnioten, *ibid.*, 5, 1879; 7, 1882.
- BRUNER: Jacobson's organ and respiratory mechanism in Amphibians. *Morph. Jahrb.*, 48, 1914.
- DISSE: Rienschleimhaut und Riechnerv bei Wirbeltiere. *Ergebnisse*, 11, 1901.
- DOGIEL: Geruchsorgane bei Ganoiden, Knochenfische, und Amphibien. *Arch. mikr. Anat.*, 29, 1887.
- FISCHER: Nasenhöhle und Tränenwege der Amphibien. *Arch. mikr. Anat.*, 55, 1900.
- FRETS: Entwicklung der Nase bei Affen, Säugern und Menschen. *Morph. Jahrb.*, 44, 1912.
- GAUPP: Nervenversorgen der Mund- und Nasenhöhlendrüsen der Wirbeltiere. *Morph. Jahrb.*, 14, 1888.
- GEGENBAUR: Nasenmuscheln der Vögel. *Jena. Zeitsch.*, 7, 1873.
- HOLM: Develop. Olfactory organ in Teleosts. *Morph. Jahrb.*, 21, 1894.

- MCCALLUM: Nasal region in Eutænia. *Proc. Canadian Inst.*, 1, 1883.
 PETER: Entwicklung der Nasenmuskeln bei Menschen und Säugetiere. *Arch. mikr. Anat.* 80, 1912.
 READ: Olfactory apparatus in dog, cat and man. *Am. Jour. Anat.*, 8, 1908.
 SCHAEFFER: Lateral wall of cavum nasi in man. *Jour. Morph.*, 21, 1910.
 SEYDEL: Nasenhöhle und Jacobson'sche Organ der Amphibien. *Morph. Jahrb.*, 23, 1895.
 STRONG: Olfactory organ and smell in birds. *Jour. Morph.*, 22, 1911.
 WILDER: Nasengegend von Menopoma [Cryptobranchus] und Amphiuma. *Zool. Jahrb., Abth. Anat.*, 5, 1892.
 WILDER: Lateral nasal glands of Amphiuma. *Jour. Morph.*, 20, 1909.
 ZUKERKANDL: Jacobson'sche Organs. *Ergebnisse*, 18, 1910.
 ZUKERKANDL: Jacobsonsorgane und Riechlappen der Amphibien. *Anat. Hefte*, 41, 1910.

Eyes

- BAGE: Retina of lateral eyes of Sphenodon. *Quar. Jour. Mic. Sci.*, 57, 1912.
 BERGER: Sehorgane der Fische. *Morph. Jahrb.*, 8, 1882.
 BERNARD: Rods and cones in frog. *Quar. Jour. Micr. Sci.*, 44, 1901.
 BRAUER: Augen der Tiefseefische. *Verhandl. deutsch. zool. Gesellsch.*, 1902.
 CARRIERE: Sehorgane der Thiere. München, 1885.
 CORNING: Anatomie der Augenskulatur. *Morph. Jahrb.*, 29, 1900.
 EGGELING: Augenlider der Säugetiere. *Jena. Zeitsch.*, 39, 1904.
 EIGENMANN: Eyes of blind vertebrates. *Biol. Bull.*, 2, 1900; 5, 1903.
 EIGENMANN: Eyes of Amblyopsidæ. *Arch. Entw. Mechan.*, 7, 1899.
 EYCLESHYMER: Development of optic vesicles in amphibia. *Jour. Morph.*, 8, 1893.
 JELGERSMA: Ursprung des Wirbeltierauges. *Morph. Jahrb.*, 35, 1906.
 LAMB: Development of eye muscles of Acanthias. *Am. Jour. Anat.*, 1, 1910.
 LOCY: Optic vesicles of elasmobranchs and their relations to other structures. *Jour. Morph.*, 9, 1894.
 MALL: Histogenesis of retina. *Jour. Morph.*, 8, 1893.
 PETERS: Harder'schen Drüse. *Arch. mikr. Anat.*, 36, 1890.
 RABL: Bau und Entwicklung der Linse. *Zeitsch. wiss. Zool.*, 63, 1898; 65, 1898; 67, 1899.
 ROBINSON: Formation and structure of optic nerve and its relation to optic stalk. *Jour. Anat. and Phys.*, 30, 1896.
 SCHAEFFER: Develop. nasolacrimal passages in man. *Am. Jour. Anat.*, 13, 1912.
 STUDNICKA: Sehnerven der Wirbeltiere. *Jena. Zeitsch.*, 31, 1897.
 SUNDWALL: The lacrimal gland. *Am. Jour. Anat.*, 20, 1916.
 WEYSSE: Histogenesis of retina. *Am. Nat.*, 40, 1906.
 WILLIAMS: Migration of eye in Pseudopleuronectes. *Bull. Mus. Comp. Zool.*, 40, 1902.

Ears

- AYERS: Vertebrate cephalogenesis (large bibliography). *Jour. Morph.*, 6, 1892.
 AYERS: Relations of hair cells of ear. *Jour. Morph.*, 8, 1893.
 BRIDGE and HADDON: Air bladder and Weberian ossicles of siluroids. *Phil. Trans.*, 184, 1893.
 DRÜNER: Anatomie und Entwicklung des Mittelohres beim Menschen und Maus. *Anat. Anl.*, 24, 1904.
 GAUFF: Schalleitenden Apparat bei Wirbeltiere. *Ergebnisse*, 8, 1898.
 GARDESTY: Probable action of tectorial membrane. *Am. Jour. Anat.*, 18, 1915.

- KINGSBURY:** *Columella auris* and *nervus facialis*. *Jour. Comp. Neurol.*, 13, 1903.
KINGSLEY: *Ossicula auditus*. *Tufts College Studies*, 1, 1900.
MALL: Development *Eustachian tube*, middle ear, etc., of chick. *Studies Biol. Lab. Johns Hopkins*, 4, 1887.
NORRIS: Development of auditory vesicle in *Amblystoma*. *Jour. Morph.*, 7, 1892.
OKAJIMA: Entwicklung d. Gehörorganes von *Hydnobius*. *Anat. Hefte*, 45, 1911.
PARKER: Hearing and allied sense in fishes. *Bull. U. S. Fish. Comm.* for 1902, 1903.
 See also *Am. Nat.*, 37, 1903.
STREETER: Development of labyrinth and acoustic and facial nerves in human embryo. *Am. Jour. Anat.*, 6, 1907.
VERSLUYS: Mittlere und äussere Ohrsphäre der *Lacertilier*. *Zool. Jahrb., Abth. Anat.*, 12, 1898.
WILLY: Development of ear and accessory organs in frog. *Quar. Jour. Micros. Sci.*, 30, 1890.

ALIMENTARY CANAL

Teeth

- ADDISON and APPLETON:** Incisor teeth of rat. *Jour. Morph.*, 26, 1915.
BEARD: Teeth of marsipobranchs. *Zool. Jahrb.*, 3, 1889.
BURCKHARDT: Gebiss der Sauropsiden. *Morph. Arbeiten*, 5, 1895.
COPE: Tritubercular molar in human dentition. *Jour. Morph.*, 2, 1888.
HARRISON: Development and succession of teeth in *Hatteria* [*Sphenodon*]. *Quart. Jour. Micr. Sci.*, 44, 1901.
HERTWIG: Zahnsystem der Amphibien und seine Bedeutung für den Genese des Skelettes der Mundhöhle. *Arch. mikr. Anat.*, 9, 1874.
KÜENTHAL: Ursprung und Entwicklung der Säugethierzähne. *Jena. Zeitsch.*, 26, 1892.
KÜENTHAL: Entwicklung des Gebiss des Dugong. *Anat. Anz.*, 45, 1914.
LAASER: Entw. der Zahnleiste der Selachier. *Anat. Anz.*, 17, 1900.
LECHE: Entwicklung des Zahnsystem der Säuger. *Morph. Jahrb.*, 19, 1892.
MARTIN: Tooth development in *Dasypus*. *Jour. Morph.*, 27, 1916.
OPPEL: Verdauungsapparat. *Ergebnisse*, 13, 1903: 14, 1904: 16, 1906.
OSBORN: Evolution of mammalian molars to and from tritubercular type. *Am. Nat.*, 22, 1888.
OSBORN: Succession of teeth in mammals. *Am. Nat.*, 27, 1893.
OSBORN: Trituberculy. *Am. Nat.*, 31, 1897.
POULTON: Teeth and horny plates of *Ornithorhynchus*. *Quar. Jour. Micr. Sci.*, 29, 1888.
RÖSE: Entwicklung der Zähne des Menschen. *Arch. mikr. Anat.*, 38, 1891.
RÖSE: Zahnleiste und Eischwiele der Sauropsiden. *Anat. Anz.*, 7, 1892.
RÖSE: Phylogense des Säugertiergebisses. *Biol. Centralblatt.*, 12, 1892.
RYDER: Mechanical genesis of tooth forms. *Proc. Acad. Nat. Sci., Philadelphia*, 1878.
TOMES: Manual of Dental Anatomy. Philadelphia, 1898.
DE TERRA: Vergl. Anatomie menschlichen Gebisses und der Zähne der Vertebraten. Jena, 1911.
WARREN: Teeth of *Petromyzon* and *Myxine*. *Quar. Jour. Micr. Sci.*, 45, 1902.
WILSON: Tooth development of *Ornithorhynchus*. *Quar. Jour. Micr., Sci.* 51, 1907

Mouth and Tongue

- FLINT:** Submaxillary gland. *Am. Jour. Anat.*, 2, 1903.
GEGENBAUR: Unterzunge der Säugethiere. *Morph. Jahrb.*, 9, 1884

- GEGENBAUR: Phylogese der Zunge. Morph. Jahrb., 11, 1886; 21, 1894.
 GEGENBAUR: Gaumenfalten des Menschen. Morph. Jahrb., 4, 1878.
 HAMMAR: Entwicklung der Zunge und Speicheldrüsen. Anat. Anz., 19, 1901.
 HEIDRICH: Mund und Schlundkopfhöhle der Vögel und ihre Drüsen. Morph. Jahrb., 37, 1907.
 KALLIUS: Entwicklung der Zunge. Anat. Hefte, 16, 1901; 28, 1905; 41, 1910.
 MAURER: Blutgefäße im Epithel. Morph. Jahrb., 25, 1887.
 OEDER: Munddrüsen und Zahnleiste der Anuren. Jena. Zeitsch., 41, 1906.
 PAWLOWSKY: Giftdrüsen einiger Scorpæniden. Zool. Jahrb., Abt. Anat., 31, 1911.
 POULTON: Tongue of Perameles. Quar. Jour. Micr. Sci., 23, 1883.
 REICHEL: Mundhöhlndrüsen der Wirbeltiere. Morph. Jahrb., 7, 1882.
 STEINHARD: Placoidschuppen in Mund- und Rachenhöhle der Plagiostomen. Arch. f. Naturgeschichte, 69 (1), 1903.
 WIEDERSHEIM: Kopfdrüsen der Amphibien. Zeit. wiss. Zool., 28, 1877.

Thyreoid and Thymus Glands, Etc.

- BADERTSCHER: Development of thymus in pig. Am. Jour. Anat., 17, 1915.
 CAMP: Development of the suprapericardial body in Squalus. Jour. Morphol., 28, 1907.
 ERDHEIM: Kiemenderivate bei Ratte, Kaninchen und Igel. Anat. Anz., 29, 1906.
 FERGUSON: Thyreoid in Elasmobranchs. Am. Jour. Anat., 11, 1911.
 GREIL: Kiemendarmderivate von Ceratodus. Anat. Anz. Ergänz. Hefte, 29, 1906.
 GREIL: Anlage der Lungen und ultimobranchial Körper. Anat. Hefte 29, 1905.
 GUDERNATSCH: Thyreoid of Teleosts. Jour. Morph., 21, 1911.
 HAMMAR: Elasmobranch Thymus. Zool. Jahrb., Abt. Anat., 32, 1911.
 HELGESSON: Embryologie der Vogelthymus. Zool. Anz., 43, 1913.
 JOHNSTONE: Thymus in marsupials. Jour. Linn. Socy., London, Zool., 26, 1898.
 KASTSCHENKO: Schicksal d. embryon. Schlundspalten bei Säugetieren. Arch. mikr. Anat., 30, 1887.
 KINGSBURY: Amphibian tonsils. Anat. Anz., 42, 1912.
 KINGSBURY: Ultimobranchial body of man. Am. Jour. Anat., 14, 1913.
 KINGSBURY: Pharyngeal derivatives of man. Anat. Anz., 47, 1915.
 MARCUS: Schlundspaltgebiet der Gymnophionen. Arch. mikr. Anat., 71, 1908.
 MAURER: Schilddrüse, Thymus und Kiemenreste der Amphibien. Morph. Jahrb., 13, 1887.
 MAURER: Schlundspalten-Derivate. Verhandl. Anat. Gesellsch., 13, 1899.
 See large article in Semon's Forschungsreise, 3, 1897-1901.
 NORRIS: Ventraler Kiemenreste and Corpus propericardiale of the frog. Anat. Anz., 21, 1902.
 PLATT: Development of thyroid and suprapericardial bodies in Necturus. Anat. Anz., 11, 1896.
 RABL: Anlage der ultimobranchialen Körper bei Vögel. Arch. mikr. Anat., 70, 1907.
 SCHAFFER: Schilddrüse von Myxine. Anat. Anz., 28, 1906.
 SUDERLUND und BACHMAN: Studien über Thymusinvolution. Arch. mikr. Anat., 73, 1909.
 STOCKARD: Development of thyreoid in Bdellostoma. Anat. Anz., 29, 1906.
 ZUCKERKANDL: Entwicklung der Schilddrüse und Thymus bei der Ratte. Anat. Hefte, 21, 1903.

Digestive Tract

- BAUMGARTNER: Development of liver and pancreas
 19, 1916.

of Amblystoma
Arch. Anat.

- BOAS:** Magen der Cameliden. *Morph. Jahrb.*, 16, 1890.
- BRACHET:** Développement de la foie et du pancréas de l'Ammocœtes. *Anat. Anz.*, 13, 1897.
- BENSLEY:** Pancreas of guinea pig. *Am. Jour. Anat.*, 12, 1911.
- BRAUN:** Pancreas bei Alytes. *Morph. Jahrb.*, 36, 1906.
- CLAYPOLE:** Enteron of lamprey. *Proc. Am. Micros. Socy.*, 1894.
- CHORONSHITZKY:** Entstehung der Milz, Leber, Gallenblase, Bauchspeicheldrüse und Pfortadersystem bei verschiedenen Wirbeltiere. *Anat. Hefte*, 13, 1900.
- EGGELING:** Dünndarmrelief und Ernährung bei Knochenfischen. *Jena. Zeitsch.*, 43, 1907.
- GÖPPERT:** Entwicklung des Pancreas bei Knochenfischen. *Morph. Jahrb.*, 20, 1893.
- GADOW:** Verdauungssystems der Vögel. *Jena. Zeitsch.*, 13, 1879.
- HELBLING:** Darm einiger Selachier. *Anat. Anz.*, 22, 1903.
- HELLY:** Pancreasentwicklung der Säugetiere. *Arch. mikr. Anat.*, 67, 1901.
- HOSKINS:** Development of the digitiform gland in *Squalus*. *Jour. Morphol.*, 28, 1917.
- HOWES:** Intestinal canal of Ichthyopsida. *Jour. Linn. Socy. London, Zool.*, 23, 1890.
- JACOBSHAGEN:** Darmsystem der Fische und Dipnoer. *Jena Zeitsch.*, 49, 1913.
- JOHNSTON:** Limit between ectoderm and entoderm in mouth of amphibia. *Am. Jour. Anat.*, 10, 1910.
- JUNGCLAUS:** Magen der Cetaceen. *Jena. Zeitsch.*, 32, 1898.
- KERR:** Development of alimentary tract in Lepidosiren. *Quar. Jour. Micr. Sci.*, 54, 1910.
- KILLIAN:** Bursa und Tonsilla pharyngea. *Morph. Jahrb.*, 14, 1888.
- KINGSBURY:** Enteron of *Necturus*. *Proc. Am. Micros.*, 1894.
- LEWIS and THYNG:** Intestinal diverticula in embryos of pig, rabbit and man. *Am. Jour. Anat.*, 7, 1908.
- MAYER:** Entwicklung des Pancreas bei Selachier. *Anat. Hefte*, 8, 1897.
- MAYER:** Spiraldarm der Selachier. *Neap. Mittheil.*, 12, 1897.
- OPPEL:** Verdauungsapparat. *Ergebnisse*, 7, 1897.
- OSAWA:** Eingeweiden der Hatteria [*Sphenodon*]. *Arch. mikr. Anat.*, 49, 1897.
- PARKER:** Spiral valve in *Raia*. *Trans. Zool. Socy. London*, 11, 1880.
- PIPER:** Entwicklung von Magen, Duodenum, Schwimmblase, Leber, Pancreas und Milz bei *Amia*. *Arch. Anat. und Physiol.*, 1902.
- POHLMAN:** Development of cloaca in human embryos. *Am. Jour. Anat.*, 12, 1911.
- REX:** Morphologie der Säugerleber. *Morph. Jahrb.*, 14, 1888.
- RÜCKERT:** Entwicklung des Spiraldarmes bei Selachiern. *Arch. f. Entwickl. mechan.* 4, 1896.
- SCAMMON:** Development of liver of Elasmobranchs. *Am. Jour. Anat.*, 14, 1913.
- SCAMMON:** Histogenesis of selachian liver. *Am. Jour. Anat.*, 17, 1915.
- SEGERATRALE:** Teleostierleber. *Anat. Hefte*, 41, 1910.
- STIEDA:** Bau und Entwicklung der Bursa Fabricii. *Zeit. wiss. Zool.*, 34, 1880.
- STÖHR:** Entwicklung der Hypochorda und dorsal Pancreas bei *Rana*. *Morph. Jahrb.* 23, 1895.
- TEICHMANN:** Kropf der Tauben. *Arch. mikr. Anat.*, 34, 1889.
- THYNG:** Pancreas in embryos of pig, rabbit, cat and man. *Am. Jour. Anat.*, 7, 1908.
- VOLKER:** Entwicklung des Pancreas bei den Amnioten. *Arch. mikr. Anat.*, 59, 1901.

RESPIRATORY ORGANS

General

- CLEMENZ:** Äussere Kiemen der Wirbeltiere. *Anat. Hefte*, 5, 1904.
- GÖPPERT:** Kehlkopf der Amphibien und Reptilien. *Morph. Jahrb.*, 22, 1894; 26, 1898; 28, 1899.

- GÖTTE: Ursprung der Lunge. Zool. Jahrb., Anat. Abth., 21, 1905.
 MAKUSCHOK: Genetische Beziehung zwischen Schwimmblase und Lungen. Anat. Anz., 44, 1913.
 MAKUSCHOK: Phylogenetische Entwicklung der Lungen. Anat. Anz., 46, 1914.
 MILLER: Structure of the lung. Jour. Morph., 8, 1893.
 MOSER: Entwicklungsgeschichte der Wirbeltierlunge. Arch. mikr. Anat., 60, 1902.
 OPPEL: Athmungsapparat. Ergebnisse, 13, 1903; 14, 1904; 16, 1906.
 SCHMIDT: Kehlhügel der Amnioten. Morph. Jahrb., 43, 1911.
 SPENGLER: Schwimmblasen, Lungen und Kiementaschen der Wirbeltiere. Zool. Jahrb. Suppl., 7, 1904.

Cyclostomes and Fishes

- BABAK: Darmathmung der Cobiten. Biol. Centralbl., 27, 1907.
 BEAUFORT: Schwimmblase der Malacopterygii. Morph. Jahrb., 39, 1909.
 BRAUS: Embryonal Kiemenapparat von Heptanchus. Anat. Anz., 29, 1906.
 BRIDGE and HADDON: Air-bladder and Weberian ossicles of Siluridae. Phil. Trans., 184, 1893.
 CORNING: Wundernetzbildes in Schwimmblase der Teleostier. Morph. Jahrb., 14, 1888.
 DAHLGREN: Breathing valve of teleosts. Zool. Bull., 2, 1898.
 DOHRN: Urgeschichte, u.s.w. Spritzlochkieme der Selachier, Opercularkieme d. Ganoiden, Pseudobranchie der Teleostier. Neapel. Mitth., 7, 1886.
 GREIL: Homologie der Anamnierkiemen. Anat. Anz., 28, 1906.
 GÖTTE: Kiemen der Fische. Zeitsch. wiss. Zool., 69, 1901.
 JÄGER: Physiologie der Schwimmblase. Biol. Centralbl., 24, 1904.
 KELLICOTT: Develop. vasc. and respiratory systems of Ceratodus. Mem. N. Y. Acad. Sci., 2, 1904.
 MAURER: Pseudobranchien der Knochenfisches. Morph. Jahrb., 9, 1883.
 MOROFF: Entwicklung der Kiemen der Knochenfischen. Arch. mikr. Anat., 60, 1902.
 MOSER: Entwicklung der Schwimmblase. Arch. mikr. Anat., 63, 1904.
 MULLER: Entwicklung und Bedeutung der Pseudobranchie bei Lepidosteus. Arch. mikr. Anat., 49, 1897.
 NUSBAUM: Gasdrüse in Schwimmblase. Anat. Anz., 31, 1907.
 RAND: Functions of spiracle in skate. Am. Nat., 41, 1907. See also Darbyshire, Jour. Linn. Socy., Zool., 30, 1907.
 STOCKARD: Development of mouth and gills in Bdellostoma. Am. Jour. Anat., 5, 1906.
 THILO: Luftsacke bei Kugelfische. Anat. Anz., 16, 1899.
 WIEDERSHEIM: Ein Kehlkopf bei Ganoiden und Dipnoern. Zool. Jahrb. Suppl., 7, 1904.
 ZOGRAFF: Labyrinthine apparatus of labyrinthine fishes. Quar. Jour. Micr. Sci., 28, 1889.

Amphibia

- BRUNER: Smooth facial muscles of anura and salamandrina (respiratory mechanism). Morph. Jahrb., 29, 1901.
 BRUNER: Mechanism of pulmonary respiration in Amphibia. Morph. Jahrb., 48, 1914.
 BRUNER: Jacobson's organ and respiration of Amphibia. Morph. Jahrb., 48, 1914.
 EKMAN: Entwicklung der Kiemenregion einiger anuren Amphibien. Morph. Jahrb., 47, 1913.
 FOX: Tympano-Eustachian passage in toad. Proc. Acad. Nat. Sci., Phila., 1901.
 GREIL: Anlage der Lungen und Ultimobranchialkörper. Anat. Hefte, 49, 1905.
 MARTENS: Entwicklung der Kehlkopfknorpel bei Anuren. Anat. Hefte, 9, 1897.
 MAURER: Kiemen und ihre Gefäße bei Amphibien. Morph. Jahrb., 14, 1888.

- OCHSNER: Lung of Necturus. Bull. Univ. Wisconsin, 33, 1900.
 SEELYE: Circulatory and respiratory systems of Desmognathus. Proc. Boston Socy., Nat. Hist., 32, 1906.
 WHIPPLE: Ypsiloid apparatus of Urodeles. Biol. Bull., 10, 1906.
 WHIPPLE: Naso-labial groove of salamanders. Biol. Bull., 11, 1906.
 WILDER: Phylogenesis of larynx. Anat. Anz., 7, 1892.
 WILDER: Amphibian larynx. Zool. Jahrb. Abth. Anat., 9, 1896.
 WILDER: Lungless salamanders. Anat. Anz., 9, 1894; 12, 1896.
 WILDER: Pharyngo-oesophageal lung of Desmognathus. Am. Nat., 35, 1901.

Sauropsida

- COPE: Lungs of ophidia. Proc. Am. Phil. Socy., 33, 1904.
 GAGE: Aquatic respiration in soft-shelled turtles. Am. Nat., 20, 1886.
 HÄCKER: Unter Kehlkopf der Singvögel. Anat. Anz., 14, 1898.
 HEIDRICH: Mund-Schlundhöhle der Vögel. Morph. Jahrb., 37, 1907.
 HUXLEY: Respiratory organs of Apteryx. Proc. Zool. Socy. London, 1882.
 LARSELL: Development of recurrent bronchi and air sacs of chick. Anat. Anz., 41, 1914.
 LOCY and LARSELL: Embryology of bird's lung. Am. Jour. Anat., 19, 1916.
 MILANI: Reptilienlungen. Zool. Jahrb., Abth. Anat., 8, 1894; 10, 1897.
 MÜLLER: Air sacs of pigeon. Smithsonian Misc. Coll., 50, 1907.
 SAPPEY: Recherches sur l'appareil respiratoire des oiseaux. Paris, 1847.
 STRASSER: Luftsacke der Vögel. Morph. Jahrb., 3, 1877.

Mammals

- BREMER: Lungs of opossum. Am. Jour. Anat., 3, 1904.
 DUBOIS: Morphologie des Larynx. Anat. Anz., 1, 1886.
 FOX: Pharyngeal pouches and their derivatives. Am. Jour. Anat., 8, 1908.
 GÜPPERT: Herkunft des Wisberg'schen Knorpels. Morph. Jahrb., 21, 1894.
 HIS: Bildungsgeschichte der Lungen bei mensch. Embryonen. Arch. Anat. und Phys., 1887.
 JUSTESSEN: Entwicklung und Verzweigung des Bronchialbaumes der Säugetierlunge. Arch. mikr. Anat., 56, 1900.
 MALL: Branchial clefts and thymus of dog. Johns Hopkins Studies Biol. Lab., 4, 1888.
 SHAEFFER: Sinus maxillaris in man. Am. Jour. Anat., 10, 1910.
 SHAEFFER: Lateral walls of cavum nasi in man. Jour. Morph., 21, 1910.
 SYMINGTON: The marsupial larynx. Jour. Anat. and Physiol., 33, 1898; 35, 1899.

CIRCULATION

General

- ALLIS: Pseudobranchial and carotid arteries in gnathostomes. Zool. Jahrb., Abth. Anat., 27, 1908.
 AYERS: Morphology of the carotids. Bull. Mus. Comp. Zool., 17, 1889.
 BOAS: Arterienbogen der Wirbelthiere. Morph. Jahrb., 13, 1887.
 BROMAN: Entwicklung, 'Wanderung' und Variation der Baucharterienzweige bei Wirbeltieren. Ergebnisse, 16, 1906.
 GREIL: Anatomie und Entwicklung des Herzens und Truncus arteriosus der Wirbelthiere. Morph. Jahrb. 31, 1903.

- GREIL: Entwicklung des Truncus arteriosus der Anamnier. *Verhandl. Anat. Gesellsch.*, 17, 1903.
- GROSSER: Kopfvenensystem der Wirbeltier. *Verh. Anat. Gesellsch.*, 21, 1907.
- HOCHSTETTER: Vergl. Anat. und Entwicklung des Venensystem der Amphibien und Fische, *Morph. Jahrb.*, 13, 1888.
- HOCHSTETTER: Entwicklungsgeschichte des Gefässsystem. *Ergebnisse*, 1, 1892.
- HOWELL: Life history of the formed elements of the blood. *Jour. Morph.*, 4, 1890.
- LEWIS: Development of the vena cava inferior. *Am. Jour. Anat.*, 1, 1902.
- LEWIS: Sinusoids. *Anat. Anz.*, 25, 1904.
- REAGAN: Origin of vascular endothelium. *Amer. Jour. Anat.*, 21, 1917.
- RÖSE: Vergl. Anat. des Herzens der Wirbelthiere. *Morph. Jahrb.*, 16, 1890.
- WEIDENREICH: Die roten Blutkörperchen. *Ergebnisse*, 13, 1903.
- WEIDENREICH: Morphologie der Blutzellen. *Anat. Record*, 4, 1910.
- WEIDENREICH: Blut und Blutbildenden und -zerstörenden Organe. *Arch. mikr. Anat.* 65-72, 1904-8.
- WENIG: Entwicklung des Herzens der Wirbeltiere. *Morph. Jahrb.*, 48, 1914.
- WRIGHT: Histogenesis of blood platelets. *Jour. Morph.*, 21, 1910.

Fishes

- ALLEN: Blood-vascular system of Loricati. *Proc. Washington Acad. Sci.*, 7, 1905.
- ALLEN: Subcutaneous vessels in tail of Lepidosteus. *Am. Jour. Anat.*, 8, 1908.
- ALLEN: Subcutaneous vessels in head of Polyodon and Lepidosteus. *Proc. Washington Acad. Sci.*, 9, 1907.
- ALLIS: Pseudobranchial and carotid arteries in Polypterus and Amiurus. *Anat. Anz.*, 33, 1908; in *Esox*, *Salmo*, *Gadus* and *Amia*, l. c., 41, 1912.
- CARAZZI: Sistema arteriosa di Squalidi. *Anat. Anz.*, 36, 1905.
- DANFORTH: Heart and arteries of Polyodon. *Jour. Morph.*, 23, 1912.
- DANFORTH: Coronary and hepatic arteries in Ganoids. *Am. Jour. Anat.*, 19, 1916.
- HOFFMANN: Entwicklung des Herzens und Blutgefässe bei Selachiern. *Morph. Jahrb.*, 19, 1893. *Venensystem*, idem, 20, 1893.
- HOLBROOK: Origin of endocardium in bony fishes. *Bull. Mus. Comp. Zool.*, 25, 1894.
- JACKSON: Vascular system of Bdellostoma. *Jour. Cincinnati Socy. Nat. Hist.*, 20, 1901.
- KEISER: Anlage des Herzens, Langsgefässstamme und Blut bei Petromyzon. *Jena. Zeitsch.*, 51, 1914.
- KELLCOTT: Development of vascular and respiratory systems of Ceratodus. *Mem. N. Y. Acad. Sci.*, 2, 1905.
- MAYER: Entwicklung des Herzens u. d. grossen Gefässstamme bei Selachier. *Mittheil. zool. Sta. Neapel*, 7, 1887; see also 8, 1888.
- PARKER: Blood-vessels of heart of Orthogoriscus. *Anat. Anz.*, 17, 1900.
- PARKER and DAVIS: Blood-vessels of heart of Carcharias, Raia and Amia. *Proc. Boston Socy. Nat. Hist.*, 29, 1899.
- RAND: Posterior connections of lateral vein in skates. *Am. Nat.*, 39, 1905.
- REX: Hirnvenen der Elasmobranchier. *Morph. Jahrb.*, 17, 1891.
- ROBERTSON: Development of heart and vascular system of Lepidosiren. *Quar. Jour. Micr. Sci.*, 59, 1913.
- SENIOR: Conus arteriosus in Tarpon and Megalops. *Biol. Bull.*, 12, 1907.
- SENIOR: Development of heart in shad. *Am. Jour. Anat.*, 9, 1909.
- SILVESTER: Blood-vascular system of Lopholatilus. *Bull. Bureau of Fisheries*, 24, 1904.
- SOBOTTA: Entwicklung des Blut, Herzens und grossen Gefässstamme der Salmoniden. *Anat. Hefte*, 19, 1902.

Amphibia

- BETHE:** Blutgefäßsystem von Salamandra, Triton und Spelerpes. *Zeit. wiss. Zool.*, 63, 1898.
- BRUNER:** Heart of lungless salamanders. *Jour. Morph.*, 16, 1900.
- HUXLEY:** Skull and heart of Menobranchus [Necturus]. *Proc. Zool. Socy. London*, 1874.
- HOPKINS:** Heart of lungless salamanders. *Am. Nat.*, 30, 1896.
- MARSHALL and BLES:** Development of blood-vessels in frog. *Studies Biol. Lab. Owens' College*, 2, 1890.
- MAURER:** Kiemen und ihre Gefäße bei Amphibien. *Morph. Jahrb.*, 14, 1888.
- MILLER:** Blood- and lymph-vessels of lung of Necturus. *Am. Jour. Anat.*, 4, 1905.
- PARKER:** Persistence of left postcardinal vein in frog; homologies of veins in Dipnoi. *Proc. Zool. Socy. London*, 1889.
- RABL:** Bildung des Herzens der Amphibien. *Morph. Jahrb.*, 12, 1887.
- REX:** Hirnvenen der Amphibien. *Morph. Jahrb.*, 19, 1892.
- ROMEISER:** Abnormal venous system in Necturus. *Am. Nat.*, 39, 1906.
- SANTHOFF and VAN VORHIS:** Vascular system of Necturus. *Bull. Univ. Wisc.*, 33, 1900.
- SEELYE:** Circulatory and respiratory systems of Desmognathus. *Proc. Boston Socy. Nat. Hist.*, 32, 1906.

Sauropsida

- BRUNER:** Cephalic veins and sinuses of reptiles. *Am. Jour. Anat.*, 7, 1907.
- DAVENPORT:** Carotids and Botall's duct of alligator. *Bull. Mus. Comp. Zool.*, 24, 1893.
- EVANS:** Earliest blood-vessels in anterior limbs of birds. *Am. Jour. Anat.*, 9, 1909.
- GROSSER and BREZINA:** Entwicklung der Venen des Kopfes und Halses der Reptilien. *Morph. Jahrb.*, 23, 1895.
- HOCHSTETTER:** Entwicklungsgeschichte des Venensystems der Amnioten. Reptilien. *Morph. Jahrb.*, 19, 1892.
- HOCHSTETTER:** Arterien des Darmcanals der Saurier. *Morph. Jahrb.*, 26, 1898.
- MACKAY:** Development of branchial arches in birds. *Trans. Roy. Socy. London*, 179, 1888.
- MILLER:** Development of postcava in birds. *Am. Jour. Anat.*, 2, 1903.
- REESE:** Vascular system of alligator. *Proc. Acad. Nat. Sci., Philadelphia*, 1914.
- STRÖMSTEN:** Anat. and develop. venous system of Chelonia. *Am. Jour. Anat.*, 4, 1905.

Mammals

- BEDDARD:** Azygos veins in mammals. *Proc. Zool. Socy. London*, 1907.
- BORN:** Entwicklungsgeschichte des Säugetierherzens. *Arch. mikr. Anat.*, 33, 1889.
- DAVIS:** Chief veins in early pig embryos. *Am. Jour. Anat.*, 10, 1910.
- DEKTER:** Vitelline veins of cat. *Am. Jour. Anat.*, 1, 1902.
- EMMEL:** Erythroblasts in pig embryo. *Am. Jour. Anat.*, 16, 1914.
- GÖPFERT:** Entwicklung von Varietäten im Arteriensystem der weissen Maus. *Morph. Jahrb.*, 40, 1909.
- HOCHSTETTER:** Entwicklungsgeschichte des Venensystems der Amnioten. *Mammalia*. *Morph. Jahrb.*, 20, 1893.
- HOCHSTETTER:** Venensystem der Edentaten. *Morph. Jahrb.*, 25, 1897.
- HOFMANN:** Entwicklung der Kopfarterien bei Sus. *Morph. Jahrb.*, 48, 1914.
- LEWIS:** Development of vena cava inferior. *Am. Jour. Anat.*, 1, 1902.
- LEWIS:** Development of veins in limbs of rabbit. *Am. Jour. Anat.*, 5, 1905.

- MCCLURE: Abnormalities in postcava of cat. *Am. Nat.*, 34, 1900.
 MCCLURE: Anatomy and development of venous system of Didelphys. *Am. Jour. Anat.* 2, 1903; 5, 1905.
 MINOT: Veins of Wolfian body of pig. *Proc. Boston Socy. Nat. Hist.*, 28, 1898.
 PARKER and TOZIER: Thoracic derivatives of postcardinals in swine. *Bull. Mus. Comp. Zool.*, 31, 1898.
 REAGAN: Fifth aortic arch in mammals. *Am. Jour. Anat.*, 12, 1912.
 RÖSE: Entwicklung des Säugethierherzens. *Morph. Jahrb.*, 15, 1890.
 SALZER: Entwicklung der Kopfvenen des Meerschweinchens. *Morph. Jahrb.*, 23, 1895.
 SICHER: Entwicklung der Kopfarterien von Talpa. *Morph. Jahrb.*, 44, 1912.
 TANDLER: Anatomie der Kopfarterien bei Mammalia. *Anat. Hefte*, 18, 1901.

Lymphatics

- ALLEN: Lymphatics of Scorpaenichthys. *Proc. Washington Acad. Sci.*, 8, 1906. *Am. Jour. Anat.*, 11, 1911.
 ALLEN: Subcutaneous vessels in tail of Lepidosteus. *Anat. Record*, 3, 1908.
 ALLEN: Development of veno-lymphatics in tail of Bdellostoma. *Quar. Jour. Micr. Sci.*, 59, 1913.
 BAETJER: Mesenteric lymph sac in pig. *Anat. Record*, 2, 1908.
 BUDGE: Lymphherzen bei Hühnerembryonen. *Arch. Anat. u. Physiol.*, 1887.
 HELLY: Hämolympdrüsen. *Ergebnisse*, 12, 1902.
 HOPKINS: Lymphatics and enteric epithelium of Amia. *Wilder Quarter Century Book*, 1893.
 HOYER und UDZIELA: Lymphgefäßssystem von Salamanderlarven. *Morph. Jahrb.*, 44, 1912.
 HUNTINGTON: Anatomy and development of systematic lymphatic vessels of cat. *Memoirs Wistar Inst.*, 1, 1911.
 HUNTINGTON and MCCLURE: Numerous papers on lymph system of mammals in *Am. Jour. Anat.* and *Anat. Record*.
 KILLIAN: Bursa und tonsilla pharyngea. *Morph. Jahrb.*, 14, 1888.
 KNOWER: Development of lymph hearts and lymph sacs in frog. *Anat. Record*, 2, 1908.
 LEWIS: Development of lymphatics in rabbit. *Am. Jour. Anat.*, 5, 1905.
 MCCLURE: Development of lymphatics in cat. *Anat. Anz.*, 32, 1908.
 MARCUS: Intersegmentale Lymphherzen der Gymnophionen. *Morph. Jahrb.*, 38, 1908.
 MAURER: Anlage der Milz und lymphat. Zellen bei Amphibien. *Morph. Jahrb.*, 16, 1890.
 MEYER: Hämolymp glands of sheep. *Anat. Record*, 2, 1908.
 MILLER: Development of jugular lymph sac of birds. *Am. Jour. Anat.*, 12, 1912.
 MÜLLER: Lymphherzens Chelonier. *Abhandl. Berlin Acad.*, 1839.
 SABIN: Origin of lymphatic system in pig. *Am. Jour. Anat.*, 1, 1902; 3, 1904; 4, 1905.
 SABIN: Lymphatic system in human embryos. *Am. Jour. Anat.*, 9, 1909.
 SABIN: Recent articles on development of lymph system. *Anat. Record*, 5, 1911 (Bibliography).
 SABIN: Mode of growth of lymphatic system, *Science*, 44, p. 145, 1916.
 STÖHR: Lymphknoten des Darmes. *Arch. mikr. Anat.*, 33, 1889.
 STÖHR: Entwicklung von Darmlymphknötchen, u. s. w. *Arch. mikr. Anat.*, 51, 1898.
 TONKOFF: Entwicklung der Milz bei Vögeln. *Anat. Anz.*, 16, 1899.
 TONKOFF: Entwicklung der Milz bei Amnioten. *Arch. mikr. Anat.*, 56, 1900.
 TONKOFF: Entwicklung der Milz bei Tropicodonotus. *Anat. Anz.*, 23, 1903.
 TONELY: Vielzählige Lymphherzens bei Salamandra. *Zool. Anz.*, 7, 1884.

UROGENITAL ORGANS

General

- BARDELEBEN:** Spermatogenese bei Menschen. *Jena. Zeitsch.*, 31, 1898.
- BORN:** Entwicklung der Geschlechtsdrüse. *Ergebnisse*, 4, 1895.
- DYSELHORST:** Harnleiter der Wirbeltiere. *Anat. Hefte*, 4, 1894.
- FELIX:** Entwicklungsgeschichte des Excretionsystemes, von Rückert (1888) bis 1904, *Ergebnisse*, 13, 1903.
- FÜRBRINGER:** Excretionsorgane der Vertebraten. *Morph. Jahrb.*, 4, 1878.
- GERHARDT:** Kopulationsorgans der Wirbeltiere. *Ergebnisse und Fortschritt der Zoologie*, 1, 1909.
- HOFFMANN:** Entwicklung der Urogenitalorgane bei Anamnia. *Zeits. wiss. Zool.*, 44, 1886.
- MONTGOMERY:** Morphology of excretory organs of metazoa. *Proc. Am. Philos. Socy.*, 47, 1908.
- PETER:** Bau und Entwicklung der Niere. *Jena*, 1909.
- RÜCKERT:** Entwicklung der Exkretionsorgane. *Ergebnisse*, 1, 1892.
- SEMON:** Bauplan der Urogenitalsystem der Wirbeltiere, u. s.w. *Jena. Zeitsch.*, 26, 1891.
- SEMPER:** Urogenitalsystem der Plagiostomen. *Arbeit. a. d. zool. zoot. Inst. Würzburg*, 2, 1875.
- TAUSSIG:** Development of the hymen. *Am. Jour. Anat.*, 8, 1908.
- WIJHE:** Mesodermsegmente des Rumpfes und Entwicklung des Exkretionsystemes. *Arch. mikr. Anat.*, 33, 1889.

Cyclostomes and Fishes

- ALLEN:** Origin of sex-cells of *Amia* and *Lepidosteus*. *Jour. Morph.*, 22, 1911.
- BATES:** Pronephric duct in Elasmobranchs. *Jour. Morph.*, 25, 1914.
- DODDS:** Segregation of germ-cells of *Lophius*. *Jour. Morph.*, 21, 1910.
- EMERY:** Kopfniere der Teleostier. *Biol. Centralb.*, 1, 1881-2.
- BALFOUR and PARKER:** *Lepidosteus*. *Phil. Trans.*, 1882.
- HALLER:** Ovarialsack der Knochenfische. *Anat. Anz.*, 27, 1905.
- HALLER:** Phylogense des Nierenorganes der Knochenfische. *Jena. Zeitsch.*, 43, 1908.
- KERR:** Male genito-urinary organs of *Lepidosiren* and *Protopterus*. *Proc. Zool. Socy. London*, 1901.
- KRALL:** Männliche Beckenflosse von *Hexanchus*. *Morph. Jahrb.*, 37, 1908.
- MAAS:** Entwicklung der Vorniere und Urnieren bei *Myxine*. *Zool. Jahrb., Abth. Anat.*, 10, 1897.
- MÜLLER:** Urogenitalsystem des *Amphioxus* und der Cyclostomen. *Jena. Zeitsch.*, 9, 1875.
- PRICE:** Development of excretory organs of *Bdellostoma*. *Am. Jour. Anat.*, 4, 1904.
- RABL:** Entwicklung des Urogenitalsystems der Selachier. *Morph. Jahrb.*, 24, 1896.
- RÜCKERT:** Entstehung der Exkretionsorgane bei Selachiern. *Arch. Anat. u. Physiol.*, 1888.
- SCHREINER:** Generationsorgane von *Myxine*. *Biol. Centralbl.*, 24, 1904.
- WHEELER:** Development of urogenital organs of Lamprey. *Zool. Jahrb., Abth. Anat.*, 13, 1899.
- WIJHE:** Entwicklung des Exkretionssystemes und andere Organe bei Selachiern. *Anat. Anz.*, 2, 1888.
- WOODS:** Origin and migration of germ-cells in *Acanthias*. *Am. Jour. Anat.*, 1, 1902.

Amphibia

- FIELD:** Development of pronephros and segmental duct in amphibia. *Bull. Mus. Comp. Zool.*, 21, 1891.

- FIELD: Morphologie der Harnblase bei Amphibien. *Morph. Arbeiten*, 4, 1894.
- HALL: Development of mesonephros and Müllerian ducts in amphibia. *Bull. Mus. Comp. Zool.*, 45, 1904.
- KING: Bidder's organ in Bufo. *Jour. Morph.*, 19, 1908.
- KING: Anomalies in genital organs of Bufo. *Am. Jour. Anat.*, 10., 1910.
- MARSHALL and BLES: Development of kidneys and fat bodies in frog. *Studies Biol. Lab. Owens Coll.*, 2, 1890.
- MOLLENDORF: Entwicklung der Darmarterien und Vornieren Glomerulus bei Bombinator. *Morph. Jahrb.*, 43, 1911.
- SEMON: Bauplan der Urogenitalsystems, dargelegt an Ichthyophis. *Jena. Zeitschr.*, 26, 1891.
- SPENGLER: Urogenitalsystem der Amphibien. *Arbeit. zool. zoot. Inst. Würzburg*, 3, 1886.

Sauropsida

- BOAS: Begattungsorgane der Amnioten. *Morph. Jahrb.*, 17, 1891.
- COPE: Hemipenes of the sauria. *Proc. Acad. Nat. Sci., Philadelphia*, 1896.
- FLECK: Entwicklung des Urogenitalsystem beim Gecko. *Anat. Hefte*, 41, 1910.
- GASSER: Entstehung der Kloacalöffnung der Hühnerembryonen. *Arch. Anat. und Physiol.*, 1880.
- GREGORY: Development of excretory system in turtles. *Zool. Jahrb., Abth. Anat.*, 13, 1900.
- HOFFMANN: Entwicklung der Urogenitalorgane bei Reptilien. *Zeit. wiss. Zool.*, 48, 1889.
- LIEBE: Männliche Begattungsorgane der Hausente. *Jena. Zeitsch.*, 51, 1914.
- RABL: Entwicklung der Vorniere bei Vögel. *Arch. mikr. Anat.*, 72, 1908.
- SCHREINER: Entwicklung der Amniotenniere. *Zeitsch. wiss. Zool.*, 71, 1902.
- SWIFT: Origin and history of germ cells of chick. *Am. Jour. Anat.*, 15, 1914, and 18, 1915.
- WIEDERSHEIM: Entwicklung des Urogenitalapparates bei Krokodilien und Schildkröten. *Arch. mikr. Anat.*, 36, 1890.

Mammals

- BEILING: Anatomie der Vagina und Uterus der Säugetiere. *Arch. mikr. Anat.*, 67, 1906.
- BROEK: Urogenital-apparates der Beutler. *Morph. Jahrb.*, 41, 1910.
- BOAS: Begattungsorgane der Amnioten. *Morph. Jahrb.*, 17, 1891.
- BREMER: Morphology of tubules of testis and epididymis. *Am. Jour. Anat.*, 11, 1911.
- BROEK: Männlichen Geschlechtsorgane der Beuteltiere. *Morph. Jahrb.*, 41, 1910.
- COLE: Intromittent sac of male guinea pig. *Jour. Anat. and Physiol.*, 32, 1897.
- COURANT: Preputialdrüse des Kaninchens. *Arch. mikr. Anat.*, 62, 1903.
- DAUDT: Urogenitalapparates der Cetaceen. *Jena. Zeitschr.*, 32, 1898.
- GERHARDT: Entwicklung der bleibenden Niere. *Arch. mikr. Anat.*, 57, 1901.
- GUDERNATSCH: Hermaphroditismus verus in man. *Am. Jour. Anat.* 11, 1911.
- GILBERT: Os Priapi der Säuger. *Morph. Jahrb.*, 8, 1892.
- GERHARDT: Kopulationsorgane der Säugetiere. *Jena. Zeitsch.*, 39, 1904.
- KAUDERN: Männl. Geschlechtsorgane von Insectivoren und Lemuriden. *Zool. Jahrb., Abt. Anat.*, 31, 1910.
- KEIBEL: Entwicklung der Harnblase. *Anat. Anz.*, 6, 1891.
- KEIBEL: Entwicklung des menschlichen Urogenitalapparates. *Arch. Anat. und Physiol. Anat. Abth.*, 1896.
- KINGSBURY: Morphogenesis of mammalian ovary. *Am. Jour. Anat.*, 15, 1914.
- KLAATSCH: Descensus testicularum. *Morph. Jahrb.*, 16, 1890.

- MACCALLUM:** Wolffian body of higher animals. *Am. Jour. Anat.*, 1, 1892.
MONTGOMERY: Human cells of Sertoli. *Biol. Bulletin*, 21, 1911.
MÜLLER: Prostata der Haussäugetiere. *Anat. Hefte*, 26, 1904.
POULTON: Structures connected with ovarian ovum of marsupials and monotremes. *Quart. Jour. Micros. Sci.*, 24, 1884.
ROBINSON: Position and peritoneal relations of mammalian ovum. *Jour. Anat. and Physiol.*, 1887.
SCHREINER: Entwicklung der Amniotenniere. *Zeitsch. wiss. Zool.*, 71, 1902.
SOBOTA: Entstehung des Corpus luteum. *Ergebnisse*, 8, 1898; 11, 1901.
WEBER: Entwicklung des uropoetisches Apparats bei Säugern. *Morph. Arbeiten*, 7, 1897.

SUPRARENALS

- AICHEL:** Entwicklungsgeschichte und Stammesgeschichte der Nebennieren. *Arch. mikr. Anat.*, 56, 1900.
COLLINGS and VINCENT: So-called suprarenals in cyclostomes. *Anat. Anz.*, 12, 1896.
FLINT: The Adrenal. *Johns Hopkins Hospital Report*, 1900.
KOHN: Nebennieren der Selachier. *Arch. mikr. Anat.*, 53, 1898.
KUNZ: Develop. adrenals in turtle. *Am. Jour. Anat.*, 13, 1912.
OGUSHI: Histol. Besonderheiten bei Trionyx: Nebenhodenepithel. *Anat. Anz.*, 45, 1913.
SRDINKO: Nebennieren bei Anuren. *Anat. Anz.*, 18, 1900.
SRDINKO: Nebennieren der Knochenfischen. *Arch. mikr. Anat.*, 71, 1908.
VINCENT: Discussion of suprarenals. *Jour. Anat. and Phys.*, 38, 1903.
WELDON: Suprarenals of vertebrates. *Quar. Jour. Micr. Sci.*, 24, 1884; 25, 1885.

FETAL ENVELOPES, PLACENTA, ETC.

- CORNING:** Erste Anlage der Allantois bei Reptilien. *Morph. Jahrb.*, 23, 1895.
HILL: Placentation of Perameles. *Quar. Jour. Micr. Sci.*, 40, 1898.
HUBRECHT: Placentation of Erinaceus. *Quar. Jour. Micr. Sci.*, 30, 1889. Of *Sorex*.
idem, 35, 1893. *Spolia Nemois* (lemurs and edentates), *idem*, 36, 1904.
MARSHALL: Physiology of reproduction. London, 1910.
MINOT: Uterus and embryo. *Jour. Morph.*, 2, 1889.
MINOT: Theory of the structure of the placenta. *Anat. Anz.*, 6, 1891.
OSBORN: Foetal membranes of marsupials. *Jour. Morph.*, 1, 1887.
ROBINSON: Segmentation cavity, archenteron, germ layers and amnion of mammals. *Quar. Jour. Micr. Sci.*, 33, 1892.
TURNER: Lectures on the anatomy of the placenta. Edinburgh, 1876.
VAN BENEDEN ET JULIN: Formation des annexes fœtales chez les Mammifères. *Archives de Biol.*, 5, 1884.

DEFINITIONS OF SYSTEMATIC NAMES

- Acanthias**, genus of sharks including common dogfish.
- Acipenser**, genus of ganoids; sturgeon.
- Aglossa**, tongueless toads from Africa and South America.
- Allantoidea**, the higher vertebrates with allantois; reptiles, birds and mammals.
- Amblystoma**, genus of tailed amphibians, largely American.
- Amia**, genus of ganoid fishes peculiar to America.
- Ammocœtes**, the larval stage of the lampreys.
- Amniotes**, division of vertebrates with amnion and allantois in development; reptiles, birds and mammal.
- Amphibia**, class of vertebrates, young with gills, adults with lungs; frogs, toads and salamanders.
- Amphioxus**, fish-like form without vertebræ, type of group of *Leptocardii*.
- Amphipnous**, eel-like fishes from India.
- Amphisbænans**, legless lizards.
- Amphiuma**, genus of tailed amphibians with rudimentary legs and gill slits; southern U. S.
- Anallantoidea**, vertebrates without an allantois; ichthyopsida.
- Anamnia**, vertebrates without an amnion; ichthyopsida.
- Anguis**, genus of footless lizards.
- Anser**, genus of birds including geese.
- Anthropoids**; sub-order of primates including the higher apes and man.
- Anura**, order containing the tailless amphibians; frogs and toads.
- Aquila**, genus of birds including eagles.
- Archæopteryx**, a fossil bird with teeth and a reptilian tail.
- Archegosaurus**, genus of extinct stegocephal amphibians.
- Arcifera**, group including toads and tree toads.
- Arthrodira**, order of extinct dipnoi (lung-fishes) some very large.
- Artiodactyla**, ungulate mammals with even number of toes; cattle, sheep, deer.
- Astroscopus**, genus of electric fishes; marine.
- Atelodus**, genus of two-horned rhinoceros.
- Aves**, the class of birds.
- Bdellostoma**, genus of myxinoids; hag fishes of the Pacific.
- Belone**, genus of fishes; bony gars.
- Bombinator**, genus of European toads unke.
- Bradypus**, genus of edentate sloths.
- Branchiosaurus**, genus of extinct stegocephal amphibia.
- Bufo**, genus of amphibians, toads.
- Buteo**, genus of raptorial birds, hawks.
- Butyrinus**, genus of herring-like fishes.
- Cæcilians**, a group of legless tropical amphibians.
- Caiman**, genus of crocodiles.
- Calamoichthys**, genus of ganoid fishes from Africa.
- Callopterus**, genus of extinct ganoid fishes.
- Camptosaurus**, genus of extinct dinosaur reptiles.
- Capitosaurus**, genus of extinct stegocephalous amphibia.
- Carcharias**, genus of sharks; sand shark.
- Carinatae**, birds with a keel to the sternum, includes all living birds except ostriches.
- Carnivores**, order of flesh-eating mammals; cats, dogs, bears, weasels, seals.
- Castor**, genus of rodents, beaver.
- Ceratodus**, genus of dipnoi (lung-fishes) from Australia.
- Ceratophrys**, genus of So. American toads.
- Cervus**, genus of Ungulates, common deer.
- Cestracion**, genus of sharks from the Pacific.
- Cetacea**, order of mammals, whales.
- Chauna**, genus of So American crane-like birds; hooded screamers.
- Chelonia**, order of reptile turtles.

- Chelone, genus of turtles, green turtle.
 Chelydra, genus of turtles, snapping turtle.
 Chelydosaurus, genus of extinct stegocephalous amphibia.
 Chimera, genus of peculiar deep-water sharks.
 Chimaeroids, order of shark-like fishes; Holocephali.
 Chiroptera, order of mammals, bats.
 Chlamydoselache, genus of primitive deep-sea sharks from Japan.
 Choloepeus, genus of edentates, sloths.
 Chondrostei, order of ganoid fishes, sturgeon.
 Chrysophrys, genus of fishes; sea bream of Europe.
 Chrysothrix, a genus of So. American monkeys.
 Cistudo, genus of chelonia; box turtles.
 Cladoselache, genus of extinct sharks.
 Clupeidæ, family of fishes including herring, shad, alewives and menhaden.
 Cobitis, genus of fishes; loaches.
 Coregonus, genus of fresh-water fishes; white fish.
 Crocodylia, order of reptiles including the alligator.
 Crotalus, genus of snakes, rattlesnakes.
 Cryptobranchus, genus of tailed amphibians with permanent gill slits; hell-bender of No. America.
 Cyclostomes; class of vertebrates without jaws, including lampreys and hag fishes.
 Cynognathus, genus of extinct theromorph reptiles.
 Cyprinids, family of freshwater fishes, carp, minnows.
 Delphinus, genus of whales; dolphins.
 Derotremes, tailed amphibia with permanent gill slits.
 Desmognathus, genus of salamanders.
 Didelphys, genus of marsupials, opossums.
 Diemyctylus, genus of small spotted salamanders.
 Dinosaurs, extinct terrestrial reptiles, some of enormous size.
 Dipnoi, sub-class of fishes with gills and lungs, lung-fishes.
 Discosaurus, genus of stegocephalous amphibians.
 Dromatherium, genus of extinct, primitive mammals.
 Echidna, genus of monotremes, spiny ant-eaters of Australia.
 Edentates, order of mammals including sloths, armadillos, etc.
 Elasmobranchs, a sub-class of vertebrates including the sharks and skates.
 Embiotocids, family of fishes from the Pacific which bear living young; surf perches.
 Epicrion, genus of cæcilians.
 Erinaceus, genus of insectivorous mammals; hedgehogs.
 Erythrinus, genus of tropical fishes.
 Euornithes, a name given to all recent birds.
 Eupomatus, fresh-water sunfish.
 Eurycormus, genus of fossil ganoid fishes.
 Firmisternia, anurous amphibia with the halves of the sternum united to each other; frogs.
 Fulica, genus of water bird; coots.
 Galeocerdo, genus of selachians; tiger sharks.
 Galeopithecus, a flying mammal from Asia of uncertain position.
 Galeus, genus of sharks; dogfish.
 Gallus, genus of birds including the common fowl.
 Gambusia, genus of fishes; top-minnow.
 Ganoids, sub-class of fishes intermediate between sharks and bony fishes; sturgeon, garpike, etc.
 Geococcyx, a genus of cuckoos.
 Geotriton, a genus of European salamanders.
 Gerrhonotus, genus of lizards.
 Glyptodon, genus of edentates allied to armadillos.
 Gnathostomes, vertebrates which have jaws; includes all except cyclostomes.
 Gobiids, family of small fishes, mostly marine; gobies.
 Gymnophiona, order of amphibia without tail or legs; tropical; cæcilians.
 Gymnotus, electric eel of So. America.
 Halmaturus, genus of kangaroos.

- Hatteria, another name for Sphenodon.
- Heloderma, poisonous lizard from Arizona; Gila monster.
- Heptanchus, primitive shark with seven gill slits.
- Hexanchus, primitive shark with six gill slits.
- Holocephali, order of shark-like fishes; Chimæra.
- Hypogeophis, genus of Cæcilians.
- Hyracoidea, order of mammals including Hyrax.
- Ichthyophis, genus of cæcilians from Ceylon.
- Ichthyopsida, group of vertebrates which have gills; fishes, amphibia.
- Ichthyosaurs, extinct aquatic reptiles.
- Iguana, genus of tropical American lizards.
- Insectivores, order of small mammals; moles, shrews, etc.
- Inuus, genus of macaques including the Barbary ape.
- Lacerta, genus including the common lizards of Europe.
- Lacertilia, sub-order of reptiles including all lizards.
- Lagenorhynchus, a genus of dolphins.
- Lepidosiren, genus of lung fishes (dipnoi) from South America.
- Lepidosteus, genus of ganoid fishes, gar-pike.
- Lopholatilus, genus of teleosts from Gulf Stream; tile fish.
- Macropus, genus of marsupials; kangaroos.
- Mammals, class of vertebrates, with hair, nourishing the young with milk.
- Manatus, genus of sirenians, manatees.
- Manis, genus of old-world edentates; scaly ant-eaters.
- Marsupialia, sub-class of mammals with pouch for young, opossums, kangaroos, etc.
- Megalops, genus of fishes including the tarpon.
- Melanerpeton, genus of extinct stegocephal amphibians.
- Monodelphia, sub-class of mammals, including all except monotremes and marsupials.
- Monotremata, sub-class of mammals with cloaca; includes duckbill and Echidna of Australia.
- Morones, genus of catfishes.
- Mugil, genus of fishes, mullets.
- Mustelus, genus of small sharks; dogfish.
- Myrmecobius, genus of Australian marsupials.
- Myxine, genus of cyclostomes; hag fishes.
- Myxinoids, group of cyclostomes; hag fishes.
- Necturus, genus of aquatic amphibians with tail and external gills, central U. S.
- Notidanids, sub-order of sharks with more than five gill clefts.
- Nototrema, genus of South American toads with dorsal brood sac.
- Ophidia, sub-order of reptiles; snakes.
- Opisthocomus, South American bird, type of a separate sub-order.
- Opisthodelphys, genus of tropical American tree-toads.
- Ornithorhynchus, genus of monotremes; duckbill of Australia.
- Ostariophysii, bony fishes with Weberian apparatus.
- Ostracoderms, a group of extinct vertebrates of very uncertain position.
- Palæohatteria, a fossil reptile allied to Sphenodon.
- Palæospondylus, a problematical fossil vertebrate from Scotland.
- Perennibranchs, tailed amphibia which retain the gills through life.
- Perissodactyls, sub-order of mammals with odd number of toes; horses, rhinoceros, tapirs.
- Petrobates, genus of extinct theromorph reptiles.
- Petromyzonts, sub-class of cyclostomes, lampreys.
- Phoca, genus of carnivores including common seals.
- Physoclisti, fishes in which the air-bladder is closed.
- Physostomi, group of fishes in which the air-bladder has a duct; mostly fresh water.
- Pipa, tongueless toad from South America.

- Pisces, the class of fishes.
- Placentalia, all mammals (except marsupials and monotremes) in which a placenta occurs.
- Placodus, genus of extinct theriomorph reptiles.
- Plesiosaurs, order of extinct, long-necked swimming reptiles.
- Polyodon, genus of ganoid fishes, paddle fish.
- Polypterus, genus of ganoids from Africa.
- Porichthys, genus of fishes from Pacific; midshipman.
- Primates, highest order of mammals, including monkeys, apes and man.
- Pristiurus, genus of European dogfish.
- Proboscidea, order of mammals, including elephants.
- Procolophon, genus of extinct theromorph reptiles.
- Proteus, genus of tailed amphibians from caves of Austria, allied to Necturus.
- Protopterus, genus of dipnoi from Africa.
- Psittacus, genus of parrots.
- Pterodactyls, extinct flying reptiles.
- Pterosaurs, extinct flying reptiles, pterodactyls.
- Pythonomorphs, a group of extinct swimming reptiles.
- Raia, genus of elasmobranchs, including the skates.
- Rana, genus of amphibia, frogs.
- Ratitæ, birds without keel to sternum, ostriches.
- Rhea, three-toed South American ostrich.
- Rhynchobatus, genus of tropical skates.
- Rhynchocephalia, order of lizard-like reptiles; Sphenodon of New Zealand only living species.
- Rodentia, order of mammals with gnawing teeth, rats, rabbits, beaver.
- Ruminants, group of ungulate mammals which chew the cud.
- Salamandra, genus of tailed amphibia from Europe.
- Salamandrina, order of tailed amphibians without gills.
- Salmonids, family of fishes including trout and salmon.
- Sauropsida, class of vertebrates including reptiles and birds.
- Sceloporus, genus of lizards of eastern United States.
- Scomber, genus of fishes; mackerel.
- Scorpænichthys, genus of sculpins.
- Selachii, order of elasmobranchs; sharks.
- Serranidæ, family of marine, perch-like fishes.
- Siluroids, order of fishes containing the cat-fishes.
- Siren, genus of tailed amphibian from U. S. with external gills.
- Sirenia, order of marine mammals; manatees and dugongs.
- Sirenoidea, order of lung-fishes, containing the living species.
- Spalacotherium, genus of extinct mammals.
- Sphenodon, genus of lizard-like reptiles from New Zealand; order Rhynchocephalia.
- Squamata, order of reptiles including snakes and lizards.
- Stegocephala, order of extinct amphibians.
- Stegosaurs, family of extinct dinosaur reptiles, some very large.
- Stenops, genus of lemurs.
- Stenostomus, genus of fishes; scup.
- Teleostomes, fishes with true jaw, includes ganoids and teleosts.
- Teleosts, order of fishes with bony skeleton, including all common fishes.
- Testudo, genus of land turtles.
- Testudinata, turtles, same as Chelonia.
- Tetrapoda, term to include amphibia, reptiles, birds, and mammals, which have feet in place of fins.
- Theromorpha, extinct reptiles, forming the lowest order of the class.
- Tinnunculus, genus of hawk-like birds; kestrel.
- Torpedo, genus of skates with remarkable electric powers.
- Trionyx, genus of fresh-water turtles.
- Triton, genus of tailed amphibian, aquatic, European.
- Tropidonotus, genus of snakes, including our water snake.
- Trygon, genus of skates, string-rays.
- Typhlopidae, family of peculiar tropical serpents.

Ungulates, order of mammals which walk on the tips of the toes; horse, cattle, deer, antelope, etc.

Urodeles, order of tailed amphibia.

Varanus, genus of lizards from Africa.

Xenarthra, sub-order of American edentates, ant-eaters and armadillos.

Xenopus, genus of tongueless toads from Africa.

Zeuglodon a genus of extinct whales (Cetacea).

Ziphius, genus of toothed whales.

LATIN AND GREEK ROOTS OF TECHNICAL WORDS

The following list of Latin and Greek roots and stems may prove of value to students who wish to know the meaning of anatomical and embryological names. The root is given in the form in which it is usually employed in combination, and there is no attempt to give the form of the word from which it is derived. Parentheses are used to show variants, usually the result of declination or conjugation.

<i>a</i> , at the beginning of many words, without	<i>aqua</i> , water
<i>ab</i> , from	<i>arach</i> , spider, spider-web
<i>abduc</i> , lead or draw from	<i>arbor</i> , tree
<i>acanth</i> , prickle or spine	<i>arc</i> , arch
<i>acer</i> , without horns	<i>arch</i> , ancient, primitive
<i>acetabul</i> , vinegar cup	<i>archos</i> , anus, the rectum
<i>acin</i> , cluster of grapes	<i>arc</i> , space
<i>acro</i> , summit or top	<i>argent</i> , silver
<i>actin</i> , ray	<i>arthro</i> , joint
<i>acust</i> , relating to hearing	<i>artic</i> , joint
<i>ad</i> , to, towards	<i>artio</i> , even in number
<i>adduct</i> , draw to or towards	<i>aryten</i> , pitcher
<i>adiipo</i> , fat	<i>asc</i> , sac, pouch
<i>advehen</i> , carrying to	<i>aspid</i> , shield
<i>adventitia</i> , foreign, coming or added to	<i>aster</i> , star
<i>aegitho</i> , sparrow	<i>astrag</i> , dice, originally a knuckle bone, used as a die
<i>affer</i> , carrying to	<i>astra</i> , star
<i>ala</i> , wing	<i>astyl</i> , without pillar or prop
<i>alb</i> , white	<i>ater</i> , <i>atra</i> , black
<i>ali</i> , wing (in some cases a different meaning)	<i>atlas</i> , a Titan, fabled to carry the on his shoulders
<i>allant</i> , sausage	<i>atr (ium)</i> , vestibule or forecourt
<i>alve</i> , pit, cavity or socket	<i>aur</i> , ear, gold
<i>ambly</i> , blunt	<i>auto</i> , self
<i>amnio</i> , a fetal envelope	<i>axi</i> , axis
<i>amoeb</i> , change	<i>azyg</i> , unpaired (without a yoke fellow)
<i>amphi</i> , both, on both sides	
<i>ampulla</i> , a flask	
<i>an</i> , at the beginning of words, without	<i>baena</i> , walking
<i>ana</i> , up, back, again, anew	<i>balan</i> , acorn
<i>anchus</i> , bend, bay or sinus	<i>barb</i> , beard
<i>andr</i> , man (male)	<i>basi</i> , at the bottom
<i>angul</i> , angle	<i>bat (is)</i> , skate, ray
<i>ankylo</i> , stiffening of the joints	<i>bdella</i> , sucker
<i>anomo</i> , lawless, irregular	<i>bi (o or a)</i> , life
<i>ante</i> , in front of	<i>bi (s)</i> , twice or two
<i>anthro</i> , man	<i>bigemin</i> , twins, paired
<i>anti</i> , opposite, against	<i>blast</i> , germ
<i>atr</i> , cave	<i>botry</i> , small bunch of grapes
<i>aorta</i> , lifted up (part of blood-vessel)	<i>brachi</i> , especially upper
<i>apo</i> , from	<i>brachy</i> , short

<i>brady</i> , slow	<i>clav</i> , key
<i>branch</i> , gill	<i>cleid</i> , key
<i>bronch</i> , windpipe	<i>cleist</i> , closed
<i>bucca</i> , cavity of mouth	<i>cleihr</i> , bar or key
<i>bull</i> , bubble, flask	<i>clin</i> , bed, recline
<i>buno</i> , hill	<i>clist</i> , closed
<i>bursa</i> , pouch	<i>cloaca</i> , sewer
<i>caduci</i> , temporary, disappearing	<i>coccy</i> (<i>x-g</i>), cuckoo
<i>caec</i> , blind	<i>cochl</i> , shell
<i>calam</i> , a reed, a pen	<i>coel</i> , hollow
<i>callos</i> , callous	<i>col</i> (<i>on</i>), large intestine
<i>camp</i> , field	<i>coll</i> , neck
<i>campanula</i> , bell	<i>collat</i> , borne together
<i>cap</i> , <i>capit</i> , head	<i>columella</i> , little column
<i>capill</i> , hair	<i>com</i> , together
<i>card</i> , heart	<i>commis</i> , sent out
<i>carin</i> , keel	<i>con</i> , together, with
<i>carn</i> , flesh	<i>conch</i> , shell
<i>carotid</i> , producing stupor (because compression of this artery was supposed to cause stupor)	<i>condyl</i> , knuckle
<i>carp</i> , wrist	<i>conus</i> , cone
<i>cary</i> , nut	<i>copro</i> , dung
<i>cauda</i> , tail	<i>cora</i> (<i>x-c</i>), raven
<i>cav</i> , hollow	<i>corb</i> , basket
<i>ceph</i> , head	<i>cord</i> , heart
<i>cera</i> , <i>cerat</i> , horn	<i>corium</i> , leather
<i>cerc</i> , horns, lobes, short tail	<i>corn</i> , horn
<i>cerv</i> , neck	<i>coron</i> , crown
<i>cheir</i> , hand	<i>corp</i> , body
<i>chelon</i> , turtle	<i>cort</i> , bark
<i>chely</i> , turtle	<i>cost</i> , rib
<i>chiasm</i> , crossing of lines	<i>cotyl</i> , cup
<i>chil</i> , lip	<i>crani</i> , skull
<i>chir</i> , hand	<i>crass</i> , thick
<i>chlamy</i> , an outer garment	<i>cremaster</i> , suspender
<i>choan</i> , funnel	<i>crep</i> , shoe, slipper
<i>choledoch</i> , bile carrying	<i>cribi</i> , sieve
<i>chondr</i> , cartilage (originally lump)	<i>cric</i> , ring
<i>chord</i> , cord	<i>crist</i> , crest
<i>chorion</i> , membrane	<i>crosso</i> , tassel, fringe
<i>chrom</i> , color	<i>crura</i> , <i>crus</i> , shank or shin
<i>chrys</i> , golden	<i>crypt</i> , hidden
<i>chyl</i> , fluid	<i>cten</i> , comb
<i>chym</i> , juice	<i>cune</i> , wedge
<i>cili</i> , eyelash	<i>cusp</i> , lance, point
<i>ciner</i> , ashy, gray	<i>cuti</i> , skin
<i>capit</i> , head	<i>cycl</i> , circular
<i>cirr</i> (<i>us</i>), tentacle (originally a curl)	<i>cyn</i> , dog
<i>clad</i> , branch	<i>cyst</i> , capsule or case
<i>clast</i> , broken	<i>cyt</i> , cell
	<i>dactyl</i> , finger
	<i>dasy</i> , thick, hairy dense, raw, crude, naked

de (*al, um*), a division of anything
deca, ten
decid, dropping, falling off
decuss, cross banding
dele, visible
delph, womb
demi, half
den (*s, t*), tooth
dendr, tree, bush
derm, skin
dero, long persisting
desmo, band
deut, second
di, dia, two, twice, double
dia, through, apart
didym, twin
digit, finger (or toe)
dino, terrible
diphy, double, grown together
diplo, double
dis, two, twice, double
divert, turn aside; *diverticulum*, a small side sac or pouch
don (*t*), tooth
dors, back
drom, quick running
duo, two, twice
duoden, twelve (this part of the intestine is about twelve inches long)
dura, hard, tough

echin, spiny
ect, outer, outside
effer, carrying away
ejacul, throwing out
elasmo, plate, flat
embio, living
embol, thrown in, inserted
end, inner
engy, narrow
ensi, sword
enter, inside, especially digestive tract
ependyma, upper or outer garment
epi, upon
equina, pertaining to horse
erythr, red
ethm, sieve
eu, well, very, exceedingly
eury, wide, broad
ex, outside, from, without
extens, drawing out
extern, outside

extra, beyond, additional, more
extrins, coming from outside

fabella, little bean
falc (*falx*), sickle
fasc (*ia, ic*), band, bundle
fauces, the upper throat
fer, to carry or bear
femur (*or*), thigh
fenestr, window
fibula, breast- or safety-pin
fil, thread
fibria, fringe
fistula, tube
flex, to bend
flocculus, lock of wool
fontan, spring, fountain
foramen, opening, usually small
fornix, vault, dome
fovea, shallow round depression
fund, to pour
furcul, fork

gaster (*tr*), stomach
gano, shining, splendor
gangli, knot in string
gallus, cock
gale, weasel
gemin, twins
genu (*ic*), knee, bent
gerro, shield
gladi, sword
glen, socket
glia, glue
glom (*us, er*), ball of yarn
gloss, tongue
glotti, tongue; as a part making a noise transferred to opening to trachea

gluta, rump
glyph, carved, engraved
gnath, jaw
gon, begetting, seed, sperm, reproductive organ
goni, angle
gubernac, that which governs
gymn, naked
gyn, woman
gyr, turning convolution

haem, blood
haben, restraining band
hamat, hook
hallu (*x, y*), great toe

- haplo*, simple
helminih, worm
helo, wart-like outgrowth
hemi, half
hepar (hepat), liver
hept, seven
hetero, different
hex, six
hibern, winter
hilum, eye of bean
hippo, horse
hippocampus, fabulous sea beast
holo, entire, complete, standing alone
hom, man or similar
homal, flat
hormon, that which excites
hyal, glass-like
hydr, water
kyo U-shaped
hyper, over, above
hypo, lower, beneath
- ichthy*, fish
ileum, twisted
iliac, flank
impar, unpaired, unequal
incis, cutting in
ida, like
incu (s, udi), anvil
ingluvies, crop
inguin, groin
innominate, without a name
inter, between
intima, innermost
intra, inside
iola, (*suffix*), diminutive
intrins, contained within
iri (s, id), Goddess of the rainbow
ischia, hip
iso, equal
iter, passage
- labi*, lips
labyrinth, tortuous passage
lacer, torn
lacrim, tears
lact, milk
lacuna, space, void
lagena, flask
lamella, leaf, layer
lemm, skin, husk
lens, lentil, bean
- lepi*, scale
lepto, slender
leuc, white
levator, lifter
lingua, tongue
lith, stone
log, discourse
loph, bunch, bundle
lumen, cavity
luna, moon
lutea, yellow
lymph, clear water
lyssa, rabies, a vesicle supposed to form beneath the tongue in hydrophobia
- macro*, great, large
macula, spot
magn, large
major, larger
mala, cheek
malleus, hammer, mallet
mamma, breast
mandib, lower jaw
manu, hand
marsupi, pouch, purse
masseter, a chewer
mast, nipple
mat (e) r, mother
maxill, jaw
maxim, greatest
meatus, passage
med, middle
medull, marrow
mela, black
menin (x, g), membrane
meno, moon
mer (os), part
mesarai, middle-thin
mesenter (supporting) the mid intestine
meso, middle
meta, after
min (or, us), smaller
minim, least
mirabile, wonderful
miss (o, u), sent
miu(e)r, turban, bishop's mitre
mixi, mingle
mola, mill
moll, soft
monil, string of beads
monimo, fixed
mono, single

morph, form
motor, that which moves
multi, many
myel, marrow
mylo, mill
myo, muscle, or to close
mys, muscle, sucker
myx, mucous
myz, sucker

nar, nose
nas, nose
necro, dead body
nect, swimming
neo, new, recent
neph, kidney
neur, nerve
nictitat, winking
non, not
noth, spurious
noto, back
nuch, neck, back of neck
nucle, little nut

obtect, concealed
obturat, closed
occip, back part of head
oct, eight
odac (odax), biting
oid, like
odont, tooth
oesoph, gullet
olecran, skull of elbow
olfaci, smelling
oliva, olive
omasu, paunch
oment, fat skin
omm, eye
omo, shoulder
omphalo, navel
onto, being
oo (o), egg
ophi, snake
ophthalm, eye
opercul, little cover
opoter, either
ops, vision, eye
opt, vision, eye
orbi, circle
orch, testicle
or (al, is), mouth
ornith, bird

os, mouth
oss, bone
ossicul, little bone
ost, bone
osti, mouth
ostrac, shell
ortho, straight
ot (i, o), ear
ov (ar, um), egg

palæ, ancient
palli, mantle
pannicul, little cloth
para, beside, near
parie, wall
parot, beside the ear
patella, small dish
paro, small
pecten (pectin), comb
pect (us, or), breast
ped, foot
peduncul, little foot
pellucid, shining through
pene, almost
pente, five
peri, around
perine, region around anus
perenni, through the year, permanent
petr, rock
phaeo, dark, dusky
phalan (g, x), close formation of fighting men

pher, bear, carry
phil, loving
phor, to bear or carry
phot, light
phragm, fence, partition
phren, diaphragm, mind
phyl, tribe
phyll, leaf
phyo, to produce
physa, bladder
physio, nature
phyto, plant
pia, pious
pil, hair
pineæ, pine cone
pinna, feather
pis (i, u), sea
pituit, secretion of mucus
plac, tablet
plagio, oblique

plan, flat, plane, smooth
plant (*ar, i*), sole of foot
plasm, forming, formed
platy, flat, broad
plec (*o, t*), twist, pluck
plesio, near
pleth, full, crowded
pleur, side
plex, interwoven
plica, fold
ploi, fitted for sailing
plum (*a*), feather
pneu (*mo, st*), air, breathing, hence lung
pno (*i*), air, breathing
pod, foot
poly, many
poll (*ex, ic*), thumb
pons, bridge
poplit (*ea*), hock
porta, gate
post, behind, after
pre, before
prim, first
pro, in front, toward, instead of
process, to project from
proct, anus
profund, deep
proliger, bearing offspring
pros, forward
prostate, in first rank
proto, first
psalter, book of psalms
pseud, false
pter, wing, feather, fin
ptyal, spittle
pubi (*c, s*), grown up, sexually mature
pulmo, lung
pyg, rump
pyl, gate
pyo, pus
pyr, pear

quad, four
quadrigemin, quadruplets
quat, four
quint, five

rach, spine
radi, root
ram (*i, u*), branch
raph, seam
rect, straight, right

ren, kidney
rept, creeping
retic, network
retina, little net
retro, back, backward, behind
revehentes, carrying back
rhabd, rod
rhage, tear, rent
rhach, spine
rhin, nose
rhiz, root
rhynch, snout
rode, gnaw
rota, turn, wheel
rostrum, beak, prow
rumen, throat

saccul, little sac
sacr (*al, um*) sacred
sarc, flesh
saur, lizard
scala, ladder, stairway
scalene, uneven
scaph, anything hollow, bowl, ship
scapula, shoulder blade
schizo, cleft, split
sciat, hip
scler, hard
scop, shadow, broom, small owl, one who sees
scut, shield
scyph, cup
seba, tallow, wax
sect, cutting
selen, moon
sella, seat, saddle
semi, half, part
sept, seven, wall^b
ser (*o, u*), any fluid formed in the body
serra, saw
sex, six
sinus, hollow, bay
sipho, tube
skler, hard
sol, sun
soma, body
sperm, seed, semen
sphen, wedge
sphinct, closing
splanchn, viscera
splen, bandage, spleen
spondyl, vertebra

squam, scale
stalsis, constriction
stapes, stirrup
stat, standing
steg, covering
stell, star
sten, narrow
stereo, solid
stern, breastbone
stom, mouth
strat, spread, layer
strept, turned, twisted
striat, marked with furrows
stroph, turning
styli, column
sub, under, below
sulc, furrow
sup (e) r, above
sutur, seam
syn, together
syrin (g, x), pipe

tact, touch
tænia, band or ribbon
talus, ankle
tapetum, carpet
tars (us, al), ankle
tect, covered
tegmen, covering
tela, web
teleo, complete, perfect
tele, far, end
temno, cut
tenacul, holding
tenor, spread like a tent
teres, round, cylindrical
terti, third
tetra, four
thalam, chamber, bed
theca, case
thel, teat, nipple
thely, female
thero, beast, mammal
thym, thyme
thyreo, large shield
tom, cut, section
torpe, numb
trab, beam
trabecul, little beam
trachy, rough
trapez, four sided, table

trema, hole
tri, three, thrice
trich, hair
troch, wheel, pulley
trochanter, a runner
troph, food
troph, turning
tunic, body garment
turb, a thing which spins, a top
turcic, Turkish
tympan, drum

ulo, woolly
ulna, elbow
ultra, beyond
umbilic, navel
unc, hook
ungui, nail, claw
ungul, hoof, claw, talon
uni, one, single
ure, urine
uro, urine, tail
utricl, little skin bag
uv (e) a, grapes

vagina, sheath
vagus, wandering
vas, vessel
vascul, little vessel
vent (e) r, belly
ven, vein
vel (a, um), veil
verm, worm
vesic, blister, bladder
vill, shaggy hair; later, velvet
visc (viscus, viscera), organs of body cavity
vita, life
vitell, yolk
vitr, glassy
vomer, ploughshare
vora, devour

zen, stranger, different
zephy, sword

ypsil, U or Y shaped

zon, girdle
zo (a, o), animal
zyg, yoke

INDEX

A

Abdominal aorta, 303
 pores, 19
 ribs, 46
 veins, 291, 313
 vertebræ, 55
 Abomasum, 242
 Accessory nerve, 192
 respiratory structures, 285
 Acetabular bone, 121, 122
 Acetabulum, 113, 118
 Acinous glands, 23
 Acrodont, 96
 Acromion process, 118
 Actinotrichia, 112
 Activators, 285, 356
 Acustico-lateralis nerves, 181
 Acoustic nerve, 189
 Adductor muscles, 137, 138
 Adipose tissue, 26
 Adrenal organs, 354
 Advehent veins, 315
 Adventitia of blood-vessels, 288
 Ægithognathous, 107
 Afferent branchial artery, 300
 Afferent nerves, 174
 Air bladder, 266
 ducts, 270
 pipes, 279
 sacs, 279, 281
 Ala orbitalis, 107
 temporalis, 68, 107
 Alimentary canal, 220
 development, 13
 Alisphenoid, 74
 cartilage, 68
 Allantoic bladder, 346
 circulation, 304, 310, 316
 Allantois, 285, 382
 Alveolar duct, 275
 Alveoli of lungs, 275
 of teeth, 228
 Amnion, 380
 Amniota, 6

Amphiarthrosis, 42
 Amphibia, 5
 brain, 167
 circulation, 318
 dermal skeleton, 45
 gill-clefts, 253, 257
 gills, 257
 girdles, 115, 169
 intestine, 245
 larynx, 270
 legs, 127
 lungs, 277
 lymph system, 331
 ribs, 62, 64
 skin, 33
 skulls, 89
 sternum, 64
 stomach, 240
 thymus, 262
 thyreoid, 265
 tongue, 232
 trachea, 273
 urogenital organs, 363
 vertebræ, 53, 58
 Amphicœlous, 49
 Amphioxus, 2
 Amphiplatyan, 50
 Ampullæ of ear, 199
 of Lorenzini, 197
 of Savi, 197
 Anal fins, 111
 Anamnia, 5
 Angulare, 79
 Ankle, 125
 Ankylosis, 42
 Anlage, viii
 Annulus, 126
 Antearticular bone, 79
 Antebrachium, 125
 Anterior cardinal vein, 310
 commissure, 159
 fissure, 145
 process, 82
 Antlers, 82
 Antrum, 82
 Of Highmore, 212

- Anura**, 6
Aorta, dorsal, 290
 ventral, 290, 298
Aortic arches, 290, 298
Aponeuroses, 134
Appendages, free, 123
 paired, 112
Appendicular skeleton, 110
Appendix vermiformis, 248
Apteria, 35
Aqueduct, 150
Aqueous humor, 218
Arachnoid membrane, 163
Arbor vitæ; 173
Arcades of skull, 77
Archenteron, 10
Archicoele, 9
Archinephric duct, 339
Arch of aorta, 303
Archipallium, 160
Archipterygium, 124
Areolar tissue, 27
Argenteal layer, 217
Arm, 125
Arteries, 287, 298
Arterial ring, 305
 trunk, 290
Arthrodira, 7
Articular process, 49
 bone, 78
Articulations of skeleton, 42
Arytenoid cartilage, 270
Ascending aorta, 303
 tracts, 146
Astrospondylous, 58
Astragalus, 126
Atlas, 56
Atrial chamber of gills, 256
Atrio-ventricular canal, 295
Atrium of heart, 290, 295
 of lungs, 279
 of nose, 209
Auditory bulla, 109
 meatus, 203
 nerve, 189
 organs, 197
 tube, 202
 vesicle, 197
Auricle, 295
Auricular muscles, 139
 nerve, 190, 191
Autostylic jaws, 79
Aves, 6
Axial skeleton, 48
Axillary artery, 306
 vein, 314
Axis, 56
 cylinder, 24
Axon, 24
Azygos appendages, 111
 vein, 327
- B**
- Backbone**, 48
Balanoglossus, 2
Baleen, 232
Barbs, 35
Barbules, 35
Basal bone, 92
 membrane, 214
Basalia, 112
Basibranchial, 72
Basilar artery, 305
 plate, 68
 process, 108
Basioccipital, 74
Basisphenoid, 74
Basitemporal plate, 105
Bell's law, 174
Bicuspid, 229
Bile, 248
 duct, 248
Birds, brains, 170
 circulation, 323
 gill-clefts, 253
 girdles, 117, 122
 intestine, 246
 limbs, 128
 lungs, 279
 lymph system, 332
 skin, 34
 skulls, 103
 sternum, 66
 stomach, 240
 thymus, 263
 thyreoid, 266
 tongue, 233
 trachea, 274
 urogenital organs, 365
 vertebræ, 59
Bladder, air, 266
 urinary, 345, 371
Blastomeres, 9

- Blastopore, 10
 Blastula, 9
 Blood, 28, 286
 corpuscles, 286
 Blood-vascular system, 287
 Body cavity, 11, 17, 18
 Bone, 27
 cartilage, 47
 membrane, 47
 sesamoid, 134
 Botall's duct, 302
 Bowman's capsule, 336
 gland, 212
 Brachial artery, 306
 plexus, 175
 vein, 314
 Brachiocephalic artery, 323
 Brachium, 125
 conjunctivum, 153
 pontis, 153
 Brain, 147
 flexures of, 151
 lobes of, 159
 stem, 152
 ventricles of, 150
 zones of, 148
 Branchiæ, 252
 Branchial arches, 69, 72
 basket, 84
 clefts, 252
 duct, 255
 heart, 296
 rays, 85
 vein, 300
 Branchio-intestinal nerve, 190
 Branchiomerism, 253
 Branchiostegal membrane, 85, 256, 257
 rays, 85, 256
 Breastbone, 63
 Breathing valves, 259
 Broad ligament, 373
 Bronchi, 270, 275
 Bronchiole, 275
 Bronchus of cyclostomes, 255
 Buccal gland, 237
 nerve, 189
 Bulbus arteriosus, 296
 oculi, 218
 Bursa entiana, 242
 Fabricii, 246
 inguinalis, 373
 omentalis, 18
- C
- Cæca, 243
 Cæcilians, 6
 Calcaneus, 126
 Campanula Halleri, 219
 Canine teeth, 228
 Capillaries, 287
 Carapace, 45
 Cardiac glands, 240
 ganglion, 177
 Carnivores, 7
 Carotid arteries, 291, 300
 glands, 264, 320
 Carpale, 126
 Carpus, 125
 Cartilage, 27
 bone, 47, 73
 bones of skull, 74
 skeleton, 47
 skull, 67
 Cauda equina, 147
 Caudal artery, 305
 fins, 111
 vein, 291, 308
 vertebræ, 55
 Cavum tympani, 202
 Cement of tooth, 226
 Centrale, 126
 Central nervous system, 143
 Cephalic duct, 328
 vein, 314
 Ceratobranchial, 72
 Ceratohyal, 73
 Cerebellar hemispheres, 153
 Cerebellum, 149, 153
 peduncles of, 152
 Cerebral fissures, 158
 hemispheres, 148
 peduncle, 149, 152
 Cerebrospinal fluid, 163
 Cerebrum, 148
 Cetacea, 7
 Cervical ganglion, 178
 plexus, 175
 sinus, 262
 vertebræ, 55
 Cervico-brachial plexus, 175
 Chain ganglia, 177
 Chambers of eye, 218
 Chelonia, 7
 Chiasma, 184

- Chiroptera, 7
 Chiropterygia, 123, 125
 Choana, 208
 Choedochal duct, 248, 249
 Chondrocranium, 67
 ossification of, 73
 Chorda tendiniæ, 296
 tympani, 188
 Chordata, 2
 Chorioid coat of eye, 216
 fissure, 214
 gland, 217
 plexus, 151
 Chorion, 380
 frondosum, 385
 Chromaffine cells, 178
 Chromophile cells, 355
 Chromatophores, 30
 Chyle, 330
 Ciliary ganglion, 184, 186
 muscles, 217
 process, 217
 Circle of Willis, 305
 Circulation, foetal, 315
 on yolk, 309
 Circulatory organs, 285
 Cistern of chyle, 329
 Claspers, 31, 124, 359
 Clavicles, 115
 Claws, 30
 Cleavage of egg, 9
 Cleft palate, 208
 Cleithrum, 115
 Clitoris, 368
 Cloaca, 244
 Cloacal glands, 369
 Coccyx, 58
 Cochlea, 201
 Cochlear duct, 201
 nerve, 189
 Coeliac artery, 303
 axis, 302
 Coelom, 11
 Coelomic cavities, 16
 Collecting tubule, 336
 Collector nerves, 176
 Columella, 81
 Columnæ carnea, 296
 Columns of cord, 145, 146
 Colon, 244
 Commissure, Jacobson's, 178
 Commissures, 154
 Conarium, 171
 Conchæ of nose, 208
 Conch of ear, 203
 Cone-cells, 214
 Cones of eye, 214
 Conjunctiva, 217
 Conus arteriosus, 296
 Convoluted tubules, 336
 Coprolites, 245
 Copulæ, 66, 72
 Copulatory organs, 353
 Coraco-arcual muscles, 138
 Coracoid, 114
 process, 118
 Corium, 29
 Cornea, 217
 Cornual cartilage, 84
 Cornua of spinal cord, 145
 trabeculæ, 68
 Corona radiata, 171
 Coronary artery, 298
 vein, 327
 Coronoid bone, 79
 Corpora bigemina, 149
 quadrigemina, 149, 153
 Corpus adiposum, 334
 callosum, 159
 luteum, 348
 mamillare, 160
 restiforme, 152
 striatum, 148
 Corpusculum bulboideum, 194
 Costa, 60
 Corti, organ of, 201
 Cotyledons of placenta, 384
 Cotyloid bone, 122
 Cowper's gland, 376
 Cranial nerves, 179
 rib, 89
 Cranium, 67
 platybasic, 68
 tropibasic, 68
 Cremaster muscle, 373
 Cribiform plate, 75, 109
 Cricoid cartilage, 270
 Cristæ acusticæ, 200
 Crista galli, 109
 Crop, 238
 Crura cerebri, 149, 152
 Crus, 125
 Ctenoid scales, 44
 Cuboides, 126

Cuneiform, 126
 Cutaneous artery, 307
 magnus, vein, 314
 nerves, 181
 Cutis, 29
 Cuvierian ducts, 18, 294, 310
 Cycloid scales, 44
 Cyclospondylous, 58
 Cyclostomata, 4
 Cyclostomes, brain, 163
 circulation, 316
 ears, 199
 gill-clefts, 253, 254
 mouth, 223
 olfactory organs, 205
 salivary gland, 235
 skull, 82
 teeth, 231
 thymus, 262
 urogenital organs, 356
 vertebræ, 57
 Cylindrical corpuscle, 194
 Cystic duct, 249

D

Decidua, 385
 Deciduata, 384
 Deiter's cells, 201
 Demibranch, 253
 Dendrites, 24
 Dens, 56
 Dental formula, 229
 papilla, 224
 ridge, 225
 shelf, 225
 Dentary bone, 79
 Dentate nucleus, 153
 Dentine, 28, 43, 224
 Dentitions, 226
 Depressor mandibulæ, 138
 muscles, 134, 136
 Derma, 29
 Dermal bones, 73
 ethmoid bone, 89
 muscles, 139
 skeleton, 42, 43
 Dermarticular, 79
 Descending aorta, 303
 tracts, 146
 Desmognathous, 107
 Deutoplasm, 9

Diaphragm, 18, 140, 284
 Diapophysis, 49
 Diarthrosis, 42
 Diastole, 295
 Diencephalon, 149, 154
 Digastric muscle, 138
 Digestive organs, 220
 tract, development, 13
 muscles of, 130
 Digitigrade, 129
 Digits, 125
 Dilator muscles, 134
 pupillæ, 217
 Dinosaurs, 6
 Dipnoi, 5
 Diphyccercal, 56
 Diplospandyly, 53
 Dorsal aorta, 290, 302
 cartilage, 83
 fins, 111
 septum, 145
 Dromaognathous, 106
 Ductless glands, 23
 Ductus Arantii, 309
 arteriosus, 302
 Botalli, 302
 Cuvierii, 18, 294, 310
 venosus, 309
 Dumb-bell bone, 77, 110
 Duodeno-hepatic omentum, 18
 Duodenum, 242
 Dura mater, 163
 spinalis, 163

E

Ear bones, 80, 203
 stones, 200
 Ears, 197
 Ect-ental line, 10
 Ectethmoid, 75
 Ectochondrostosis, 47
 Ectoderm, 10
 Ectopterygoid, 87, 95
 Ecto-turbinals, 211
 Edentata, 7
 Efferent branchial artery, 300
 Efferent nerves, 174
 Egg, 9
 teeth, 232
 Ejaculatory duct, 376
 Elasmobranchii, 5

- Electrical organs, 140
 Electroplax, 141
 Elevator muscles, 134
 Embryo, circulation, 315
 nutrition of, 378
 respiration, 379
 Embryonic tissue, 26
 Enamel, 44, 224
 organ, 43, 224
 Endocardium, 292
 Endolymph, 200
 duct, 197
 End organs, 193
 Endorhachis, 162
 Endoskeleton, 47
 Ensiform process, 63
 Entepicondylar foramen, 129
 Enterocoele, 11
 Enteropneusta, 2
 Entochondrostosis, 47
 Entoderm, 10
 Entoglossal bone, 87, 106
 Entoplastron, 46
 Entopterygoid, 87
 Entoturbinals, 211
 Entovarial canal, 353
 Epaxial muscles, 132
 Ependyma, 145
 Epibranchial, 72
 ganglion, 190
 muscles, 138
 Epicardium, 19, 292
 Epicoele, 150
 Epicoracoid, 116
 Epidermal teeth, 231
 Epidermis, 29
 Epididymis, 349
 Epigastric artery, 306
 vein, 313
 Epihyal, 73
 Epimere, 14
 Epineurals, 61
 Epiotic bone, 75
 Epipharyngeal bones, 88
 Epiphyses, 47, 149
 Epiplastron, 46, 117
 Epipleurals, 61
 Epipterygoid bone, 89, 96
 Epipubic process, 119
 Episternum, 66
 Epistropheus, 56
 Epithalamus, 149, 154
 Epithelial bodies, 264
 Epitheliomorph layer, 51
 Epithelium, 21
 Epitrichium, 29
 Erythrocytes, 286
 Ethmoidalia, 74
 Ethmoid bone, 76
 plate, 68
 Ethmoturbinals, 211
 Eustachian tube, 202, 253
 Excretory organs, 334
 tubules, 335
 Exoccipital, 74
 Extensor muscles, 134, 137
 External mandibular nerve, 189
 Extrabranchnial cartilages, 73
 Extrinsic muscles, 136
 Eyes, 213
 Eyelids, 218
 Eye muscles, 133
 Eye-muscle nerves, 184
- F
- Fabellæ, 127
 Facial nerve, 188
 Falciform process, 219
 Fallopian tube, 374
 False amnion, 380
 ribs, 63
 Falx cerebri, 163
 Fascia, 134
 Fasciculi, 134
 Fat, 26
 body, 334
 Feathers, 34
 Feather tracts, 35
 Femoral artery, 306
 pores, 34
 vein, 314
 Femur, 125
 Fenestra hypophyseos, 68
 ischio-pubic, 118
 ovale, 81, 201
 rotunda, 201
 tympani, 201
 vestibuli, 81, 201
 Fibrin, 286
 Fibrous tissue, 26
 Fibula, 125
 Fifth ventricle, 160
 Filoplumes, 35

- Filum terminale**, 147
Fins, 111, 124
Fishes, appendages, 124
 brain, 164
 circulation, 317
 dermal skeleton, 44
 gill-clefts, 253, 254
 girdles, 114, 118
 intestine, 244
 lymph system, 331
 ribs, 61
 scales, 44
 skin, 31
 skull, 84
 stomach, 240
 thymus, 262
 thyroid, 265
 tongue, 232
 urogenital organs, 359
 vertebræ, 57
Fissure, cerebral, 158
 of Sylvius, 158, 170
 petrotympanic, 82
Fissures of cord, 145
Flexor muscles, 134, 137
Flexures of brain, 151
Flocculus, 153
Floor plate, 144
Fœtal circulation, 315
 envelopes, 379
Folian process, 82
Fontanelles, 69
Food yolk, 9
Fore brain, 148
Foramen cæcum, 234, 266
 entepicondylar, 129
 epiploicum, 18
 incisivum, 109
 interventricular, 150
 lacerum anterior, 74
 magnum, 74
 of Monro, 150
 of Winslow, 18
 obturator, 118
 Panizza, 297, 323
 parietal, 76
 supracondylar, 129
Fornix, 160
Fossa hypophyseos, 68
 rhomboidalia, 151
Fossæ of skull, 77
Fovea centralis, 215
Free nerve ends, 193
Frontal bones, 76
 lobe, 159
 sinus, 212
Frontalis muscle, 139
Fundus glands, 240
Funiculi of cord, 146
Furcula, 117

G

Gall, 248
 bladder, 249
 capillaries, 248
Ganglion cells, 23
Ganoidea, 5
Ganoid scales, 44
Gasserian ganglion, 186
Gastralia, 45, 46
Gastric glands, 240
 artery, 303
Gastrohepatic omentum, 17
Gastrosplenic omentum, 18
Gastrula, 10
Gastrulation, 10
General cutaneous nerves, 181
Geniculate ganglion, 188
Geniohyoid muscle, 135
Genital artery, 307
 fold, 378
 prominence, 368
 ridge, 346, 378
Germ layers, 11
Gill arches, 69
 clefts, 252
 cover, 256
 remnants, 264
Gills, 252
Girdles, 113
Gizzard, 240
Gladius, 63
Glands, 23
 internal secretion, 178
Glans penis, 378
Glenoid fossa, 109, 113
Glia, 145
 cells, 23, 75
Glomeruli of olfactory nerve, 183, 205
Glomerulus of kidney, 336
Glomus, 339
Glossopharyngeal nerve, 189
Glottis, 270

- Gluteus muscle, 137
 Gnathostomata, 4
 Gonads, 335
 Goniale, 79
 Gonotome, 347
 Graafian follicle, 348
 Grandry's corpuscle, 194
 Gray matter, 25, 145;
 ramus, 178
 Gubernaculum, 373
 Gular bones, 86
 Gymnophiona, 6
 Gyri of brain, 159
- H
- Habenula, 154
 Habenular commissure, 154
 Hæmal arch, 49
 spine, 49
 Hæmapophyses, 49
 Hæmoglobin, 286
 Hæmolymph glands, 334
 Hæmopophysial rib, 60
 Hagfish, 4
 Hair, 37
 cells, 201
 Hallux, 126
 Hamatum, 126
 Hand, 125
 Harder's glands, 219
 Hare lip, 208
 Haversian canals, 27
 Head cavities, 133
 kidney, 337
 Heart, 292
 muscle, 26
 Hemiazygos vein, 327
 Hemipenes, 367
 Hemispheres of brain, 148, 153
 Henle's loop, 336
 Hepar, 248
 Hepatic artery, 303
 duct, 248, 249
 portal system, 309
 sinus, 317
 vein, 309
 Herbst's corpuscle, 194
 Hermaphroditism, 354
 Heterocercal, 56
 Hibernating glands, 334
 Hilum of kidney, 370
 Hind-brain, 148
 Hippocampal commissure, 159
 tract, 171
 Hippocampus, 160
 Histology, 21
 Holocephali, 5
 Holonephros, 337
 Holorrhinal, 105
 Homocercal, 57
 Hoofs, 31
 Hormones, 23, 356
 Horns, 109
 Humerus, 125
 Hyaloid artery, 216
 Hyoid arch, 69, 71, 233, 235
 nerve, 188
 Hyomandibular cartilage, 72
 bone, 79
 Hyoplastron, 46
 Hyostylic jaws, 79
 Hypaxial muscles, 132
 Hypoartia, 4
 Hyperotretia, 4
 Hypobranchial, 72
 Hypocentrum, 53
 Hypogastric artery, 291, 303
 ganglion, 177
 Hypoglossal muscles, 133
 nerve, 192
 Hypohyal, 73
 Hypoischium, 120
 Hypomere, 14
 Hypopharyngeal bones, 87
 Hypophysial duct, 221
 Hypophysis, 157
 Hypoplastron, 46
 Hypothalamus, 149
 Hypurals, 57
- I
- Ichthyopsida, 5
 Ichthyopterygia, 123
 Ichthyosaurs, 6
 Ileo-colic valve, 243
 -costalis muscle, 136
 Ileum, 244
 Iliac artery, 291, 306
 vein, 291, 312
 Iliocæcal valve, 243
 Ilium, 118
 Incisive foramen, 109

Incisors, 228
 Incus, 82
 Index, 126
 Inferior jugular vein, 310
 oblique muscle, 133
 turbinal, 109
 vena cava, 314
 Infraclavicle, 115
 Infracrostral cartilage, 92
 Infratemporal fossa, 77
 Infundibulum of brain, 149
 of lungs, 275
 Ingluvies, 238
 Innominate vein, 327
 Insectivores, 7
 Insertion of muscles, 134
 Instep, 125
 Insula, 158
 Integument, 29
 Interbasal muscles, 138
 Interbranchial septum, 253
 Intercalaria, 55
 Intercentrum, 53
 Interclavicle, 66
 Intercostal arteries, 291, 305
 muscles, 135
 Interhyal bone, 87
 Intermaxillary gland, 236
 Intermedium, 126
 Internal carotid, 291
 naris, 208
 Internasal gland, 236
 Interoperculum, 85
 Interorbital septum, 68
 Interparietal bone, 76
 Interrenal organs, 354
 veins, 315
 Interstitial cells of testis, 376
 Intertemporal bone, 76
 bones, 108
 Intertrabecula, 104
 Interventricular foramina, 150
 Intestine, 242
 Intestinal nerve, 190
 Intima of blood-vessels, 288
 Intratarsal joint, 127
 Intrinsic muscles, 136
 Invagination, 10
 Inverted eye, 215
 Involuntary muscle, 25
 Iris, 217
 Ischiadic artery, 306

Ischiadic vein, 314
 Ischio-pubic fenestra, 118
 Ischio-pubis, 121
 Ischium, 118
 Island of Riel, 158, 170
 Isthmus, 149
 of fauces, 266
 of gill region, 256
 Iter, 150

J

Jacobson, organ of, 205, 212
 Jacobson's commissure, 178
 glands, 208
 Jaws, suspension of, 79
 Jejunum, 244
 Jugal bone, 77
 Jugular ganglion, 190
 vein, 291, 311

K

Kidneys, 335, 337, 344, 369
 Krausse's corpuscle, 194

L

Labial cartilages, 73
 glands, 236
 Labyrinth of ear, 199, 200
 Labyrinth of gills, 259
 Lacrimal bone, 76
 ducts, 219
 glands, 219
 Lacteals, 330
 Lagena, 199
 Lamina terminalis, 148
 Lampreys, 4
 Lanugo, 37
 Laryngeal nerves, 191
 Larynx, 270
 Lateral abdominal vein, 313
 ethmoid, 76
 line, 197
 line organs, 194
 plate zone, 14
 Lateralis ganglion, 190
 nerves, 181, 188, 190
 Latissimus dorsi, 137
 Legs, 125
 Lens, 217

Leptocardii, 2
 Leucocytes, 287
 Levator muscles, 136
 scapulæ, 137
 Leydig's duct, 343
 Ligaments of ovary, 373
 Ligamentum medium pelvis, 120
 teres, 313
 Limiting sulcus, 148
 Linea alba, 132
 Lingual cartilage, 84
 gland, 237
 nerve, 187, 190
 Lips, 223
 Liver, 248
 Lobes of brain, 159
 Longissimus capitis muscle, 136
 dorsi muscles, 136
 Longitudinal fissure, 148
 Lorenzini's ampullæ, 197
 Lumbar artery, 305
 plexus, 175
 vertebræ, 55
 Lumbo-sacral plexus, 175
 Luminous organs, 31
 Lunatum, 126
 Lungs, 252, 269, 275
 Lutein cells, 348
 Lymph, 286
 follicles, 333
 glands, 333
 hearts, 330
 sacs, 329
 Lymphatic system, 327
 Lymphocytes, 287
 Lyssa, 234

M

Macula lutea, 215
 Maculæ acusticæ, 200
 Malar bone, 77
 Male ducts, 349
 Malleus, 82
 Malpighian corpuscle, 336
 layer, 29
 Mammæ, 40
 Mammalia, 8
 Mammals, brain, 170
 circulation, 324
 dermal skeleton, 46
 gill-clefts, 253

Mammals, girdles, 118, 122
 intestine, 246
 larynx, 271
 limbs, 128
 lungs, 275, 283
 lymph system, 332
 oral glands, 237
 ribs, 63
 scales, 38, 47
 skin, 37
 skull, 107
 sternum, 66
 stomach, 241
 thymus, 263
 thyreoid, 266
 tongue, 234
 trachea, 275
 urogenital organs, 369
 vertebræ, 59
 Mammary glands, 40
 Mamillary bodies, 154
 Mandibular arch, 69
 artery, 294
 nerve, 187
 Mantle, 148
 Manubrium, 63
 mallei, 82
 Manus, 125
 Manyplies, 242
 Marrow cavity, 48
 Marsipobranchii, 4
 Marsupial bones, 123
 Marsupials, 7
 Marsupium, 40
 Masseter muscle, 138
 Mastoid process, 109
 Maxillary bone, 77
 nerve, 186
 sinus, 212
 Maxilloturbinals, 210
 Meatus, auditory, 203
 Meckelian cartilage, 71
 Median appendages, 111
 Mediastinum, 19
 Medulla oblongata, 149, 152
 Medullary groove, 12
 plate, 12, 143
 sheath, 24
 velum, 153
 Meibomian glands, 219
 Meissner's corpuscle, 194
 Membrana tectoria, 202

Membrane bones, 47, 73
 bones of skull, 76
 Membranocranium, 67
 Membranous skeleton, 47
 Meninges, 162
 Meninx primitiva, 162
 Mento-Meckelian bone, 78
 Merkel's corpuscle, 194
 Mesencephalon, 149, 153
 Mesenchyme, 11, 20
 Mesenteric arteries, 303
 Mesenteries, 16
 Mesenteron, 220
 Mesethmoid, 75
 Mesoarium, 347
 Mesobronchus, 279
 Mesocardia, 18, 293
 Mesocolon, 17
 Mesoderm, 10
 Mesogaster, 17
 Mesohepar, 17
 Mesomere, 14
 Mesonephric ducts, 342
 tubules, 340
 Mesonephros, 337, 340
 Mesopterygium, 124
 Mesopterygoid, 87
 Mesorchia, 18, 347
 Mesorectum, 17
 Mesothelium, 11
 Mesovaria, 18, 347
 Metacarpus, 125
 Metacoele, 16
 of brain, 151
 Metamerism, 13
 Metanephros, 337, 344, 369
 Metapodium, 125
 Metapterygium, 124
 Metapterygoid, 87
 Metatarsus, 125
 Metencephalon, 149, 153
 Mid-brain, 148, 153
 Middle plate, 14
 Milk glands, 40
 Minimus, 126
 Mitral valve, 297
 Mixipterygium, 124, 358
 Molar glands, 237
 teeth, 229
 Monimostylic, 95
 Monotremes, 7
 Monro, foramen of, 150

Monro, sulcus of, 148
 Morphology, 1
 Mossy cells, 25
 Motor nerves, 174
 Müllerian duct, 343, 351
 Multangulum, 126
 Muscle plate, 14
 Muscles, development, 131
 parietal, 131
 sphincter, 134
 types of, 130
 visceral, 138
 Musculus papillosus, 296
 Muscular system, 129
 tissue, 25
 Musk glands, 34, 368
 Myelin, 24
 Mylohyoid muscle, 138
 Myocardium, 292
 Myocoele, 14, 131
 Myocommata, 132
 Myoepicardial mantle, 293
 Myofibrillæ, 25
 Myosepta, 42, 49, 132
 Myotomes, 14, 131
 Myxinoidei, 4

N

Nails, 31
 Nares, 205
 Naro-hypophysial duct, 205
 Nasal bones, 76
 capsules, 69
 glands, 212
 Naso-hypophysial canal, 84
 Naso-pharyngeal duct, 209
 Naso-turbinals, 210
 Navel cord, 382
 Naviculare, 126
 Neopallium, 160
 Nephridia, 335
 Nephridial arteries, 307
 Nephrocœles, 16
 Nephrostomes, 16, 335, 338
 Nephrotomes, 16, 338
 Neural arch, 48
 crest, 173
 folds, 12, 143
 groove, 144
 plate, 12, 49, 143
 spine, 49

- Neurapophyses, 49
 Neurenteric canal, 12
 Neuroblasts, 145
 Neuroglia, 25, 145
 Neuromasts, 181, 195
 Neuromeres, 161
 Neurons, 23
 Neuropore, 12
 Nerve cells, 23
 centres, 152
 components, 181
 -end apparatus, 193
 hillocks, 195
 plexus, 175
 roots, 173
 Nerves, collector, 176
 cranial, 179
 motor, 174
 sensory, 174
 spinal, 174
 visceral, 175
 Nervous system, 142
 central, 143
 development, 12
 envelopes of, 162
 peripheral, 173
 sympathetic, 177
 tissue, 23
 Newts, 6
 Nictitating membrane, 218
 Nidamental organ, 358
 Nipples, 41
 Nodose ganglion, 191
 Non-deciduata, 384
 Non-elastic tissue, 26
 Nose, 204
 Notochord, 13, 51
 Notochordal sheath, 51
 Nuchal flexure, 151
 Nucleus dentatus, 153

 O

 Oblique muscles, 133, 135
 Obturator foramen, 118
 Occipital bone, 76
 lobe, 159
 muscle, 139
 nerves, 192
 vertebræ, 69
 Occipitalia, 74
 Oculomotor nerve, 184

 Odontoblasts, 28, 43, 224
 Odontoid process, 56
 Oesophageo-cutaneous duct, 255
 Oesophagus, 238
 Olecranon process, 129
 Olfactory bulb, 171, 183
 duct, 208
 lobe, 148
 nerve, 182
 organs, 204
 sac, 205
 tract, 160, 171, 183
 Omasus, 242
 Omenta, 17
 Omosternum, 65
 Omphalo-mesenteric artery, 291
 vein, 291, 294, 307
 Ontogeny, 1
 Opercular apparatus, 256
 gill, 259
 Operculare, 85
 Operculum, 85, 256
 Ophthalmic nerve, 186
 Opisthocœlous, 50
 Opisthotic, 75
 Optic cup, 213
 lobes, 149
 nerve, 184
 pedicel, 218
 recess, 148
 stalk, 213
 vesicle, 213
 Oral cavity, 223
 glands, 235
 hood, 223
 plate, 220
 Orbicularis muscles, 139
 Orbital glands, 237
 Orbitosphenoid, 74
 Organ of Corti, 201
 of Jacobson, 205, 212
 Origin of muscles, 134
 Oronasal groove, 207
 Os basale, 92
 Os cloacæ, 120
 Os en ceinture, 94
 Os entoglossum, 106, 233
 Os pubis, 118
 Os transversum, 95
 Os uncinatum, 106
 Os uteri, 375
 Ossa suprasternalia, 66

Ossicula auditus, 80
 Ossein, 27, 43
 Osseous tissue, 27
 Osteoblasts, 43
 Ostium tubæ abdominale, 351
 Ostracoderms, 7
 Otic bones, 75
 capsule, 67
 ganglion, 178, 187
 Otoliths, 200
 Ovarial cords, 347
 Ovarian artery, 307
 Ovary, 335, 347
 Oviduct, 343, 351
 Ovotestis, 354
 Ovum, 9

P

Pacini's corpuscle, 194
 Paired appendages, 112
 Palæospondylus, 7
 Palatal glands, 236
 Palatine bone, 77
 nerve, 188
 Palatoquadrate, 71
 Pallial commissure, 159
 Pallium, 148, 160
 Pancreas, 250
 Panniculus carnosus, 139
 Parabronchi, 279
 Parachordal plates, 68
 Paraflocculus, 173
 Paraglossa, 106, 233
 Paramastoid process, 108
 Parapinealis, 163
 Parapophysis, 49
 Parasphenoid bone, 77
 Paraterminal body, 159
 Parathyroids, 264
 Parietal bones, 76
 foramen, 76, 156
 lobe, 159
 muscles, 131
 organ, 149
 Paroccipital, 108
 Parotid gland, 33, 237
 Parovarial canal, 353
 Parovarium, 376
 Patella, 127, 129
 Paunch, 242
 Pearl organs, 31
 Pecten of eye, 219
 Pectineal process, 122
 Pectineus muscle, 137
 Pectoral girdle, 114
 Pectoralis muscle, 137
 Peduncles of cerebellum, 153
 of cerebrum, 152
 Pelvic ganglion, 177
 girdle, 118
 Pelvis, 118
 of kidney, 370
 Penis, 367, 378
 bone, 378
 Pepsin, 240
 Pericardial cavity, 293
 sac, 290
 Pericardio-peritoneal canals, 18, 295
 Pericardium, 18, 19, 292
 Perichondrium, 27, 42
 Periderm, 29
 Peridural space, 163
 Perilymph, 200
 duct, 201
 Perimeningeal space, 163
 Perimysium, 26, 134
 Perineum, 377
 Perineureum, 25
 Periosteum, 28, 43
 Peripheral nervous system, 173
 Peristalsis, 130, 222, 243
 Peritoneal canals, 20
 cavity, 18
 Peritoneum, 19
 Peroneal artery, 306
 Pes, 125
 Petromyzontes, 4
 Petrosal bones, 75, 109
 ganglion, 189
 Peyer's patches, 333
 Phæochrome cells, 355
 Phalanges, 125
 Pharyngeal derivatives, 262
 nerve, 190, 191
 plate, 220
 tonsils, 266
 Pharyngobranchial, 72
 Pharynx, 238, 252
 Phosphorescent organs, 31
 Photophores, 31
 Phrenic nerve, 140
 Phyllospondylous, 54
 Pia mater, 163

- Pigment cells, 26, 30
 layer, 213
 Pigmented epithelium, 216
 Pillar cells, 201
 Pinealis, 171
 Pisces, 5
 Pisiforme, 126
 Placenta, 382
 Placoid scales, 44, 224
 Plantigrade, 129
 Plasma, 28, 286
 Plastron, 45
 Platybasic cranium, 68
 Platysma myoides, 140
 Plesiosaurs, 6
 Pleura, 19, 275
 Pleural cavities, 18
 rib, 60
 Pleurodont, 96
 Plexus, 175
 Plicæ semilunaris, 218
 Plicæ fimbriatæ, 234
 Plumæ, 35
 Plumulæ, 35
 Pneumatic bones, 282
 duct, 267
 Pneumatocyst, 266
 Pneumogastric nerve, 190
 Podium, 125
 Poison fangs, 102, 228
 glands, 31, 236
 Pollex, 126
 Polymastism, 40
 Pons varolii, 153
 Popliteal artery, 306
 Pori abdominales, 19
 Portal circulation, 308
 heart, 317
 system, 309, 311
 vien, 309
 Postbranchial bodies, 264
 Postcardinal sinus, 317
 vein, 291
 Postcava, 314, 323
 Postclavicle, 115
 Posterior commissure, 154
 septum, 145
 Postfrontal bone, 76
 Postminimus, 126
 Postorbital bone, 76
 Postparietal bone, 76
 Postpubic process, 121
 Posttemporal fossa, 77
 Posttemporals, 115
 Posttrematic nerves, 182
 Precava, 323
 Predentary bone, 96
 Prefrontal bone, 76
 Prehallux, 126
 Premaxillary bone, 77
 Premolars, 229
 Prenasal bone, 109
 Preoperculum, 85
 Prepollex, 126
 Prepubis, 121
 Presphenoid, 74
 Pretrematic nerves, 182
 Prevertebral ganglia, 177
 Prevomers, 77
 Primates, 7
 Primitive groove, 10, 143
 ova, 347
 streak, 10
 Primordial ova, 347
 Proatlas, 56
 Proboscis, 212
 Procoelous, 50
 Procoracoid, 116
 Proctodeum, 13, 220
 Profundus nerve, 186
 Pronephric duct, 339
 tubules, 339
 Pronephros, 337
 Prootic, 75
 Propterygium, 124
 Prostate glands, 376
 Proterandric hermaphroditism, 354
 Protovertebræ, 15
 Protractor muscles, 136
 Proventriculus, 240
 Psalterium, 242
 Pseudobranch, 259
 Pseudoconch of nose, 210
 Pterodactyls, 6
 Pterotic, 75
 Pterygoid bone, 77, 108
 Pterygoideus muscle, 138
 Pterygopodial glands, 31
 Pterygoquadrate, 71
 Pterylæ, 35
 Ptyalin, 235
 Pubis, 118
 Pubofemoralis muscle, 137
 Pulmonary circulation, 298

Pulmonary vein, 315
 Pulmones, 252
 Pulp cavity, 225
 Pygostyle, 59
 Pyloric cæca, 242
 glands, 240
 Pylorus, 239
 Pyramidalis muscle, 135
 Pyramids, 150, 152
 Pyriformis muscle, 137

Q

Quadrate bone, 77
 Quadratojugal bone, 77

R

Radial artery, 306
 Radialia, 112, 126
 Radix aortæ, 290, 299
 Radius, 125
 Ramus dorsalis, 174
 intestinalis, 174
 ventralis, 174
 visceralis, 174
 Rathke's pocket, 221
 Rectal gland, 244
 Rectum, 244
 Rectus abdominis muscle, 135
 capitis muscles, 136
 muscles, 133, 135
 Recurrent bronchi, 282
 nerve, 188
 Renal arteries, 291, 307, 327
 corpuscle, 336
 portal system, 311
 Rennet, 242
 Reproductive ducts, 349
 organs, 346
 Reptiles, brain, 168
 circulation, 320
 dermal skeleton, 45
 gill-clefts, 253
 girdles, 116, 120
 intestine, 245
 larynx, 271
 legs, 127
 lungs, 278
 lymph system, 332
 oral glands, 236
 ribs, 62

Reptiles, scales, 45
 skin, 33
 skulls, 95
 sternum, 65
 stomach, 240
 thymus, 263
 thyreoid, 266
 tongue, 233
 trachea, 274
 urogenital organs, 365
 vertebræ, 58
 Reptilia, 6
 Respiration of embryo, 379
 Respiratory circulation, 298
 duct, 208
 organs, 251
 Rete mirabile, 268
 Retia mirabilia, 287
 Reticulum, 242
 Retina, 214
 Retinal artery, 216
 layer, 213
 vein, 216
 Retractor bulbi, 133, 218
 muscles, 136
 Retrolingual gland, 237
 Revehent veins, 315
 Rhachis, 35
 Rhachitinous, 53
 Rhinal fissure, 170
 Rhinencephalon, 148
 Rhynchocephals, 7
 Ribs, 60
 Riel, island of, 158
 Rodentia, 7
 Rods of eye, 214
 Roof plate, 144
 Rostral bone, 96
 cartilage, 84
 Rostrum sphenoidale, 105
 Rotator muscles, 137
 Rumen, 242

S

Sacculo-utricular canal, 198
 Sacculus, 198
 endolymphatic, 198
 Sacral artery, 305
 plexus, 175
 ribs, 63
 vertebræ, 55

- Sacrum, 55
 Salamanders, 6
 Salivary gland, 235
 Santorini's duct, 250
 Sarcolemma, 26
 Saurognathous, 107
 Sauropsida, 6
 Savi's ampullæ, 197
 Scalæ of ear, 199, 201
 Scalene muscles, 135
 Scales, 43
 horny, 30
 Scaphoid, 126
 Scapula, 114
 Scent glands, 34, 39
 Schizocœle, 11
 Schizognathous, 107
 Schizorhinal, 105
 Schwann's sheath, 24
 Sciatic artery, 306
 vein, 314
 Sclera, 69, 217
 Scleroblasts, 43
 Sclerotic bones, 76, 218
 coat, 69
 Sclerotomes, 16, 20, 51
 Scrotum, 348, 373
 Sebaceous glands, 39
 Seessel's pocket, 221
 Segmentation cavity, 9
 of egg, 9
 Sella turcica, 68
 Semicircular canals, 199
 Semilunar ganglion, 186
 Seminal vesicles, 376
 Seminiferous tubules, 348
 Semiplacenta, 384
 Sense hillocks, 181
 Sensory nerves, 174
 organs, 192
 Septum pellucidum, 160
 transversum, 18, 294
 Serosa, 380
 Sertoli's cells, 348
 Serratus muscle, 137
 Serum, 286
 Sesamoid bones, 134
 Sexual glands, 335
 Shagreen, 44
 Sheath of notochord, 51
 Shell gland, 358, 366
 Shoulder girdle, 114
 Sinus impar, 269
 Sinus of Morgagni, 273
 terminalis, 309
 urogenitalis, 349
 venosus, 290, 295
 Sinuses of nose, 212
 Sinusoids, 287
 Sirenia, 7
 Skeletogenous tissues, 41, 51
 Skeleton, 41
 Skin, 29
 Skull, 67
 Smell, 204
 Smooth muscle, 25
 Solar plexus, 177
 Somatic arteries, 291
 layer, 11
 nerves, 175
 Somatopleure, 16
 Spermatic artery, 307
 Spermatozoon, 9, 348
 Sphenethmoid, 93
 Sphenodon, 6
 Sphenoid bone, 76
 Sphenoidalia, 74
 Sphenoidal fissure, 74
 sinus, 212
 turbinal, 109
 Sphenopalatine ganglion, 178
 Sphenotic, 75
 Sphincter muscles, 134, 239
 pupillæ, 217
 Spina scapulæ, 118
 Spinal artery, 305
 cord, 144
 muscles, 136
 nerves, 174
 Spiracle, 254
 Spiracular gills, 259
 Spiral valve, 244
 Splanchnic layer, 11
 Splanchnocœle, 18
 Splanchnopleure, 16
 Spleen, 333
 Splenial bone, 79
 Splenic artery, 303
 Squamata, 7
 Squamosal bone, 77
 Stannius' corpuscles, 362
 Stapes, 81, 82
 Stegocephali, 6
 Stenon's duct, 237

- Stenson's gland, 212
 Sternal ribs, 61
 Sternebræ, 64
 Sternocleidomastoid muscle, 137
 Sternohyoid muscle, 135
 Sternum, 63
 Stomach, 239
 primitive, 10
 Stomodeum, 13, 220
 Stratified epithelium, 22
 Stratum corneum, 30
 germinativum, 29
 lucidum, 37
 Streptostylic, 95
 Striped muscle, 25
 Sturgeon, 5
 Styloid process, 109
 Subcardinal vein, 311
 Subclavian artery, 291, 306
 vein, 291, 312
 Subcutis, 30
 Subdural space, 163
 Sublingua, 234
 Sublingual gland, 236
 Subintestinal vein, 291, 308
 Submaxillary ganglion, 178
 gland, 237
 Suboperculum, 85
 Subspinal muscles, 138
 Subunguis, 31
 Sulci of brain, 159
 Sulcus of Monro, 148
 Superficial lateralis nerve, 191
 ophthalmic nerve, 186, 189
 Superior commissure, 154
 maxillary nerve, 186
 mesenteric artery, 303
 oblique muscle, 133
 Supraclithra, 115
 Supracondylar foramen, 129
 Supraethmoid bone, 89
 Suprangulare, 79
 Supraoccipital, 74
 Supraorbital bone, 76
 Suprapericardial bodies, 264
 Suprapharyngeal plate, 84
 Suprarenal organs, 354
 Supraorostral cartilage, 92
 Suprascapula, 114, 116
 Suprasternalia, 64, 66
 Supratemporal bone, 76
 fossa, 77
 Supratrabecula, 104
 Suspensor of jaws, 72
 Suture, 42
 Sweat glands, 39
 Sweetbreads, 263
 Swim bladder, 266
 Sylvian fissure, 158, 170
 Sympathetic system, 177
 trunk, 178
 Symphysis, 78
 Symplectic bone, 79, 87
 Synarthroses, 42
 Synostosis, 42
 Synotic tectum, 69
 Synovial cavities, 21
 membrane, 42
 Synsacrum, 59
 Systemic circulation, 298
 heart, 297
 Systole, 295
 Syrinx, 274

T

- Tabulare, 76
 Tactile corpuscle, 193
 senses, 194
 Tænia marginalis, 107
 Talus, 126
 Tapetum lucidum, 217
 Tarsal glands, 219
 Tarsale, 126
 Tarsus, 125
 Tarso-metatarsus, 128
 Taste, 204
 Tear gland, 219
 Teats, 41
 Teeth, 223
 epidermal, 231
 Tegmen cranii, 69
 Tela conjunctiva, 30
 Telæ chorioidea, 151
 Telencephalon, 148
 Teleostei, 5
 Teleostomes, 8
 Telodendra, 24
 Temnospondylous, 53
 Temporal bone, 109
 fossa, 77
 lobe, 77
 Temporalis muscle, 138
 Tenaculum, 218

- Tenderloin, 133
 Tentorium, 163
 Terminal nerve, 184
 Testis, 335, 348
 Testes, descent of, 373
 Tetrapoda, 8
 Thalamencephalon, 149
 Thalamic nerve, 184
 Thalamus, 149, 154
 Thecodont, 96
 Theromorphs, 6
 Thoracic aorta, 303
 duct, 328
 vertebræ, 55
 Thread cells, 32
 Thymus glands, 262
 Thyreohyal, 110
 Thyreoid cartilage, 271
 gland, 265
 Tibia, 125
 Tibial artery, 300
 Tibiale, 126
 Tibio-tarsus, 128
 Tissues, 21
 Tongue, 232
 Tonsils, 266, 333
 Touch organs, 194
 Trabecula communis, 68
 Trabeculæ cranii, 68
 Trachea, 270, 273
 Tracts of cord, 146
 Transverse process, 49
 Transversospinal muscles, 136
 Transversus muscle, 135
 Trapezium, 126
 Trapezius muscle, 137
 Trapezoides, 126
 Tricuspid valves, 297
 Trigeminal nerve, 186
 Triquetrum, 126
 Tropibasic cranium, 68
 Trochanters, 129
 Trochlearis nerve, 184
 Truncus arteriosus, 290, 296
 transversus, 294
 Tuber cinereum, 154
 Tuberculum impar, 233, 234
 Tubular glands, 23
 Tunica serosa, 16
 vasculosa, 216
 Tunicata, 2
 Turbinal bones, 75, 109, 210
 Turbinal cartilage, 107
 *Twixt brain, 149, 154
 Tympanic annulus, 93
 bone, 93
 cavity, 254
 membrane, 202
 Tympanum, 202
- U
- Ulna, 125
 Ulnar artery, 306
 Ulnare, 126
 Ultimobranchial bodies, 264
 Umbilical artery, 304, 316
 cord, 382
 veins, 310
 vesicle, 380
 vessels, 316
 Uncinate bone, 106
 process, 63
 Unguis, 31
 Ungulata, 7
 Unguligrade, 129
 Ureter, 344
 Urethra, 346, 370
 Urinary bladder, 345, 371
 organs, 334
 Urocyst, 345
 Urodela, 6
 Urogenital sinus, 349, 371
 system, 334
 Urohyal bone, 87, 106
 Uropygial glands, 34
 Urostyle, 58
 Uterus, 374, 382
 masculinus, 376
 Utriculus, 198
 Uvea, 217
- V
- Vagina, 374
 Vagus nerve, 190
 Vallecule, 170
 Valve of Vieussens, 153
 Valves of heart, 296
 Varolius, pons, 153
 Vasa efferentia, 349
 Vascular cells, 292
 system, 286
 Vas deferens, 349, 376

- Vater's corpuscle, 194
 Veins, 287, 307
 Velum medullare, 153, 173
 transversum, 148
 Vena cava, 314, 323
 Venous heart, 297
 Ventral fissure, 145
 aorta, 290, 296
 Ventricle, fifth, 160
 of heart, 290, 295
 of larynx, 273
 Ventricles of brain, 12, 150
 Vermiform appendix, 248
 Vermis, 153
 Vertebrae, 48
 development of, 51
 Vertebral canal, 49
 column, 48
 ribs, 61
 vein, 315
 Vertebrarterial canal, 61
 Vertebrata, characteristics of, 2
 classification of, 4
 geological distribution, 7
 Vesical artery, 304
 Vestibular nerve, 189
 Vestibule of nose, 209
 Vestibulum of ear, 198
 Vibrissæ, 38
 Vieussens, valve of, 153
 Villi of intestine, 243
 Visceral arches, 69
 clefts, 252
 muscles, 138
 nerves, 175
 pouches, 252
 skeleton, 67, 69
 Vitelline circulation, 309
 veins, 309, 310
 Vitreous body, 215
 Vocal cords, 271, 273
 Voluntary muscle, 25
 Vomer, 77
 Vomero-nasal organ, 212
- W
- Weber, nerve of, 204
 Weberian apparatus, 61, 269
 Whalebone, 232
 Wharton's duct, 237
 White matter, 25, 145
 Willis, circle of, 305
 Windpipe, 270
 Wirsung's duct, 250
 Wishbone, 117
 Wolffian body, 337
 duct, 343
 ridge, 337
- X
- Xiphiplastron, 46
 Xiphisternum, 65
 Xiphoid process, 63
- Y
- Yellow tissue, 27
 Yolk circulation, 309
 sac, 221, 379
 Ypsiloid cartilage, 119
- Z
- Zones of brain, 148
 Zonula ciliaris, 217
 zinnii, 217
 Zygantra, 58
 Zygapophysis, 49
 Zygomatic bone, 77
 Zygosphenæ, 58

